



Conservative treatment of pediatric thoracic and lumbar spinal fractures

Audrey Angelliaume, Anne-Laure Simon, Louis Boissière, Aurore Bouty, Jérôme Sales de Gauzy, Jean-Marc Vital, Olivier Gille, Clément Tournier, Stéphane Aunoble, Jean-Roger Pontailler, et al.

► To cite this version:

Audrey Angelliaume, Anne-Laure Simon, Louis Boissière, Aurore Bouty, Jérôme Sales de Gauzy, et al.. Conservative treatment of pediatric thoracic and lumbar spinal fractures. *Journal of Pediatric Orthopaedics B*, 2017, 26 (1), pp.73-79. 10.1097/BPB.0000000000000329 . hal-02310652

HAL Id: hal-02310652

<https://hal.science/hal-02310652>

Submitted on 10 Oct 2019

HAL is a multi-disciplinary open access archive for the deposit and dissemination of scientific research documents, whether they are published or not. The documents may come from teaching and research institutions in France or abroad, or from public or private research centers.

L'archive ouverte pluridisciplinaire **HAL**, est destinée au dépôt et à la diffusion de documents scientifiques de niveau recherche, publiés ou non, émanant des établissements d'enseignement et de recherche français ou étrangers, des laboratoires publics ou privés.




Open Archive Toulouse Archive Ouverte (OATAO)

OATAO is an open access repository that collects the work of Toulouse researchers and makes it freely available over the web where possible

This is an author's version published in: <http://oatao.univ-toulouse.fr/23134>

Official URL: <https://doi.org/10.1097/BPB.0000000000000329>

To cite this version:

Angelliaume, Audrey and Simon, Anne-Laure and Boissière, Louis and Bouty, Aurore and Sales de Gauzy, Jérôme  and Vital, Jean-Marc and Gille, Olivier and Tournier, Clément and Aunoble, Stéphane and Pontailier, Jean-Roger and Lefèvre, Yan *Conservative treatment of pediatric thoracic and lumbar spinal fractures*. (2017) Journal of Pediatric Orthopaedics B, 26 (1). 73-79. ISSN 1060-152X

Any correspondence concerning this service should be sent
to the repository administrator: tech-oatao@listes-diff.inp-toulouse.fr

Conservative treatment of pediatric thoracic and lumbar spinal fractures: outcomes in the sagittal plane

Audrey Angelliaume^a, Anne-Laure Simon^c, Louis Boissière^b, Aurore Bouty^a, Jérôme Sales de Gauzy^d, Jean-Marc Vital^b, Olivier Gille^b, Clément Tournier^b, Stéphane Aunoble^b, Jean-Roger Pontallier^a and Yan Lefèvre^a

To assess sagittal plane spinopelvic balance and functional outcomes in a pediatric cohort of patients with a thoracic and/or a lumbar fracture treated conservatively. A multicentric study retrospectively reviewed radiological and functional outcomes (mean follow-up 49 months) of 48 patients (mean age 12 years) with thoracic and/or lumbar spinal fractures that occurred between 1996 and 2014. Demographic data and radiological spinopelvic parameters were analyzed. Functional outcome was evaluated by a telephone interview. First, a comparison between the initial and the last follow-up full-spine radiographs was performed for the assessment of bone remodeling and sagittal plane balance. Then, patients were classified into two groups (group 1: Risser ≤ 2 and group 2, Risser > 2) to assess the influence of skeletal maturity on the restoration of a correct sagittal balance. A total of 62% of the patients were at skeletal maturity at the final follow-up (Risser 4 and 5). Patients with a Risser grade of 2 or less had a higher remodeling potential. The mean residual local kyphosis in thoracic and lumbar fractures was, respectively, 8.2° and 8.7°. The mean thoracic global kyphosis remains stable at the last follow-up, in contrast to lumbar lordosis, which increased significantly. Sagittal plane global measurements on the basis of the C7-plumbline remained unchanged at

the last follow-up. There was no change in the pelvic parameters, except for the sacral slope in the group 1 for patients with a lumbar fracture. The current study confirms a greater correction in younger patients (Risser ≤ 2) in spinal fractures and reported that thoracic fractures have a higher remodeling potential than lumbar fracture. A local kyphosis of almost 10° remained at the last follow-up. However, no deterioration in the sagittal plane balance was found. This suggests compensatory mechanisms in adjacent structures for children and adolescents and excludes the only hypothesis of bone remodeling. *J Pediatr Orthop B* 00:000–000 Copyright © 2016 Wolters Kluwer Health, Inc. All rights reserved.

Journal of Pediatric Orthopaedics B 2016, 00:000–000

Keywords: conservative treatment, growing spine, sagittal balance, spinopelvic parameters, thoracic and lumbar fractures

Departments of ^aPediatric Orthopaedics, ^bAdult Orthopaedics, Pellegrin University Hospital, Bordeaux, ^cDepartment of Pediatric Orthopaedics, Robert Debré Hospital, ap-hp, Paris and ^dDepartment of Pediatric Orthopaedics, Purpan University Hospital, Toulouse, France

Correspondence to Audrey Angelliaume, MD, Department of Pediatric Orthopaedics, Pellegrin University Hospital, Place Amélie Raba-Léon, 33076 Bordeaux, France
Tel: + 33 556 799 811; fax: + 33 556 799 855;
e-mail: angelliaume.audrey@gmail.com

Introduction

Spinal injuries in children are relatively rare (0.3–4% of pediatric traumatology) [1–4]. In comparison with adults, spinal fractures are uncommon because of the elasticity of capsule and ligaments; the incidence is 2–5% of overall spinal injuries [1]. The lesions are localized in the thoracic or the lumbar area in 20–60% of the cases [3]. Conservative treatment remains the first choice because of the potential bone remodeling and the low risk of vertebral loss of height. To the best of our knowledge, no study has analyzed radiological sagittal balance after thoracic or lumbar spinal fractures in children. Adjacent anatomical structures of the spine and the sacropelvis unit are connected, resulting in a stable and balanced posture [5–7]. Vertebral fractures create a vertebral kyphosis in children by an anterior wedging of the vertebral body, which alters the sagittal postural balance.

The aim of the present study was to investigate the potential of vertebral remodeling in a pediatric cohort of thoracic and lumbar fractures treated conservatively to highlight the risks of residual local kyphosis after a spinal fracture and to analyze radiological sagittal balance.

Materials and methods

Patients

A retrospective multicentric (two hospitals, three departments of surgery) study was carried out between 1996 and 2014. Patients were included using electronic medical records (Table 1). Inclusion criteria were as follows: age younger than 18 years and a lumbar and/or thoracic vertebra fracture. Exclusion criteria were as follows: a surgery during the first year after the accident, a neurologic deficiency, and a pre-existing scoliosis or

Table 1 Demographic data

Patient number	Age (months)	Sex	Injury date	Risser's grades	Y-cartilage	Mechanism of injury	Level of injury	Fracture	Osteoarticular associated lesions	Visceral associated lesion	Total follow-up (month)	Risser's grade at follow-up
1	146.4	F	26 February 2012	1	Closed	MVA	L2	B1	No	Jejunum wound	24	4
2	213.6	M	24 January 1996	4	Closed	Fall	T12	A1	Head injury	No	12	5
3	171.6	M	25 March 2011	0	Open	Fall	T12	A1	No	No	18	0
4	135.6	F	02 March 2011	0	Open	SA	T11	A1	No	No	36	5
5	175.2	F	02 February 2011	4	Closed	Fall	L1, L2	A1, A1	Ankle sprain		36	5
6	177.6	M	21 July 2010	0	Open	SA	T5	A1	No	No	42	4
7	124.8	F	29 June 2010	0	Open	Fall	T9	A1	No	No	48	5
8	165.6	M	23 November 2010	0	Closed	SA	T4	A1	No	No	54	4
9	166.8	F	20 November 2010	4	Closed	Fall	T10, T11	B1, A1	Transverses apophysis fractures T7–12, ankle sprain	Right pneumotorax, left pulmonary contusion pulmonaire	36	5
10	136.8	M	28 March 2012	0	Open	Fall	T12	A1	No	No	24	1
11	148.8	F	27 February 2010	0	Open	MVA	L2	B1	No	Liver and pulmonary wound	48	4
12	198	M	01 March 2009	4	Closed	MVA	T6, T7, T8, T9	A1	No	Cervical and forearm wound	60	5
13	201.6	M	21 May 2004	4	Closed	SA	L1	A1	Facial traumatism, rib, pelvis and tibial fractures	No	120	5
14	198	F	21 July 2003	5	Closed	Fall	L2	A1			48	5
15	164.4	F	16 April 2008	4	Closed	Fall	L1, L2, L3, L4, L5	A1	Right foot dislocation, open fracture of right leg, left wrist fracture		72	5
16	140.9	F	14 January 2007	0	Open	SA	T10	A1	No	No	36	4
17	142.8	F	13 December 2008	0	Open	SA	T6, T7, T8	A1, A1, A1	No	No	12	1
18	130.2	M	30 October 1998	0	Open	Fall	T11	A1	Head injury	No	24	0
19	31.7	M	15 March 2010	0	Open	Fall	T12	A1	No	No	48	0
20	132.4	F	12 October 2011	0	Open	SA	L1	A1	No	No	12	0
21	123.7	M	23 March 2003	0	Open	SA	T4, T5, T6	A1, A1, A1	No	No	24	0
22	186	F	15 December 2006	4	Closed	SA	L3, L4	A1, A1			101	5
23	156.7	F	12 July 1997	0	Closed	MVA	L1	A1	Pelvis fractures, head injury	No	36	5
24	189.6	M	12 June 2008	4	Closed	MVA	T6, T7, T8	A1, A1, A1	Head injury	Abdominal injury	66	5
25	120.9	F	27 February 2007	0	Open	SA	L2	A1	No	No	36	1
26	93.6	F	14 April 2007	1	open	SA	L1	A1			84	4
27	202.8	F	14 December 2008	4	Closed	Fall	L1, L2	A1, A1	Fractures of transverse apophysis T4–6, rib fractures	Pulmonary contusion	48	5
28	85.2	F	16 July 2008	0	Open	SA	T6, T7, T8, L1	A1, A1, A1, A1	No	No	66	5
29	200.4	M	10 December 2008	4	Closed	MVA	L5	A1	Left forearm, right femur and radius fractures, head injury	No	72	5
30	124.8	F	13 July 2005	0	Open	SA	T4, T5, T6	A1, A1, A1	No	No	24	3
31	105.6	M	19 February 2004	0	Open	MVA	L1	B1	No	Duodenal contusion	120	5
32	153.6	F	26 May 2005	3	Closed	SA	L1, L2, L3	A1, A1, A1				

33	108	M	10 December 2012	0	Open	SA	T8, T9	A1	No	No	24	0
34	134.4	M	08 July 2005	0	Open	Fall	T9	A1	No	No	24	0
35	128.4	F	08 January 2009	0	Open	SA	T6, T7, T8	A1	No	No	24	0
36	140	F	25 June 2001	1	Closed	Fall	L1	A1	No	No	24	4
37	183.6	M	07 April 2001	3	Closed	MVA	L1, L2, L3, L4	A1, A1, A1, A1	Right foot dislocation, sacrum fracture	Liver fracture	12	4
38	106.3	F	30 March 1993	0	Open	SA	T7, T8	A1, A1	No	No	72	5
39	150	F	15 July 2003	1	Open	MVA	T9	A1	Head injury	No	132	0
40	97.2	M	07 August 2010	0	Ouvert	SA	L1, L2	B1, A1	No	No	42	0
41	161.9	M	27 July 2003	0	Open	MVA	T8, T9	A1, A1	Head injury	No	12	0
42	106.8	F	13 July 2006	0	Open	SA	T7	A1	No	No	96	5
43	148.8	M	24 April 2008	0	Open	SA	L3	A1	No	No	18	3
44	205.2	F	14 January 2010	5	Closed	SA	L2	A1	No	No	48	5
45	180	M	13 December 1996	4	Closed	MVA	L1, L2	A1, A1	Face fracture	No	210	4
46	158.5	M	20 June 1998	0	Open	SA	L2	A1	Left foot and hand fractures	No	12	12
47	160.7	M	30 January 1998	0	Open	SA	L1	A1	No	No	12	12
48	195.6	F	26 February 2000	4	Closed	MVA	L1, L2	A1	Rib fractures	Left pneumothorax	12	5

MVA, motor vehicle accident; SA, sports accident.

spinal deformity. Patients' demographics data are summarized in Table 1.

Radiological analysis

Spinal measurements were performed using Surgimap Spine 2.0 imaging software (Nemaris Inc., New York, New York, USA). Fractures were classified according to the Magerl classification, which classifies thoracic and lumbar fractures according to the mechanism of injury: compression (type A), flexion-extension (type B), and rotation (type C) [8]. Full-spine standing radiographs were used and a pediatric orthopedic surgeon performed all the measurements. The first radiograph was performed during the first week after the trauma. Patients were treated by a brace or a cast, which was worn during the acquisition. At the last follow-up, radiographs were repeated without any orthopedic device. On lateral view radiographs, the following angles were measured: the local kyphosis, which measures the post-traumatic vertebrae deformity and corresponds to the angle between the lower and the upper end plate of the fracture. T4–T12 thoracic kyphosis and L1–L5 lumbar lordosis were measured to quantify the regional deformity after a thoracic and a lumbar fracture, respectively (Fig. 1). The pelvic parameters (PP) [pelvic incidence, pelvic tilt, and sacral slope (SS)] were measured to quantify pelvic adaptive mechanisms. The pelvic incidence is the angle between a line drawn from the center of the femoral head axis to the midpoint of the sacral plate and perpendicular to the center of the sacral plate. The pelvic tilt is the angle between the vertical line and the line connecting the middle of the sacral plate to the femoral head axis. The sacral slope is the angle between the horizontal line and the superior plate of the sacrum (Fig. 2). Global sagittal balance was assessed by measuring the C7 plumbline (Fig. 1). The measurement was considered positive if directed forwards and negative if directed backwards.

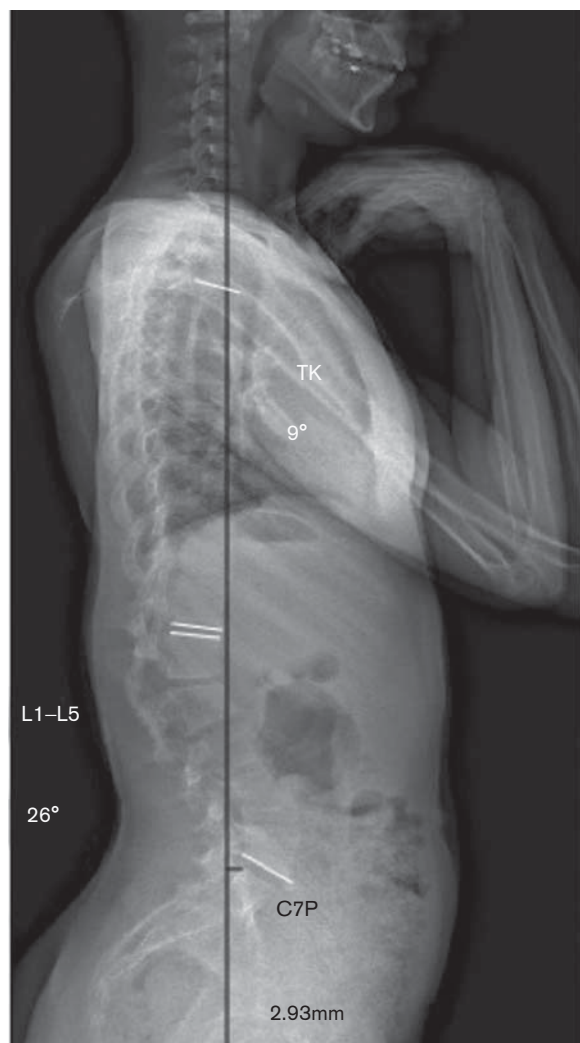
Analyses

Initial and final follow-up radiological measurements were compared. First, data were compared according to the level of the fracture between the thoracic fracture group and the lumbar fracture group. Second, the patients were classified into two groups according to the initial Risser grade to analyze the influence of skeletal maturity: group 1 (Risser 0, 1, and 2) and group 2 (Risser 3, 4, and 5).

Functional outcomes

At the last follow-up, a telephone interview was conducted to assess functional outcomes. Patients were asked about their pain, consumption of painkillers in relation to the spinal fracture, and return to initial recreational and professional activities.

Fig. 1



Sagittal plane global and local radiological angles: T4–T12 thoracic kyphosis (TK), L1–L5 lumbar lordosis (L1–L5), and C7-plumbline (C7P).

Statistical analysis

Statistical analyses were carried out using SPSS, version 12.0 (SPSS Inc., Chicago, Illinois, USA). Numeric data were expressed as mean and range. A two-tailed Student *t*-test was performed for comparison of the means. Statistically significant results were considered valid with a significance of *P*-value of less than 0.05.

Results

Patients' demographics data

Initially, an electronic search yielded to a total of 320 patients in center 1 and 41 patients in center 2. Forty-eight patients (23 males and 25 females) fulfilled the inclusion criteria (Fig. 3).

A total of 84 fractured vertebrae were analyzed, 43 thoracic fractures (T4–T12) and 41 lumbar fractures (L1–L5) (Table 2). Most fractures (89.6%) were Magerl A1 fractures. All of them were treated conservatively with a brace in 85.4% of the cases or with a cast in 14.6% of the cases. The cast was performed on a Cotrel table to apply external reduction maneuvers. The mean age of the patients at injury was 12.3 years (range 2.6–17.1), with a mean follow-up duration of 49 months. Of the total, 62% of the patients were at skeletal maturity at the final follow-up (Risser 4 and 5).

Comparison of thoracic fracture group and lumbar fracture group

The two groups were initially comparable in age, sex, initial Risser grade, mechanism of injury, and follow-up. The analysis confirmed the remodeling potential of young patients. In fact, local kyphosis decreased from 11.6° to 8.2° after thoracic fracture ($P=0.0007$) and from 11.3° to 8.7° after lumbar fracture ($P=0.07$). The L1–L5 lordosis after lumbar fracture increased significantly. The other parameters remain stable. There was no sagittal imbalance according to the C7-plumbline and there was no change in PP (Tables 3 and 4).

Comparison of group 1 and group 2

Initially, both groups were comparable in age, sex, mechanism of injury, and follow-up. Results confirmed the remodeling potential of the group 1, but were only significant for the thoracic fracture group. Local kyphosis decreased significantly from 12.2° to 7.9° ($P=0.0004$) in group 1 and for the thoracic fracture group. L1–L5 lumbar lordosis increased significantly for lumbar fracture in both groups 1 and 2. Thoracic kyphosis remained stable. Patients maintained correct sagittal alignment according to the C7 plumbline. There was no change in the PP, except for the SS, which was significantly increased for lumbar fractures in group 1 (Tables 5–8).

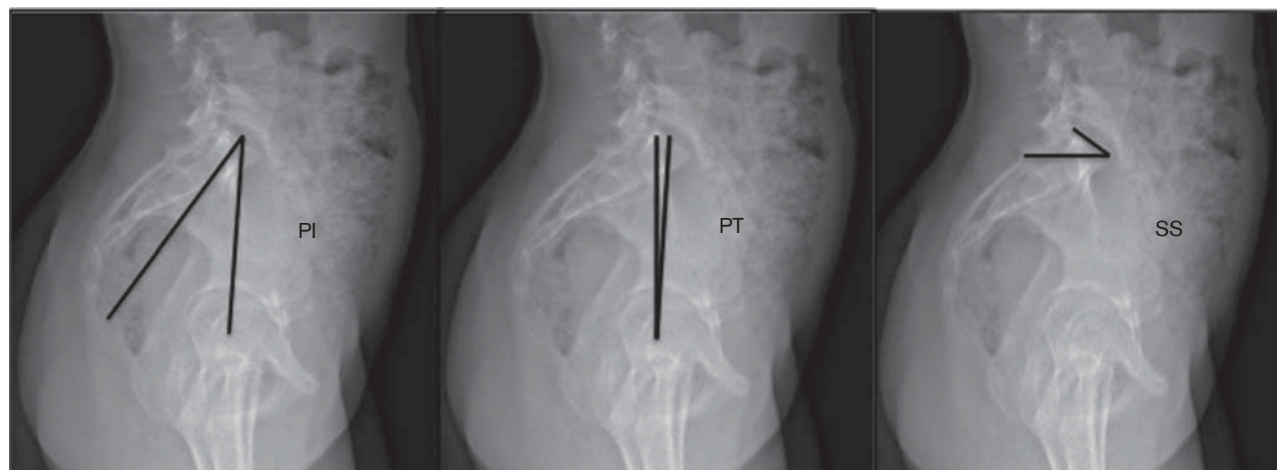Functional outcomes

Thirty-two patients were contacted by telephone: 81% reported back pain with no change in their quality of life or consumption of painkillers in 87.5% of the cases. Overall 97% patients returned to their normal professional activity or student schedule. Only one patient stopped his professional activity because of severe back pain. Mechanisms of injury were sport accidents in 50% of the cases, motor vehicle accidents in 26% of the cases, and falls in 23% (accidents or suicide attempts). Associated injuries were found in 42% of the cases in the current study, 33% associated fractures and 18.75% visceral injury.

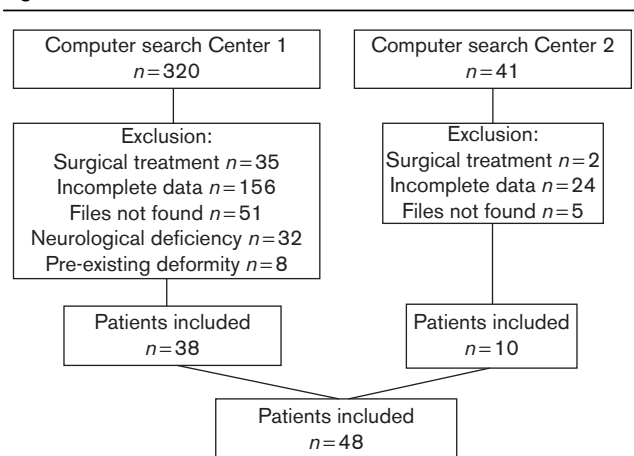
Discussion

Radiological findings

The current study reported no change in sagittal balance at the final follow-up, which can be attributed to the high

Fig. 2

Pelvic parameters: pelvic incidence (PI), sacral slope (SS), and pelvic tilt (PT).

Fig. 3

Study flow chart.

flexibility of spinal structures in the pediatric growing spine.

Data confirm the greater spinal correction of vertebra deformity in younger children (group 1: Risser 0, 1 and 2). This confirms that in case of a stable spinal fracture without neurological deficiency, conservative treatment must be the first treatment of choice in children.

Eight degrees of local kyphosis remained in the thoracic area, despite no change in sagittal parameters. Residual

vertebral kyphosis in thoracic spine does not affect global thoracic kyphosis and seems to have no effects on children's sagittal spinopelvic balance. However, at the lumbar level, data indicated an increased lumbar lordosis in contrast to the remaining 9° of local kyphosis at the last follow-up. These results suggest that structures other than bones are involved in post-traumatic sagittal compensatory mechanisms. In fact, measurement of the local kyphosis is a specific measure of the bone deformity. It measures the wedging of the vertebra, in contrast to thoracic kyphosis and lumbar lordosis, which measure the amount of soft tissue and bone deformity. Intervertebral discs may play a role as shown for scoliosis deformity and adult spinal deformities. Modi *et al.* [9] reported that disc wedging increased with the severity of adolescent idiopathic scoliosis. In a similar population, Schlosser *et al.* [10] analyzed the contribution of vertebral body and intervertebral discs in adolescent idiopathic scoliosis three-dimensional deformity. They showed that discs contribute more toward the three-dimensional deformity than the vertebra because of the intervertebral fibrocartilage, which is more flexible.

The significant difference between the initial and the final local kyphosis at the thoracic level was not found for the lumbar level. It is hypothesized that the brace is more efficient at the thoracic level than at the lumbar level and enables more remodeling, decreasing compressive forces by an antikyphotic effect. Furthermore, it is easier to correct a thoracic kyphosis than a lumbar one using an

Table 2 Level injury

Fracture level	T4	T5	T6	T7	T8	T9	T10	T11	T12	L1	L2	L3	L4	L5
Number of fractures	3	3	7	7	8	6	2	3	4	17	14	5	3	2

Table 3 Evolution of sagittal measurements on initial radiographs and on the final follow-up radiographs, thoracic fractures

	Local kyphosis (°)	Thoracic kyphosis (°)	L1–L5 lordosis (°)	Pelvic tilt (°)	Sacral slope (°)	Pelvic incidence (°)	C7 Plumb line (mm)
Initial (I)	11.6 (1–22)	35.8 (14–65)	34.9 (21–56)	10.1 (1–22)	37 (18–65)	47.9 (32–88)	–2.5 (–38.6 to 38.1)
Final (F)	8.2 (0–18)	39.6 (14–66)	34.2 (20–41)	9 (1–22)	36.1 (15–57)	46.3 (31–69)	–3.6 (–36.1 to 49)
P	$I > F$, $P = 0.0007$	> 0.05	> 0.05	> 0.05	> 0.05	> 0.05	> 0.05

Table 4 Evolution of sagittal measurements on initial radiographs and on the final follow-up radiographs, lumbar fractures

	Local kyphosis (°)	L1–L5 lordosis (°)	Pelvic tilt (°)	Sacral slope (°)	Pelvic incidence (°)	C7 Plumb line (mm)
Initial (I)	11.3 (1–29)	27.3 (14–43)	12.3 (1–28)	36.4 (24–47)	49.2 (37–66)	–6.8 (–53.9 to 40.6)
Final (F)	8.7 (0.23)	37.6 (17–64)	9.5 (1–30)	40.1 (28–56)	46.9 (20–62)	–3.8 (–18.25 to 12)
P	0.07	$F > I$, $P = 0.001$	> 0.05	> 0.05	> 0.05	> 0.05

Table 5 Results of subgroup Risser grades 0, 1, and 2, thoracic fractures

	Local kyphosis (°)	Thoracic kyphosis (°)	L1–L5 lordosis (°)	Pelvic tilt (°)	Sacral slope (°)	Pelvic incidence (°)	C7 Plumb line (mm)
Initial (I)	12.2 (1–22)	34.5 (14–60)	35.9 (25–56)	10.3 (1–28)	38.1 (31–65)	47.1 (34–88)	–1.2 (–38.6 to 38.1)
Final (F)	7.9 (1–18)	38.3 (14–66)	34.6 (26–41)	6.8 (1–16)	36.6 (17–47)	45.8 (31–62)	–3.4 (–45.4 to 49)
P	$I > F$, $P = 0.0004$	> 0.05	> 0.05	> 0.05	> 0.05	> 0.05	> 0.05

Table 6 Results of subgroup Risser grades 3, 4, and 5, thoracic fractures

	Local kyphosis (°)	Thoracic kyphosis (°)	L1–L5 lordosis (°)	Pelvic tilt (°)	Sacral slope (°)	Pelvic incidence (°)	C7 Plumb line (mm)
Initial (I)	9.8 (6–20)	41.3 (28–65)	30.7 (21–44)	10.5 (3–18)	34 (18–56)	49.8 (22–65)	–8.65 (–11.4 to –5.9)
Final (F)	9.3 (5–17)	43 (37–53)	32 (20–39)	11.3 (2–17)	33.7 (15–57)	48.7 (30–69)	–4.6 (–31.5 to 19.3)
P	> 0.05	> 0.05	> 0.05	> 0.05	> 0.05	> 0.05	> 0.05

Table 7 Results of subgroup Risser grades 0, 1, and 2, lumbar fractures

	Local kyphosis (°)	L1–L5 lordosis (°)	Pelvic tilt (°)	Sacral slope (°)	Pelvic incidence (°)	C7 Plumb line (mm)
Initial (I)	13.5 (4–28)	26.8 (14–43)	10.3 (1–28)	34.9 (24–42)	46.2 (36–66)	–7.8 (–18.2 to –2.1)
Final (F)	10.2 (1–23)	35.1 (17–52)	6.8 (1–16)	42.3 (28–56)	47.8 (20–62)	–0.1 (–5 to 5.3)
P	> 0.05	$F > I$, $P = 0.02$	> 0.05	$F > I$, $P = 0.02$	> 0.05	> 0.05

Table 8 Results of subgroup Risser grades 3, 4, and 5, lumbar fractures

	Local kyphosis (°)	L1–L5 lordosis (°)	Pelvic tilt (°)	Sacral slope (°)	Pelvic incidence (°)	C7 Plumb line (mm)
Initial (I)	8.6 (1–29)	28.4 (25–31)	16.4 (3–24)	39 (28–47)	55.2 (39–65)	–5.7 (–53.9 to 40.6)
Final (F)	6.9 (1–17)	42.3 (26–64)	13.7 (6–30)	36.5 (30–41)	46.7 (35–61)	–7.5 (–18.2 to 12)
P	$P > 0.05$	$F > I$, $P = 0.05$	> 0.05	> 0.05	> 0.05	> 0.05

antikyphotic brace. Roaf [11] have reported these bio-mechanical laws and they described the vicious cycle of thoracic kyphosis in Scheuermann's disease. According to the vicious cycle, small vertebral wedging produces abnormal compressive forces on the vertebral end plate, which increase the wedged deformity further, thus producing further abnormal forces.

The current study found no change in the PP at the final follow-up, except for the sacral slope in the lumbar fractures of group 1. The results of sagittal parameter values (PP, pelvic incidence, SS, thoracic kyphosis, lumbar lordosis) are also consistent with the literature [5,12]. Spinal adaptive mechanisms are more involved after a vertebral

fracture than pelvic ones. Increased sacral slope in a lumbar fracture is compensatory to increased lumbar lordosis. Surprisingly, this result was found only in group 1.

Functional outcomes

Functional results indicated a high rate of back pain. However, patients' functional results were satisfactory because they reported no limitations in their daily life activities and did not use painkillers. Variable rates of functional outcomes have been reported, with 12–57% incidences of back pain after a conservative treatment [1,4,13,14]. However, rates of back pain in adolescents without back injury are also high, with a prevalence of 7–70% [14–16].

Mechanisms of injury and the percentage of associated lesions were similar to those in the literature [17–19], with 42–65% of associated injuries (5–50% of skull or long bone fracture and 20–37% of visceral injuries) [3,18,20].

Limitations

The retrospective design is responsible for the heterogeneous data in the medical records. However, the current study is the first to include only pediatric patients with similar spinal fractures. The initial and the follow-up examination and radiological assessment were performed by the same surgeon. Although the values of ‘normal’ thoracic kyphosis and lumbar lordosis in the general population are variable [21], these are stable during childhood [8,22,23], enabling a comparison between the initial and the final values. Moreover, these values are similar for males and females until 40 years of age [24]. The initial radiological measures were performed on standing full-spine radiographs, with the patient wearing a brace or a cast. This might have influenced the sagittal parameter measurements. However, an initial assessment was necessary for comparison. Radiographs performed for the diagnosis of the fracture were performed with the patients in a supine position, which is not a suitable position to assess sagittal balance. This is why the authors decided to obtain radiographs in the standing position with the patient in a brace or a cast even if the brace or the cast modified the post-traumatic sagittal curves.

This study confirms that patients with a Risser 2 or less have a high growth potential, which enables the correction of post-traumatic local kyphosis. Thoracic fractures have a higher remodeling potential than lumbar fractures. At the final follow-up, a local kyphosis of almost 10° remained, but sagittal balance was still maintained. The results suggest that there are adaptive mechanisms in adjacent structures. Therefore, bone remodeling is not the only mechanism involved in pediatric spinal fractures.

Acknowledgements

Conflicts of interest

There are no conflicts of interest.

References

- 1 Parisini P, Di Silvestre M, Gregg T. Treatment of spinal fractures in children and adolescents: long-term results in 44 patients. *Spine* 2002; **27**:1989–1994.

- 2 Rush JK, Kelly DM, Astur N, Creek A, Dawkins R, Younas S, *et al.* Associated injuries in children and adolescents with spinal trauma. *J Pediatr Orthop* 2013; **33**:393–397.
- 3 Sayama C, Chen T, Trost G, Jea A. A review of pediatric lumbar spine trauma. *Neurosurg focus* 2014; **37**:E6.
- 4 Karlsson MK, Moller A, Hasseri R, Besjakov J, Karlsson C, Ohlin A. A modeling capacity of vertebral fractures exists during growth: an up-to-47-year follow-up. *Spine* 2003; **28**:2087–2092.
- 5 Mac-Thiong JM, Labelle H, Berthodnaud E, Betz RR, Roussouly P. Sagittal spinopelvic balance in normal children and adolescents. *Eur Spine J* 2007; **16**:227–234.
- 6 Berthodnaud E, Dimnet J, Roussouly P, Labelle H. Analysis of the sagittal balance of the spine and pelvis using shape and orientation parameters. *J Spinal Disord Tech* 2005; **18**:40–47.
- 7 Bernhardt M, Bridwell KH. Segmental analysis of the sagittal plane alignment of the normal thoracic and lumbar spines and thoracolumbar junction. *Spine* 1989; **14**:717–721.
- 8 Magerl F, Aebi M, Gertzbein SD, Harms J, Nazarian S. A comprehensive classification of thoracic and lumbar injuries. *Eur Spine J* 1994; **3**:184–201.
- 9 Modi HN, Suh SW, Song HR, Yang JH, Kim HJ, Modi CH. Differential wedging of vertebral body and intervertebral disc in thoracic and lumbar spine in adolescent idiopathic scoliosis – a cross sectional study in 150 patients. *Scoliosis* 2008; **3**:11.
- 10 Schlosser TP, van Stralen M, Brink RC, Chu WC, Lam TP, Vincken KL, *et al.* Three-dimensional characterization of torsion and asymmetry of the intervertebral discs versus vertebral bodies in adolescent idiopathic scoliosis. *Spine* 2014; **39**:1159–1166.
- 11 Roaf R. Vertebral growth and its mechanical control. *J Bone Joint Surg Br* 1960; **42**:40–59.
- 12 Mac-Thiong JM, Labelle H, Roussouly P. Pediatric sagittal alignment. *Eur Spine J* 2011; **20**:S586–S590.
- 13 Moller A, Hasseri R, Redlund-Johnell I, Ohlin A, Karlsson MK. Nonoperatively treated burst fractures of the thoracic and lumbar spine in adults: a 23- to 41-year follow-up. *Spine J* 2007; **7**:701–707.
- 14 Kerttula LI, Serlo WS, Tervonen OA, Paakko EL, Vanharanta HV. Post-traumatic findings of the spine after earlier vertebral fracture in young patients: clinical and MRI study. *Spine* 2000; **25**:1104–1108.
- 15 Bjorck-van Dijken C, Fjellman-Wiklund A, Hildingsson C. Low back pain, lifestyle factors and physical activity: a population based-study. *J Rehabil Med* 2008; **40**:864–869.
- 16 Grauers A, Topalis C, Moller H, Normelli H, Karlsson M, Danielsson A, *et al.* Prevalence of back problems in 1069 adults with idiopathic scoliosis and 158 adults without scoliosis. *Spine* 2014. [Epub ahead of print].
- 17 Yaszay B. Pediatric spinal trauma. *Spine secrets plus*, 2nd ed. St Louis, MO: Elsevier Mosby; 2012, pp. 304–310.
- 18 Erfani MA, Pourabbas B, Nouraei H, Vadiiee I, Vosoughi AR. Results of fusion and instrumentation of thoracic and lumbar vertebral fractures in children: a prospective ten-year study. *Musculoskelet Surg* 2014; **98**:107–114.
- 19 Mahan ST, Mooney DP, Karlin LI, Hresko MT. Multiple level injuries in pediatric spinal trauma. *J Trauma* 2009; **67**:537–542.
- 20 Denis F. Thoracolumbar spine trauma. *Moe's textbook of scoliosis and other spinal deformities*, 3rd ed. London: W.B. Saunders; 1995. pp. 430–450.
- 21 Stagnara P, De Mauroy JC, Dran G, Gonon GP, Costanzo G, Dimnet J, *et al.* Reciprocal angulation of vertebral bodies in a sagittal plane: approach to references for the evaluation of kyphosis and lordosis. *Spine* 1982; **7**:335–342.
- 22 Boseker EH, Moe JH, Winter RB, Koop SE. Determination of ‘normal’ thoracic kyphosis: a roentgenographic study of 121 ‘normal’ children. *J Pediatr Orthop* 2000; **20**:796–798.
- 23 Cil A, Yazici M, Uzumcugil A, Kandemir U, Alanay A, Alanay Y, *et al.* The evolution of sagittal segmental alignment of the spine during childhood. *Spine* 2005; **30**:93–100.
- 24 Fon GT, Pitt MJ, Thies AC Jr. Thoracic kyphosis: range in normal subjects. *Am J Roentgenol* 1980; **134**:979–983.