



## **Prenatal imaging of genital defects: clinical spectrum and predictive factors for severe forms**

Florent Fuchs, Paula Borrego, Cyril Amouroux, Benoît Antoine, Margot Ollivier, Jean-Michel Faure, Christophe Lopez, Dominique Forgues, Alice Faure, Thierry Merrot, et al.

### **► To cite this version:**

Florent Fuchs, Paula Borrego, Cyril Amouroux, Benoît Antoine, Margot Ollivier, et al.. Prenatal imaging of genital defects: clinical spectrum and predictive factors for severe forms. BJU International, 2019, 10.1111/bju.14714 . hal-02281648

**HAL Id: hal-02281648**

**<https://hal.science/hal-02281648>**

Submitted on 27 Jul 2023

**HAL** is a multi-disciplinary open access archive for the deposit and dissemination of scientific research documents, whether they are published or not. The documents may come from teaching and research institutions in France or abroad, or from public or private research centers.

L'archive ouverte pluridisciplinaire **HAL**, est destinée au dépôt et à la diffusion de documents scientifiques de niveau recherche, publiés ou non, émanant des établissements d'enseignement et de recherche français ou étrangers, des laboratoires publics ou privés.

# Prenatal imaging of genital defects: clinical spectrum and predictive factors for severe forms

Florent Fuchs\*, Paula Borrego<sup>†‡</sup>, Cyril Amouroux<sup>‡§¶</sup>, Benoît Antoine\*, Margot Ollivier<sup>†‡¶</sup>, Jean-Michel Faure\*, Christophe Lopez<sup>†‡¶</sup>, Dominique Forgues<sup>†‡</sup>, Alice Faure\*<sup>ID</sup>, Thierry Merrot\*, Pierre Boulot\*, Claire Jeandel<sup>‡§¶</sup>, Pascal Philibert<sup>‡§¶</sup>, Laura Gaspari<sup>‡§¶</sup>, Charles Sultan<sup>‡§¶</sup>, Françoise Paris<sup>‡§¶</sup> and Nicolas Kalfa<sup>†‡¶</sup>

\*Service de Gynécologie-Obstétrique, Hôpital Arnaud de Villeneuve – CHU Montpellier, <sup>†</sup>Unité de Chirurgie Viscérale et Urologique Pédiatrique, Hôpital Lapeyronie – CHU Montpellier, <sup>‡</sup>Université de Montpellier, <sup>§</sup>Unité d'Endocrinologie-Gynécologie Pédiatrique, Département de Pédiatrie, Hôpital Arnaud de Villeneuve – CHU Montpellier, <sup>¶</sup>National Reference Network DSD DevGen, Centre Constitutif Sud. – CHU Montpellier, Montpellier, and \*\*Service de Chirurgie Pédiatrique, Hôpital La Timone, APHM, Marseille, France

F.F. and P.B. contributed equally to this work

## Objectives

To report the clinical spectrum of genital defects diagnosed before birth, identify predictive factors for severe phenotypes at birth, and determine the rate of associated malformations.

## Patients and methods

A retrospective study (2008–2017) of 4580 fetuses, identified prenatally with abnormalities evaluated by our Reference Center for Fetal Medicine, included cases with fetal sonographic findings of abnormal genitalia or uncertainty of fetal sex determination. Familial, prenatal and postnatal data were collected via a standardised questionnaire.

## Results

In all, 61 fetuses were included. The positive predictive value (PPV) of the prenatal diagnosis of genital defects was 90.1%. Most cases were 46,XY-undervirilized boys, 42 cases (68.8%), which included 29 with mid-penile or posterior hypospadias, nine with anterior hypospadias, and epispadias, micropenis, scrotal transposition, and buried penis (one each). In all, 46, XX-virilized girls were identified in seven cases (11.5%), which included four with congenital adrenal hyperplasia, two

with isolated clitoromegaly, and one with ovotestis. Other defects included prune belly syndrome and persistent cloaca (six cases). Early detection during the second trimester (58.1% vs 18.8%,  $P = 0.03$ ), intra-uterine growth restriction (IUGR) (45.2% vs 9.1%,  $P = 0.06$ ), and curvature of the penis (38.7% vs 0%,  $P = 0.02$ ), were more frequently related to severe defects in male newborns. Associated malformations (14 cases, 22.9%) and genetic defects (six) were frequent in undervirilized boys.

## Conclusion

Prenatal imaging of genital defects leads to a wide range of phenotypes at birth. Its PPV is high and extra-urinary malformations are frequent. Early diagnosis during the second trimester, associated IUGR, and curvature of the genital tubercle, should raise suspicion of a severe phenotype and may justify delivery near a multidisciplinary disorders/differences of sex development team.

## Keywords

Hypospadias, disorders/differences of sex development (DSD), congenital adrenal hyperplasia, prenatal diagnosis, ultrasonography, prognostic factors

## Introduction

Genital abnormalities represent one of the most frequent congenital defects and include a wide spectrum of phenotypes, ranging from isolated minor hypospadias to severe developmental abnormalities with undetermined sex at birth. The average incidence varies according to the phenotype from 1/300 to 1/10 000, and may increase in specific geographical areas and in some ethnic groups [1]. Genital abnormalities can be related to genetic mutations or

variants [2], endocrine disorders [3], maternal exposure to environmental endocrine disrupting chemicals [4,5], or they may remain unexplained. In their more severe forms, genital abnormalities recapitulate the disorders/differences of sex development (DSD), which are defined as congenital conditions with a discrepancy between chromosomal, gonadal or anatomical sex [6].

Technological advances in ultrasonography (US) and expertise in fetal US have resulted in earlier and improved detection of

congenital abnormalities [7]. Unfortunately, the prenatal diagnosis of genital abnormalities remains inaccurate compared to other defects [8–12] and the diagnosis of genital malformations is still performed at birth in the vast majority of cases. In cases of a prenatal suspicion of a genital abnormality, reliable predictive factors that could point toward the most severe forms of genital malformations are still lacking [10]. Detecting these severe phenotypes would be of great interest, as they require a complete anatomical, hormonal and genetic evaluation in a timely manner at birth by a multidisciplinary and expert team. This accurate prenatal screening would thus be helpful to support parental counselling, to optimise early postnatal management and to avoid its pitfalls [8,9,13].

The aims of the present study were to report the clinical spectrum of genital defects diagnosed before birth, determine the rate of associated defects, and identify predictive factors for severe phenotypes that require specific DSD management at birth.

## Patients and methods

### Patients' inclusion

Between January 2008 and August 2017, ~250 000 pregnant women underwent a routine fetal US screening in the region of our Reference Center for Fetal Medicine. In France, prenatal follow-up includes three systematic prenatal US scans supported by the national health insurance system. They are performed at 11–14 weeks of gestation (first trimester), 22–24 weeks of gestation (second trimester), and 32–34 weeks of gestation (third trimester). Women were referred to the multidisciplinary Reference Center for Fetal Medicine in cases of visualisation of a genital defect or in cases of uncertainty of fetal sex determination despite repeated US scans (i.e., change in sex determination during pregnancy or visualisation of undifferentiated genitalia, or discordance between US findings and fetal karyotype if performed). During this period all of these cases were retrospectively and anonymously included. Fetuses with bladder exstrophy, cloacal exstrophy, and isolated undescended testis (absence of testis in the scrotum on transverse and parasagittal scans of the scrotum) were excluded. The local ethics committee (Centre de Protection des Personnes Sud Méditerranée 4, CPPSMIV) approved this study (Reference number: CPP-SM4-Q20171001).

### Data collection

For every case, a standardised questionnaire was used to collect familial, prenatal and postnatal data. Familial data included: history of genital abnormalities, outcomes of previous pregnancies, and other congenital defects. General data of the current pregnancy included: gestational age at diagnosis of the fetal malformation, biometric measurements

(biparietal diameter, head circumference, abdominal circumference, and femur length) to screen for intra-uterine growth restriction (IUGR) and integrated risk of trisomy 21. Prenatal anatomical data focused on curvature of the genital tubercle, aspect of the genital folds, position of the gonads, and visualisation of the müllerian ducts. Hypospadias was diagnosed by a transverse US scan showing an enlarged distal part of the penis corresponding to the cutaneous dorsal hood, and a sagittal scan of the genital tubercle demonstrating a ventral curvature, a direct visualisation of a shortened urethra, and an ectopic meatus during micturition. The length of the genital tubercle was not used in this study as it was not reproducible enough. Finally, a global US examination of the fetus was also performed to exclude other associated defects.

Postnatal data were collected by a paediatric urologist and/or endocrinologist and included: gestational age at birth, birth weight, birth size, size of the stretched penis on its dorsal face, numbers of urinary and genital openings, level of division of corpus spongiosum if any, position of the gonads, aspect of the genital folds (fusion and their position related to the tubercle), and associated malformations and syndromes. The same data were collected by a fetopathologist in cases of termination of the pregnancy. In cases of DSDs, endocrine evaluation (usually performed during the mini-puberty) and results of the karyotype and molecular analyses were also collected.

### Statistical analysis

First, a descriptive analysis of the population was carried out. Patients' characteristics are presented using the median and range for continuous variables and frequencies for categorical variables. Then to identify predictive factors for severe phenotypes in male fetuses, we compared the group of fetuses with severe genital defects, with a less favourable functional and cosmetic outcome (defined as existence of a posterior and mid-penile hypospadias, or micropenis, or epispadias), to non-severe ones (defined as the presence of an anterior and glanular hypospadias, or isolated scrotal transposition, or isolated concealed penis). Comparison between those groups was assessed using a chi-squared test or Fisher's exact test for qualitative variables as appropriate using R<sup>®</sup> software (version 2.13.1; R: A language and environment for statistical computing. R Foundation for Statistical Computing, Vienna, Austria). For all tests a  $P < 0.05$  was considered as statistically significant.

## Results

### Prenatal US and postnatal findings

From January 2008 to August 2017, 4580 cases of fetal abnormalities were evaluated by our Reference Center for

Fetal Medicine. Amongst those cases, 61 fetuses (1.6%) with genital defects were included. The prenatal diagnoses were hypospadias in 31 cases, clitoral hypertrophy in 10, uncertainty of sex determination in seven, micropenis in six, isolated labial hypertrophy in two, discordance between external genitalia and fetal karyotype in one, and other unusual genital defects in four (megalourethra, triangular shaped penis). The postnatal findings are summarised in Table 1. Most of the newborns were undervirilized 46,XY boys (42 cases, 68.9%). The most frequent phenotype was hypospadias (38 cases, 29 posterior and mid-penile, and nine anterior). Seven newborns (11.5%) were virilized 46,XX girls, mainly represented by congenital adrenal hyperplasia (four cases). Other diagnoses included persistent cloaca and prune belly syndrome, all of them initially detected by an external atypical aspect of their genitalia (six cases, 9.8%). Amongst the 61 newborns, six (9.8%) were finally considered as 'normal' at birth.

The overall positive predictive value (PPV) of the prenatal diagnosis of genital defects was 90.1%, and higher in boys than in girls (93.8% vs 76.9%,  $P = 0.1$ ), but this did not reach statistical significance. Prenatal US findings were particularly well correlated with postnatal phenotype in male fetuses. Hypospadias was the most reliable diagnosis and was correctly diagnosed during pregnancy in 76.3% of cases (29/38). Other circumstances of hypospadias screening were uncertainty of sex determination (six cases), micropenis (one), clitoral hypertrophy (one), and discordance between US findings and fetal karyotype (one; Fig. 1). In the six normal newborns, the suspected prenatal findings were hypospadias (two cases), clitoral hypertrophy (two), labia majora hypertrophy (one), and uncertainty of sex determination (one).

**Table 1** Clinical phenotypes found at birth after a prenatal diagnosis of genital abnormality.

Prenatal diagnosis of genital abnormality	Phenotype found at birth	N
46XY DSD, $n = 42$ (68.9%)	Posterior / mid-penile hypospadias	29
	Anterior / glanular hypospadias	9
	Isolated micropenis	1
	Epispadias	1
	Concealed penis	1
46XX DSD, $n = 7$ (11.5%)	Isolated penoscrotal transposition	1
	Congenital adrenal hyperplasia	4
	Isolated transient clitoromegaly	2
Other DSD, $n = 6$ (9.8%)	46 XX Ovotestis	1
	Prune belly	3
	Persistent cloaca	3
Normal genitalia, $n = 6$ (9.8%)	Normal boy	3
	Normal girl	3

*The child with ovotestis had a 46,XX karyotype and the diagnosis was confirmed by pathological study. The child with isolated penoscrotal transposition had neither covered hypospadias nor micropenis. The children with isolated transient clitoromegaly had a normal hormonal profile at birth, a 46,XX karyotype and a spontaneous regression of the clitoromegaly that remained unexplained.*

## Prenatal predictive factors for severe genital defects in males at birth

We then aimed to determine if some prenatal findings might be associated with severe phenotypes in male fetuses. According to our definitions, 31 male fetuses had a severe genital defect with a less favourable functional and cosmetic outcome in comparison to 11 non-severe ones. First, the prenatal detection of the genital defect was earlier (i.e., during the second trimester) in fetuses with a severe phenotype than in those with a non-severe one [18 (58.1%) vs two (18.8%);  $P = 0.03$ ]. Second, IUGR was more commonly associated with severe defects [14 (45.2%) vs one (9.1%);  $P = 0.06$ ]. Lastly, the prenatal visualisation of a curvature of the penis was more frequently related to severe defects in male newborns at birth than in others [12 (38.7%) vs 0;  $P = 0.02$ , Fig. 2]. Neither a familial history of genital defects [eight (25.8%) vs two (18.2%);  $P = 1$ ] nor the inguinal position of the gonads [three (9.7%) vs one (9.1%);  $P = 1$ ] was predictive of severe phenotypes. The prenatal estimation of penile length was not reproducible enough to be of prognostic value in our series (variations according to the term of pregnancy, IUGR, and low reproducibility between examiners, data not shown).

## Associated malformations and genetic defects

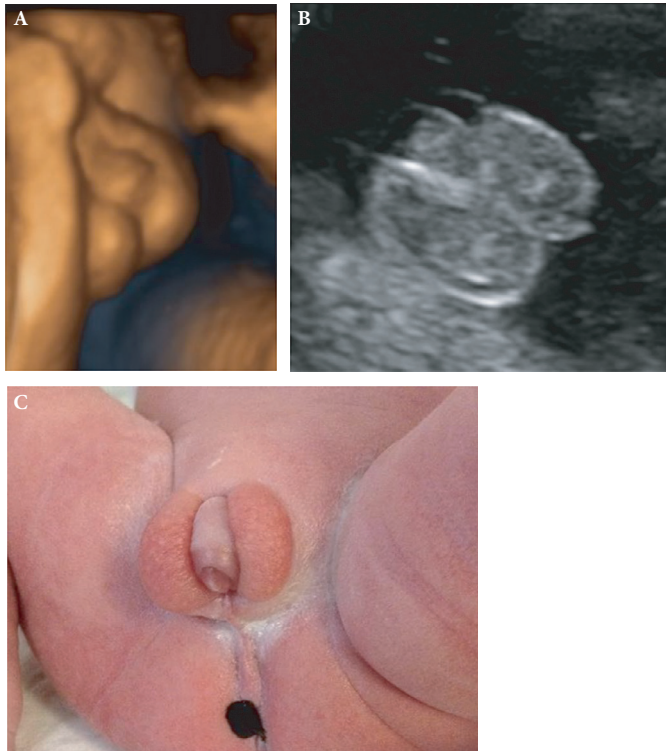
The overall prevalence of associated malformations in our series was high (14 cases, 22.9%). Eight of the 42 undervirilized boys had an additional defect that included: hexadactyly, syndactyly, cleft palate, Pierre Robin sequence, Fallot tetralogy, inter-atrial communication, aortic coarctation, corpus callosum hypoplasia, omphalocele, and doubled kidney with dysplastic upper pole. In the virilized girls, no associated malformation was reported but a simple ovarian cyst was observed in two out of four fetuses with congenital adrenal hyperplasia.

In three cases prune belly syndrome was diagnosed. The atypical external genitalia appeared as a megalourethra (one case), a triangular shape penis (one) or a micropenis (one) before birth. In these fetuses, associated malformations were megacystis (three cases), bilateral ureterohydronephrosis (two), and undescended testis (two).

In three cases the genital abnormalities (clitoromegaly and difficulties in fetal sex determination) led to a diagnosis of persistent cloaca. Associated defects were bilateral hydronephrosis (two cases), hydrometrocolpos (three), renal abnormality (two, ectopic kidney and horseshoe kidney), cleft palate (one), and vascular abnormality (two aneurisms of the umbilical vein with dilation of the superior vena cava, single umbilical artery).

Genetic defects were identified in six of the undervirilized boys. Cytogenetic studies revealed a partial trisomy of the

**Fig. 1** A case of prenatal diagnosis of genital abnormality. The diagnosis was performed during the second trimester of pregnancy. Presented images were taken at the 32nd week of gestation. The three-dimensional (A) and two-dimensional (B) US images show a ventrally curved genital tubercle (arrow) and two gonads in the genital folds (stars). C, shows the phenotype at birth. The serum testosterone and anti-müllerian hormone levels were normal. There was no residual müllerian duct detectable at US. The sex-determining region of Y chromosome (SRY) gene was present and the sequence of the AR gene was normal. The karyotype identified a partial trisomy on the chromosome 2p (26 Mb) and a 12p monosomy (409 Kb) inherited from the mother (46,XX,t(2;12)(p23;p13.3)).

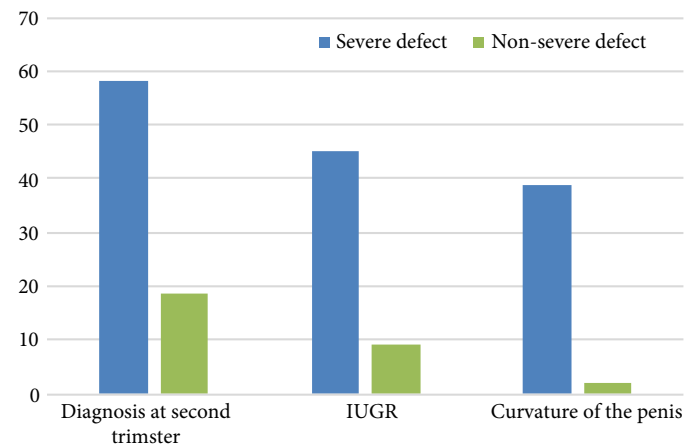


chromosome 2p with a 12p monosomy in one case and a deletion of a part of the chromosome 10 in another case (del 10q26.12). Molecular studies showed mutations of the androgen receptor (AR) gene in three cases (p.Asp257Asn, p.Ala597Thr, p.Ala720Thr) and a mutation of the steroidogenic factor 1 gene (SF1) in one case (p.Arg92Trp).

## Discussion

Fetal sex determination is part of routine evaluation of the genitourinary tract during pregnancy. Beyond parental curiosity [14], it provides important information for perinatal management of sex-linked disorders, such as sex-related congenital malformations (posterior urethral valves in boys, ovarian cysts and Turner's syndrome in girls) [8] and X-linked genetic diseases (haemophilia and Duchenne's muscular dystrophy) [15]. The accuracy of sex determination is very high, ~98–100% at 20 weeks of gestation [16]. Based

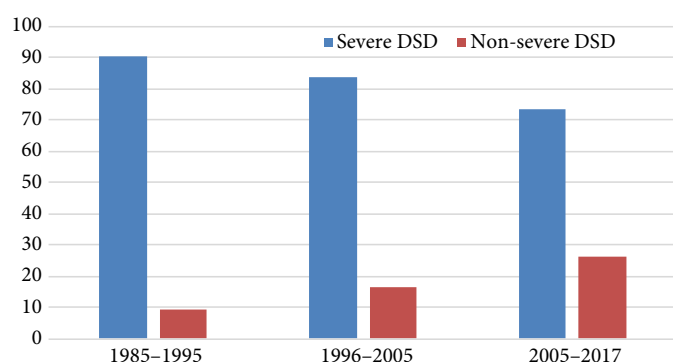
**Fig. 2** Comparison of the gestational age at diagnosis, of the association with IUGR, and of the curvature of the genital tubercle, in both severe and non-severe phenotype groups. Severe genital defects in boys are those with a less favourable functional and cosmetic outcome and are defined in the text.



on indirect signs, such as the angle between the genital tubercle and the horizontal line in the sagittal plane [17], earlier determination is even possible at 13 weeks despite the lack of difference in size between the penis and the clitoris at this time.

Beside this routine and well-codified determination of fetal sex, prenatal identification of genital abnormalities remains a rare finding compared to other defects. Even though the first cases of prenatal diagnosis of genitalia abnormalities were reported >30 years ago [18], large series remain sparse in literature. More specifically, the accuracy of prenatal imaging of genitalia defects remains disputable, as a wide spectrum of phenotypes is still possible at birth, ranging from newborns with normal genitalia to severe DSD or complex urological defects and syndromes, such as persistent cloaca [19]. Recent studies are even more likely to face this variability, as minor phenotypes that were rarely detected in the past are more commonly identified before birth today (Fig. 3) [8,10–12,15,19–21,30–35]. Despite this wide clinical variability, the PPV of prenatal screening has improved. In the present study, the overall PPV of the prenatal diagnosis of genital defects was >90%. Children may exhibit normal genitalia at birth despite a prenatal diagnosis of hypospadias and clitoral hypertrophy. Such false positives may cause anxiety to family members. Fortunately, such situations are increasingly less frequent with an increasing PPV since the 2000s (79% in 2000 [8], 84% in 2014 [10]). The recent developments in high-resolution US equipment and the improved assessment of the developing fetal genitalia [14] may explain these enhancements. However, most genital abnormalities remain undiagnosed before birth with repeated normal scans [12]. Unfortunately, our present study was not designed to investigate the sensitivity, specificity, and negative predictive

**Fig. 3** Relative proportions of severe vs non-severe DSD in the literature since 1985. Time periods of 10 years have been defined arbitrary to identify significant trends in time. A total of 14 publications are summated in this figure including 167 fetuses. Severe and non-severe DSDs were retrospectively attributed in each study according to the definition we propose in the text. The relative proportion of minor phenotypes increases with time and experience. The repartition of phenotypes is not significantly different between the 1985–1995 vs the 1996–2005 periods ( $P = 0.55$ , Fisher's exact test) and vs the 2006–2017 period ( $P = 0.09$ ). Studies included in this figure are [8,10–12,15,19–21,30–35].



value of the prenatal diagnosis of genital defects. A cohort study on a large number of fetuses is required and remains challenging.

The large variability of phenotype at birth makes such prenatal findings difficult to exploit in clinical practice and parental counselling. Despite useful studies that define the normal anatomy and growth of the fetal genitalia [14], assessing the severity of phenotype based solely on the genital tubercle's length can lead to erroneous gender assignment, especially when trying to distinguish a small penis from a large clitoris [15]. Additional information such as testicular descent in male fetuses or visualisation of the endometrium in female fetuses is not available until late in the pregnancy [22]. Even if some reports confirm a high accuracy [23], defining precisely the type of genital malformation in the fetus remains challenging. Data on the accuracy and reliability of prenatal diagnosis are sparsely reported. Cheikhelard et al. [8], based on 43 pregnancies, concluded better reliability with postnatal findings in male fetuses than in female ones. But anterior hypospadias were excluded from the study that included rather severe phenotypes. More recently, Gilboa et al. [19] reported that fetuses with hypospadias may be identified according to a shorter anogenital distance, but fetuses with severe growth retardation or associated malformations were also excluded. To our knowledge, no previous report has focused on the whole range of phenotypes to elucidate predictive factors for the severity of the genital phenotype at birth. In a context of an increased prenatal detection of minor defects, such as anterior and glanular hypospadias, this point may be relevant for our future clinical practice.

In the present study, we found that an early diagnosis around the 24th week of gestation, association with IUGR and a curvature of the penis were more frequently associated with a severe phenotype at birth, i.e., posterior or mid-penile hypospadias, micropenis and epispadias. Conversely, mild defects, such as anterior hypospadias, were rather diagnosed later during pregnancy in a normal growth fetus and a straight genital tubercle. The rationale for the association of these last two factors is in agreement with previous knowledge on hypospadias. Connections between hypospadias and IUGR have been extensively reported [24]. IUGR is more frequent in hypospadiac boys than in controls [25]. Children with more severe IUGR are those with more severe hypospadias [25]. IUGR could be the consequence of placental insufficiency. Placental infarcts, small placental weight and small birth weight are indeed more frequent in male fetuses with a genital defect [26,27]. All of this strengthens our finding that IUGR should be taken in account in a prenatal diagnosis of a genital defect. In addition, a significant curvature of the penis has been reported to be more frequent and more severe in posterior hypospadias [28]. This US finding recapitulates the growth defect of the ventral face of the penis and was more reliable in our experience than the length of the genital tubercle itself (data not shown, very low reproducibility). Overall, these risk factors may be of clinical interest to provide a more accurate counselling to parents, to focus on pregnancies that justify prenatal genetic testing, and to screen out the most severe DSD that justify delivery near a multidisciplinary DSD team.

Another point of interest of the present work is the high frequency of associated malformations and syndromes. In this respect, prenatal diagnosis is rather opposed to the postnatal diagnosis of genital defects. The vast majority of hypospadias, micropenis and other DSDs that are discovered at birth are isolated and remain unexplained. In these patients, no particular screening of associated malformations is recommended except the usual hormonal and genetic evaluations related to severe phenotype with uncertain sex. On the contrary to this postnatal vision, we found an additional congenital abnormality in almost a quarter of boys with a prenatally detected genital defect. Genetic defects are also more frequently identified in these fetuses than in a general cohort of hypospadiac boys after birth [29]. The rate of associated abnormalities and genetic defects encourages caution and a complete and systematic US screening in a tertiary prenatal centre.

Some limits of the present series should be acknowledged. Due to its retrospective methodology, use of a standardised description of the external genitalia with well-defined images and methods for measurement of the genital tubercle are not used. That would avoid any subjectivity in the prenatal picture, e.g., 'micropenis' or 'clitoromegaly', with a more

neutral vocabulary as used after birth. The present series also focuses on the performance of prenatal imaging and does not propose a precise protocol of hormonal and genetic evaluation before birth. Last, the present study was not designed to assess the sensitivity and specificity of prenatal US screening. This work should thus be considered as a basis for a prospective study on a large cohort of pregnant women.

## Conclusion

Prenatal imaging of genital defects leads to a wide range of phenotypes at birth. Its PPV is high and extra-urinary malformations are frequent. Early diagnosis during the second trimester, associated IUGR, and curvature of the genital tubercle should raise suspicion of a severe phenotype, and may justify delivery in a medical facility with a multidisciplinary DSD team. Prospective studies are needed to confirm the value of these prognostic factors and to determine the sensitivity and specificity of this prenatal screening.

## Conflicts of Interest

None declared.

## References

- Nordkap L, Joensen UN, Blomberg Jensen M, Jorgensen N. Regional differences and temporal trends in male reproductive health disorders: semen quality may be a sensitive marker of environmental exposures. *Mol Cell Endocrinol* 2012; 355: 221–30
- Geller F, Feenstra B, Carstensen L et al. Genome-wide association analyses identify variants in developmental genes associated with hypospadias. *Nat Genet* 2014; 46: 957–63
- Rey RA, Codner E, Iniguez G et al. Low risk of impaired testicular Sertoli and Leydig cell functions in boys with isolated hypospadias. *J Clin Endocrinol Metab* 2005; 90: 6035–40
- Gaspari L, Paris F, Jandel C et al. Prenatal environmental risk factors for genital malformations in a population of 1442 French male newborns: a nested case-control study. *Hum Reprod* 2011; 26: 3155–62
- Kalfa N, Paris F, Philibert P et al. Is hypospadias associated with prenatal exposure to endocrine disruptors? A French collaborative controlled study of a cohort of 300 consecutive children without genetic defect. *Eur Urol* 2015; 68: 1023–30
- Hughes IA, Houk C, Ahmed SF, Lee PA, Lawson Wilkins Pediatric Endocrine Society/European Society for Paediatric Endocrinology Consensus Group. Consensus statement on management of intersex disorders. *Arch Dis Child* 2006; 91: 554–63
- Karim JN, Roberts NW, Salomon LJ, Papageorgiou AT. Systematic review of first-trimester ultrasound screening for detection of fetal structural anomalies and factors that affect screening performance. *Ultrasound Obstet Gynecol* 2017; 50: 429–41
- Cheikhelard A, Luton D, Philippe-Chomette P et al. How accurate is the prenatal diagnosis of abnormal genitalia? *J Urol* 2000; 164: 984–7
- Chitayat D, Glanc P. Diagnostic approach in prenatally detected genital abnormalities. *Ultrasound Obstet Gynecol* 2010; 35: 637–46
- Epelboym Y, Estrada C, Estroff J. Ultrasound diagnosis of fetal hypospadias: accuracy and outcomes. *J Pediatr Urol* 2017; 13: e1–4
- Pajkrt E, Petersen OB, Chitty LS. Fetal genital anomalies: an aid to diagnosis. *Prenat Diagn* 2008; 28: 389–98
- Pinhas-Hamiel O, Zalel Y, Smith E et al. Prenatal diagnosis of sex differentiation disorders: the role of fetal ultrasound. *J Clin Endocrinol Metab* 2002; 87: 4547–53
- Rosoklija I, D'Oro A, Chen D, Finlayson C, Johnson EK. Clinician Communication at Initial DSD Diagnosis: parental Perspectives. Montreal, QC: Pediatric Urology Fall Congress, 2017.
- Perlitz Y, Keselman L, Haddad S, Mukary M, Izhaki I, Ben-Ami M. Prenatal sonographic evaluation of the penile length. *Prenat Diagn* 2011; 31: 1283–5
- Smith DP, Felker RE, Noe HN, Emerson DS, Mercer B. Prenatal diagnosis of genital anomalies. *Urology* 1996; 47: 114–7
- Kearin M, Pollard K, Garbett I. Accuracy of sonographic fetal gender determination: predictions made by sonographers during routine obstetric ultrasound scans. *Australas J Ultrasound Med* 2014; 17: 125–30
- Colmant C, Morin-Surroca M, Fuchs F, Fernandez H, Senat MV. Non-invasive prenatal testing for fetal sex determination: is ultrasound still relevant? *Eur J Obstet Gynecol Reprod Biol* 2013; 171: 197–204
- Elejalde BR, de Elejalde MM, Heitman T. Visualization of the fetal genitalia by ultrasonography: a review of the literature and analysis of its accuracy and ethical implications. *J Ultrasound Med* 1985; 4: 633–9
- Gilboa Y, Perlman S, Kivilevitch Z, Messing B, Achiron R. Prenatal anogenital distance is shorter in fetuses with hypospadias. *J Ultrasound Med* 2017; 36: 175–82
- Sides D, Goldstein RB, Baskin L, Kleiner BC. Prenatal diagnosis of hypospadias. *J Ultrasound Med* 1996; 15: 741–6
- Timor-Tritsch IE, Shapiro E, Patrick SL, Monteagudo A. Prenatal sonographic diagnosis of a buried penis. *J Ultrasound Med* 2009; 28: 1389–92
- Glanc P, Umraniar S, Koff D, Tomlinson G, Chitayat D. Fetal sex assignment by sonographic evaluation of the pelvic organs in the second and third trimesters of pregnancy. *J Ultrasound Med* 2007; 26:563–9.
- Chitty LS, Chatelain P, Wolfenbittel KP, Aigrain Y. Prenatal management of disorders of sex development. *J Pediatr Urol* 2012; 8: 576–84
- Boisen KA, Chellakooty M, Schmidt IM et al. Hypospadias in a cohort of 1072 Danish newborn boys: prevalence and relationship to placental weight, anthropometrical measurements at birth, and reproductive hormone levels at three months of age. *J Clin Endocrinol Metab* 2005; 90: 4041–6
- Yinon Y, Kingdom JC, Proctor LK et al. Hypospadias in males with intrauterine growth restriction due to placental insufficiency: the placental role in the embryogenesis of male external genitalia. *Am J Med Genet A* 2010; 152A: 75–83
- Stoll C, Alembik Y, Roth MP, Dott B. Genetic and environmental factors in hypospadias. *J Med Genet* 1990; 27: 559–63
- Ghirri P, Scaramuzzo RT, Bertelloni S et al. Prevalence of hypospadias in Italy according to severity, gestational age and birthweight: an epidemiological study. *Ital J Pediatr* 2009; 35: 18
- Snodgrass W, Bush N. Staged tubularized autograft repair for primary proximal hypospadias with 30-degree or greater ventral curvature. *J Urol* 2017; 198: 680–6
- Kalfa N, Philibert P, Werner R et al. Minor hypospadias: the “tip of the iceberg” of the partial androgen insensitivity syndrome. *PLoS One* 2013; 8: e61824
- Benacerraf BR, Saltzman DH, Mandell J. Sonographic diagnosis of abnormal fetal genitalia. *J Ultrasound Med* 1989; 8: 613–7
- Cooper C, Mahony BS, Bowie JD, Pope II. Prenatal ultrasound diagnosis of ambiguous genitalia. *J Ultrasound Med* 1985; 4: 433–6
- Devesa R, Munoz A, Torrents M, Comas C, Carrera JM. Prenatal diagnosis of isolated hypospadias. *Prenat Diagn* 1998; 18: 779–88
- Ginsberg NA, Cadkin A, Strom C, Bauer-Marsh E, Verlinsky Y. Prenatal diagnosis of 46, XX male fetuses. *Am J Obstet Gynecol* 1999; 180: 1006–7

- 34 Mandell J, Bromley B, Peters CA, Benacerraf BR. Prenatal sonographic detection of genital malformations. *J Urol* 1995; 153: 1994–6
- 35 Smulian JC, Scorza WE, Guzman ER, Ranzini AC, Vintzileos AM. Prenatal sonographic diagnosis of mid shaft hypospadias. *Prenat Diagn* 1996; 16: 276–80

**Correspondence:** Nicolas Kalfa, Service de Chirurgie Viscérale et Urologique Pédiatrique, Hôpital Lapeyronie – CHU

Montpellier, 371 avenue du Doyen Gaston Giraud, 34295 Montpellier Cedex 5, France

**e-mail:** nicolaskalfa@gmail.com

**Abbreviations:** AR, androgen receptor; DSD, disorders/differences of sex development; IUGR, intra-uterine growth restriction; PPV, positive predictive value; US, ultrasonography/ultrasound.