



HAL
open science

A virtual liver biopsy based on mixed MRI radiomics and biological data: a proof of concept

Benjamin Leporq, Sophie Gaillard, Liadeh Cuminal, Valerie Hervieu, Olivier Guillaud, Jérôme Dumortier, Pierre-Jean Valette, Olivier Beuf

► **To cite this version:**

Benjamin Leporq, Sophie Gaillard, Liadeh Cuminal, Valerie Hervieu, Olivier Guillaud, et al.. A virtual liver biopsy based on mixed MRI radiomics and biological data: a proof of concept. 27th Annual meeting of the ISMRM, May 2019, Montréal, Canada. hal-02266794

HAL Id: hal-02266794

<https://hal.science/hal-02266794>

Submitted on 16 Aug 2019

HAL is a multi-disciplinary open access archive for the deposit and dissemination of scientific research documents, whether they are published or not. The documents may come from teaching and research institutions in France or abroad, or from public or private research centers.

L'archive ouverte pluridisciplinaire **HAL**, est destinée au dépôt et à la diffusion de documents scientifiques de niveau recherche, publiés ou non, émanant des établissements d'enseignement et de recherche français ou étrangers, des laboratoires publics ou privés.

A virtual liver biopsy based on mixed MRI radiomics and biological data: a proof of concept

Benjamin Leporq¹, Sophie Gaillard¹, Liadeh Cuminal², Valerie Hervieu³, Olivier Guillaud⁴, Jerome Dumortier⁴, Pierre-Jean Valette⁵, and Olivier Beuf¹

¹CREATIS CNRS UMR 5220; Inserm U1206; INSA-Lyon; UCBL Lyon 1, Université de Lyon, Villeurbanne, France, ²Department of Radiology, CHU Edouard Herriot, Lyon, France, ³Department of Pathology, CHU Edouard Herriot, Lyon, France, ⁴Department of Hepato-Gastro-Enterology, CHU Edouard Herriot, Lyon, France, ⁵Department of Radiology, CHU Lyon Sud, Lyon, France

Synopsis

Whereas NASH is associated with poor long-term outcome, widespread screening is not currently feasible given that a definitive diagnosis of NASH can only be made through liver biopsy. In this study, a virtual liver biopsy was developed with machine learning from mixed multiparametric MRI radiomics and biological data.

Introduction

In the past decade, an epidemic increase in non-alcoholic fatty liver disease (NAFLD) prevalence has been observed in Western countries and NAFLD is among the most common causes of chronic liver disease with a prevalence ranging between 17 and 46% (1). NAFLD include simple steatosis and nonalcoholic steato-hepatitis (NASH). Whereas simple steatosis has good prognosis, NASH is associated with poor long-term outcome (2) and is characterized by steatosis, hepatocyte ballooning, inflammation, with or without fibrosis at histology. About 20% of NASH patients develop cirrhosis or hepatocellular carcinoma, so that NASH has become the fastest growing cause of liver-related morbidity/mortality worldwide (3). Widespread screening is not currently feasible given that a definitive diagnosis of NASH can only be made through identification of the characteristic histopathologic pattern on liver biopsy (4). Therefore, there is a pressing unmet medical need for reliable and accurate non-invasive tools to evaluate liver steatosis, fibrosis and inflammation simultaneously. The aim of this study was to develop a virtual liver biopsy based on multiparametric MRI (mpMRI) radiomics and biological data.

Methods

70 patients with chronic liver diseases, histology (ISHAK classification), blood serum markers and 3.0T mpMRI data available were retrospectively enrolled from the HEPATOMAP database. Gd-BOPTA-enhanced (t = 20 min) fat-suppressed T1w images were used as a radiomic fingerprint. PDFF-map was computed from chemical-shift-encoded acquisition according to (5). ASAT, ALAT and Gamma GT-values were recorded. From BOPTA-enhanced radiomic fingerprint, the liver were manually segmented to extract the radiome including 87 features describing shape, size, distribution and texture in images and frequency domain (Fig.1). Overall, 91 features were integrated. The learning base dimension was reduced using a backward selection by thresholding on t-test p-value (t < 0.05). Two models were established to predict advanced fibrosis (F > 2, n = 35) and inflammation (A > 1, n = 46). To predict inflammation, a k-nearest neighbor algorithm with a cosine node function and 10 neighbors was used as a classifier. To predict fibrosis, a support vector machine with a linear kernel was used as a classifier. Steatosis grades were predicted without classifier and directly from the mean PDFF-value. Internal validation was performed with a holdout cross-validation method (75% of data used for training and 25% for test).

Results

Diagnosis performances to predict steatosis grades, advanced fibrosis and inflammation are summarized in Fig.2.

Discussion

This work shows the feasibility to predict key liver histological characteristics (steatosis, fibrosis and inflammation) with mixed radiomics and biological data in patients with chronic liver diseases. Limitations of the study are the absence of external validation and the heterogeneity of etiologies in the database. Shared multicenter data are mandatory to extend this proof of concept to NASH only, to perform a thinner classification, and to obtain an external validation.

Acknowledgements

This work was performed within the framework of LABEX PRIMES (ANR-11-LABX-0063), program "Investissements d'Avenir" (ANR-11-IDEX-0007).

References

(1) Chalasani N et al. Hepatology 2012; 55(6):2005-2023. (2) Angulo P et al. Gastroenterology 2015; 149(2):389-397. (3) Satapathy SK et al. Semin Liver Dis 2015; 35(3):221-235 (4) Chalasani N et al. Hepatology. 2018; 67:328–357 (5) Leporq B et al. Eur Radiol 2013; 23(8):2175-2186

Figures

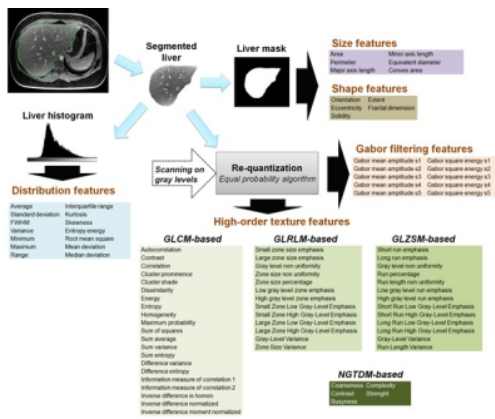


Fig.1: Radiome extraction pipeline. Size and shape features were extracted from the binary mask. Intensity distribution features were extracted from the histogram built with 256 bins. Images gray levels were discretized in a smaller number of gray levels with an equal probability algorithm. Images were discretized in 8, 16, 24, 32, 40, 48 and 64 gray levels. For each discretization level, four matrixes were built: GLCM (Gray-level co-occurrence), GLRLM (Gray-level run length), GLSZM (Gray-level size zone) and NGTDM (Neighborhood gray tone difference) from which characteristics were extracted, then averaged. Frequency domain-based texture features were extracted using a Gabor filtering.

	STEATOSIS		FIBROSIS	INFLAMMATION
	<i>S</i> > 0 grade	<i>S</i> > 2-3 grades	<i>F</i> > 2 grade	<i>A</i> > 1 grade
AUROC	0.98	0.96	0.98	0.91
Sensitivity	97.1 (91.4 – 103)	95.0 (85.5 – 105)	85.7 (59.8 – 111)	100 (100 – 100)
Specificity	93.8 (85.4 – 102)	93.5 (86.3 – 100)	100 (100 – 100)	80.0 (54.9 – 105)
PPV (%)	94.3 (86.6 – 102)	86.4 (72.0 – 101)	100 (100 – 100)	90.0 (71.4 – 108)
NPV (%)	96.7 (90.5 – 103)	97.8 (93.3 – 102)	87.5 (64.6 – 110)	100 (100 – 100)
Accuracy	95.5 (90.4 – 100)	93.9 (88.2 – 99.7)	92.9 (79.3 – 106)	92.9 (79.3 – 106)

Fig.2: Diagnosis performances to predict key liver histological characteristics (PPV and NPV are the negative predictive value and the positive predictive value respectively)