



HAL
open science

In search of consensus: Terminology for enthesal changes (EC)

Sébastien Villotte, Sandra Assis, Francisca Alves Cardoso, Charlotte Yvette Henderson, Valentina Mariotti, Marco Milella, Doris Pany-Kucera, Nivien Speith, Cynthia Wilczak, Robert Jurmain

► To cite this version:

Sébastien Villotte, Sandra Assis, Francisca Alves Cardoso, Charlotte Yvette Henderson, Valentina Mariotti, et al.. In search of consensus: Terminology for enthesal changes (EC). *International Journal of Paleopathology*, 2016, 13, pp.49-55. 10.1016/j.ijpp.2016.01.003 . hal-02266502

HAL Id: hal-02266502

<https://hal.science/hal-02266502v1>

Submitted on 19 Feb 2021

HAL is a multi-disciplinary open access archive for the deposit and dissemination of scientific research documents, whether they are published or not. The documents may come from teaching and research institutions in France or abroad, or from public or private research centers.

L'archive ouverte pluridisciplinaire **HAL**, est destinée au dépôt et à la diffusion de documents scientifiques de niveau recherche, publiés ou non, émanant des établissements d'enseignement et de recherche français ou étrangers, des laboratoires publics ou privés.

TECHNICAL NOTE

1
2
3
4
5
6
7
8
9
10
11
12
13
14
15
16
17
18
19
20
21
22
23
24
25
26
27
28
29
30
31
32
33
34
35
36
37
38
39
40
41
42
43
44
45
46
47
48
49
50
51
52
53
54
55
56
57
58
59
60
61
62
63
64
65

Title: In Search of Consensus: Terminology for Enthesal Changes (EC)

Short title: Terminology for EC

Authors and Affiliations:

Sébastien Villotte

Anthropologie des Populations Passées et Présentes, UMR 5199 PACEA, Bâtiment B8, Allée Geoffroy Saint Hilaire, Université de Bordeaux, CS, 50023, Pessac Cedex, France 33615
s.villotte@pacea.u-bordeaux1.fr

Sandra Assis

CIAS – Research Centre for Anthropology and Health, Department of Life Sciences, University of Coimbra, Portugal.
sandraassis78@gmail.com

Francisca Alves Cardoso

NOVA CRIA – Centre for Research in Anthropology, Faculty of Social Sciences and Humanities, Universidade NOVA de Lisboa, Portugal.
francicard@fesh.unl.pt

Charlotte Yvette Henderson

CIAS – Research Centre for Anthropology and Health, Department of Life Sciences, University of Coimbra, Portugal.
c.y.henderson@uc.pt

Valentina Mariotti

1-Laboratorio di Bioarcheologia ed Osteologia Forense - Antropologia – Dipartimento di Scienze Biologiche, Geologiche e Ambientali - Alma Mater Studiorum Università di Bologna, Via Selmi 3, 40126 Bologna.
2- ADÉS, UMR 7268 CNRS/Aix-Marseille Université/EFS, Aix-Marseille Université, CS80011, Bd Pierre Dramard, 13344 Marseille Cedex 15 (France).
valentina.mariotti@unibo.it

Marco Milella

Anthropological Institute & Museum, University of Zurich, Winterthurerstrasse 190, 8057 Zurich, Switzerland.
marco.milella@aim.uzh.ch

Doris Pany-Kucera

Natural History Museum Vienna, Department of Anthropology/Institute for Oriental and European Archaeology, Austrian Academy of Sciences, Vienna, Austria

dpany@nhm-wien.ac.at

Nivien Speith

Department of Archaeology, Anthropology and Forensic Science, Bournemouth University, Talbot Campus,
Fern Barrow, Poole BH12 5BB, UK

nspeith@bournemouth.ac.uk

Cynthia A Wilczak

Department of Anthropology, San Francisco State University, San Francisco, CA USA

cwilczak@sfsu.edu

Robert Jurmain

Department of Anthropology, San Jose State University, San Jose, CA USA

robert.jurmain@sjsu.edu

Corresponding author:

Sébastien Villotte,

Anthropologie des Populations Passées et Présentes, UMR 5199 PACEA, Bâtiment B8, Allée Geoffroy Saint
Hilaire, Université de Bordeaux, CS, 50023, Pessac Cedex, France 33615

Abstract

This article presents a consensus terminology for enthesal changes that was developed in English by an international team of scholars and then translated into French, Italian, Portuguese, Spanish and German. Use of a standard, neutral terminology to describe enthesal morphology will reduce misunderstandings between researchers, improve the reliability of comparisons between studies, and eliminate unwarranted etiological assumptions inherent in some of the descriptive terms presently used in the literature.

Keywords: Enthesis; terminology; Fibrocartilaginous enthesis; spondyloarthropathies; diffuse idiopathic skeletal hyperostosis (DISH)

Abbreviations:

Enthesal change: EC

Fibrocartilaginous enthesis: FCE

1. Introduction

“Musculoskeletal stress markers”, renamed “enthesal changes” (ECs) by Jurmain and Villotte (2010), have been widely studied in past populations as indicators of activity and social divisions of labor (e.g. Dutour, 1986; Hawkey and Merbs, 1995; Robb, 1998; Villotte et al., 2010a; Havelková et al., 2011, 2013; Lieverse et al., 2013;

1 Villotte and Knüsel, 2014). However, the problem of oversimplified etiological interpretations that primarily
2 equated EC with increased muscle use became widely apparent at a workshop held in 2009 in Coimbra, Portugal
3 (Santos et al., 2011). Discussions at this meeting led to the establishment of three working groups aimed at
4 standardizing key EC research aspects, namely terminology, recording methodology, and the understanding of
5 definitions of occupation. The three working groups met again in Coimbra at a new workshop in 2013.
6

7
8 This technical note focuses on the results from the terminology working group (SV, RJ). A survey of researchers
9 taken prior to the 2013 workshop clearly showed the need for standardized descriptions of ECs. Only one third
10 of respondents described the EC in Figure 1c using the same term (Table 1), and a similar lack of consensus was
11 found for other types of ECs. During the 2013 workshop, the terminology working group compiled an initial list
12 of neutral terms and descriptions of the most common EC types. The terms proposed by this group have been
13 discussed with the members of the other working groups (SA, FAC, CYH, VM, MM, DPK, NS, CAW), and a
14 consensus was finally reached. The terminology proposed here includes neutral (i.e. without inherent etiological
15 concepts), descriptive terms with figures (Fig. 1 and 2, see also Table 2 for other illustrations of the EC defined
16 here in previous publications by the authors), which researchers can use to describe ECs arising from any
17 etiology, including those associated with pathological conditions, e.g. the seronegative spondyloarthropathies or
18 diffuse idiopathic skeletal hyperostosis. It should be noted that similar changes can occur at other anatomical
19 locations (e.g. synovial joints), but this is outside the scope of this paper. The proposed terminology (Fig. 3),
20 alongside its translation into five major European languages (Table 2), should reduce communication barriers as
21 well as lead to improved data sharing amongst researchers if widely adopted.
22
23
24
25
26
27
28
29
30

31 **TABLE 1**

32 33 34 **2. Proposed terminology**

35
36
37
38 Two groups of entheses can be distinguished according to the tissue type present at the skeletal attachment site
39 (Benjamin et al., 1986, 2002; Cooper and Misol, 1970; see Villotte et al., 2010b for a list of the main post-cranial
40 fibrous and fibrocartilaginous entheses). A normal fibrocartilaginous enthesis (FCE) is smooth, well
41 circumscribed and devoid of vascular foramina (Benjamin et al., 2002; Henderson, 2009; Henderson et al., 2015;
42 Villotte, 2006, 2009; Villotte et al., 2010b); thus any alteration from this definition is considered an EC. For
43 fibrous entheses, for which there is no clear definition of a “normal” aspect, we consider a theoretical smooth
44 cortical surface as a base line (Henderson, 2009; Villotte, 2006, 2009). In the following text “fibrous entheses”
45 refers only to fibrous tendon attachment sites, and not to sites where fleshy muscle fibers attach to the
46 periosteum (e.g. the origin of tibialis anterior muscle).
47
48
49
50
51

52 We distinguished three main categories of EC: mineralized tissue formation, surface discontinuity, and complete
53 loss of original morphology with subcategories where appropriate (Fig. 3). Note that the definition of EC does
54 not include architectural variation (e.g. a more or less developed deltoid tuberosity, or “waving” of the surface
55 itself).
56
57
58

59 **2.1. Mineralized tissue formation**

60
61
62
63
64
65

1 The morphological change exceeds the level of the original surface, from roughness of the surface to a clear
2 structure of any size or shape.
3

4 2.1.1. Diffuse and non-protruding formation

5 Not clearly distinct from the surface of the enthesis. Two morphological subtypes are identified according to the
6 enthesis type.
7

8 2.1.1.1 Grained surface

9
10 A textural change of a diffuse granular nature (similar to fine grained sandpaper, Henderson et al., 2015) at FCEs
11 (Fig. 1a). The surface does not look as smooth as it is in unaltered FCEs, and it can feel roughened to the touch.
12 Based on a picture of a histological section of such a change (Fig. 6-11 and 6-63 in Schultz, 2003), this granular
13 texture is likely to be related to the mineralization of the uncalcified fibrocartilage.¹ This type of change is
14 mainly seen at the ischial and radial tuberosities.
15
16
17
18
19
20

21 2.1.1.2 Diffuse cortical irregularity

22 The area is rough to the touch due to diffuse tissue formation (Fig. 1b). The surface looks well remodeled (i.e.
23 likely to be long standing). This is an extremely common feature at fibrous entheses and may be related to the
24 direct attachment of tendon fibers to bone (Villotte and Knüsel 2013). It is also seen at the margin (Zone 1 in
25 Henderson et al. 2013, see also Villotte, 2006) of FCEs, a region with little fibrocartilage.
26
27
28
29

30 2.1.2 Isolated protrusion

31 Identified as a clearly distinct protrusion from the surface of the enthesis.
32
33

34 2.1.2.1 Enthesophyte

35
36 A clear bony projection (Fig. 1c) mostly seen at the margin of FCEs. The height of the projection can be easily
37 measured, tends to be greater in length than in width, and tapers towards the end. In histological studies, these
38 spurs have been found to contain (and be surrounded by) calcified fibrocartilage from the original entheses
39 (Abreu, et al.2003; Moriggl et al.2001; Rufai et al. 1995). Enthesophytes form through endochondral ossification
40 in the Achilles tendon and subscapular ligament (Moriggl et al. 2001; Rufai et al. 1995), but they form through
41 intramembranous and chondroidal ossification in the plantar fascia (Kumai and Benjamin 2002).
42
43
44
45
46

47 2.1.2.2 Raised margin

48 A raised rim at the margin of a FCEs (Fig. 1d) that is not as developed as an enthesophyte (i.e. it is difficult to
49 measure the height of the bony projection).
50
51
52

53 2.1.2.3 Longitudinal protrusion

54
55
56 1 Or, as stated by Schultz (2003), related to the ossification of the tendon. However, this second
57 hypothesis seems less likely. In the caption of the figure 6.63, Schultz (2003) stated that the two layers of
58 calcified tissue (green structures) correspond to mineralized tendon and that the process occurred in two
59 waves. Actually, it seems to correspond to the layers of uncalcified and calcified fibrocartilage separated by
60 the tidemark (see Benjamin et al., 2002), the first layer being mineralized in that pathological case.
61
62
63
64
65

1 A longitudinal bony protrusion at a fibrous enthesis normally affects nearly the entire length of the enthesis (Fig.
2 1e), either continuously or discontinuously. The protrusion is clearly distinct from the surrounding cortical
3 surface, but it is not as developed and distinctive as an enthesophyte (i.e. it is difficult to measure the height of
4 the bony projection). It can occur in conjunction with a smooth or a coarse surface.
5
6

7 2.1.2.4 Shapeless protrusion

8 A relatively flat or mound-like protruding mineralized tissue formation (Fig. 1f). It is highly variable in size,
9 affecting a very limited part of the enthesis (a small raised area, i.e. nodule) to the entire attachment site. It
10 occurs at both fibrocartilaginous (typically the central portion) and fibrous entheses.
11
12
13

14 **FIGURE 1**

15 16 17 18 2.2 Surface discontinuity

19 Depressions and other mineralized tissue loss of the surface (Rothschild, 2013). In fibrous entheses, cortical
20 surface discontinuity can also involve the trabecular bone. In FCEs, the discontinuity involves the calcified
21 cartilage and the subchondral bone (i.e. the subchondral bone plate and the trabecular bone). Possible origins
22 include a resorptive process, a resorptive and hypertrophic process, hypervascularisation or avulsions (e.g.
23 Flemming et al., 2003; Miller et al., 2004; Milz et al., 2004).
24
25
26
27

28 2.2.1 Porosity

29 Pores are macroscopically observable small rounded openings in the surface².
30
31
32

33 2.2.1.1 Fine porosity

34 Very small pinholes with a diameter of less than 1 mm, usually occurring in a cluster (Henderson et al. 2015).
35 The opening is too small to see the subsurface morphology. These occur at both fibrocartilaginous and fibrous
36 entheses (Fig. 2a).
37
38
39

40 2.2.1.2 Macro porosity

41 Pores \geq 1mm in diameter (Henderson et al. 2015), which occur singularly or in small clusters at
42 fibrocartilaginous or fibrous entheses (Fig. 2b). The subsurface morphology is variable and, depending on the
43 size of the opening, can sometimes be seen. When the subsurface morphology has the appearance of a channel,
44 the pore is very likely a vascular foramen (often seen during skeletal development in FCEs). A macro pore can
45 also be the entrance to a cavitation (see 2.2.3).
46
47
48
49
50

51 2.2.2 Cortical defect

52
53
54
55
56 ² We avoided the term "pitting", very often used as a descriptive term in paleopathology, but usually not
57 defined (e.g. Ortner, 2003; Roger and Waldron, 2015). However, it should be noted that our definition of
58 "porosity" is similar to the definition of "pitting" given by Waldron (2008:27) in the context of changes
59 taking place in articulating bones: "pitting on the joint surface manifested as a series of holes on the joint
60 surface, some of which may communicate with sub-chondral cysts."
61
62
63
64
65

1 Focal bone loss, usually longitudinal in shape, often remodeled, and of variable depth (Fig. 2c). The floor of the
2 depression often exhibits numerous pores. Cortical defects are mostly seen at the metaphyseal region of long
3 bones, especially on the humerus at the insertions of the *MM. pectoralis major* and *teres major*, and at the
4 attachment of the costoclavicular ligament on the clavicle. Possible origins include an avulsion, or an erosion
5 from the periosteal or endosteal surface (Villotte, 2008). In immature skeletons, cortical defects at metaphyseal
6 attachment sites are likely related to the unbalanced activity of osteoclasts and osteoblasts when the attachments
7 of tendons and ligaments migrate as long bones grow in length (Villotte and Knüsel 2013).
8
9

10 11 2.2.3. Erosive lesion

12 Destruction of the mineralized cartilage and subchondral bone (Henderson et al. 2015). The erosive lesion is
13 generally greater in width than depth. Its edges are often irregular and can be minimally or significantly
14 remodeled. The floor of the depression exhibits exposed trabeculae or numerous pores (Fig. 2d). The
15 morphology is very similar to erosions at synovial joints (see Rogers and Waldron, 1995:12). It can be observed
16 at virtually all the appendicular FCEs.
17
18
19
20
21

22 2.2.4 Cavitation

23 Spherical subchondral lacuna with an opening at the surface that is smaller than the diameter of the cavitation
24 and a clear floor that is not a channel (Henderson et al. 2015) (Fig. 2e). Usually cavitations have remodeled
25 trabecular bone walls. They may correspond to the cysts described in the biomedical literature (Milz et al., 2004;
26 Fritz et al., 2007). Cavitations are only seen at FCEs, especially at the proximal humerus.
27
28
29
30

31 2.2.5. Furrowed surface (fibrous entheses)

32 This feature seems to occur only at fibrous entheses in immature skeletons. The cortical surface is covered by
33 very thin, straight furrows of variable length (usually no more than a 2-3 millimeters) that are generally oriented
34 along the long axis of the attachment (Fig. 2f). The appearance of numerous areas of bone resorption
35 interspersed with hypertrophic bone formation suggests the furrows are related to the active process of bone
36 growth (Villotte and Knüsel, 2013).
37
38
39
40
41

42 2.3. Complete loss of original morphology

43 Associated with bone formation, and / or erosion, and porosity (Fig. 2g). Loss of morphology is most often seen
44 at the greater tuberosity of the humerus.
45
46
47
48
49

50 **FIGURE 2**

51 **FIGURE 3**

52 **TABLE 2**

53 54 55 56 57 58 59 **3. Conclusion**

60
61
62
63
64
65

1 The evaluation of “ECs” in bioarchaeological research became a common practice 30 years ago. As more
2 researchers evaluated these morphological changes it became clear that both the common name for them and the
3 varied descriptive terminology lacked scientific rigor and consistency (Jurmain and Villotte, 2010), and our goal
4 here is to propose an initial attempt towards greater standardization. In so doing, we hope to encourage further
5 discussion and a more focused intellectual exchange among bioarcheologists and paleopathologists.
6
7
8
9

10 **Acknowledgements**

11
12 The authors would like to thank the Wenner-Gren Foundation (grant number Gr. CONF-632) for funding the
13 workshop entitled ‘EC and Reconstruction of Human Behavior: Towards Standardization’ hosted by CIAS
14 (Research Centre for Anthropology and Health, University of Coimbra, Portugal - UID/ANT/00283/2013) with
15 support from CRIA (Centro em Rede de Investigação em Antropologia, Universidade de Nova, Lisbon, Portugal
16 - UID/ANT/04038/2013). We also thank W. Reichmann, who took the pictures in Figures 1d and 2e together
17 with D. Pany-Kucera at the 18th Paleopathology Association meeting in Vienna, Austria, with the permission of
18 M. Teschler-Nicola. The copyright of those pictures is retained by the Natural History Museum Vienna, Austria.
19 Fig. 2a has been taken by V. Mariotti at the Dpt. BiGEA of the Alma Mater Studiorum, University of Bologna,
20 with permission of M. G. Belcastro. We are also grateful to the many colleagues who kindly participated in the
21 survey concerning the terms they use for enthesal changes. We would like to thank Maria Alejandra Acosta
22 (CEF-Centre for Functional Ecology and the Laboratory of Forensic Anthropology, University of Coimbra) for
23 translating the terminology into Spanish. Finally, we would like to thank the three anonymous reviewers for their
24 useful comments.
25
26
27
28

29 Authors C. Henderson and F. Alves Cardoso are funded by the Portuguese FCT – Fundação para a Ciência e a
30 Tecnologia bursary SFRH/BPD82559/2011 and Investigator Programme IF/00127/2014, respectively and
31 supported by the European Commission ESF and POPH.
32
33
34

35 **References**

- 36 Abreu, M.R., Chung, C.B., Mendes, L., Mohana-Borges, A., Trudell, D., Resnick, D., 2003. Plantar calcaneal
37 enthesophytes: new observations regarding sites of origin based on radiographic, MR imaging, anatomic and
38 palaeopathologic analysis. *Skeletal Radiol.* 32, 13-21.
39
40 Benjamin, M., Evans, E.J., Copp, L., 1986. The histology of tendon attachments to bone in man. *J. Anat.* 149,
41 89-100.
42
43 Benjamin, M., Kumai, T., Milz, S., Boszczyk, B.M., Boszczyk, A.A., Ralphs, J.R., 2002. The skeletal
44 attachment of tendons - tendon "entheses." *Comp. Biochem. Physiol. A Mol. Integr. Physiol.* 133, 931-945.
45
46 Cooper, R.R., Misol, S., 1970. Tendon and ligament insertion. A light and electron microscopic study. *J. Bone.*
47 *Joint. Surg. Am.* 52, 1-20.
48
49 Dutour, O., 1986. Enthesopathies (lesions of muscular insertions) as indicators of the activities of Neolithic
50 Saharan populations. *Am. J. Phys. Anthropol.* 71, 221-224.
51
52 Flemming, D.J., Murphey, M.D., Shekitka, K.M., Temple, H.T., Jelinek, J.J., Kransdorf, M.J., 2003. Osseous
53 involvement in calcific tendinitis: a retrospective review of 50 cases. *Am. J. Roentgenol.* 181, 965-972.
54
55 Fritz, L.B., Ouellette, H.A., O'Hanley, T.A., Kassarian, A., Palmer, W.E., 2007. Cystic changes at supraspinatus
56 and infraspinatus tendon insertion sites: association with age and rotator cuff disorders in 238 patients.
57 *Radiology* 244, 239-248.
58
59 Havelková, P., Villotte, S., Velemínský, P., Poláček, L., Dobisíková, M., 2011. Enthesopathies and activity
60 patterns in the Early Medieval Great Moravian population: Evidence of division of labour. *Int. J. Osteoarchaeol.*
61 21, 487-504.
62
63
64
65

- 1 Havelková, P., Hladík, M., Velemínský, P., 2013. Enthesal changes: do they reflect socioeconomic status in the
2 Early Medieval Central European population? (Mikulčice – Klášterfisko, Great Moravian Empire, 9th – 10th
3 century). *Int. J. Osteoarchaeol.* 23, 237-251.
- 4 Hawkey, D.E., Merbs, C.F., 1995. Activity-induced musculoskeletal stress markers (MSM) and subsistence
5 strategy changes among ancient Hudson Bay Eskimos. *Int. J. Osteoarchaeol.* 5, 324-338.
- 6 Henderson, C.Y., 2009. Musculo-skeletal stress markers in bioarchaeology: indicators of activity levels or
7 human variation? A re-analysis and interpretation. PhD thesis. Department of Archaeology, Durham University.
- 8 Henderson, C.Y., Mariotti, V., Pany-Kucera, D., Villotte, S., Wilczak, C., 2013. Recording specific enthesal
9 changes of fibrocartilaginous entheses: initial tests using the Coimbra Method. *Int. J. Osteoarchaeol.* 23, 152-162.
- 10 Henderson, C.Y., Mariotti, V., Pany-Kucera, D., Villotte, S., Wilczak, C., 2015. The new “Coimbra method”: a
11 biologically appropriate method for recording specific features of fibrocartilaginous enthesal changes. *Int. J.*
12 *Osteoarchaeol.* [early view] DOI: 10.1002/oa.2477
- 13
14 Jurmain, R., Villotte, S., 2010. Terminology. Enteses in medical literature and physical anthropology: a brief
15 review. Document published online in 4th February 2010 following the Workshop in Musculoskeletal Stress
16 Markers (MSM): limitations and achievements in the reconstruction of past activity patterns, University of
17 Coimbra, July 2-3, 2009. Coimbra, CIAS – Centro de Investigação em Antropologia e Saúde. Consulted in 27th
18 February 2015. Available from: http://www.uc.pt/en/cia/msm/MSM_terminology3.pdf.
- 19
20 Kumai, T., Benjamin, M., 2002. Heel spur formation and the subcalcaneal entheses of the plantar fascia. *J*
21 *Rheumatol.* 29, 1957-1964.
- 22
23 Lieverse, A.R., Bazaliiskii, V.I., Goriunova, O.I., Weber, A.W., 2013. Lower limb activity in the Cis-Baikal:
24 Entesal changes among middle Holocene Siberian foragers. *Am. J. Phys. Anthropol.* 150, 421-432.
- 25
26 Mariotti, V., Facchini, F., Belcastro, M.G., 2004. Entesopathies - Proposal of a standardized scoring method
27 and applications. *Coll. Antropol.* 28, 145-159.
- 28
29 Mariotti, V., Facchini, F., Belcastro, M.G., 2007. The Study of Enteses: Proposal of a Standardized Scoring
30 Method for Twenty-Three Enteses of the Postcranial Skeleton. *Coll. Antropol.* 31, 291-313.
- 31
32 Moriggl, B., Jax, P., Milz, S., Buttner, A., Benjamin, M., 2001. Fibrocartilage at the enteses of the
33 suprascapular (superior transverse scapular) ligament of man - a ligament spanning two regions of a single bone.
34 *J. Anat.* 199: 539-545
- 35
36 Miller, T.T., Adler, R.S., Friedman, L., 2004. Sonography of injury of the ulnar collateral ligament of the elbow-
37 initial experience. *Skeletal Radiol.* 33, 386-391.
- 38
39 Milz, S., Tischer, T., Buettner, A., Schieker, M., Maier, M., Redman, S., Emery, P., McGonagle, D., Benjamin,
40 M., 2004. Molecular composition and pathology of enteses on the medial and lateral epicondyles of the
41 humerus: a structural basis for epicondylitis. *Ann. Rheum. Dis.* 63, 1015-1021.
- 42
43 Ortner, D., 2003. Identification of Pathological conditions in human skeletal remains. Second Edition. Academic
44 Press, Amsterdam.
- 45
46 Robb, J.E., 1998. The interpretation of skeletal muscle sites: a statistical approach. *Int. J. Osteoarchaeol.* 8, 363-
47 377.
- 48
49 Rogers, J., Waldron, T., 1995. A field guide to joint disease in archaeology. John Wiley & Sons, Chichester.
- 50
51 Rothschild, B.M., 2013. Nondestructive, epi-illumination surface microscopic characterization of surface
52 discontinuity in bone: A new approach offers a descriptive vocabulary and new insights. *Anat. Rec.* 296, 580-
53 589.
- 54
55 Rufai, A., Ralphs, J.R., Benjamin, M., 1995. Structure and histopathology of the insertional region of the human
56 Achilles tendon. *J. Orthop. Res.* 13: 585-593
- 57
58 Santos, A.L., Alves Cardoso, F., Assis, S., Villotte, S., 2011. The Coimbra Workshop in Musculoskeletal Stress
59 Markers (MSM): an annotated review. *Antropologia Portuguesa* 28, 135-161.
- 60
61 Schultz, M., 2003. Light microscopic analysis in skeletal paleopathology, in: Ortner, D. (Ed.), Identification of
62 Pathological conditions in human skeletal remains. Second Edition. Academic Press, Amsterdam, pp. 73-108.
63
64
65

1 Villotte, S., 2006. Connaissances médicales actuelles, cotation des enthésopathies: nouvelle méthode. Bull. Mem.
2 Soc. Anthropol. Paris 18, 65-85.

3 Villotte, S., 2008. L'insertion humérale « en fosse » du muscle grand pectoral, in: Charlier, P. (Ed.), Ostéo-
4 archéologie et techniques médico-légales: tendances et perspectives. Pour un "Manuel pratique de
5 paléopathologie humaine". Editions De Boccard, Paris, pp. 391-392.

6 Villotte, S., 2009. Enthésopathies et activités des Hommes préhistoriques - Recherche méthodologique et
7 application aux fossiles européens du Paléolithique supérieur et du Mésolithique. Archaeopress, Oxford.

8 Villotte, S., Churchill, S.E., Dutour, O., Henry-Gambier, D., 2010a. Subsistence activities and the sexual
9 division of labor in the European Upper Paleolithic and Mesolithic: evidence from upper limb enthesopathies. J.
10 Hum. Evol. 59, 35-43.

11 Villotte, S., Castex, D., Couallier, V., Dutour, O., Knüsel C.J., Henry-Gambier, D., 2010b. Enthesopathies as
12 occupational stress markers: evidence from the upper limb. Am. J. Phys. Anthropol. 142, 224-234.

13 Villotte, S., Knüsel, C.J., 2013. Understanding enthesal changes: definition and life course changes. Int. J.
14 Osteoarchaeol. 23, 135-146.

15 Villotte, S., Knüsel, C.J., 2014. "I sing of arms and of a man...": medial epicondylitis and the sexual division of
16 labour in prehistoric Europe. J. Archaeol. Sci. 43, 168-174.

17 Waldron, T., 2008. Palaeopathology. Cambridge University Press, Cambridge.

21 22 Table list

23
24 Table 1. Results of a survey eliciting responses on the naming of EC, specifically what is defined in this paper as
25 an enthesophyte (Fig 1c white arrow).
26

27 Table 2. The proposed new terminology alongside translations into French, Italian, Portuguese, Spanish, and
28 German. References to other illustrations in publications by the authors of the EC defined here are also provided.
29
30

31 32 Figure list

33 Figure 1. Examples of enthesal changes (mineralized tissue formation) to illustrate the terminology. a)
34 grained surface. b) diffuse cortical irregularity. c) enthesophyte. d) raised margin. e) longitudinal protrusion. f)
35 shapeless protrusion. Scale: 2cm. Photo credits: Villotte, S. (a, c, e, f); Assis, S. (b); Reichmann, W. and Pany-
36 Kucera, D. (d).
37
38

39 Figure 2. Examples of enthesal changes (surface discontinuity, and complete loss of original morphology) to
40 illustrate the terminology. a) fine porosity. b) macro porosity. c) cortical defect. d) erosive lesion. e) cavitation. f)
41 furrowed surface. g) complete loss of original morphology. Scale: 2cm. Photo credits: Mariotti, V. (a); Villotte,
42 S. (b, c, f, g); Henderson, C. (d); Reichmann, W. and Pany-Kucera, D. (e).
43
44
45
46

47 Figure 3. Graphical summary of the proposed terminology. "Fibrous"; fibrous entheses, "FC"; fibrocartilaginous
48 entheses.
49
50
51
52
53
54
55
56
57
58
59
60
61
62
63
64
65

Figure 1
[Click here to download high resolution image](#)

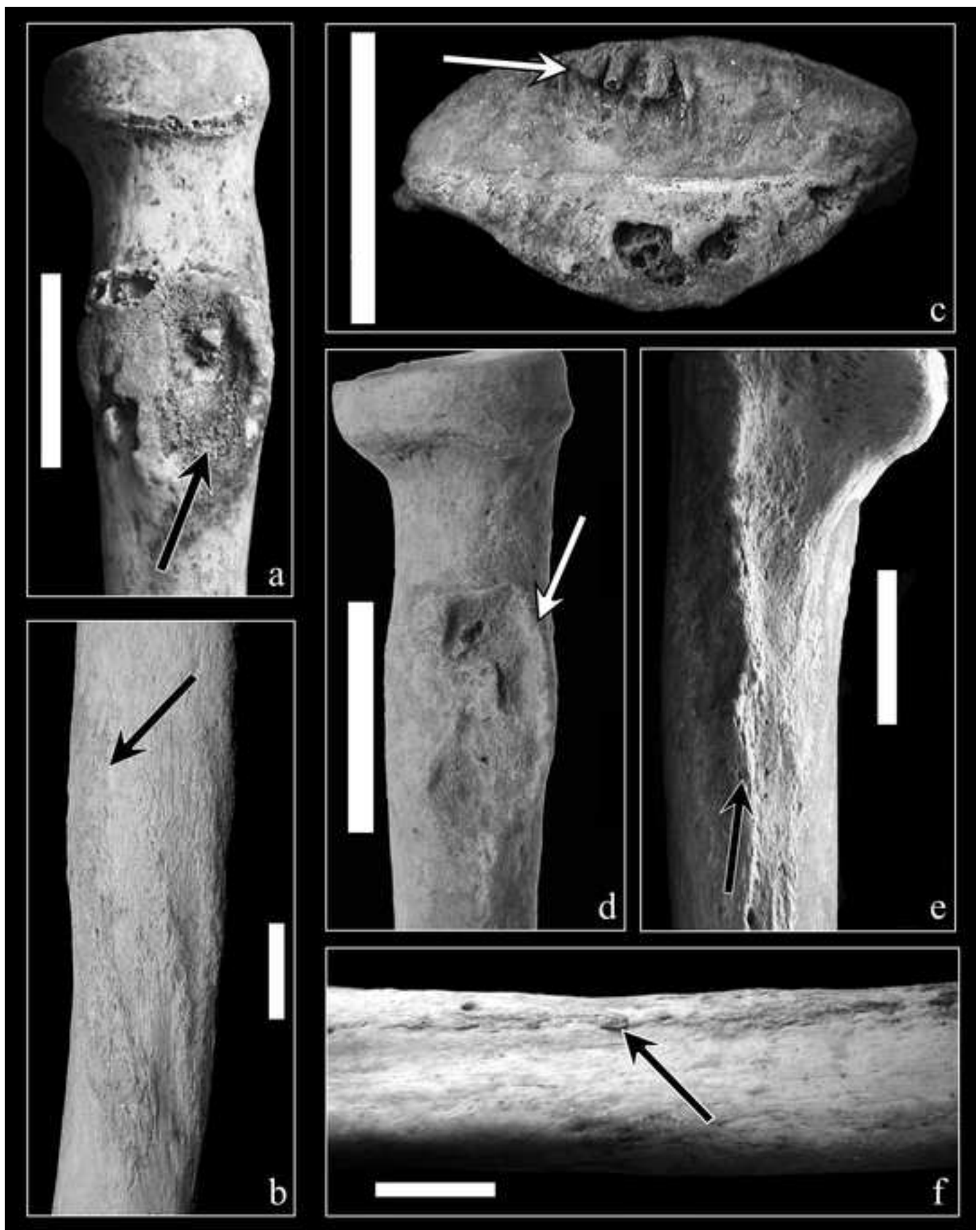

Figure 2
[Click here to download high resolution image](#)

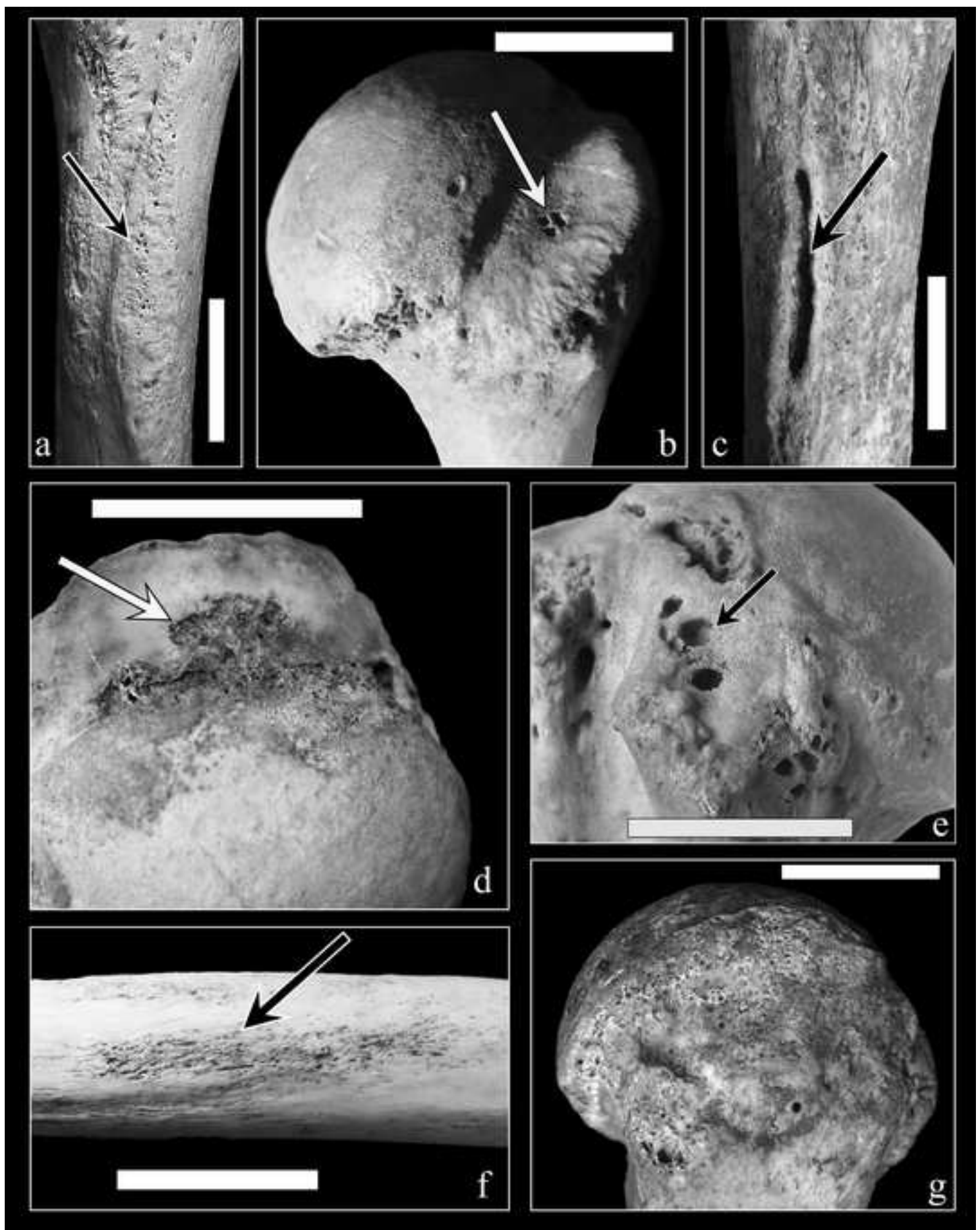


Figure 3
[Click here to download high resolution image](#)

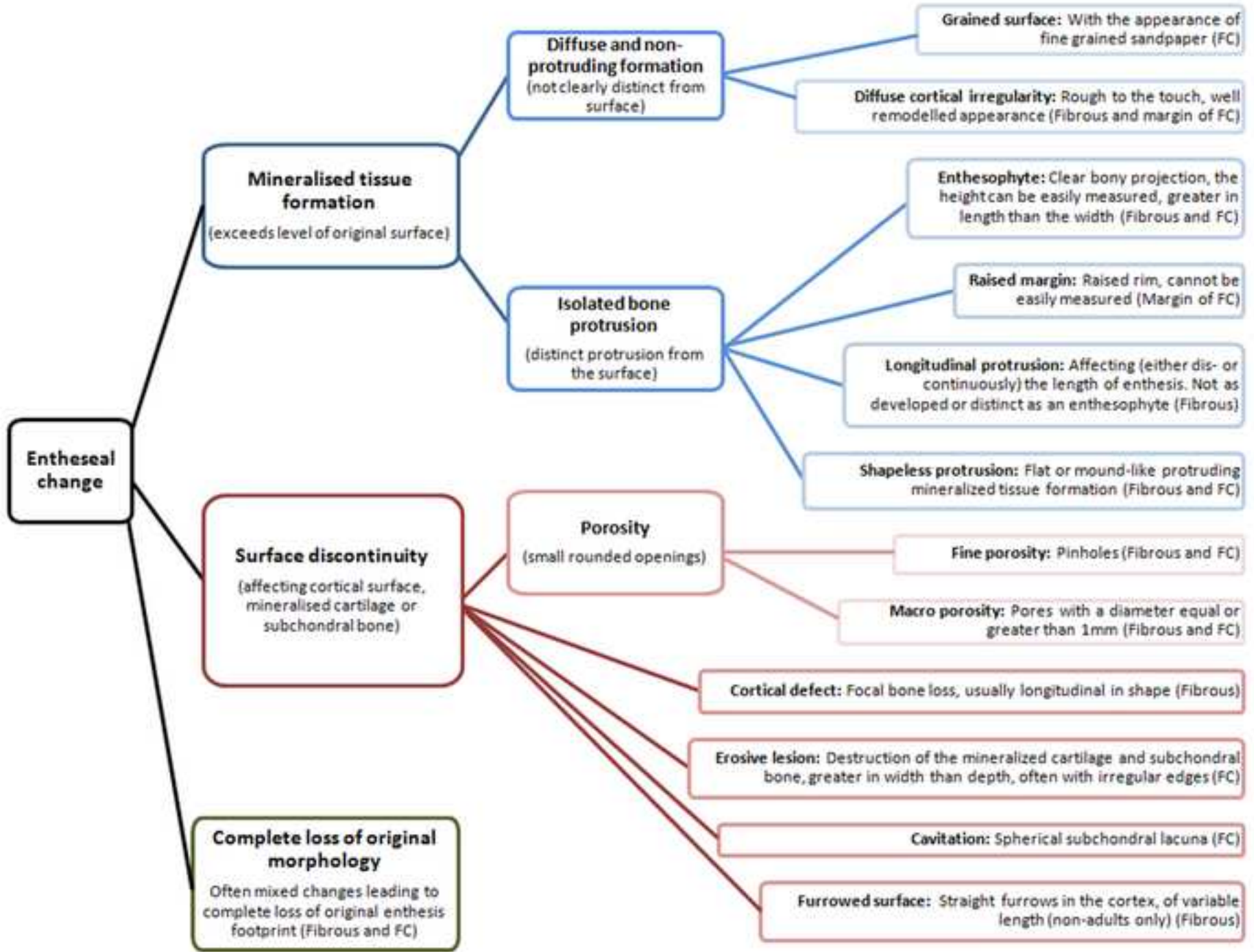


Table 1.

Answers	N
Enthesophyte(s)	13
Osteophyte(s)	5
Exostosis / exostoses	4
Bone spur(s)	2
Bone growth(s) / outgrowth(s)	2
EC	2
Bone formation	1
Enthesitis	1
Hyperostotic change(s)	1
Osteophytic formation	1
<i>Total</i>	<i>32</i>

Table 2

Term	French	Italian	Portuguese	Spanish	German	Illustrations in previous papers by the authors
1. Mineralised tissue formation	Formation de tissu minéralisé	Formazione di tessuto mineralizzato	Formação de tecido mineralizado	Formación de tejido mineralizado	Bildung von mineralisiertem Knochengewebe	
<i>1.1. Diffuse and non-protruding formation</i>	Formation diffuse et non saillante	Formazione diffusa e non sporgente	Formação difusa e não protrusa	Formación difusa y no saliente	Ausbildung diffuser und nicht-erhabener Struktur	
<i>1.1.1. Grained surface</i>	Surface rapeuse / granuleuse	Superficie granulare	Superfície granular	Superficie granular	körnige Oberfläche	Fig. 3a in Henderson et al., 2015
<i>1.1.2. Diffuse cortical irregularity</i>	Irregularité corticale diffuse	Irregolarità corticale diffusa	Irregularidade cortical difusa	Irregularidad cortical difusa	diffuse kortikale Unregelmäßigkeit	Fig. 1e and 5c in Villotte 2006
2. Isolated bone protrusion	Projection osseuse isolée	Protrusione (o escrescenza) ossea isolata	Protrusão óssea isolada	Protuberancia ósea aislada	isolierter Knochenvorsprung	
<i>2.1. Enthesophyte</i>	Enthésophyte	Entesofita	Entesófito	Entesofito	Enthesiophyt	Fig. 3b in Villotte 2006; Fig. 2-4 in Mariotti et al., 2004
<i>2.2. Raised margin</i>	Marge saillante	Margine rialzato	Margem saliente	Margen saliente	erhöhter Rand	Fig. 1c in Villotte 2006
<i>2.3. Longitudinal protrusion</i>	Saillie longitudinale	Cresta longitudinale	Protrusão longitudinal	Protuberancia longitudinal	longitudinaler Knochenvorsprung	Fig. 5g in Villotte 2006; Fig. 18, 19, 23 in Mariotti et al., 2007
<i>2.4. Shapeless protrusion</i>	Saillie amorphe	Protrusione (o escrescenza) amorfa	Protrusão amorfa	Protuberancia amorfa	formloser Knochenvorsprung	Fig. 6 in Mariotti et al., 2004
3. Surface discontinuity	Solution de continuité de la surface	Superficie discontinua/discontinuità della superficie	Discontinuidade na superfície	Discontinuidad en la superficie	Oberflächendiskontinuität	
<i>3.1. Porosity</i>	Porosité	Porosità	Porosidade	Porosidad	Porosität	Fig. 4a in Henderson et al., 2015
<i>3.1.1. Fine porosity</i>	Porosité fine	Porosità fine	Porosidade fina	Porosidad fina	Feinporosität	Fig. 2b in Villotte 2006
<i>3.1.2. Macro porosity</i>	Macro porosité	Macroporosità	Macroporosidade	Macro porosidad	Makroporosität	Fig. 3c in Henderson et al., 2015
<i>3.2. Cortical defect</i>	Défaut cortical	Difetto corticale	Defeito cortical	Defecto cortical	kortikaler Defekt	Fig. 5i in Villotte 2006; Fig. 11 and 14 in Mariotti et al., 2004
<i>3.3. Erosive lesion</i>	Lésion érosive	Lesione erosiva / erosione	Lesão erosiva	Lesión erosiva	erosive Läsion	Fig. 3c in Villotte 2006

<i>3.4. Cavitation</i>	Géode	Cavitazione	Cavitação	Cavitación	Hohlraum	Fig. 2b and 5 in Henderson et al., 2015
<i>3.5. Furrowed surface</i>	Surface couverte de sillons	Superficie solcata	Superfície sulcada	Superficie surcada	geriffelte Oberfläche	Fig. 5 in Villotte and Knüsel 2013
<i>4. Complete loss of original morphology</i>	Perte complete de la morphologie originale	Perdita della morfologia originale	Perda completa da morfologia original	Perdida completa de la morfología original	vollständiger Verlust der ursprünglichen Morphologie	