



HAL
open science

Prenatal imaging features suggestive of liver gestational allo immune disease

C. Sciard, S. Collardeau-Frachon, A. Atallah, D. Combourieu, J. Massardier, S. Heissat, P. Gaucherand, L. Guibaud, M. Massoud

► To cite this version:

C. Sciard, S. Collardeau-Frachon, A. Atallah, D. Combourieu, J. Massardier, et al.. Prenatal imaging features suggestive of liver gestational allo immune disease. *Journal of Gynecology Obstetrics and Human Reproduction*, 2019, 48 (1), pp.61–64. 10.1016/j.jogoh.2018.11.005 . hal-02195198

HAL Id: hal-02195198

<https://hal.science/hal-02195198v1>

Submitted on 21 Oct 2021

HAL is a multi-disciplinary open access archive for the deposit and dissemination of scientific research documents, whether they are published or not. The documents may come from teaching and research institutions in France or abroad, or from public or private research centers.

L'archive ouverte pluridisciplinaire **HAL**, est destinée au dépôt et à la diffusion de documents scientifiques de niveau recherche, publiés ou non, émanant des établissements d'enseignement et de recherche français ou étrangers, des laboratoires publics ou privés.



Distributed under a Creative Commons Attribution - NonCommercial 4.0 International License

Title: Prenatal imaging features suggestive of liver gestational allo immune disease

Short title: Ultrasound aspect of liver gestational allo immune disease

Clémentine Sciard¹, Sophie Collardeau-Frachon², Anthony Atallah¹, Danièle Combourieu¹, Jérôme Massardier¹, Sophie Heissat³, Pascal Gaucherand¹, Laurent Guibaud^{1,4}, Mona Massoud¹

1- Fetal Medicine unit, Université Claude Bernard, Lyon 1, Hospices Civils de Lyon, Hôpital Femme Mère Enfant, 59 boulevard Pinel 69500 Bron-Lyon, France

2- Department of Fetal and perinatal pathology, Université Claude Bernard, Lyon 1, Hospices Civils de Lyon, Hôpital Femme Mère Enfant, 59 boulevard Pinel 69500 Bron-Lyon, France

3- Pediatric unit, Université Claude Bernard, Lyon 1, Hospices Civils de Lyon, Hôpital Femme Mère Enfant, 59 boulevard Pinel 69500 Bron-Lyon, France

4 - Department of Radiology and Fetal Imaging, Université Claude Bernard, Lyon 1, Hospices Civils de Lyon, Hôpital Femme Mère Enfant, 59 boulevard Pinel 69500 Bron-Lyon, France

Corresponding author: Mona Massoud

Fetal Medicine unit, Université Claude Bernard, Lyon 1, Hospices Civils de Lyon, Hôpital Femme Mère Enfant, 59 boulevard Pinel 69500 Bron-Lyon, France

mona.massoud@chu-lyon.fr

All authors declare no conflict of interest

Funding statement: none

Pediatric knowledge of Neonatal Hemochromatosis is frequently described in medical literature. However, few articles deal with the antenatal suspicion and management of neonatal hemochromatosis. This article tends to highlight the ultrasound features and the pathological description of this uncommon disease.

ABSTRACT

We report prenatal imaging features of four cases of neonatal hemochromatosis due to an alloimmune disease. All cases exhibited intra uterine growth restriction (IUGR) without arguments for a vascular etiology, associated with oligohydramnios. Placental hydrops was present in 75% of cases. Splenomegaly was identified in one case. Other causes of NH have been ruled out during diagnostic workup including karyotype, detection of IGFBP-1 to evaluate a premature rupture of membranes, maternal serologic tests. MRI was performed in two cases and showed an atrophic liver associated with a low signal intensity on T2-sequence in one case. Prenatal NH was suspected in this later case and the fetus was successfully treated with two IVIG (intravenous immunoglobulins) perfusions performed during pregnancy followed by exchange transfusion and IVIG after birth. The child is doing well with normal liver function tests after 17 months of follow up. Our aim was to highlight the importance of suggesting NH-GALD when facing IUGR with oligohydramnios, ascites, placental hydrops, splenomegaly on prenatal ultrasound with negative work up for placental vascular pathologies and infectious fetopathies. MRI might be of a good help, showing an atrophic liver but enhancing iron overload in hepatic and extrahepatic tissue is helpful but not constant.

KEY WORDS: neonatal hemochromatosis, prenatal diagnosis, iron overload, gestational allo immune liver disease, oligohydramnios, IUGR, placental hydrops, fetal ascites.

CASE SERIES

Neonatal hemochromatosis (NH) (OMIM 231100) is a rare gestational disease characterized by severe liver injury associated with hepatic and extrahepatic iron overload, that classically spare the reticuloendothelial system [1]. It is the main cause of neonatal liver failure (NLF).

However, NH is a phenotype which can be due to many causes: infections (including parvovirus and CMV), metabolic disorders (transaldolase deficiency, galactosemia, hereditary tyrosinemia type 1, mitochondrial respiratory chain disorders (MRC2)[2]), inborn errors of bile-acid synthesis [3,4], familial lymphohistiocytosis, , and gestational allo immune liver disease (GALD). The rate of mortality and recurrence of GALD is very high (80-92%)[5,6]. Without any treatment, the prognosis is poor with a high risk of fetal stillbirth or neonatal death[7]. A successful treatment has been first proposed by Whittington et al in 2004 and has significantly improved the outcome of this disease: it consisted in administration of high-dose intravenous immunoglobulin (IVIg) 1g/kg during pregnancy , associated with exsanguino transfusion in newborn [5]. Knowing that prenatal treatment could be proposed and might improve the evolution, prenatal diagnosis of NH could have a real interest. However, diagnosis of NH-GALD is rarely made during the prenatal period, it is mainly suggested during the post-mortem examination. We reviewed our cases of NH-GALD (Neonatal hemochromatosis- gestational allo immune liver disease) in order to assess specific signs on prenatal imaging that might suggest the diagnosis. We retrospectively analyzed four cases of NH related to GALD whose ultrasound files were available in the department of fetal medicine, between 2006 and 2016. The comity considered NH owing to GALD if the following criteria were met: multigravida patients, maternal obstetric history of subsequent pregnancies resulting in fetal death or NLF, history of fetal autopsy or liver biopsy consistent with NH, positive immunostaining with monoclonal antibodies to human C5b-9 neoantigen, and exclusion of other NH in relation with infections and metabolic disorders [7].

All of our patients were referred after 18 weeks and underwent fetal ultrasound between 19 and 32 weeks. None of the patients have a history of consanguinity. All mothers were multigravida and two of them had a history of previous fetal demise (cases 1 and 4). All fetuses presented with intra uterine growth restriction (IUGR) (Figure 1) without arguments for vascular etiology (Normal Doppler analysis). Oligohydramnios was observed in all patients (figure 1). In three of them, placental hydrops and fetal ascites (cases 2, 3 and 4) were noted. Splenomegaly was identified in one case (case 4), but the spleen was not examined in the other cases. Diagnostic work-up including karyotype, PROM test, maternal serologic tests

(HSV, CMV, parvoB19, EBV) was normal. MRI was performed in two cases at 32 and 33 weeks (cases 3 and 4) and showed an atrophic liver. It was associated with a T2 low signal intensity-in the liver suggestive of iron overload in case 4. This case also exhibited a splenomegaly (Figures 2a, 2b). In this case (case 4), prenatal NH was suspected and the fetus was successfully treated with two IVIG perfusions at the dose of 1g/kg body weight, during two weeks after the diagnosis. One exchange transfusion with two IVIG perfusions were performed after birth. Liver biopsy performed at two month, confirmed hepatic liver overload. Investigations for mitochondrial cytopathies were negative. MRI anomalies of liver and spleen remained similar one month later. Then, he was only followed with abdominal ultrasound and liver function tests. To date, after 17 months of follow up, this child is doing well with normal liver function tests and normal liver imaging features. Moderate splenomegaly is still remaining. The 3 other cases died: fetal death occurred at 21 weeks in case 1, caesarian section was performed in case 2 at 30 weeks due to IUGR but the newborn died at day 3, and medical termination of pregnancy was performed at 32 weeks in case 3 regarding the poor prognosis discussed during prenatal counseling . Diagnosis of NH was performed at autopsy for these three cases (cases 1, 2 and 3) and GALD was retained after an extensive work-up allowing ruling out other NH causes (Table 1). Immunostaining with C5b-9 antibody was positive in case 1, 2 and 3 (respectively 5, 80 and 60%) (Figure 3). In case 4, it was not significant.

DISCUSSION

NH related to GALD is a rare severe disease. Mortality without treatment is extremely high with a rate of lethal recurrence approximately around 90% [8]. Baruteau et al reported 33% of fetal demise and 67% of neonatal death. According to Whittington et al, GALD is the most common cause of NH [9]. NH is clearly underdiagnosed and diagnosis is often performed at autopsy [10]. We also report 3 cases in which (case 1 to 3) the diagnosis was made at post-mortem examination. If the diagnosis is not suggested before birth, practitioners may have difficulties attributing symptoms to NH since neonatal presentation of liver failure is not specific of NH that is often misdiagnosed and global sepsis or metabolic disorders[11] could be suggested instead. In our study, one of the surviving newborn died on the third day; clinical and biological investigations showed severe coagulopathy with disseminated intravascular coagulation syndrome, elevated level of alpha foeto protein (70736 ng/ml) and hyperferritinemia (2948 ng/ml). Such laboratory findings were found in most of the neonates described in the literature with a NH-GALD. The only way to confirm the diagnosis of NH is

based on histopathological proof (Figure 3). Positive immunostaining with C5b-9 antibody can be helpful to diagnose GALD but is not specific as this antigen can be expressed in non GALD- NH cases[12].

Only few articles have studied prenatal ultrasound pattern related to this rare pathology. In our series IUGR and oligohydramnios were present in all cases. Baruteau et al reported 78% of oligohydramnios and 56% of IUGR. Heissat et al reported 43% of IUGR in NH fetuses. However, when facing a case of IUGR with normal Doppler examinations, and a negative work up for other common etiologies of IUGR, it could be interesting to raise the suspicion of NH-GALD especially when ascites or placenta hydrops are associated and one should be aware to search for a splenomegaly. Heissat et al reported 63% of edema or ascites [13]. We also observed one case with mild splenomegaly. Spleen biometrics were not assessed in the three other cases. Mild enlargement of the spleen can be explained by extrahepatic hematopoiesis [10]. However, when splenomegaly is important, one should think of familial lymphohistiocytosis, which can lead to NH phenotype.

Only two MRI have been performed in our series (case 3 and 4), an atrophic liver was seen in both cases, and only one MRI showed accumulation of iron in hepatic and extra hepatic tissues. Iron overload is not the first injury of the disease. It only appears after hepatocytes lysis due to complement mediated inflammation [14]. However, this MRI showed an atrophic liver with an enlarged spleen. Our four cases highlight the fact that diagnosis of NH during pregnancy is complicated and often undone. Indeed, when facing IUGR with normal doppler flowmetry and anhydramnios, placenta hydrops with/or without associated ascites or edema, splenomegaly during ultrasound assessment associated to an atrophic liver with or without overload of iron in the hepatic and extrahepatic tissue, on MRI, one should consider the prenatal diagnosis of NH-GALD. Complementary examinations should include prenatal MRI, karyotype, PROM test, and maternal serologic tests to look for others causes. Neonatal hemochromatosis is not a single disorder but is a phenotype.

Prenatal diagnosis of GALD remains challenging during prenatal period. However, we underline that recognition of NH is crucial when facing IUGR with anhydramnios, placental hydrops, fetal ascites, splenomegaly on prenatal ultrasound with negative work up for placental vascular pathologies and infectious fetopathies. MRI might be of a good help, showing an atrophic liver but enhancing iron overload in hepatic and extrahepatic tissue is helpful but not constant. One should be aware of subtle differential diagnosis including metabolic disorders, placental vascular pathologies and infectious fetopathies.

Figure 1. Ultrasound examination with an axial view of the abdominal circumference. Intra uterine growth restriction and anhydramnios with a splenomegaly (S)

Figure 2a. Zoom of T2-weighted coronal MR imaging of the fetal abdomen - hypointense atrophic liver (L) and a splenomegaly (S)

Figure 2b. Zoom of T2-weighted axial MR imaging on fetal abdomen - hypointense atrophic liver (L) and a splenomegaly (S)

Figure 3 (a,b,c) Microscopic features of the liver

(a) HES (hematoxylin Eosin Saffron) staining x 100

(b) Perls staining x 100

(c) C5b9 immunostaining x 100

References

- [1] Whittington PF. Fetal and infantile hemochromatosis. *Hepatology* 2006;43:654–60. doi:10.1002/hep.21129.
- [2] Lee WS, Sokol RJ. Mitochondrial hepatopathies: advances in genetics and pathogenesis. *Hepatology* 2007;45:1555–65. doi:10.1002/hep.21710.
- [3] Siafakas CG, Jonas MM, Perez-Atayde AR. Abnormal bile acid metabolism and neonatal hemochromatosis: a subset with poor prognosis. *J Pediatr Gastroenterol Nutr* 1997;25:321–6.
- [4] Shneider BL, Setchell KD, Whittington PF, Neilson KA, Suchy FJ. Delta 4-3-oxosteroid 5 beta-reductase deficiency causing neonatal liver failure and hemochromatosis. *J Pediatr* 1994;124:234–8.
- [5] Whittington PF, Hibbard JU. High-dose immunoglobulin during pregnancy for recurrent neonatal haemochromatosis. *Lancet Lond Engl* 2004;364:1690–8. doi:10.1016/S0140-6736(04)17356-X.
- [6] Rand EB, Karpen SJ, Kelly S, Mack CL, Malatack JJ, Sokol RJ, et al. Treatment of neonatal hemochromatosis with exchange transfusion and intravenous immunoglobulin. *J Pediatr* 2009;155:566–71. doi:10.1016/j.jpeds.2009.04.012.
- [7] Baruteau J, Heissat S, Broué P, Collardeau-Frachon S, Bouvier R, Fabre M, et al. Transient neonatal liver disease after maternal antenatal intravenous Ig infusions in gestational alloimmune liver disease associated with neonatal haemochromatosis. *J Pediatr Gastroenterol Nutr* 2014;59:629–35. doi:10.1097/MPG.0000000000000514.
- [8] Whittington PF. Gestational alloimmune liver disease and neonatal hemochromatosis. *Semin Liver Dis* 2012;32:325–32. doi:10.1055/s-0032-1329901.
- [9] Shanmugam NP, Bansal S, Greenough A, Verma A, Dhawan A. Neonatal liver failure: aetiologies and management--state of the art. *Eur J Pediatr* 2011;170:573–81. doi:10.1007/s00431-010-1309-1.
- [10] Collardeau-Frachon S, Heissat S, Bouvier R, Fabre M, Baruteau J, Broue P, et al. French retrospective multicentric study of neonatal hemochromatosis: importance of autopsy and autoimmune maternal manifestations. *Pediatr Dev Pathol Off J Soc Pediatr Pathol Paediatr Pathol Soc* 2012;15:450–70. doi:10.2350/12-02-1155-OA.1.
- [11] Feldman AG, Whittington PF. Neonatal hemochromatosis. *J Clin Exp Hepatol* 2013;3:313–20. doi:10.1016/j.jceh.2013.10.004.
- [12] Dubruc E, Nadaud B, Ruchelli E, Heissat S, Baruteau J, Broué P, et al. Relevance of C5b9 immunostaining in the diagnosis of neonatal hemochromatosis. *Pediatr Res* 2017. doi:10.1038/pr.2017.8.
- [13] Heissat S, Collardeau-Frachon S, Baruteau J, Dubruc E, Bouvier R, Fabre M, et al. Neonatal hemochromatosis: diagnostic work-up based on a series of 56 cases of fetal death and neonatal liver failure. *J Pediatr* 2015;166:66–73. doi:10.1016/j.jpeds.2014.09.030.
- [14] Pan X, Kelly S, Melin-Aldana H, Malladi P, Whittington PF. Novel mechanism of fetal hepatocyte injury in congenital alloimmune hepatitis involves the terminal complement cascade. *Hepatology* 2010;51:2061–8. doi:10.1002/hep.23581.

Figure 1 . Ultrasound examination with an axial view of the abdominal circumference. Intra uterine growth restriction and anhydramnios with a splenomegaly (S)

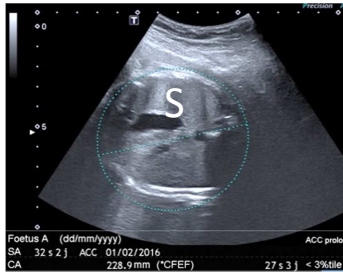


Figure 2a. Zoom of T2-weighted coronal MR imaging of the fetal abdomen - hypointense atrophic liver (L) and a splenomegaly (S)

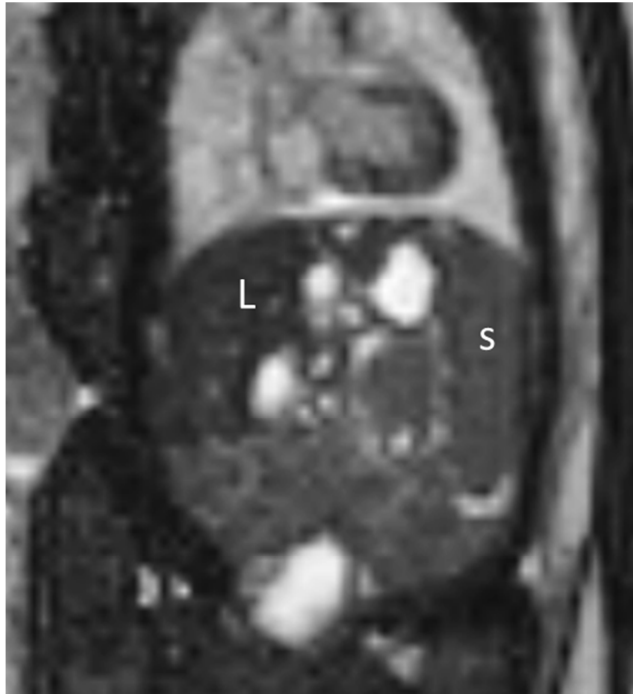
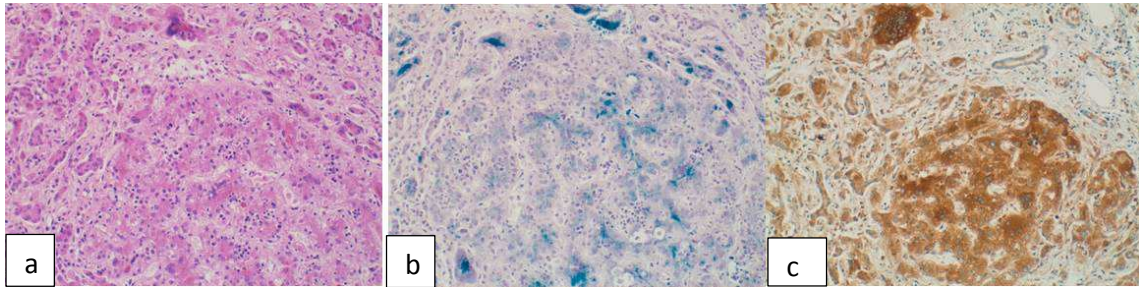


Figure 2b. Zoom of T2-weighted axial MR imaging on fetal abdomen - hypointense atrophic liver (L) and a splenomegaly (S)

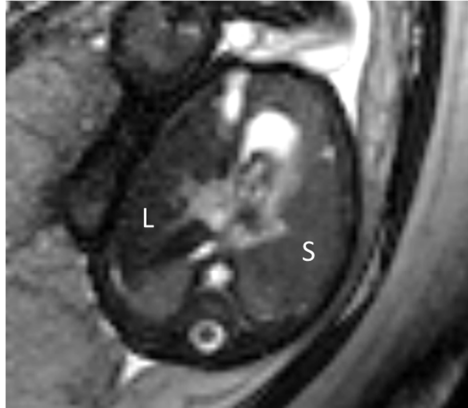

Figure 3 (a,b,c) Microscopic features of the liver



(a) HES (hematoxylin Eosin Saffron) staining x 100

(b) Perls staining x 100

(c) C5b9 immunostaining x 100

Table 1

Cases	GA at referral (weeks)	Prenatal sonographic findings	MRI	Pregnancy outcome	NH diagnosis
1	19	Hydrops fetalis	-	Fetal demise 21 weeks	Autopsy - intense iron overload - positive immunostaining
2	29	IUGR Anhydramnios Ascites Placental hydrops	-	Cesarean section at 30 weeks and neonatal death at day 3	Autopsy - fibrosis and atrophic liver - intense iron overload - splenomegaly - positive immunostaining
3	32	IUGR Anhydramnios Ascites Hyperechoic intestines Placental hydrops	Atrophic liver No iron accumulation	Termination of pregnancy at 32 weeks	Autopsy - fibrosis and atrophic liver - iron overload - positive immunostaining
4	32	IUGR Anhydramnios Ascites Splenomegaly Placental hydrops	Atrophic liver Iron accumulation	Prenatal IVIG Cesarean section at 34 weeks Postnatal ET and IVIG	Liver biopsy after birth - fibrosis - moderate iron overload - no significant positive immunostaining