



**HAL**  
open science

## No structural Brain differences in 'de novo' Parkinsonian patients

Verónica Muñoz Ramírez, Florence Forbes, Pierrick Coupé, Michel Dojat

### ► To cite this version:

Verónica Muñoz Ramírez, Florence Forbes, Pierrick Coupé, Michel Dojat. No structural Brain differences in 'de novo' Parkinsonian patients. OHBM 2019 - 25th Annual Meeting of the Organization for Human Brain Mapping, Jun 2019, Rome, Italy. pp.1-5. hal-02192447

**HAL Id: hal-02192447**

**<https://hal.science/hal-02192447v1>**

Submitted on 23 Oct 2019

**HAL** is a multi-disciplinary open access archive for the deposit and dissemination of scientific research documents, whether they are published or not. The documents may come from teaching and research institutions in France or abroad, or from public or private research centers.

L'archive ouverte pluridisciplinaire **HAL**, est destinée au dépôt et à la diffusion de documents scientifiques de niveau recherche, publiés ou non, émanant des établissements d'enseignement et de recherche français ou étrangers, des laboratoires publics ou privés.

# No Structural Brain Differences in 'de novo' Parkinsonian Patients

## Submission No:

2021

## Submission Type:

Abstract Submission

## Authors:

Verónica Muñoz Ramírez<sup>1</sup>, Florence Forbes<sup>2</sup>, Pierrick Coupé<sup>3</sup>, Michel Dojat<sup>1</sup>

## Institutions:

<sup>1</sup>Inserm U1216, Univ. Grenoble Alpes, La Tronche, France, <sup>2</sup>Inria, Univ. Grenoble Alpes, CNRS, Grenoble INP, LJK, Montbonnot, France, <sup>3</sup>Laboratoire Bordelais de Recherche en Informatique, UMR 5800, Univ. Bordeaux, France

## Introduction:

In general, the diagnosis of Parkinson's disease (PD) is dependent on the identification of motor symptoms benchmarked by a loss of 50% of nigrostriatal neurons. This strongly motivates the definition of biomarkers to detect PD at the earliest pre-clinical stages. Morphological brain differences between PD and healthy controls (HC) can potentially reveal key regions affected during the PD prodromal phase. Voxel-based morphometry (VBM) is a popular automatic technique allowing the detection of subtle morphometric group differences at a voxel level in structural MRI.

## Methods:

We performed a VBM study of 144 de novo PD patients (age:  $61.30y \pm 9.06$ ; sex: 53F) and 66 HC (age:  $60.12y \pm 11.39$ ; sex: 23F) from the PPMI database [1] through two different state-of-the-art pipelines: 1) CAT12 [2] and 2) volBrain [3]. All 3D T1-weighted scans selected were obtained under the same acquisition conditions. Both CAT12 and volBrain follow similar pre-processing steps including intensity normalization, bias and noise correction. CAT12 registers the images to a reference brain using an affine and non-linear method, whereas volBrain utilizes a linear affine transformation. For tissue segmentation, CAT12 integrates a classical Markov Random Field and the Adaptive Maximum Posterior (AMAP) technique to reduce the dependency on tissue probability maps. In addition, partial volumes are estimated using two additional mixed classes: GM-WM and GM-CSF. volBrain robustly computes the mean values of the different tissues by excluding partial volume voxels and using an unbiased robust mean estimator [3]. Partial volume coefficients are computed as well. volBrain segments the brain into cerebrum, cerebellum, brainstem, hemispheres and seven subcortical structures (putamen, caudate, globus pallidus, thalamus, hippocampus, amygdala, and accumbens) with a multi-template method that considers a non-local label fusion scheme [4]. Additionally substantia nigra was manually delineated. The segmented images from both pipelines (Fig 1) were modulated and smoothed with an isotropic Gaussian kernel (8mm). The statistical analysis was performed with CAT12. We designed a general linear model (GLM) where age, sex, and total intracranial volumes (TIV) were used as covariates and compared GM and WM maps of PD vs HC with a two-sample T-test. To equilibrate size populations [5], we repeated our analysis five times with 66 controls versus 66 randomly selected patients using sampling with replacement technique.

## Results:

For the differential analysis, PD vs HC, no voxels survive ( $p < 0.05$  FWE corr.) for neither CAT12 or volBrain tissue images. We also analyzed independently the subcortical structures segmented by volBrain, previously deformed to CAT12 template space with DARTEL. No differences were found ( $p < 0.05$  FWE corr.). Exploratory analysis ( $p < 0.001$  uncorr.) revealed decreases in caudate nucleus, hippocampus, putamen and substantia nigra (manually segmented). No differences were found ( $p < 0.05$  FWE corr.) in the equilibrated populations.

### Conclusions:

Using two recent approaches for accurate tissue classification (CAT12 and volBrain) we failed to detect robust structural differences between de novo PD patients and healthy controls. Findings of structural brain differences reported in the literature tend to be contradictory. This lack of consensus may be due to a variety of factors, notably the study of small cohorts, differences in segmentation techniques, and more importantly, the lack of correction for multiple comparison inevitably increasing false positive rates. We reinforce the message that VBM is a delicate technique involving many parameters that should be handled with care to avoid false positive impacting the final results [5]. In sight of the lack of morphological differences, we suspect that early PD biomarkers may lie on the physiological properties of the Parkinsonian brain and could be investigated through quantitative MRI techniques (relaxometry, diffusion and perfusion imaging).

### Disorders of the Nervous System:

Parkinson's Disease and Movement Disorders <sup>1</sup>

### Imaging Methods:

Anatomical MRI <sup>2</sup>

### Modeling and Analysis Methods:

Segmentation and Parcellation

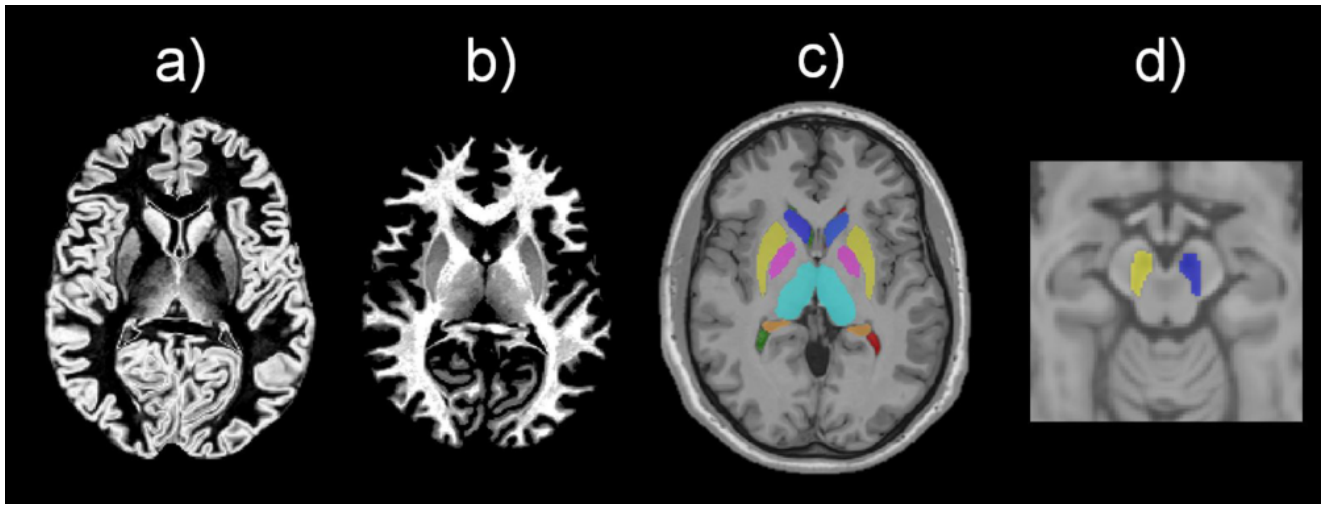
### Neuroanatomy:

Cortical Anatomy and Brain Mapping  
Subcortical Structures

### Keywords:

Degenerative Disease  
Morphometrics  
MRI  
Neurological  
Segmentation  
STRUCTURAL MRI  
Sub-Cortical

<sup>1|2</sup>Indicates the priority used for review



·volBrain segmentation: a) GM, b) WM and c) subcortical structures. d) Manually segmented substantia nigra.