



## **Total femur replacement in non-oncologic indications: Functional and radiological outcomes from a French survey with a mean 6 years' follow-up**

Sophie Putman, Henri Migaud, Dominique Saragaglia, Jean-Yves Jenny,  
Franck Dujardin, Antoine-Guy Hue, Fabrice Fiorenza, Olivier Meric, Paul  
Bonnevialle

### **► To cite this version:**

Sophie Putman, Henri Migaud, Dominique Saragaglia, Jean-Yves Jenny, Franck Dujardin, et al.. Total femur replacement in non-oncologic indications: Functional and radiological outcomes from a French survey with a mean 6 years' follow-up. *Orthopaedics & Traumatology: Surgery & Research*, 2019, 105 (4), pp.591-598. 10.1016/j.otsr.2018.12.013 . hal-02181571

**HAL Id: hal-02181571**

**<https://hal.science/hal-02181571>**

Submitted on 25 Oct 2021

**HAL** is a multi-disciplinary open access archive for the deposit and dissemination of scientific research documents, whether they are published or not. The documents may come from teaching and research institutions in France or abroad, or from public or private research centers.

L'archive ouverte pluridisciplinaire **HAL**, est destinée au dépôt et à la diffusion de documents scientifiques de niveau recherche, publiés ou non, émanant des établissements d'enseignement et de recherche français ou étrangers, des laboratoires publics ou privés.



Distributed under a Creative Commons Attribution - NonCommercial 4.0 International License

## Original article

# Total femur replacement in non-oncologic indications: Functional and radiological outcomes from a French survey with a mean 6 years' follow-up

Sophie **Putman**<sup>a,b,\*</sup>, Henri **Migaud**<sup>a,b</sup>, Dominique **Saragaglia**<sup>c</sup>, Jean-Yves **Jenny**<sup>d</sup>,  
Franck **Dujardin**<sup>e</sup>, Antoine-Guy **Hue**<sup>e</sup>, Fabrice **Fiorenza**<sup>f</sup>, Olivier **Méric**<sup>g</sup>, Paul  
**Bonnevialle**<sup>g</sup>, and French Hip and Knee Society (SFHG)<sup>h</sup>

a- Université de Lille Nord de France, 59000 Lille, France

b- Service d'Orthopédie, Hôpital Roger Salengro, Place de Verdun, Centre Hospitalier  
Régional Universitaire de Lille, 59037 Lille, France

c- Département universitaire de chirurgie orthopédique et de traumatologie du sport, CHU de  
Grenoble Hôpital Sud, Avenue de Kimberley 38130, Echirolles, France

d- Centre de Chirurgie Orthopédique et de la Main, Hôpitaux Universitaires de Strasbourg, 10  
Avenue Baumann, 67400, Illkirch-Graffenstaden, France

e- Département de chirurgie orthopédique, Hôpital Charles Nicolle, CHU de Rouen, 1 rue de  
Germont, 76031 Rouen, France

f- Service d'Orthopédie Traumatologie CHU Dupuytren, 2, avenue Martin-Luther-King,  
87042 Limoges, France

g- Département d'Orthopédie et Traumatologie CHU Toulouse. Hôpital PP Riquet. Place  
Baylac Toulouse, France

h- 52, rue Boissonade, 750014 Paris, France

\* Corresponding author : Sophie Putman, Service d'Orthopédie, Hôpital Roger Salengro,  
Place de Verdun, Centre Hospitalier Régional Universitaire de Lille, 59037 Lille, France  
Email = [sophie.putman@chru-lille.fr](mailto:sophie.putman@chru-lille.fr)

## Abstract:

## **Introduction**

There are few published studies on total femur replacement (TFR) because its indications are rare. Other than malignant diseases, the indications extend to revisions and interprosthetic femur fractures; however the outcomes of these indications have not been well defined. The aim of this retrospective survey was to analyze the complication rate and functional outcomes of these newer indications.

## **Hypothesis**

The morbidity and outcomes after TFR are comparable to those reported in the literature for non-cancer indications.

## **Material and Methods**

Between 1997 and 2016, 29 TFR procedures were done at 6 French teaching hospitals in 15 women and 14 men, average age  $68 \pm 14$  years [32–85]. The primary indication was degenerative joint disease in the hip and/or knee in 16 cases, mechanical failure of the implant used after tumor resection in 11 cases and femur fracture in 2 cases. The mean number of surgical procedures before TFR was 3.6 (maximum 5) at the hip and 4.5 (maximum 10) at the knee. Six different models were implanted consisting of a rotational hinge knee (except in one case); 20 patients received a dual mobility system and 9 a standard hip replacement bearing. The femoral shaft was partially conserved 21/29 times and the trochanter 25/29 times.

## **Results**

Five patients suffered a general complication and 12 suffered a local complication (including 4 hematomas and 2 hip dislocations). Eight patients (28.6%) suffered a surgical site infection, although three had a prior infection. Among the 12 patients with a history of infection or progressive infection before the TFR, 9 healed and 3 had the infection continue. At a minimum follow-up of 2 years and mean of 6 years, 23 TFR implants were still in place and not infected; the other 6 had been removed or were infected, including one patient who

underwent disarticulation. The median survival of the non-infected TFR was 15 years. At 10 years, 70% of TFR implants were still in place and non-infected.

Walking was possible with or without a cane in 15 patients (51.7%), with two canes or a walker in 12 patients (41.3%) and impossible in 2 patients. Active knee flexion averaged  $79.4^{\circ} \pm 30.3$  [0–120]; 17 patients (62.9%) had  $90^{\circ}$  or more flexion; two patients (7.4%) had no flexion. The extension deficit averaged  $3.7^{\circ} \pm 7$  [–20 to 10] and 20 patients had no flexion deformity. The leg length difference averaged  $1.3 \text{ cm} \pm 2.3$  [0–10]; 19 patients (67.8%) had no difference in leg length.

## **Discussion**

Our starting hypothesis was confirmed for the complication rate and clinical outcomes. The benefits of dual mobility cups are emphasized. While the indications for TFR are rare, they will likely increase in the coming years.

Level of evidence: IV, Retrospective cohort study

**Keywords:** Total femoral replacement. Hip arthroplasty loosening. Knee arthroplasty loosening. Periprosthetic femoral fracture. Chronic periprosthetic infection

## **1. Introduction**

Total femur replacement (TFR) – in which a diaphyseal stem joins total hip arthroplasty (THA) and total knee arthroplasty (TKA) implants – was performed for sarcoma diffusion by Marcove et al. [1] and then validated in cancer-related indications [2-6]. Buchman had previously published one case of resection–replacement for Paget’s disease of the femur [7],

followed by a few publications in the same, non-tumor context [8-11]. The role of this procedure is limited, as evidenced by the paucity of publications and the number of reported cases, except for Berend et al. [12] and Friesecke et al. [13].

In the French scientific literature, Soenen et al. [14] reported performing TFR in 3 patients following repeated failure of interprosthetic fractures. Other than in cases of tumor resection, the indications for TFR are rare: septic and mechanical revisions with multiple operations, along with mechanical failure of implants used in tumor resection cases [15-19]. The outcomes of TFR are not known in these indications, particularly in France. A retrospective survey was carried out with members of the French Hip and Knee Society (SFHG) about these newer indications to determine 1) the complication rate and 2) the functional outcomes. We hypothesized that morbidity and outcomes after TFR are comparable to those in the literature for non-cancer indications.

## **2. Material and Methods**

### **2.1. Inclusion criteria**

The inclusion criteria were repeated mechanical failure of ipsilateral THA and/or TKA whether accompanied or not by intra- or interprosthetic fracture; infection with removal-implantation in one or two steps. Failure of arthroplasty (TFR, THA or TKA) implanted for a cancer-related indication in a patient in long-term remission or who is cancer-free was included. A minimum of 2 years' follow-up was required for inclusion in the study. The exclusion criteria were any primary TFR following tumor resection and/or less than 2 years' follow-up.

### **2.2 Patients**

Between 1997 and 2016, 29 patients fitting these criteria underwent TFR at various French teaching hospitals: Grenoble (n=4), Lille (n=9), Limoges (n=1), Rouen (n=4), Strasbourg (n=4) and Toulouse (n=7). There were 15 women and 14 men with an average age of  $68 \pm 14$  years [32–85] at the time of TFR. Three patients were ASA 1, 17 patients were ASA 2, 8 patients were ASA 3 and 1 patient was ASA 5 [20]. The mean preoperative Parker and Palmer score was 5.4 [0–9] [21].

The initial femur pathology was a fracture in 2 cases, tumor resection in 11 cases (thus an indication for mechanical failure in a cancer-free patient) and degenerative joint disease in the hip and/or knee in 16 cases. For the 11 patients with a prior tumor, the mean follow-up was 12.4 years (minimum 3, maximum 23). None had clinical or radiological signs of local progression of the tumor. Details of these 29 cases are given in Figure 1. Twenty-seven of the 29 patients had undergone multiple procedures before the TFR; the clinical history of these patients is given in Figure 2. The mean number of procedures at all locations before the TFR was 3.6 (range, 1 to 10). At the hip, the mean number was  $3.6 \pm 1.8$  (maximum 5) and at the knee it was  $4.5 \pm 2.4$  (maximum 10). The reasons leading to TFR are listed in Figure 3.

At the time of TFR, 12 patients had a history of infection on the operated femur in one or both joints, of which 8 were progressive. Three had both knee and hip implants, while nine had a periprosthetic fracture at the THA or TKA.

### 2.3 Surgical technique

The following TFR implants were used: 10 Mega System (Waldemark-Link, Hamburg, Germany), 7 Global Modular Replacement System (Stryker, Pusignan, France) (Figure 4), 7 Mutars (Implantcast GmbH, Buxtehude, Germany) (Figure 5), 2 Modular Endoprosthetic Total System (Stanmore, Borehamwood, UK), 2 Orthopaedics Salvage System (Zimmer-Biomet, Brognard, France) and 1 Askorn (Askorn Medical, Cesson-Sévigné, France). The hip

joints had a standard bearing in 9 cases and dual mobility bearing in 20 cases. A metal reinforcement ring was implanted in the acetabulum in 6 cases. At the knee, a rotating hinge implant was used in all cases but one. The femoral shaft was partially conserved in 21 cases and completely resected in 8 cases. The trochanter was conserved in 25 cases and removed in 4 cases. All the tibial implants were cemented.

## **2.4 Assessment methods**

The data were collected in a spreadsheet used to capture standard demographic and epidemiology information, in particular the preoperative and postoperative ASA [20], Parker and Palmer [21] scores for patients above 65 years of age. The clinical and radiological evaluation carried out at the longest documented follow-up visit (beyond 2 years) was used.

## **2.5 Statistical methods**

All statistical tests were performed using the software Stata (version 8.4.6, O. Méricq, Toulouse, France). Qualitative variables were summarized by their counts and percentages, while the numeric variables were summarized by their mean and standard deviation. Student's *t*-test was used to compare different mean values, while the Chi<sup>2</sup> test was used with independent qualitative variables when the sample size was more than 5. Fisher's exact test was used when the sample size was less than 5. The significance threshold was set at  $p < 0.05$ .

# **3. Results**

## **3.1 Complications**

One patient had an intraoperative fat embolism with regressive cardiopulmonary arrest. In the early postoperative period, four patients suffered a general complication: stroke with neurological sequelae in one patient, pulmonary embolism in one patient and kidney

failure related to antibiotics in two patients. The following local complications were documented: hematoma (n=4), hip dislocation (n=2), wound healing disturbance (n=3), implant disassembly (n=1), trochanter detachment in one patient and tibial tuberosity avulsion (n=1). Eight patients (27.6%) suffered a surgical site infection (three of whom had an on-going infection). Among the 12 patients with a history of infection or on-going infection before the TFR, 9 healed and 3 remained infected, including one who required disarticulation. The four cases of septic etiology reported by one surgeon (JYJ) all resolved.

### 3.2 Survival

The minimum follow-up was 2 years, with a mean follow-up of  $6 \pm 4.5$  years. In our case series, the patients with a history of infection had the longest follow-up. The median actuarial survival was 18.1 years; at 10 years, 59% of patients were still alive. At the latest follow-up, 23/29 (79.6%) of TFR implants were still in place and not infected, while 6 (20.6%) had been removed or were infected and being treated with long-term antibiotics. The median survival of the 17 TFR cases without history of infection was 15 years; at 10 years, 17/12 (70%) of these patients still had the implants in place and were infection-free.

### 3.3 Functional outcomes

Walking was possible without a cane in 5 patients (17.2%), with one cane in 10 (34.5%), with two canes in 7 (24.1%) and with a walker in 5 (17.2%). Walking was impossible for two patients (6.9%) including the patient who underwent disarticulation. Active knee flexion (evaluated in 27 patients) averaged  $79.4^\circ \pm 30.3^\circ$  [ $0^\circ$ – $120^\circ$ ]; 17 patients (62.9%) had  $90^\circ$  or more knee flexion, 8 patients (29.6%) had flexion between  $40^\circ$  and  $85^\circ$  while two patients (7.4%) had no flexion. The knee extension deficit averaged  $3.7 \pm 7^\circ$  [ $-20^\circ$ ;  $+10^\circ$ ] with a maximum of  $20^\circ$ ; 20 patients (74.1%) had no flexion deformity. The average leg length difference was  $1.3 \pm 2.3$  cm (0 to 10 cm); 19 patients (67.8%) had less than 1 cm



difference in leg length. The mean final Parker and Palmer score was  $6.1 \pm 1.9$ ; 6 patients had a score of 8 or more (25 %) and 5 had a score between 1 and 2 (20.8%).

#### **4. Discussion**

This study has three main findings. 1) The indications for TFR are rare, with only 29 cases at 6 French teaching hospitals over a 20-year period. However, we believe the frequency will increase with revision of implants used in tumor resection and aging of the population contributing to revisions for interprosthetic fractures on weakened bone. 2) The frequency of infection-related complications is considerable (28%) with one patient requiring disarticulation. 3) The modest nature of the clinical outcomes is obvious: only 15 patients (58.6%) could walk normally or with a cane after TFR.

Among the six published studies of TFR for non-oncologic indications, two single-center studies differentiate themselves because of their sample size ([Table 1](#)). Berend et al. [13] reported the outcomes of a cohort of 59 patients operated for periprosthetic fracture or repeated loosening. The Hamburg Endo-Klinik case series reported by Friessecke et al. [14] consisted of 100 consecutive patients operated between 1973 and 2000. The indications in our study are identical overall to those of other published studies in terms of age and the number of prior surgeries, evidence of the extreme nature of the TFR indication. The same goes for the clinical outcomes, which are somewhat comparable given the outcome measures used, which essentially show improved patient autonomy.

The rarity of postoperative dislocations in our cohort (2/29 or 6.9%) can be attributed to the nearly systematic use of dual mobility implants; the instability rate in other studies was 25% to 40% ([Table 2](#)). Dual mobility implants have been shown to be very useful in the context of tumor resection [22-24]. In fact, the risk of instability is higher because of gluteal muscle atrophy secondary to multiple surgical procedures. Resection of a larger portion of the

femoral shaft leading to direct and unpredictable reattachment of the muscles on the implant, and the uncertain mechanical values of trochanter fixation or even its resection, increase this risk of instability. In most of the cases in our study, the aim was to preserve bone whenever possible (even if more demanding) [25-26]: femoral diaphysis preserved in 21 cases and trochanter in 25 cases.

The postoperative infection rate in our study was in the range of that reported in other published studies (Table 2). It corresponds to that of mega-prostheses in tumor resection surgery [27]. The highest infection rate was reported in a study with a minimum of 2 years' follow-up [19] like in the other reported studies. As in our study, more than 2 years' follow-up is recommended to confirm the revision has not resulted in an infection, especially when there is a history of infection or presence of an on-going infection.

The TFR indication was made in 12 patients in our study (41%) who had a history of infection or an on-going infection; this rate is similar to that in other published studies (Table 3). In the studies by Berend et al. [12] and Frisecke et al. [13], the infection healing rate after TFR was higher than in our study; however, their follow-up was shorter. The four cases of infection-only etiology belonging to one surgeon (JYJ) all had a good outcome, confirming the advantage of single-stage removal-implantation in a specialized center [28,29].

The limitations of our study are significant and are mainly related to the diversity of the source of patients, involvement of multiple surgeons, long time span and use of different implants. However, the nearly systematic implantation of a rotating hinge knee implant and the high frequency of dual mobility use at the hip joint contributed to the homogeneity of these cases. Similarly, the extreme nature of the procedures and the high number of prior procedures and infections offer insight into how this procedure will fare in the worst conditions, providing some external validation to our findings.

#### **4. Conclusion**

This study—both in terms of its indications and findings (clinical outcomes and complications observed)—is comparable to the literature and confirms our starting hypothesis. The indications for TFR are rare, but with the increase in the number of patients with ipsilateral hip and knee implants that could fail mechanically or due to infection, this scenario will be increasingly common in the future. When performing TFR for this indication, one should keep in mind the risk of disarticulation in case of failure.

#### **Conflict of interest:**

None of the authors have conflicts to declare related to this study. Outside this study, P Bonneville is a research and teaching consultant for Stryker, S Putman is a research and teaching consultant for Corin-Tornier, H Migaud is a Deputy Editor for Orthopaedics & Traumatology Surgery & Research and is a research and teaching consultant for Zimmer-Biomet, Corin-Tonier, MSD and SERF, JY Jenny has received royalties from B-Braun Aesculap, was a paid consultant for Exatech and received conference financing from FH Orthopaedics, D. Saragaglia has received royalties from B-Braun Aesculap, F. Dujardin is a consultant for SERF. The other authors have no conflict of interest outside this study.

#### **FUNDING**

No funding was received for this study

#### **Contributions**

PB collected the data, operated on patients and wrote the article HM and SP operated on patients, collected data and wrote the article; DS, JYJ, FD and FF operated on patients and collected data AGH and OM collected data.

Table 1: Demographics of the key recently published studies that have more than 10 patients.

(in studies 13 and 15, 4 and 2 patients respectively had metastatic indication)

Reference Patient inclusion years	Sex and mean age (years) (m) Implant	Indications	Mean and high/low number of prior surgeries
Berend et al. [12] 1987–2001	36 W/23 M Age = 74  Finn Orthopaedic Salvage System (Biomet)	21 periprosthetic fractures 5 repeated loosening 6 loosening and distal fracture 10 interprosthetic fractures	Hip: 3.3 (0–15)  Knee: 1.9 / N/S
Frisecke et al. [13] 1989–1997	87 W/13 M Age = 68  Endo-Modell total femur replacement (Waldemar-Link)	77 THA revisions (21 THA loosening / 31 THA and knee osteoarthritis / 25 periprosthetic fractures) 4 TKA revisions 25 periprosthetic fractures 19 interprosthetic fractures History of infection: 33	N/S
Fountain et al. [15] 1977–2007	5 M / 9 W Age = 63.7  Endo-Modell total femur replacement (Waldemar-Link)	12 aseptic loosening (8 THA / 3 THA and TKA / 1 TKA) 2 nonunions of interprosthetic fracture	Hip: 3.6/ 0–10 Hip and knee: 4 / 2–4
Hoell et al. [16] 1999–2010	12 (M/W?) Age = 73  Modular Universal Tumor and Revision System (Implantcast)	5 infections 7 loosening (5 THA / 2 TKA and 1 interprosthetic fracture)	Hip: 3.3 (0–10)  Knee: 1.8 (0–7)
Clement et al. [17] 2000–2010	8 M / 11 W Age = 68.4  GMRS (Stryker)	11 nonunions of periprosthetic fractures 2 femoral defects 2 septic nonunions 2 fractures below THA 2 metastasis	N/S
Amanatullah et al. [18] 1994–2007	4 M / 16 W Age = 65 16 GMRS (Stryker) 2 Orthopaedic Salvage System (Biomet) 2 Total Femur (Link)	10 infections  7 periprosthetic fractures  4 loosening	N/S
Toepfer et al. [19] 1995–2015	4 M / 14 W Age = 78 ± 7 Type MML ESKA /Orthodynamics	11 periprosthetic fractures 7 aseptic loosening	Periprosthetic fracture: 4.2 (1–8) Loosening: 2 (1–3)
Our study 1997–2016	14 M / 15 W Age = 67.3 9 Waldemar- Link, 7 GMRS, 7 Mutars, 3 Stanmore, and 3 others	17 loosening (7 THA, 3 THA-TKA, 3 TKA, 3 THA, 1 diaphyseal stem) 9 periprosthetic fractures 3 knee osteoarthritis with femoral implant in place History of infection / active infection: 12	Hip: 3.6 (0–10)  Knee: 4.5 (0–4)

THA: total hip arthroplasty, TKA: total knee arthroplasty, M: men, W: Women, N/S: Not specified

Table 2: Outcomes of the key recently published studies (N/S not specified)

Reference	Range and mean follow-up	Complications Postoperative infection	Other complications	Implant survival	Number of deaths
Berend et al. [12]	1–13 years m = 4 years, 10 months	8/59 (13.5%)	5 dislocations (8.4%) 2 leg length difference 1 knee stiffness	75% at 12.5 years	14 (23.7%) 0 perioperative
Frisecke et al. [13]	1 month–11.5 years  m = 4.9 years	12/100 (12%) (6 early / 6 late)	7 dislocation (7%) 3 loosening	N/S	3 perioperative (3%)
Fountain et al. [15]	1–17 years m = 7.5 years	3/14 infections (21%)  2 deep  1 superficial	6 dislocations (42.8%)  3 revised successfully / 3 left in dislocated state	N/S	1 at 1 year
Hoell et al. [16]	0.5–7.5 years  m = 2.6	None	1 sciatic palsy	N/S	None
Clement et al. [17]	0.7–12.4 m = 5.4	2/19 (10.5%): - long-term antibiotics - disarticulation	1 dislocation (reduction/successful)	86% at 10 years	5% at 1 year 58% at 10 years
Amanatullah et al. [18]	m = 6 ± 5 minimum 2 years	7/20 (35%)	5 dislocations (25%): - 4 revised - 1 reduction (successful)	65% at 5 years	None
Toepfer et al. [19]	m = 6.6 (2.3–11)	8/18 (44.4%)	5 dislocations (27.7%) 2 stiffness 11 wound healing disturbances	56% at 5 years	None
Our study	m = 6 (2–10)	8/29 (27.6%)	2 dislocations (6.9%) 4 hematomas 3 wound healing disturbances	70% at 10 years	41% of patients died at 10 years

Table 3: Infection-related complications and infection-related indications from the key recently published studies

Reference	Complications Postoperative infection and outcome	Patients with history of infection / entire cohort Outcome
Berend et al. [12]	8/49 (16.3%): - 3 removal-reimplantation (successful) - 1 failure (disarticulation) - 4 NP	14/49 (23.7%): - 1 recurrence (disarticulation) - 13 healed (92.8%)
Frisecke et al. [13]	12/100 (12%) - 2 failures (disarticulation) - 10 healed	33/100 (33%): - 5 recurrences - 28 healed (84.8%)
Fountain et al. [15]	3/14 (21.4%): - 1 good outcome with antibiotics - 2 revision in two phases / healed	12/14 (85.7%) Outcome N/S
Hoell et al. [16]	0/12	5/12 (41.6%): 5 healed (100%)
Clement et al. [17]	2/19 (10.5%): - 1 long-term antibiotics - 1 disarticulation	2/19 (10.5%): 2 failures (postoperative infection)
Amanatullah et al. [18]	7/20: 5 revisions N/S including disarticulation / 1 or 2 stage implant change	10/20 (50%): outcome N/S
Toepfer et al. [19]	8/18 (44.4%): 8 healed (1 without changing implant, 4 partial and 3 complete)	No cases of infection
Our study	8/29 (27.6%): 5 healed / 3 failures (3 long-term antibiotics)	12/29 (41.4%): 3 chronic infections 9 healed (75%)

N/S: not specified

## References

- 1/ Marcove R, Lewis MM, Rosen R, Huvos A. Total femur and total knee replacement. A preliminary report. Clin Orthop Relat Res 1977;126:47-52.
- 2/ Katznelson A, Nerubay J. Total femur replacement in sarcoma of the distal end of the femur. Acta Orthop Scand 1980;51:845-51.
- 3/ Nerubay J, Katznelson A, Tichler T, Rubinstein Z, Morag B, Bubis JJ. Total femoral replacement Clin Orthop Relat Res 1988;229:143-8.
- 4/ Sewell MD1, Spiegelberg BG, Hanna SA, Aston WJ, Bartlett W, et al. Total femoral endoprosthesis replacement following excision of bone tumours. J Bone Joint Surg Br 2009;91:1513-20.
- 5/ Kalra S, Abudu A, Murata H, Grimer RJ, Tillman RM, Carter SR. Total femur replacement: primary procedure for treatment of malignant tumors of the femur. Eur J Surg Oncol 2010; 36:378-83.
- 6/ Sevelde F, Schuh R, Hofstaetter JG, Schinhan M, Windhager R, Funovics PT. Total femur replacement after tumor resection: limb salvage usually achieved but complications and failures are common. Clin Orthop Relat Res 2015;473:2079-87.
- 7/ Buchman J. Total femur and knee joint replacement with a vitallium endoprosthesis. Bull Hosp Joint Dis 1965;26:21-34.
- 8/ Huang G, Cao M. Total replacement of the femur with simultaneous total hip and knee joint endoprostheses with plasma sprayed ceramic coating. Zentralbl Chir 1991;116:199-207.

9/ Ward WG, Dorey F, Eckardt JJ. Total femoral endoprosthetic reconstruction. Clin Orthop Relat Res 1995;316:195-206.

10/ Freedman EL1, Eckardt JJ. A modular endoprosthetic system for tumor and non-tumor reconstruction: preliminary experience. Orthopedics 1997;20:27-36.

11/ McLean A, Patton JT, Moran M. Femoral replacement for salvage of periprosthetic fracture around a total hip replacement. Injury 2012;43:1166-9.

12/ Berend K, Lombardi A, Mallory T, Adams J, Dodds K. Total femoral arthroplasty for salvage of end-stage prosthetic disease. Clin Orthop Relat Res 2004;427:162-70.

13/ Friesecke C1, Plutat J, Block A. Revision arthroplasty with use of a total femur prosthesis. J Bone Joint Surg Am 2005;87:2693-701.

14/ Soenen M, Migaud H, Bonnomet F, Girard J, Mathevon H, Ehlinger M. Interprosthetic femoral fractures: analysis of 14 cases. Proposal for an additional grade in the Vancouver and SoFCOT classifications. Orthop Traumatol Surg Res 2011;97:693-8.

15/ Fountain JR1, Dalby-Ball J, Carroll FA, Stockley I. The use of total femoral arthroplasty as a limb salvage procedure: the Sheffield experience. J Arthroplasty 2007;22:663-9.

16/ Hoell S, Butschek S, Gosheger G, Dedy N, Dieckmann R, et al. Intramedullary and total femur replacement in revision arthroplasty as a last limb-saving option: is there any benefit from the less invasive intramedullary replacement? J Bone Joint Surg Br 2011;93:1545-9.

17/ Clement N, MacDonald D, Ahmed I, Patton J, Howie C. Total femoral replacement for salvage of periprosthetic fractures. Orthopedics 2014;37:789-95.



18/ Amanatullah D, Trousdale R, Hanssen A, Lewallen D, Taunton M. Non-oncologic total femoral arthroplasty: retrospective review. J Arthroplasty 2014;29:2013-5.

19/ Toepfer A, Harasser N, Petzschner I, Pohlig F, Lenze U, et al. Short to long term follow-up total femoral replacement in non-oncologic patients. BMC Musculoskeletal disorders 2016;16:498-507.

20/ ASA Physical Classification System, <http://www.asah-q.org/Home/For-Members/Clinical-Information/ASA-Physical-Status-Classification-System>

21/ Parker MJ, Palmer CR. A new mobility score for predicting mortality after hip fracture J Bone Joint Surg Br 1993;75:797-8.

22/ Philippot R, Adam P, Reckhaus M, Delangle F, Verdout F, Curvale G, Farizon F. Prevention of dislocation in total hip revision surgery using a dual mobility design. Orthop Traumatol Surg Res 2009;95:407-13.

23/ Philippeau JM, Durand JM, Carret JP, Leclercq S, Waast D, Gouin F. Dual mobility design use in preventing total hip replacement dislocation following tumor resection. Orthop Traumatol Surg Res 2010;96:2-8.

24/ Schneider L, Philippot R, Boyer B, Farizon F. Revision total hip arthroplasty using a reconstruction cage device and a cemented dual mobility cup. Orthop Traumatol Surg Res 2011;97:807-13.

25/ Lombardi AV Jr1, Berend KR. The shattered femur: radical solution options. J Arthroplasty. 2006 Jun;21(4 Suppl 1):107-11.

26/ Peters CL1, Hickman JM, Erickson J, Lombardi AV, Berend KR, Mallory TH. Intramedullary total femoral replacement for salvage of the compromised femur associated with hip and knee arthroplasty. J Arthroplasty. 2006 Jan;21(1):53-8.

27/ Mavrogenis AF, Pala E, Angelini A, Calabro T, Romagnoli C, et al. Infected prostheses after lower-extremity bone tumor resection: clinical outcomes of 100 patients. Surg Infect 2015;16:267-75.

28/ Jenny JY, Lengert R, Diesinger Y, Gaudias J, Boeri C, Kempf JF. Routine one-stage exchange for chronic infection after total hip replacement. Int Orthop 2014;38:2477-81.

29/ Massin P, Delory T, Lhotellier L, Pasquier G, Roche O, et al. Infection recurrence factors in one- and two-stage total knee prosthesis exchanges. Knee Surg Sports Traumatol Arthrosc 2016;24:3131-

## Figure legends

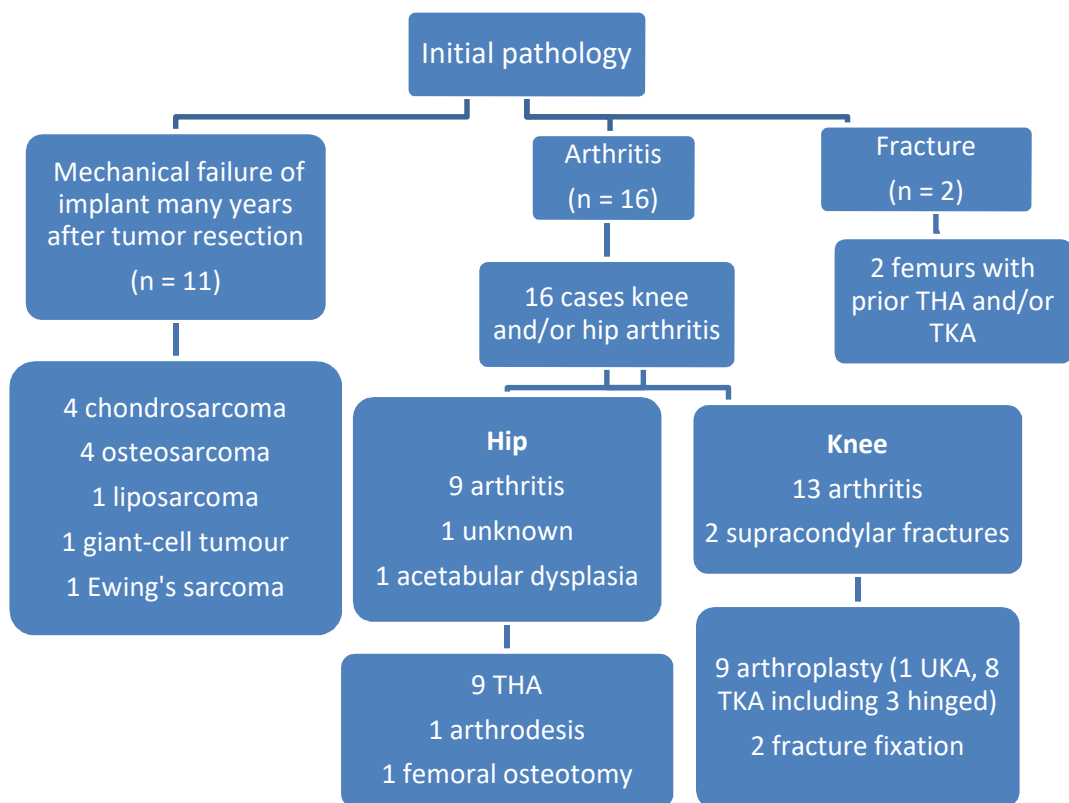
Figure 1: Flow chart showing the initial pathology in the 29 patients who underwent total femur replacement (THA: total hip arthroplasty, TKA: total knee arthroplasty)

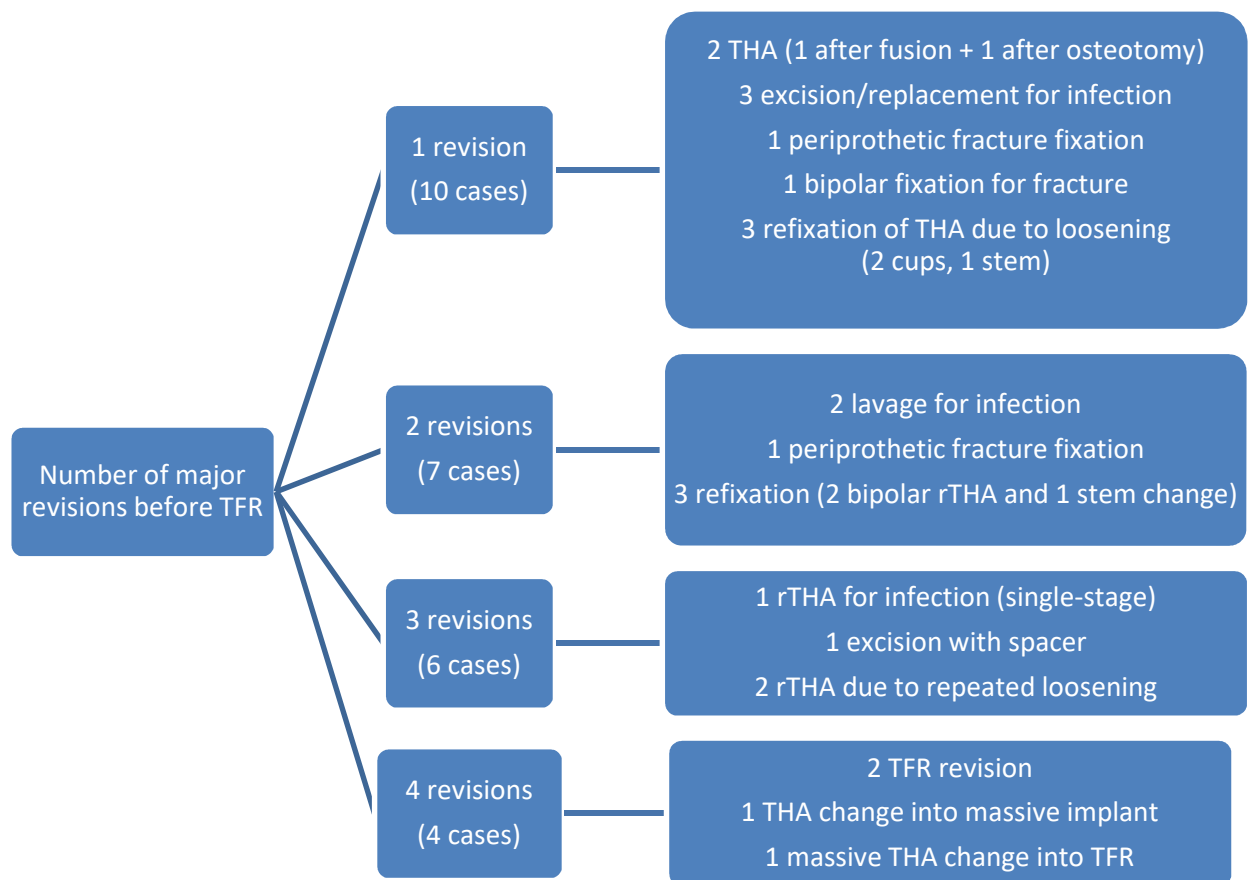
Figure 2: Flow chart showing the types of prior surgery before the total femur replacement (TFR: total femur replacement, THA: total hip arthroplasty, rTHA: revision total hip arthroplasty)

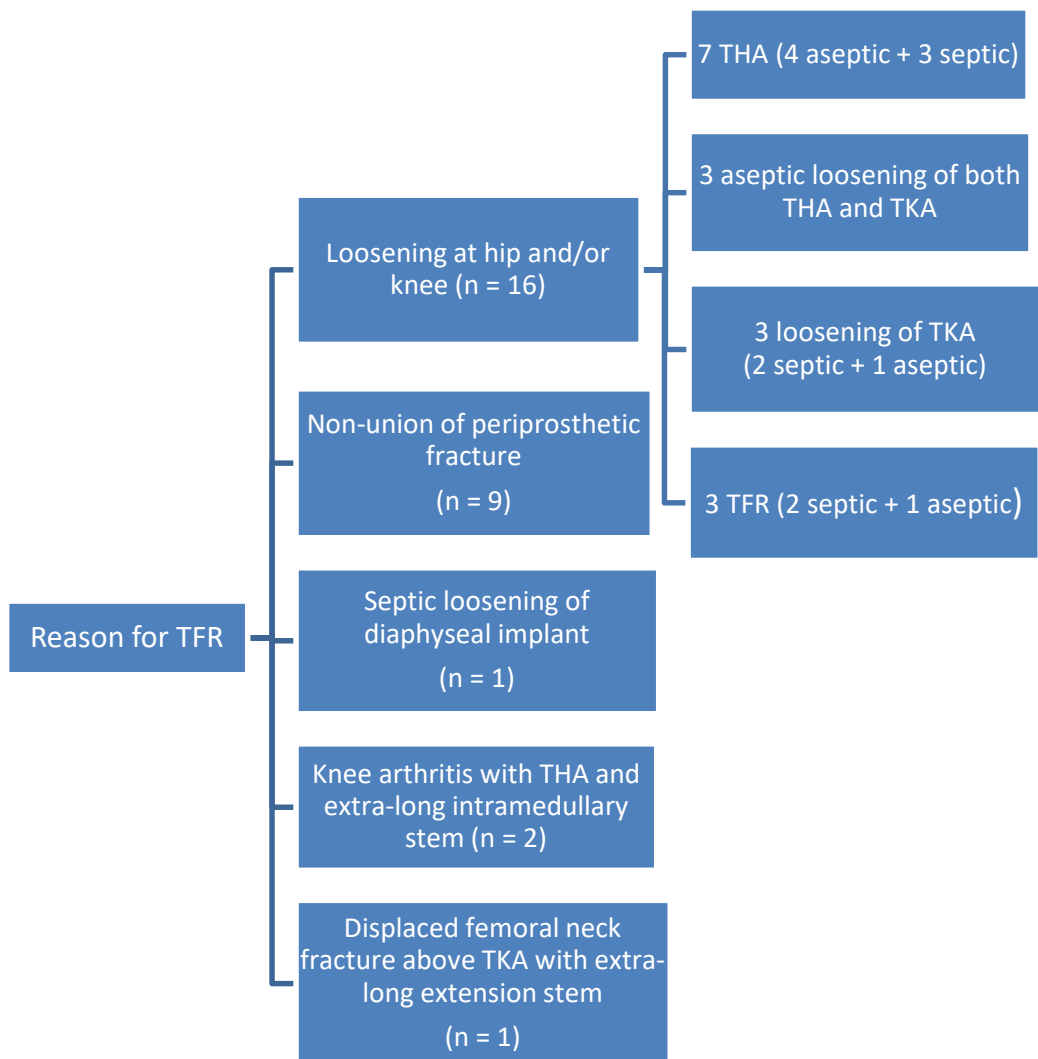
Figure 3: Flow chart showing the reasons for total femur replacement (TFR) (THA: total hip arthroplasty, TKA: total knee arthroplasty)

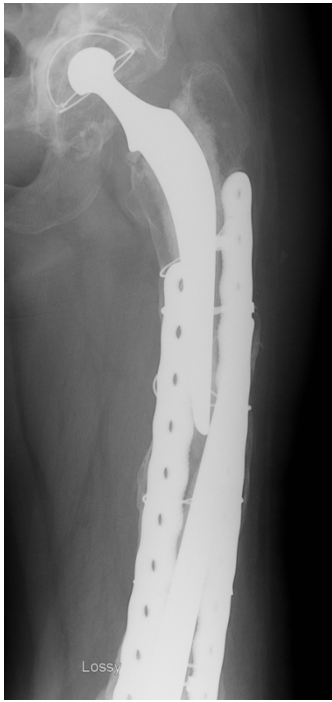
Figure 4: Female 70-year-old patient who uses a walker, bipolar loosening of the TKA (implanted in 1992, loosening in 2000 treated with hinged implant) and THA (implanted in 1985), repeated interprosthetic fracture (4A and 4B). 4C – GMRS implant inserted in 2012. Clinical outcome (2017) – walked with one cane, knee 0/90°, 3 cm leg length difference that was corrected, Parker 7.

Figure 5: Male 47-year-old patient. Distal femur resection in 1990 due to osteosarcoma with reconstruction implant; revised in 2003 (simple cemented femoral revision without reconstruction) then lost to follow-up until 2013 when he consulted because of stiffness (20° flexion deformity / 90° flexion) with significant pain and 4.5 cm shortening. 5A – Modest amount of remaining bone stock combined with the risk of false passage and challenging cement extraction led to a total femur replacement procedure being done (Mutars implant) with a very good outcome at 4 years. 5B – no pain, no limping, walks without cane, 95° knee flexion with 10° flexion deformity, 5 mm leg length difference did not require correction. The trochanters and residual proximal bone were preserved to improve pelvis stability.

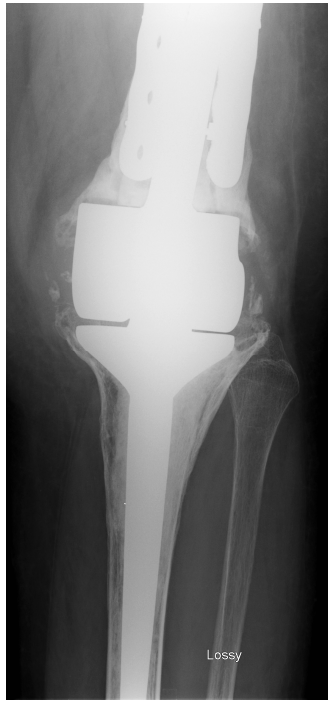




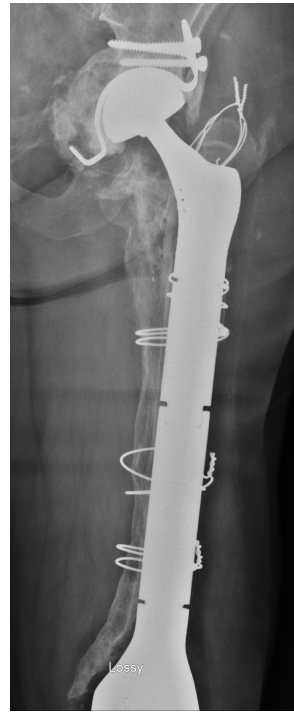


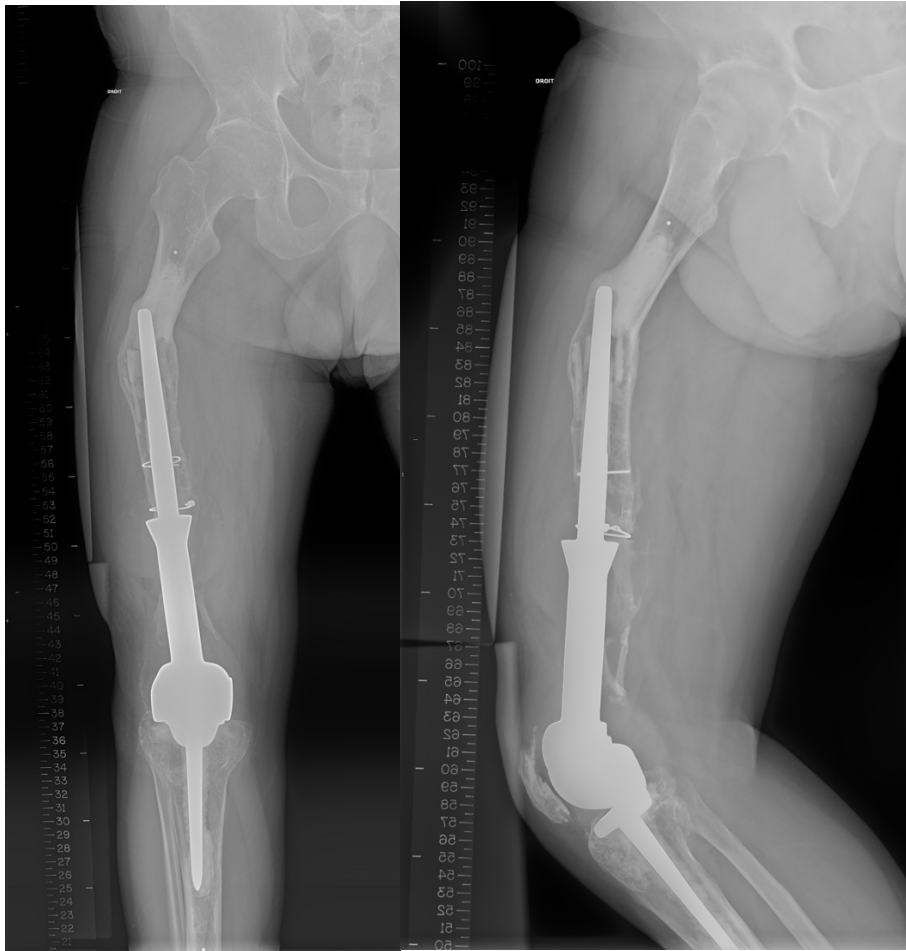
4A



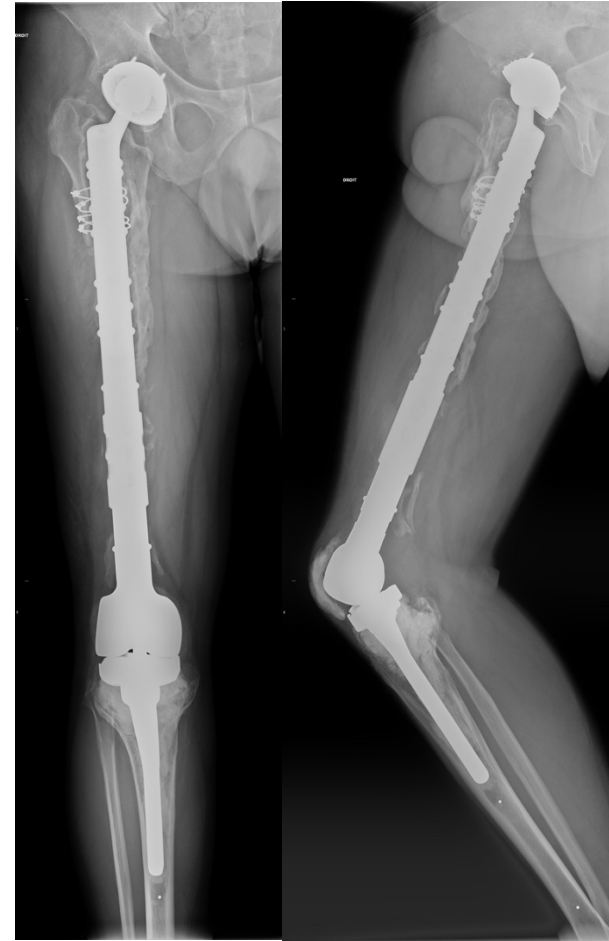4B



4C



5A



5B