



HAL
open science

Smartphone-based Thermal Imaging System for Diabetic Foot Ulcer Assessment

Rania Niri, Yves Lucas, Sylvie Treuillet, Hassan Douzi

► **To cite this version:**

Rania Niri, Yves Lucas, Sylvie Treuillet, Hassan Douzi. Smartphone-based Thermal Imaging System for Diabetic Foot Ulcer Assessment. Journées d'Etude sur la TéléSanté, Sorbonne Universités, May 2019, Paris, France. hal-02161044

HAL Id: hal-02161044

<https://hal.science/hal-02161044>

Submitted on 20 Jun 2019

HAL is a multi-disciplinary open access archive for the deposit and dissemination of scientific research documents, whether they are published or not. The documents may come from teaching and research institutions in France or abroad, or from public or private research centers.

L'archive ouverte pluridisciplinaire **HAL**, est destinée au dépôt et à la diffusion de documents scientifiques de niveau recherche, publiés ou non, émanant des établissements d'enseignement et de recherche français ou étrangers, des laboratoires publics ou privés.

Smartphone-based Thermal Imaging System for Diabetic Foot Ulcer Assessment

Niri R.¹, Lucas Y.², Treuillet S.² and Douzi H.¹

¹Ibn Zohr University, Laboratory IRF-SIC, Agadir, Morocco

²Orléans University, Laboratory PRISME, Orléans, France
nirirania@gmail.com

Abstract - This research work is part of the *STANDUP* project <http://www.standupproject.eu/> dedicated to improve diabetic foot ulcer prevention and treatment of the plantar foot surface using smartphone-embedded thermal imaging system. The aim of this preliminary work is to build an ulcer assessment tool based on a smartphone and an IR thermal camera. The proposed system represents a practical tool for accurate DFU healing assessment, combining color and thermal information in a single user-friendly system. To ensure robust tissue identification, an annotation software was developed based on SLIC superpixel segmentation algorithm. The tool thus developed allows clinicians to achieve objective and accurate tissue identification and annotation.

The proposed system could serve as an intelligent telemedicine system to be deployed by clinicians at hospitals and healthcare centers for more accurate diagnosis of diabetic foot ulcers.

Keywords: Diabetic Foot Ulcer (DFU), biomedical images, mobile health, thermal imaging, SLIC superpixel.

I. INTRODUCTION

A majority of people affected by Diabetes are prone to having foot problems. Foot ulceration is the most frequently recognized complication of diabetes, affecting up to 50% of patients with both type 1 and 2 diabetes [1]. Diabetic foot (DF) disease includes neuropathy, peripheral arterial disease and infection which may lead to ulceration and subsequent lower limb amputation. Every 30 seconds a lower limb or part of a lower limb is lost to amputation somewhere in the world as a consequence of diabetes [2]. Associated costs in terms of quality of life and health as well as sociable care expenditures are expected to strongly rise in DF if no measures are taken. To avoid such complication, it is essential that these ulcers be monitored and treated adequately at an early stage.

However, diabetic foot ulcer (DFU) assessment require frequent clinical visits to diagnose the ulcer healing status by health professionals which is very costly and time consuming for patients. The clinical assessment of DFUs represents a critical task to perform an accurate diagnosis and to select a suitable treatment [3]. The wound assessment process is based on visual examination, clinicians describe the ulcer by its physical dimensions (area and volume) and the nature of the different skin tissue types inside the wound bed such as granulation, slough, and necrotic ones [4]. Assessing color and proportion of these tissues help to determine the healing

progress of the ulcer and to provide quantitative measurement without contact. During visual DFU assessment, the healing status is based on red-yellow-black color evaluation model corresponding respectively to the dominant color of the different tissues found within the ulcer boundaries: granulation, slough and necrosis (Fig. 1).

However, during wound tissue identification, experts have a problem of determining exactly the proportion of each tissue within DFU area due to many factors (their clinical experience, color inexactness, etc.) [5]. So, the clinical follow-up of DFU healing and tissue identification over the ulcer region are entirely subjective.

Nowadays, medical imaging technologies has been widely used in clinical practice for diabetic foot ulcers diagnosis and tissue analysis. However, most of these technologies are expensive, non-portable and require an expert knowledge. Considering the low-cost and the prevalence of smartphones, DFUs management using a smartphone-based system became an attractive option.

In recent years, thermal imaging [6] has been used for DFUs detection, it has the advantage of providing information about temperature variations underlying the skin surface [7]. Previous studies using infrared thermal imaging help to identify possible ulcerous regions, a difference of temperature of 2.2°C between left and right feet corresponding sites is considered as sign of abnormality in skin circulation and can prevent diabetic foot ulcers [8]. IR thermography can also be used after foot ulceration not only to detect temperature changes due to inflammation or infection but also to detect type of the ulcer. The neuroischaemic ulcer tends to be cold, but at the contrary, the neuropathic one tends to be warm [9,10]. Hence, combining these two modalities will allow clinicians to get more information about ulcer health for a better DFU assessment. In this work, we have proposed a smartphone-based thermal imaging system that can be used by clinicians to detect foot ulceration or to predict the healing status of DFUs for more accurate and qualitative assessment.

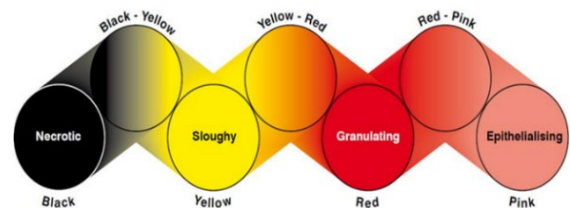


Figure 1: Wound Healing Continuum (Gray et al. 2005)

II. IMAGE MODALITIES AND MATERIALS

In current clinical practices, visual assessment of DFUs is based on wound tissue analysis. These wounds generally have a mixture of yellow slough, red granulation tissue and black necrotic tissue. Determining the proportions of each tissue represent an important factor to predict the healing status of the ulcer [11]. This process depends on the medical expert, so, does not produce objective measurements of the healing status of the wound [12].

With the spreading of low-cost digital cameras, imaging technology started to upgrade DFU assessment with the capture of color pictures of the ulcers. These photographs are objective and allow clinicians to diagnose and evaluate the ulcers. Nowadays, smartphones became a viable candidate for image capture and replaced digital cameras. These low-cost devices contain a high-resolution camera and are very familiar for experts and patients. Colour images can be used to analyze different ulcer tissues and also to calculate areas occupied by these tissues more accurately. This image modality could be of great aid to health-care professionals in the assessment of the healing of DFUs.



Figure 2: Flir One Pro camera

IR thermography is a real-time temperature measurement detecting thermal changes. Thermal imaging cameras are very powerful for several industrial applications. In the recent past years, their price has been dramatically reduced while the technical progress strongly increased. Today, IR cameras are considered as non-invasive tools to detect the variation of temperature on the human skin surface and they are increasingly used for monitoring and diagnosing diabetic foot disorders.

FLIR offers low cost IR cameras with a very high quality. The Flir One Pro CAMERA [13] can easily be plugged into a smartphone and have the advantage of combining thermal and optical imaging. This camera offers high thermal image resolution of 19,200 pixels. Maximum temperature measurements are up to 400°C (752°F) and the sensitivity detects temperature differences down to 70 mK which means the deepest skin detection is highly possible in biomedical applications. Fig. 2 shows the Fir One Pro camera and Table 1 presents an overview of its main features. The use of Flir One camera requires an application which is available on Google play and App store for free.

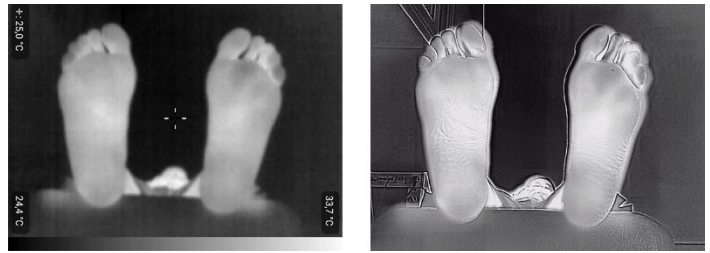


Figure 3: Example of plantar feet surface image taken with a Flir One Pro camera. Thermal mode (a), MSX mode (b).

The proposed system will be composed of a Smartphone equipped with a Flir One Pro camera, to take, at the same time color and thermal image. To combine the thermal image with the visual camera, Flir One uses its MSX image processing mode to analyze the contours of objects for more detailed view. Using this mode, the visual camera displays contours as transparent lines over the thermal image to maximize details and image sharpness (Fig. 3).

TABLE 1: FLIR ONE PRO OVERVIEW

<i>Resolution</i>	1440 × 1080 pixels
<i>Scene Dynamic Range</i>	-20°C to +400°C (-4°F to +752°F)
<i>Thermal sensitivity</i>	70 mK
<i>Accuracy</i>	±3°C or ±5%
<i>Weight</i>	36.5 g
<i>Dimensions (H x W x D)</i>	68 × 34 × 14 mm

III. METHODOLOGY

A. Image Acquisition

The acquisition system is composed of a smartphone and an IR thermal camera Flir One Pro to take thermal and color images at the same time. Images will be acquired by clinical staff during clinical examination of DFUs. Hence, the images were not acquired using a very strict protocol, which represent a big challenge especially for thermal images acquisition. The temperature may be influenced by many factors such as weather conditions, room lighting, etc.

Cajacuri et al. [14] used an infrared device namely FLIR I5 IR camera to obtain thermal images of diabetic foot plantar surface. All images are taken using a strict acquisition protocol. Room temperature should be maintained between 18 and 23 °C and temperature should not vary more than 1°C during the acquisition. IR camera was positioned 1.1 m away from the feet and all windows must be covered to prevent outside infrared radiation.

However, in our case, images are acquired from the regular clinical work environment. Hence, a preliminary requirement is to take the images in a controlled environment where the temperature is set to room temperature. The use of flash as the primary light source is avoided, adequate room lights are used instead to get the consistent colors in images. The images should be acquired with close-ups of the full foot and with the parallel orientation to the plane of an ulcer [15].

B. DFU Segmentation and Expert Labelling

During wound tissue identification, clinicians have a problem of determining manually proportion of the different tissues within ulcer region due to many factors (their clinical experience, color inexactness, etc.) [16]. So, tissue classification over the DFU region is a very complex task for clinicians. As solution, we developed a labelling software based on an image segmentation algorithm that can allow clinicians to directly label pre-segmented ulcer regions. Hence, this process will become easier, more accurate and less time consuming.

There are many segmentation algorithms, and recently superpixel algorithms have become widely used in computer vision applications specially in medical imaging. They showed the ability to provide powerful segmentation results with high efficiency, especially in real-time vision systems.

The images were segmented with Simple Linear Iterative Clustering algorithm (SLIC) [17]. SLIC is the state-of-the-art superpixel segmentation algorithm which doesn't require much computational power. The algorithm is based on the concept of a local k-means clustering that finds clusters of pixels based on their color similarity in the combined five-dimensional color space $[l, a, b, x, y]$ and proximity in the image plane. This algorithm is semi-automatic, as it is necessary to define number of superpixels. The advantage of SLIC is that the only input parameter is the number of superpixels k . Hence, clinicians can control the number of desired segmented regions according to the complexity and the size of the ulcer by increasing or decreasing k . A hidden parameter m is used to control the compactness of superpixels. Authors of the algorithm have chosen $m=10$ [18], this value offers a good balance between color similarity and spatial proximity [19].

In order to assess quantitatively the quality of superpixels generated by SLIC, we have used popular benchmark measurements such as Dice Similarity coefficient [20] and computation time. The Dice similarity coefficient (DSC), also called the overlap index, is the most used metric in validating medical image segmentations [21]. The DSC value quantifies the region overlap between the automatic and the ground truth labelling, and is defined as:

$$DSC = 2 \frac{|A_A \cap A_G|}{|A_A| + |A_G|} = \frac{2TP}{2TP + FP + FN}$$

where A_G and A_A indicate the region of ground truth of the foreground and the region of segmentation of the foreground by the proposed algorithm, respectively.

TABLE 2 : SEGMENTATION EVALUATION RESULTS USING DSC

	<i>SLIC</i>	<i>WATERSHED</i>
<i>DSC (%)</i>	98.25	97.95

SLIC is benchmarked against the Compact Watershed (WS) method [22]. It is a very fast algorithm based on Seeded

Watershed segmentation. This algorithm has been used in several applications to produce low-level segmentations. Both methods have been tested on 26 wound images of sizes 2048×1536 pixels after colorimetric correction. As segmentation ground truth, each image has been manually segmented by medical expert.

Results for DSC using different number of superpixels for both SLIC and Watershed are shown in Table 2. SLIC resulted in the highest Dice similarity coefficient. We compute the runtime of the two algorithms on a personal computer based on Intel Core i7 2.60 GHz processor with 16GB RAM. (Fig. 4) shows the curves of runtime versus the number of superpixels for these two methods. As we can notice, the Compact Watershed algorithm is a little faster than SLIC.

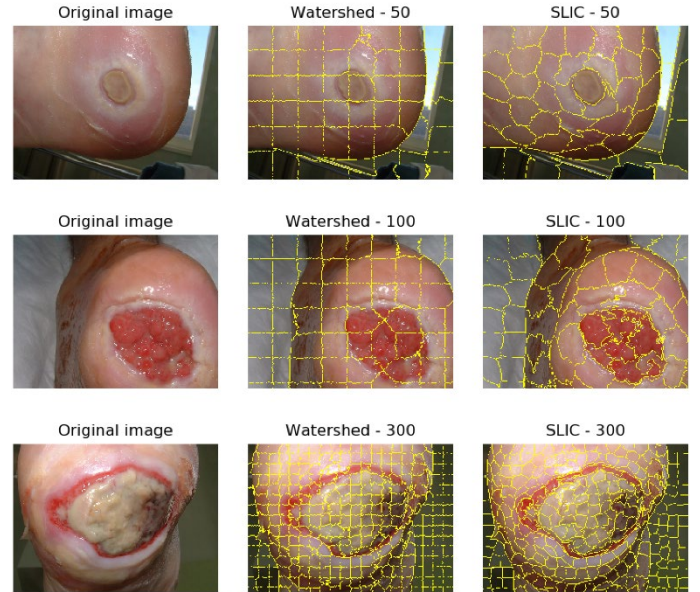


Figure 4 : Superpixel Segmentation Comparison

Moreover, good segmentation is when we have a compromise between segmentation quality and runtime. So, we tried to find a fast superpixel segmentation algorithm that provides the perfect segments. To compare the segmentation quality, we tested the two algorithms on same wound images with the same number of generated superpixels. As shown in (Fig. 6), SLIC adheres very well to wound boundaries compared to WS. Based on the evaluated results presented above, certainly WS is the fastest algorithm but the segmentation quality is not the best. SLIC produce more regular and compact superpixels with good adherence to wound boundaries while maintaining high computational efficiency. Hence, the superpixel method SLIC could be used for fast and accurate wound segmentation in real-time.

Once the segmentation is done, clinicians can easily annotate the pre-segmented regions of the ulcer (Fig. 6). They can also control the number of the segmented region by increasing the number of superpixels according to the size and the complexity of the ulcer. Each region should contain at most one type of tissue. This software is very simple to use, medical experts can

directly label the different tissues within the ulcer area through simple mouse clicks, by selecting corresponding color for each pre-segmented region of the DFU.

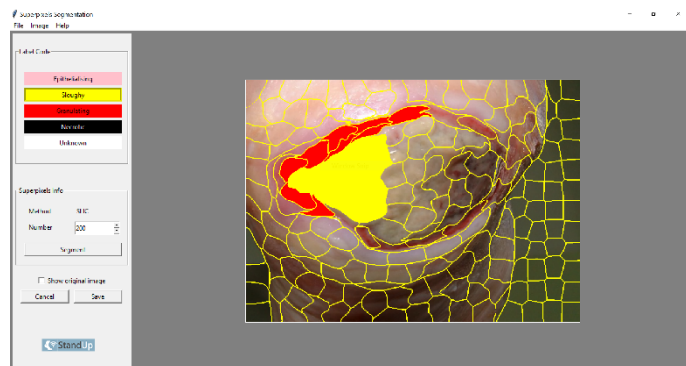


Figure 5: Graphical interface for the expert manual labeling.

IV. Conclusion and Perspectives

In this preliminary study, we propose a low cost and easy-to-use system that will help clinicians to manage diabetic foot ulcers for patients with diabetes. This system will be composed of a smartphone and a Flir One Pro IR camera, in order to combine tissue and temperature information for more qualitative and accurate DFU assessment. In addition, a DFUs labelling software was developed, which will allow the health professionals to easily identify and annotate each tissue inside the wound bed. This study still has to be completed to obtain an automatic and accurate classification of DFU tissues using image analysis algorithms.

Various Machine learning models were created to perform wound tissue classification. A crucial step in the traditional ML workflow is the extraction of discriminant features from the images. This process is still done by human. On the other hand, deep neural networks do not require manual feature engineering. Instead, it learns on its own by processing and learning the high-level features from raw data.

So, as future work, we plan to develop a new image processing algorithm for tissue classification based on Deep Learning approach by applying convolutional neural networks to multispectral (colour and thermal) DFU images in order to improve diabetic foot ulcer monitoring over time. Combining these two image modalities will allow clinicians to get at the same time tissue and temperature information of the ulcer. DFU assessment should become more accurate and robust, diagnosis and therapeutic decisions could be assisted by clinicians and finally DFU healing should benefit of these works.

Furthermore, Deep networks require to collect massive amount of color and thermal DFU images as classification accuracy of deep learning classifier is largely dependent on the quality and size of the dataset. The database should be annotated by medical experts, which is difficult and costly. The proposed

labeling software will be used for DFU images annotation to help clinicians in the labeling process. Further, testing and validation of the system should be performed during clinical trials in hospitals. The STANDUP project plans collaborations with several hospitals in France and Peru to collect medical databases and realize clinical trials with patients to evaluate diabetic ulcer monitoring.

ACKNOWLEDGMENT

This research program is supported by internal funding sources of PRISME laboratory, Orleans, France and from the European Union's Horizon 2020 under the Marie Sklodowska-Curie grant agreement No 777661.

REFERENCES

- [1] Didac Mauricio, Edward Jude, Alberto Piaggese and Robert Frykberg, "Diabetic Foot: Current Status and Future Prospects", Journal of Diabetes Research Volume 2016, Article ID 5691305, 2 pages.
- [2] <https://www.idf.org/aboutdiabetes/what-is-diabetes/complications.html>
- [3] Leslie Casas, Castaneda Benjamin and Sylvie Treuillet, "Imaging technologies applied to chronic wounds: a survey", ISABEL 2011, 4th International Symposium on Applied Sciences in Biomedical and Communication Technologies, Oct 2011, Barcelona, Spain. p1-5.
- [4] Hazem Wannous, Yves Lucas and Sylvie Treuillet, "Combined Machine Learning with Multi-view Modeling for Robust Wound Tissue Assessment", VISAPP 2010, Fifth International Conference on Computer Vision Theory and Applications, May 2010, Angers, France. 1, pp.92-104, 2010.
- [5] Samsunnisha Pate, Rachna Patel and Dhara Desai, "Diabetic Foot Ulcer Wound Tissue Detection and Classification", International Conference on Innovations in information Embedded and Communication Systems (ICIIECS), 2017.
- [6] Bharara M, Cobb JE, Claremont DJ. Thermography and thermometry in the assessment of diabetic neuropathic foot: a case for furthering the role of thermal techniques. Int J Low Extrem Wounds. 2006;5:250-260.
- [7] Marek Chojnowski, "Infrared thermal imaging in connective tissue diseases", Reumatologia 2017;55:38-43.
- [8] Armstrong DG, Holtz-Neiderer K, Wendel C, Mohler MJ, Kimbriel HR, Lavery LA., "Skin temperature monitoring reduces the risk for diabetic foot ulceration in high-risk patients", Am J Med. 2007;120(12):1042-6.
- [9] R. Davern, M. Hatunic, "An Overview of the Management of Diabetic Foot Ulcers", <http://imj.ie/an-overview-of-the-management-of-diabetic-foot-ulcers/>, Irish Medical Journal.
- [10] https://www.coloplast.us/Global/US/Wound%20Care/Diabetic%20Foot%20Ulcers%20Quickguide_M4007N.pdf
- [11] William Paul Berriss, Stephen John Sangwine, "Automatic Quantitative Analysis of Healing Skin Wounds using Colour Digital Image Processing", World Wide Wounds, Edition 1.1,1997.
- [12] H. Wannous, Y. Lucas, S. Treuillet, B. Albouy, "A complete 3D wound assessment tool for accurate tissue classification and measurement," IEEE 15th Conf. on Image Processing, pp. 2928-2931, Oct. 2008.
- [13] <https://www.flir.com/products/flir-one-pro/>

- [14] Cajacuri L., "Early diagnostic of diabetic foot using thermal images", Université d'Orléans, 2014, <https://tel.archives-ouvertes.fr/tel-01022921/document>. Accessed 11 Jul 2014.
- [15] M. H. Yap, K. E. Chatwin, C.-C. Ng, C. A. Abbott, F. L. Bowling, S. Rajbhandari, A. J. Boulton, and N. D. Reeves, "A new mobile application for standardizing diabetic foot images", *Journal of diabetes science and technology*, vol. 12, no. 1, pp. 169–173, 2018.
- [16] Samsunnisha Pate, Rachna Patel and Dhara Desai, "Diabetic Foot Ulcer Wound Tissue Detection and Classification", *International Conference on Innovations in information Embedded and Communication Systems (ICIECS)*, 2017.
- [17] Radhakrishna Achanta, Appu Shaji, Kevin Smith, Aurelien Lucchi, Pascal Fua, and Sabine Süsstrunk, "SLIC superpixels compared to state-of-the-art superpixel methods". *IEEE Transactions on Pattern Analysis and Machine Intelligence (TPAMI)* 34(11), 2274–2282, 2012.
- [18] <https://jayrambhia.com/blog/superpixels-slic>
- [19] Radhakrishna Achanta, Appu Shaji, Kevin Smith, Aurelien Lucchi, Pascal Fua, and Sabine Süsstrunk, "SLIC Superpixels", *EPFL Technical Report 149300*, June 2010.
- [20] Lee R. Dice, "Measures of the amount of ecologic association between species", *Ecology*, Vol. 26, No. 3 (Jul., 1945), pp. 297-302.
- [21] Abdel Aziz Taha and Allan Hanbury, "Metrics for evaluating 3D medical image segmentation: analysis, selection, and tool", *BMC Medical Imaging*, 2015.
- [22] Peer Neubert and Peter Protzel, "Compact Watershed and Preemptive SLIC: On improving trade-offs of superpixel segmentation algorithms", *22nd International Conference on Pattern Recognition*, 2014.