



HAL
open science

Anterior cervical spine surgical site infection and pharyngoesophageal perforation. Ten-year incidence in 1475 patients

Régis Gamain, Rémy Coulomb, Karim Houzir, Nicolas Molinari, Pascal Kouyoumdjian, Nicolas Lonjon

► To cite this version:

Régis Gamain, Rémy Coulomb, Karim Houzir, Nicolas Molinari, Pascal Kouyoumdjian, et al.. Anterior cervical spine surgical site infection and pharyngoesophageal perforation. Ten-year incidence in 1475 patients. *Orthopaedics & Traumatology: Surgery & Research*, 2019, 105 (4), pp.697-702. 10.1016/j.otsr.2019.02.018 . hal-02143278

HAL Id: hal-02143278

<https://hal.science/hal-02143278v1>

Submitted on 29 May 2019

HAL is a multi-disciplinary open access archive for the deposit and dissemination of scientific research documents, whether they are published or not. The documents may come from teaching and research institutions in France or abroad, or from public or private research centers.

L'archive ouverte pluridisciplinaire **HAL**, est destinée au dépôt et à la diffusion de documents scientifiques de niveau recherche, publiés ou non, émanant des établissements d'enseignement et de recherche français ou étrangers, des laboratoires publics ou privés.

Anterior cervical spine surgical site infection and pharyngoesophageal perforation. Ten-year incidence in 1475 patients

Régis Gamain^{a,*}, Rémy Coulomb^a, Karim Houzir^b, Nicolas Molinari^c,
Pascal Kouyoumdjian^a, Nicolas Lonjon^d

^a CHU Caremeau, place du Pr-Debré, 30029 Nîmes cedex 9, France

^b Clinique Via Domitia, 1, rue des Alicantes, 34400 Lunel, France

^c CHU Montpellier DIM, allée Charpentier, 34090 Montpellier, France

^d CHU Montpellier – Gui-de-Chauliac, 80, avenue Augustin-Fliche, 34090 Montpellier, France

ABSTRACT

Background: Surgical site infection is reputed to be infrequent in anterior cervical spine surgery. Data on pathophysiological mechanism and risk factors are sparse. The relationship between local site infection and pharyngoesophageal perforation is unclear. The present study aimed: (1) to estimate the incidence of surgical site infection in anterior cervical spine surgery, (2) estimate the incidence of associated pharyngoesophageal perforation, and (3) suggest a decision-tree for early management of this two-fold issue.

Hypothesis: Although with very low incidence, anterior cervical spine surgical site infection and pharyngoesophageal perforation are frequently associated.

Material and methods: A 2-center retrospective study included all anterior cervical spine surgeries between January 1, 2007 and December 31, 2016. Data were provided by the two medical information departments. Patients undergoing anterior revision surgery on the cervical spine were included. Files were analyzed to determine whether the revision surgery was secondary to surgical site infection. **Results:** In total, 1475 patients with anterior cervical spine surgery were identified: 1180 in center A (80%) and 295 in center B (20%). The rate of revision surgery for surgical site infection was 0.34% (5/1475). There were 3 cases of pharyngoesophageal perforation (0.2%).

Discussion: The incidence of revision surgery for anterior cervical spine surgical site infection was comparable to rates in the international literature (0.07–1.6%). An association between surgical site infection and pharyngoesophageal perforation was frequent, but not statistically significant. This complication is extremely serious, requiring urgent multidisciplinary management.

Level of evidence: IV, retrospective study.

Keywords:

Surgical site infection

Cervical spine

Anterior surgery

Pharyngoesophageal perforation

Retrospective study

Incidence

1. Introduction

There are numerous indications for cervical spine surgery on an anterior approach. It enables decompression and stabilization. The main pathologies concerned are degenerative, traumatic or tumoral. Postoperative course is often uncomplicated [1]. The main complication encountered is dysphagia, resolving spontaneously, with incidence ranging between 26.9% and 88.8% depending on the report and criteria [2–4]. Epidemiological data for surgery site

infection are sparse compared to those for the thoracolumbar spine [5], but it is reputed to be infrequent.

Revision rates for anterior cervical spine surgical site infection are low, but it is nevertheless a diagnostic and therapeutic challenge in which surgical revision is common. It is sometimes related to or associated with another severe iatrogenic complication: pharyngoesophageal perforation. The link between the two is not known.

The main objective of the present study was to estimate the incidence of surgical revision for septic complications following anterior cervical spine surgery. Secondary objectives were to estimate the incidence of iatrogenic pharyngoesophageal perforation in anterior cervical discectomy and fusion (ACDF) surgery, and to draw up a decision-tree for early treatment.

* Corresponding author. Service de chirurgie orthopédique et traumatologique, place du Pr-Debré, 30029 Nîmes cedex 9, France.

E-mail address: regis.gamain@gmail.com (R. Gamain).

2. Patients and methods

2.1. Description of study

A retrospective study was conducted in two university hospital centers (A and B) approved for surgical treatment of spinal trauma. Patients with surgery site infection in the cervical segment operated on by an anterior approach over a 10-year period were included, and epidemiological, clinical and radiologic characteristics were analyzed.

2.2. Data collection

All anterior surgeries on cervical vertebrae in levels C2 to C7 performed between January 1, 2007 and December 31, 2016 were included. Patient lists were provided by the two medical information department databases.

The following codes of the French CCAM medical acts classification were retrieved for primary surgeries: LDFA 002, LDFA 006, LDFA 007, LDFA 008, LDFA 009, LDFA 0011, LDCA 004, LDCA 011, LDCA 013, LDKA 900, LDPA007, and LDPA008 (see [Appendix](#)). Patients were included and analyzed if they had cervical spine revision surgery with one of the above and/or one of the following codes: LDGA 001, LDGA 002, LDHA 002, LHHH 001, LHHH 002, LHHH 003, QAJA 003 (see [Appendix](#)). Surgical site infection was defined as clinical or documented infection with onset within the first year of primary surgery. Patient files were screened for cervical surgery site infection based on:

- French national health insurance procedure codes;
- radiographs;
- bacteriologic and pathologic findings;
- operative reports;
- and medical observations at admission and consultation.

Patients with surgical revision for infection in the cervical level treated by the index surgery, with onset within 1 year postoperatively, were included. Clinical history was examined, recording time to onset of septic symptoms, type of bacterium, diagnostic method, and treatment.

2.3. Statistics

Descriptive statistical analysis used Excel software (Microsoft®).

3. Results

3.1. Population

There were 1475 patients receiving cervical surgery on an anterior approach: 1180 (80%) in center A and 295 (20%) in center B. Fifty-four patients in center A (4.6%) and 19 (6.4%) in center B underwent anterior cervical revision surgery: i.e., 4.9% overall.

Analysis of files retrieved 4 patients (0.34%; mean age, 64.3 years; 75% male) with revision for sepsis in center A, and only 1 (0.34%; age, 45 years; male) in center B ([Fig. 1](#)). There was no significant difference between centers for surgical site infection rates.

Cumulative incidence of sepsis in the anterior approach to the cervical spine was 0.34% ($n=5$) for the two centers over a 10-year period. Mean age at revision was 60.4 years (range: 43–80 years). Four of the patients were smokers (4/5). Two were trauma victims, with Subaxial Cervical Spine Injury (SLIC) score of 7 [6]; 2 had degenerative discopathy; and 1 underwent plate removal and bacteriological sampling during cancer surgery. In 3 cases, the interbody level involved was C5C6. Pharyngoesophageal perforation was found in 3 of the 5 cases of surgical revision for surgical site infection: $n=3/1475$; 0.2% of operated patients; no intraoperative complications, however, were recorded in the surgical reports.

3.2. Case details and treatments

[Table 1](#) details the main clinical features of the 5 cases of surgical site infection. [Fig. 2](#) shows a sagittal CT slice through the initial lesion in case No. 1.

Two of the 3 patients with perforation were cured, although 1 showed mild recurrent nerve palsy; the third died from progressive neoplasia after multiple suture attempts. Diagnosis of these 3 perforations was late, at a mean 35 days (range: 11–57 days) after primary surgery, partially explaining failure of the first pharyngoesophageal suture ([Fig. 3](#)).

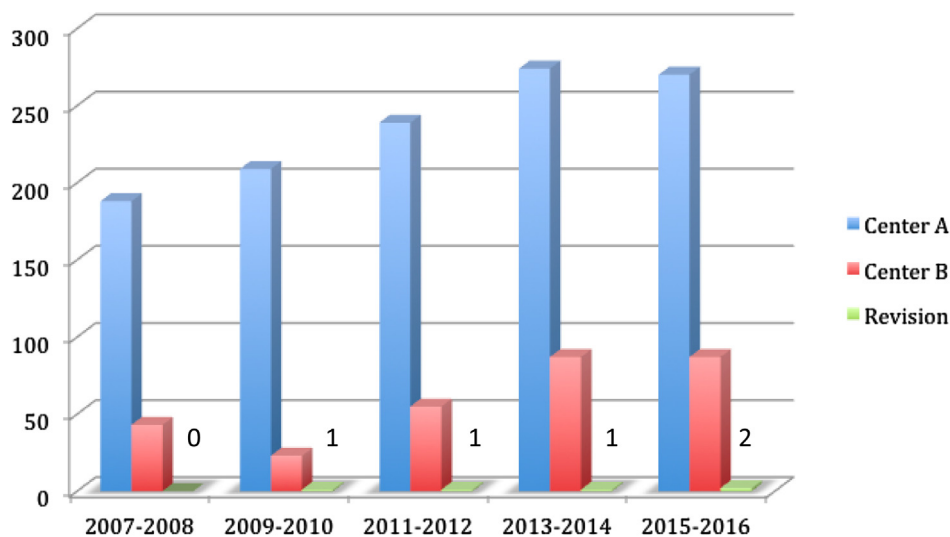


Fig. 1. Surgical spine procedures per center and overall revision procedures, 2007–2016.

Table 1
Clinical data.

Case	Epidemiology					Lesion		Primary procedure				Revision for SSI				
	Age (yrs)	Gender	ASA	Smoking (P-yr)	BMI (kg/m ²)	Type	Level	SLIC	Time (min)	Altmeier classification	Blood loss (mL)	Interval after primary surgery (days)	Isolate	PEP	Number of revisions	Died
1	43	F	1	18	19.1	Dislocation	C2C3	7	168	1	<100	27	Flore orale	+	2	-
2	80	M	2	-	26.5	Fracture	C4C5	7	110	1	<50	11	SA+EB	-	1	-
3	45	M	1	15	26.6	Fracture	C5C6	7	105	1	<50	57	SA	+	3	-
4	66	M	1	25	25.1	CBN	C4	-	130	1	<100	10	SA	-	1	-
5	68	M	3	40	20.3	OSMA	C5C6	-	85	1	<50	17	PA	+	6	+

SSI: surgery site infection; M: male; F: female; ASA: American Society of Anesthesiologists score; P-yr: pack-years; BMI: body-mass index; CBN: cervicobrachial neuralgia; OSMA: osteosynthesis material ablation; SLIC: subaxial cervical spine injury classification; SA: *Staphylococcus aureus*; EB: *Enterobacter baumannii*; PA: *Pseudomonas aeruginosa*; PEP: pharyngoesophageal perforation.

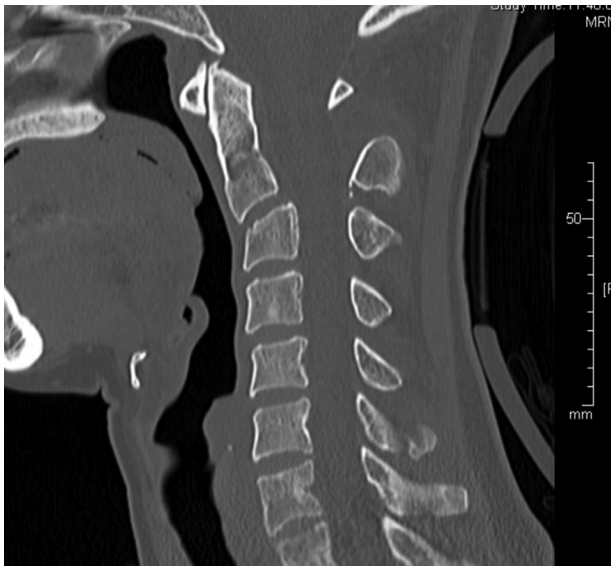


Fig. 2. Sagittal CT slice of C2–C3 subluxation on Effendi type II fracture in case 1.

4. Discussion

The present retrospective series confirmed that revision rates for surgical site infection following anterior spinal surgery are very low.

4.1. Comparison with the literature

The revision rate for surgical site infection following anterior spinal surgery in the present series was 0.34%, comparable to international reports of rates between 0.07% and 1.6% [7–9].

Ghobrial et al. [9], in a retrospective series, reported 6 septic complications in 8887 cases in 21 US centers, for a mean septic complication rate of 0.07% (range: 0–0.39%). Fountas et al. [7], in a retrospective series of 1015 patients, reported a single early abscess (0.15%), as did Bertalanffy and Eggert [10] in a series of 450 patients (i.e., 0.2%). In 2011, Christiano and Goldstein [8] reported rates of 0.1% to 1.6% in ACDF.

4.2. Risk factors

Low sample sizes in international reports as well as the present series prevent identification of significant risk factors. In the present series of 5, the male/female sex ratio was 4:1, and mean age was 60.4 years (range: 43–80 years). There were 4 active smokers (4/5). There were 3 esophageal fistulae, 2 with traumatic etiology

and 1 in a context of head and neck neoplasia. The level involved was C5C6 in 2 cases, but no significant correlation could be shown. Risk could seem to be greater at C5C6, where the posterior side of the esophagus is thin and more vulnerable, with the hypopharynx projecting toward the C5 body and the mouth of the esophagus at C6 level.

4.3. Treatment of surgical site infection

According to the literature, cervical surgery site infection has no specific pathognomic signs, although pain is the most frequent [11], with onset during the first postoperative weeks [7,12–14]. When the patient is stable, MRI or contrast-enhanced CT should be used to screen for deep effusion [15]. Timely revision surgery enables bacteriological diagnosis and targeted antibiotic therapy, reducing the risk of abscess and neurologic complications. Debridement and drainage seems to be the usual attitude. Antibiotic therapy is administered for 6 to 12 weeks, depending on the isolate or isolates [16]. Instrumentation may be retained, replaced by autologous tricortical graft with anterior plate in early (<1 month) infection, or removed in late infection with acquired fusion [17–20].

4.4. Particular case of early pharyngoesophageal or pharyngeal perforation (Fig. 4)

Esophageal perforation is a potentially serious complication, with mortality up to 20% [21]. Incidence in anterior surgical spine surgery is 0.25–1.49% [22,23]. It is iatrogenic in at least 70% of cases, implicating surgical instruments [24]. It may show early or late symptomatology, with cervical or retrosternal pain, hematemesis, odynophagia or dysphagia [25–27]. There are subacute forms secondary to deep retropharyngeal abscess. It requires multidisciplinary management including head and neck and spine specialists [28].

In early (<1 month) lesions, the current tendency is interbody autologous tricortical grafting [29,30] with the new “low-profile” anterior plate [14]. Other teams use complementary posterior cervical fixation or external contention by occipito-cervico-thoracic brace [28]. Simple ablation seems to suffice in late perforation by esophageal compression due to material migration [24].

Pharyngoesophageal fistula causes a frequent problem of tightness of repair requiring iterative surgery [31]. The mucosal edges should be resected, with end-to-end absorbable suture protected by biologic glue. In revision, a local myofascial interposition graft is necessary. The two present cases involved protection of the pharyngoesophageal suture by the sternal head of the sternocleidomastoid muscle ipsilateral to the cervicotomy. A free flap may be used, depending on the microsurgery team’s experience [32]. Iterative recurrence requires surgical revision with suture and biologic

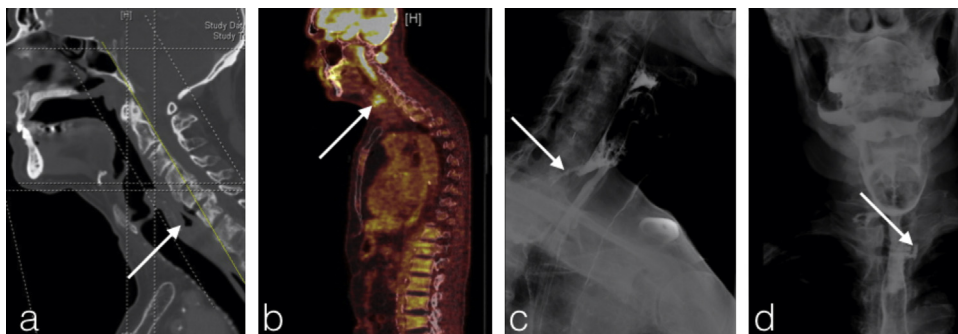


Fig. 3. C6 pharyngoesophageal fistula in patient 5: a: sagittal cervical CT slice with C5C6 prevertebral air density; b: PET scan with hyperfixation at pharyngoesophageal junction; c: lateral esophago-gastric-duodenal transit at cervical level with additive retroesophageal image; d: esophago-gastric-duodenal transit at cervical level with contrast medium leakage.

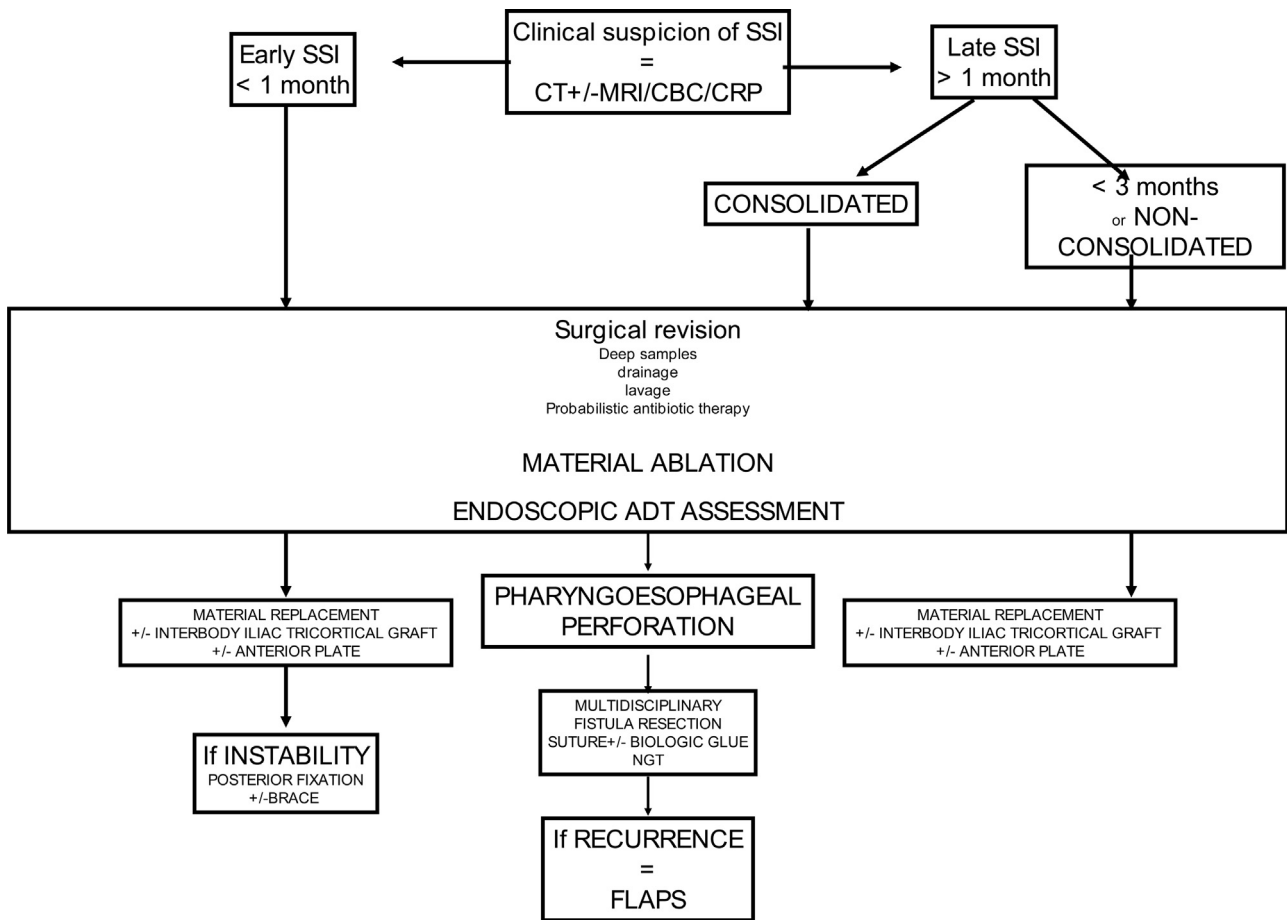


Fig. 4. Decision-tree for anterior cervical spine surgery site infection with and without pharyngoesophageal perforation. SSI: surgery site infection; ADT: aerodigestive tract; NGT: nasogastric tube.

glue using a pediculated flap taken from the superior sternocostal head of the pectoralis major. Esophago-gastric-duodenal transit is reserved for postoperative follow-up, to enable resumption of oral feeding after 2 weeks [28].

4.5. Study limitations

The present study had the limitations inherent to its retrospective design; but the rarity of these septic complications imposes purely observational study. The bias was limited by using a continuous series of all cases of revision for sepsis over a 10-year period in 2 centers. Some patients were doubtless lost to follow-up and may have been managed elsewhere. Moreover, the data collection method meant that only data for patients with 2 surgical procedures were collected, excluding any treated medically for documented spondylodiscitis. The rate of revision for cervical operative site infection may thus have been underestimated. The strong point of the study, on the other hand, is that it was the first French series measuring incidence of surgery site infection and pharyngoesophageal perforation at 10 years following anterior cervical spine surgery.

5. Conclusion

Spinal surgery on an anterior approach showed only a 0.34% rate of septic complications. Association of cervical infection and esophageal or pharyngeal perforation was frequent (3/5), although significance could not be demonstrated. This is a serious complication that should be systematically suspected in case of any surgery

site infection in a cervical segment. Early surgical intervention is mandatory, with multidisciplinary management involving spine surgeon, ENT physician and infectologist.

Disclosure of interest

Régis Gamain, Rémy Coulomb, Karim Houzir, Nicolas Molinari and Nicolas Lonjon declare that they have no competing interest. Pascal Kouyoumdjian is a consultant for Stryker®, but declare that he has no competing interest.

Funding

None.

Authors' contributions

Regis Gamain conducted and wrote up the study, based on an idea from Nicolas Lonjon. The epidemiological aspect was directed by Nicolas Molinari. Karim Houzir worked on one case. Rémy Coulomb, Pascal Kouyoumdjian and Nicolas Lonjon revised and corrected the manuscript.

Acknowledgments

Dr. Thierry Boudemaghe, BESPIM, CHU de Nîmes.

Appendix A. Supplementary data

Supplementary data associated with this article can be found, in the online version, at <https://doi.org/10.1016/j.otsr.2019.02.018>.

References

- [1] Zhao H, Duan L-J, Gao Y-S, et al. Comparison of the adverse events of anterior cervical disc replacement versus anterior cervical discectomy and fusion: a protocol for a systematic review and meta-analysis of prospective randomized controlled trials. *Medicine (Baltimore)* 2018;97:0015.
- [2] Fr Joaquim AF, Murar J, Savage JW, Patel AA. Dysphagia after anterior cervical spine surgery: a systematic review of potential preventative measures. *Spine J* 2014;14:2246–60.
- [3] Zeng J-H, Zhong Z-M, Chen J-T. Early dysphagia complicating anterior cervical spine surgery: incidence and risk factors. *Arch Orthop Trauma Surg* 2013;133:1067–71.
- [4] Kalb S, Reis MT, Cowperthwaite MC, et al. Dysphagia after anterior cervical spine surgery: incidence and risk factors. *World Neurosurg* 2012;77:183–7.
- [5] Sierra-Hoffman M, Jinadatha C, Carpenter JL, Rahm M. Postoperative instrumented spine infections: a retrospective review. *South Med J* 2010;103:25–30.
- [6] Vaccaro AR, Hulbert RJ, Patel AA, et al. The subaxial cervical spine injury classification system: a novel approach to recognize the importance of morphology, neurology, and integrity of the disco-ligamentous complex. *Spine* 2007;32:2365–74.
- [7] Fountas KN, Kapsalaki EZ, Nikolakakos LG, et al. Anterior cervical discectomy and fusion associated complications. *Spine* 2007;32:2310–7.
- [8] Christiano LD, Goldstein IM. Late prevertebral abscess after anterior cervical fusion. *Spine* 2011;36:798–802.
- [9] Ghobrial GM, Harrop JS, Sasso RC, et al. Anterior cervical infection: presentation and incidence of an uncommon postoperative complication. *Global Spine J* 2017;7:12–6.
- [10] Bertalanffy H, Eggert HR. Complications of anterior cervical discectomy without fusion in 450 consecutive patients. *Acta Neurochir (Wien)* 1989;99:41–50.
- [11] Lonjon G, Dauzac C, Fourniols E, Guigui P, Bonnomet F, Bonnevielle P. Early surgical site infections in adult spinal trauma: a prospective, multicentre study of infection rates and risk factors. *Orthop Traumatol Surg Res* 2012;98:788–94.
- [12] Hegde V, Meredith DS, Kepler CK, Huang RC. Management of postoperative spinal infections. *World J Orthop* 2012;3:182.
- [13] Basu S, Sreeramalingam R. Adjacent level spondylodiscitis after anterior cervical decompression and fusion. *Indian J Orthop* 2012;46:360.
- [14] Korovessis P, Repantis T, Vitsas V, Vardakastanis K. Cervical spondylodiscitis associated with oesophageal perforation: a rare complication after anterior cervical fusion. *Eur J Orthop Surg Traumatol* 2013;23:159–63.
- [15] Ghobrial GM, Beygi S, Viereck MJ, et al. Timing in the surgical evacuation of spinal epidural abscesses. *Neurosurg Focus* 2014;37:1.
- [16] Shousha M, Heyde C, Boehm H. Cervical spondylodiscitis: change in clinical picture and operative management during the last two decades. A series of 50 patients and review of literature. *Eur Spine J* 2015;24:571–6.
- [17] Ghobrial GM, Viereck MJ, Margiotta PJ, et al. Surgical management in 40 consecutive patients with cervical spinal epidural abscesses: shifting toward circumferential treatment. *Spine* 2015;40:949–53.
- [18] Jin S-W, Kim S-H, Choi J-I, Ha S-K, Lim D-J. Late infection from anterior cervical discectomy and fusion after twenty years. *Korean J Spine* 2014;11:22.
- [19] Tominaga H, Setoguchi T, Kawamura H, et al. Risk factors for unavoidable removal of instrumentation after surgical site infection of spine surgery: a retrospective case-control study. *Medicine (Baltimore)* 2016;95(43):e5118.
- [20] Boudissa M, Lebecque J, Boissière L. Early reintervention after anterior cervical spine surgery: epidemiology and risk factors: a case-control study. *Orthop Traumatol Surg Res* 2016;102:485–8.
- [21] Tate JL, Shockley WW, Stucker FJ. Management of perforations of the hypopharynx and cervical esophagus. *Laryngoscope* 1985;95:939–41.
- [22] Phommachanh V, Patil YJ, McCaffrey TV, Vale F, Freeman TB, Padhya TA. Otolaryngologic management of delayed pharyngoesophageal perforation following anterior cervical spine surgery. *Laryngoscope* 2010;120:930–6.
- [23] Woolley SL, Smith DRK. Pharyngeal perforation: a late complication of cervical spine surgery. *J Laryngol Otol* 2005;119:913–6.
- [24] Ashier M, Doğan E, Ecevit MC, Erdağ TK, İkiz AO. The treatment of pharyngoesophageal perforation following anterior cervical spine intervention. *Auris Nasus Larynx* 2016;43:359–65.
- [25] Khoo S-Y, Deimel GW, Park JG. 87-year-old woman with painful swallowing. *Mayo Clin Proc* 2010;85:86–9.
- [26] Hanson JM, Neilson D, Pettit SH. Intramural oesophageal dissection. *Thorax* 1991;46:524–7.
- [27] Krishnan P, Kartikueyan R, Patel SM, Bose PP, Mukherjee KK. Two cases of esophageal injury following anterior cervical discectomy and fusion: one overt and one covert. *Ann Neurosci* 2017;24:126.
- [28] Orlando ER, Caroli E, Ferrante L. Management of the cervical esophagus and hypofarinx perforations complicating anterior cervical spine surgery. *Spine* 2003;28:290–5.
- [29] Skeppholm M, Olerud C. Pain from donor site after anterior cervical fusion with bone graft: a prospective randomized study with 12 months of follow-up. *Eur Spine J* 2013;22:142–7.
- [30] Schnee CL, Freese A, Weil RJ, Marcotte PJ. Analysis of harvest morbidity and radiographic outcome using autograft for anterior cervical fusion. *Spine* 1997;22:2222–7.
- [31] Perrone O, Tassi V, Mattioli B, et al. Pharyngoesophageal perforation following anterior cervical discectomy and fusion: management and results. *Eur J Cardiothorac Surg* 2017;51:160–8.
- [32] Benazzo M, Spasiano R, Bertino G, Occhini A, Gatti P. Sternocleidomastoid muscle flap in esophageal perforation repair after cervical spine surgery: concepts, techniques, and personal experience. *J Spinal Disord Tech* 2008;21:597–605.