



HAL
open science

Do clinical results of arthroscopic subtalar arthrodesis correlate with CT fusion ratio?

Rémy Coulomb, Elyes Hsayri, Bastien Nougarede, Philippe Marchand, Olivier Mares, Pascal Kouyoumdjian, Nicolas Cellier

► To cite this version:

Rémy Coulomb, Elyes Hsayri, Bastien Nougarede, Philippe Marchand, Olivier Mares, et al.. Do clinical results of arthroscopic subtalar arthrodesis correlate with CT fusion ratio?. *Orthopaedics & Traumatology: Surgery & Research*, 2019, 10.1016/j.otsr.2019.01.017 . hal-02143259

HAL Id: hal-02143259

<https://hal.science/hal-02143259>

Submitted on 29 May 2019

HAL is a multi-disciplinary open access archive for the deposit and dissemination of scientific research documents, whether they are published or not. The documents may come from teaching and research institutions in France or abroad, or from public or private research centers.

L'archive ouverte pluridisciplinaire **HAL**, est destinée au dépôt et à la diffusion de documents scientifiques de niveau recherche, publiés ou non, émanant des établissements d'enseignement et de recherche français ou étrangers, des laboratoires publics ou privés.

Do clinical results of arthroscopic subtalar arthrodesis correlate with CT fusion ratio?

Rémy Coulomb*, Elyes Hsayri, Bastien Nougarede, Philippe Marchand, Olivier Mares, Pascal Kouyoumdjian, Nicolas Cellier

Service de chirurgie orthopédique et traumatologique, CHU Carêmeau, Place du Pr Debré, 30029 Nîmes cedex 9, France

ABSTRACT

Background: CT analysis of arthroscopic subtalar arthrodesis rarely finds complete fusion. The aim of the present study was to determine, at 12 months' follow-up of arthroscopic subtalar arthrodesis: (1) CT fusion ratio, (2) functional results, and (3) the correlation between the two.

Hypothesis: Incomplete fusion ratio does not impair the result of arthrodesis.

Materials and methods: A continuous series of 22 arthroscopic subtalar arthrodeses was assessed at 12 months' follow-up. The procedure used a posterior approach without bone graft, with stabilization by 2 compression screws. Clinical assessment comprised of a numerical analog pain scale (NAS, AOFAS and SF12) scores. Satisfaction was assessed on an NAS and on Odom's criteria. CT analysis at 12 months determined the posterior subtalar joint fusion ratio.

Results: At follow-up, 2 patients showed non-union (9.1%). Among the 20 patients with fusion (91%), fusion was complete ($> 67^\circ$) in 16 (72.7%) and partial (34–66%) in 4 (18.2%). Mean fusion ratio at 12 months was $77.7\% \pm 14.8$ (range, 36–98%). Functional gains (Δ) were: Δ pain NAS 4.8 ± 2 (range, 1–10) and Δ AOFAS score 31.1 ± 14 (range, 10–59). Mean satisfaction score was 8 ± 2.5 (range, 3–10). There were no significant correlations between fusion ratio and any clinical or satisfaction scores. **Conclusion:** Although clinical gain was systematic, functional and satisfaction scores were independent of whether subtalar fusion ratio was partial or complete.

Level of evidence: IV, retrospective study.

Keywords:

Arthrodesis
Subtalar joint
Arthroscopy
Fusion

1. Introduction

Various etiologies, such as primary osteoarthritis, inflammatory arthropathy, congenital pathology, sequelae of osteoarthritis or trauma, or acquired deformity [1], may induce subtalar joint degeneration. The usual symptoms comprise of pain, deformity and instability [2]. After failure of non-operative treatment, fusion provides lasting pain relief and improves functional status [3–8]. Technological progress and surgeons' improved arthroscopic skill have opened a field of possibilities to reduce morbidity following subtalar fusion. Fusion times and rates seem to be better with arthroscopic techniques, although there remains some disagreement [3–11].

Despite improved functional scores, pain persists after fusion [10]. Jones et al. (2006) [12] reported that radiography detected non-union only half the time; Computed Tomodensitometry Scan

(CT) is the reference examination to assess hindfoot fusion. Post-operative CT fusion ratio is often incomplete [13]. Ratios $> 33\%$ are predictive of stable fusion [14], but may still worry surgeons, who attribute residual pain to incomplete fusion. The present study hypothesis was that partial CT fusion ratios ($> 33\%$) do not impact functional results following arthrodesis.

The study objectives were to determine, at 12 months following arthroscopic subtalar fusion: (1) CT fusion ratio, (2) functional results, and (3) the correlation between the two.

2. Materials and methods

2.1. Population

A retrospective continuous single-surgeon series of 22 arthroscopic subtalar arthrodeses performed between September 2014 and October 2016 was analyzed by an independent investigator. The study had local review board approval (IRB 18.02.01). Exclusion criteria comprised: follow-up < 12 months, surgical revision of fusion, malunion with > 5 hindfoot deformity, and talofibular

* Corresponding author.

E-mail address: coulomb.remy@neuf.fr (R. Coulomb).

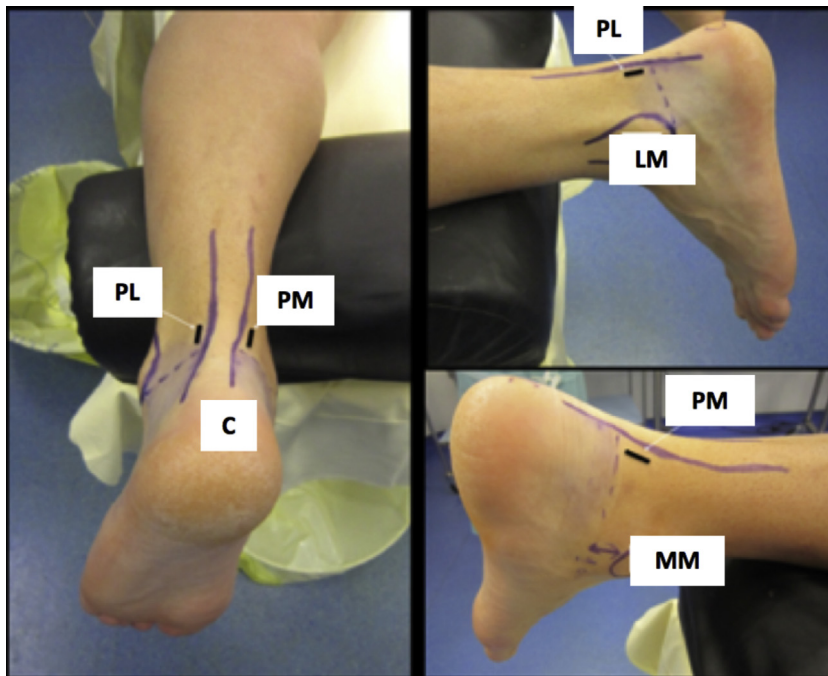


Fig. 1. Anatomic landmarks and approaches. C: calcaneus; LM: lateral malleolus; MM: medial malleolus; PL: posterolateral approach; PM: posteromedial approach.

impingement (usually treated by open fusion). Two patients underwent surgical revision, and were excluded from statistical analysis.

2.2. Surgical procedure

All patients were treated using the same arthroscopic procedure. The patient was positioned prone on the edge of the operating table, with the operated limb slightly raised. A tourniquet was applied to the root of the thigh. The posterior approach, following van Dijck et al. (2000) [15], used a 4.5 mm 30° arthroscope. The anatomic landmarks of the Achilles tendon, calcaneus and malleoli were marked. The posterolateral optical portal and posteromedial instrumental portal were marked over a line parallel to the sole of the foot through the summit of the lateral malleolus (Fig. 1).

A single skin incision and subcutaneous dissection allowed retraction of neighboring neurovascular structures: posterior tibial neurovascular pedicle and posteromedial calcaneal nerve branch or posterolateral sural nerve. The arthroscope was inserted posterolaterally down to talar bone contact. The shaver was introduced via the posteromedial portal and visualized by triangulation; the work chamber could then be created. This step concluded when the components of the hindfoot were identifiable (Fig. 2). The hallucis flexor longus muscle constituted the medial boundary of release. Posterior debridement was sometimes necessary to release osteophytes and access the subtalar joint. In the early learning curve, fluoroscopy was sometimes used for joint location. Synovectomy was performed using the shaver, and joint freshening by curette. Introducing the arthroscope into the joint provided distraction and visualization of the entire joint surface. Fixation used two 6.5 mm AutoFIX™ cannulated screws (Stryker®) over pins passed through the thalamus under visual control (Fig. 3). A talar incision was required for percutaneous insertion of the screws in the calcaneal tuberosity. Screw fixation in ankle dorsiflexion was controlled under fluoroscopy (Fig. 4). No bone grafts were performed. The scar was closed by simple suture. A definitive plaster boot cast was made.

All procedures were performed on an outpatient basis. Postoperative care comprised of plaster boot cast immobilization with

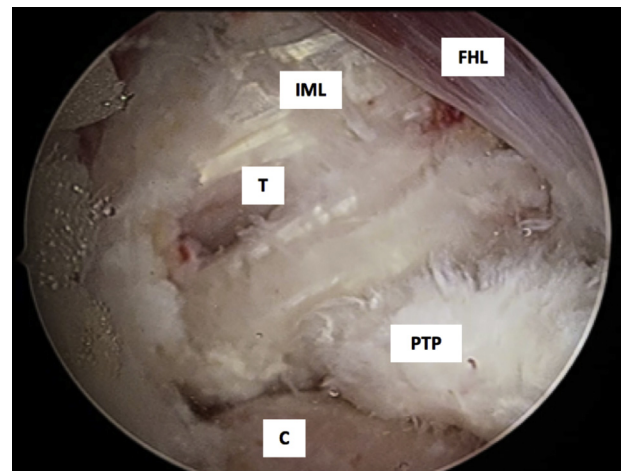


Fig. 2. Creation of work chamber and identification of hindfoot elements. FHL: flexor hallucis longus; PTP: posterior talar process; IML: intermalleolar ligament; T: talus; C: calcaneus.

complete non-weight-bearing and preventive-dose anticoagulation therapy for 6 weeks. Complete unprotected weight-bearing was resumed and rehabilitation began after these 6 weeks' immobilization.

2.3. Clinical assessment

Clinical assessment was performed at 12 months' follow-up. Age, gender, weight, height, body-mass index (BMI), ASA score, onset-to-surgery interval, etiology and work-accident status are shown in Table 1. Risk factors for non-union were collected: smoking, atheromatous disease, use of corticosteroids. Pain and functional scores were analyzed on preoperative and 12-month data. A numerical analog scale (NAS) assessed pain (0=no pain, to 10=worst imaginable pain). The AOFAS [16] and SF-12 [17] scales assessed functional status. At last follow-up, satisfaction was

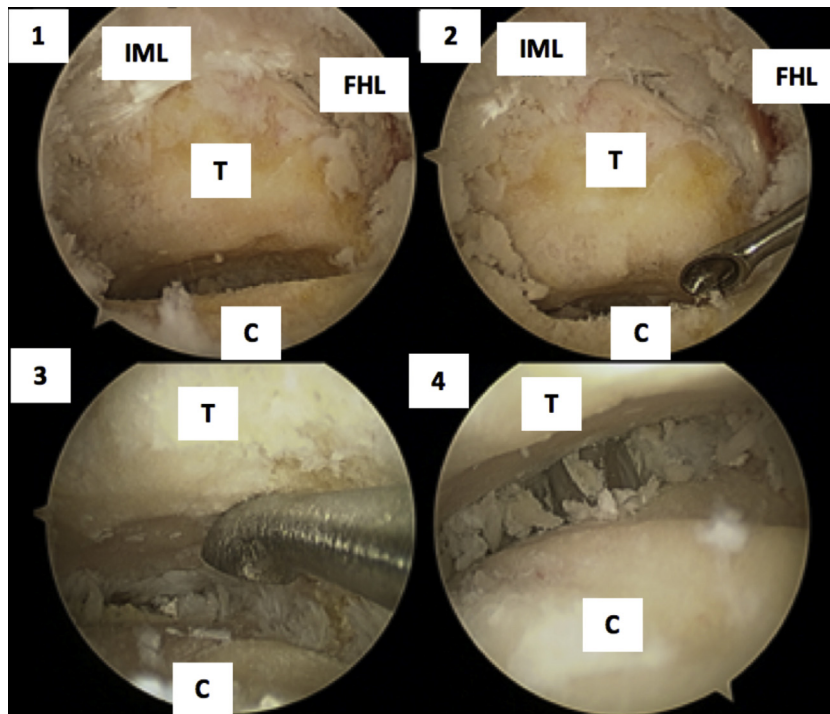


Fig. 3. Exposure of hindfoot. 1–2: joint surface freshening; 3: passage of pins for cannulated screws; 4: T: talus; C: calcaneus; IML: posterior intermalleolar ligament; FHL: flexor hallucis longus.

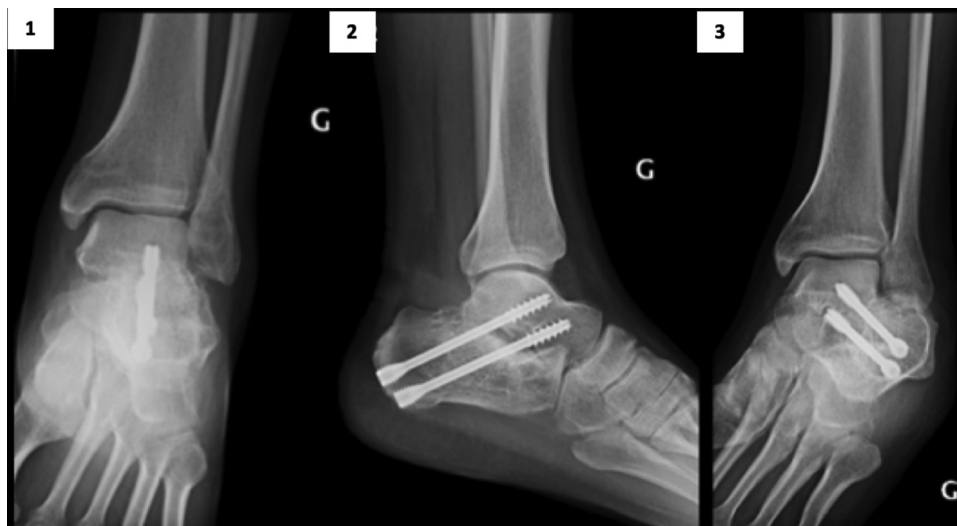


Fig. 4. Control radiograph. 1: Antero-posterior ; 2: lateral; 3: broaden incidence. G =left.

assessed on a NAS (0 = poor result, to 10 = excellent result) and Odom's criteria [18] (Table 2).

2.4. CT measurement technique

At 12 months, CT fusion ratio was assessed on 2 mm sagittal slices through the subtalar joint. Fusion ratio was calculated on each slice, as the ratio of joint fusion length to total joint length. The various ratios were averaged over the number of slices, as described by Dorsey et al. (2009) [14] (Fig. 5).

2.5. Statistical analysis

A descriptive analysis of the population was performed, with results reported as mean, standard deviation and range. The

quantitative variables (NAS, AOFAS, SF-12) were not normally distributed on Shapiro-Wilk test and were therefore compared on Wilcoxon test for matched groups (preoperative, follow-up). Correlations with fusion ratio were assessed on Spearman ranks test for quantitative clinical variables and on Mann-Whitney test for qualitative clinical variables. The significance threshold was set at 5%.

3. Results

3.1. CT fusion ratio

Mean posterior subtalar fusion ratio at 12 months was $77.7\% \pm 14.8$ (range, 36–98%). Fusion was achieved in 20 cases (90.9%): 16 (72.7%) complete (> 67%), and 4 (18.2%) partial (33–67%)

Table 1
Population data.

Follow-up (months)	24.1 ± 9.4 (12–38)
Time to surgery (months)	67.7 ± 102 (8–468)
Age (years)	49.5 ± 15.3 (20–78)
BMI	7.1 ± 4.9 (19.8–40)
Gender	Male: 16 Female: 6
Etiology	Trauma: 17 Synostosis: 3 Rheumatoid: 1 Instability: 1
ASA score	1: 9 2: 12 3: 1 4: 0
WA	WA: 5 non-WA: 17
Smoking	Active: 9

BMI: body-mass index; ASA score: American Society of Anesthesiologists score; WA: work accident.

Table 2
Odom satisfaction criteria.

Criterion	After the operation, you find:
Excellent	All preoperative symptoms relieved. Abnormal findings improved.
Good	Minimal persistence of preoperative symptoms. Abnormal findings unchanged or improved
Satisfactory	Definitive relief of some preoperative symptoms. Other symptoms unchanged or slightly improved.
Poor	Symptoms and signs unchanged or exacerbated

The 2 cases of non-union (9.1%) concerned subtalar osteoarthritis secondary to talar enucleation, and underwent open revision fusion with bone graft.

3.2. Functional results

NAS pain score progressed from 7 ± 1.4 (range, 4–10) preoperatively to 2.1 ± 1.2 (range, 0–4) at follow-up ($p < 0.001$): i.e., mean gain, 4.8 ± 2 (range, 1–10). AOFAS score progressed from 46.4 ± 13.4 (range, 13–61) to 76.4 ± 10.1 (range, 57–97) ($p < 0.001$): i.e., mean

gain, 31.1 ± 14 (range, 10–59). The SF12 physical component progressed from 30.1 ± 9.1 (range, 21.7–42.9) to 46.6 ± 11.4 (range, 24.7–56.2) ($p < 0.001$), and the mental component from 42.2 ± 10.7 (range, 21.5–51.7) to 53.1 ± 6.4 (range, 45.5–60.3) ($p < 0.05$).

Mean NAS satisfaction score was $8 \pm 2.5/10$ (range, 3–10). Results on Odom's criteria were poor in 3 cases, satisfactory in 7 and good in 10, with no excellent results.

Complications comprised 1 case of dysesthesia of the calcaneal branch of the tibial nerve at 1 year, suggestive of a lesion of the calcaneal branch of the tibial nerve, and 1 case of sural nerve dysesthesia, both resolving during follow-up. Two cases of discomfort with fixation material required ablation by last follow-up. The two patients suffering impingement underwent revision exostectomy.

3.3. Correlation between fusion ratio and clinical scores

There were no correlations between fusion ratio and age ($p = 0.17$), BMI ($p = 0.087$), postoperative pain NAS ($p = 0.057$), AOFAS score, SF-12 physical or mental component scores ($p = 0.33$) or satisfaction ($p = 0.57$). In the present series, smoking ($p = 0.15$), history ($p = 0.74$), work accident ($p = 0.56$), gender ($p = 0.65$), etiology and Odom criteria ($p = 0.86$) did not appear as risk factors for poor fusion ratio; only high ASA score was associated with lower fusion ratio ($p < 0.05$).

4. Discussion

With significant improvement in pain scores and a good level of satisfaction, the present study confirms the good results of arthroscopic posterior subtalar fusion. Although residual pain was systematic, it was unrelated to fusion ratio.

There have been few studies of CT fusion ratio following subtalar fusion and of its clinical implications. Jones et al. (2006) [12] developed a CT scoring system for fusion to assess the efficacy of ultrasound stimulation. In the absence of any standard, authors have arbitrarily arrived at definitions of non-union as 0–33% fusion, incomplete fusion as 34–66% and complete fusion as 67–100%. Dorsey et al. (2009) [14] were the first to assess the clinical relevance of fusion ratio in subtalar or ankle fusion, and found ratios < 33% to show high specificity and sensitivity as predictors of unstable fusion. Thauat et al. (2011) [13] reported a mean 39% CT fusion ratio, with 4 non-unions; their series, however, lacked homogeneity and fixation used a single screw in 10

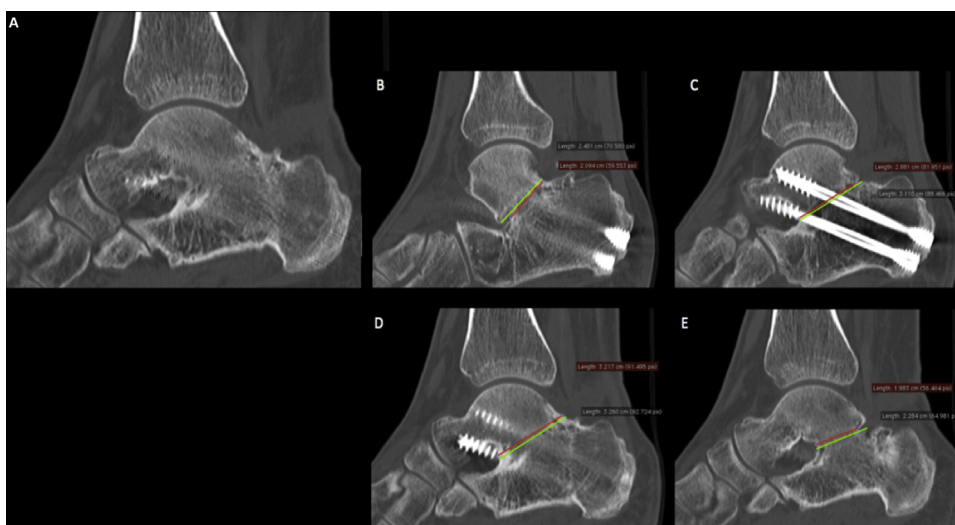


Fig. 5. Computed tomodensitometry (CT) fusion ratio in subtalar arthrodesis, following Dorsey. A: CT result of arthroscopic subtalar fusion; B–E: example of fusion ratio measurement for each slice.

of the 13 cases. Despite these fusion ratios, they found a 26-point improvement in function on AOFAS score. With a mean fusion ratio of 77.9% and 2 non-unions, the present results were better. Fixation by two cannulated compression screws probably provided more rigid assembly, blocking rotational stress and thus accounting for the present fusion ratios. With mean 93.9% and 91.1% talar and calcaneal freshening, respectively, Lintz et al. (2013) [19], in a cadaver study, confirmed that lateral arthroscopic fusion ensured optimal freshening, indispensable to good fusion quality. However, despite, complete freshening on a posterior approach, Mouilhade et al. (2011) [20] found imperfect contact between the freshened surfaces in 80% of cases. These fusion conditions thus seemed not to influence the fusion ratio in the present series.

Rungprai et al. (2016) [11], at last follow-up of arthroscopic posterior subtalar fusion, reported a 5.1 point gain in pain VAS, and 24.5 and 17 point gains in SF-36 physical and mental component scores respectively. Other authors likewise reported mean AOFAS score gains ranging between 31 and 50 points [4,5,8]. With mean gains of 4.8 points on pain NAS and 31.1 points on AOFAS score, the present results were similar. The arthroscopic procedure without bone graft allows optimal preparation of the posterior subtalar joint, enabling outpatient management [21] and earlier rehabilitation [11]. However, even if fusion does not involve the entire joint surface, the present results suggest that clinical outcome is unaffected by fusion ratio when it exceeds 33%.

This study had several limitations. It was retrospective, with a minimum 12 months' follow-up. Comparison of fusion ratios with an open surgery control group could confirm that arthroscopic results are at least equivalent. Moreover, the sample was too small for any conclusion to be drawn as to the relation between clinical outcome and fusion ratio. Finally, methodologically, the fusion ratio as calculated in the present study, included the area occupied by the screws, so that the true fusion ratio was inevitably lower.

5. Conclusion

With a 77.7% fusion ratio and 2 non-unions, the present results for arthroscopic posterior subtalar fusion were excellent. Although clinical improvement was systematic, residual pain was also systematic, and unrelated to fusion ratio.

Disclosure of interest

The authors Rémy Coulomb, Elyes Hsayri and Bastien Nougarede declare that they have no competing interest.

Olivier Mares has no conflicts of interest to disclose in relation to the present article, but is a consultant for Newclip and Stryker.

Philippe Marchand, Pascal Kouyoumdjian and Nicolas Cellier have no conflicts of interest to disclose in relation to the present article, but are consultants for Stryker.

Funding sources

None.

Author contributions

Rémy Coulomb: Substantial contributions to project design and experimental protocol, data acquisition, analysis and interpretation of results, and writing and critical revision of the article.

Elyes Hsayri: Substantial contributions to project design and experimental protocol, data acquisition, analysis and interpretation of results, and writing and critical revision of the article.

Bastien Nougarede: Substantial contributions to project design and experimental protocol, data acquisition, analysis and interpretation of results, and writing and critical revision of the article.

Philippe Marchand: Writing first draft and contribution to critical revision.

Olivier Mares: Writing first draft and contribution to critical revision.

Pascal Kouyoumdjian: Substantial contributions to project design and experimental protocol, data acquisition, analysis and interpretation of results.

Nicolas Cellier: Substantial contributions to project design and experimental protocol, data acquisition, analysis and interpretation of results, and writing and critical revision of the article.

All authors read and approved the final submitted version of the article.

References

- [1] Roster B, Kreulen C, Giza E. Subtalar Joint Arthrodesis: Open and Arthroscopic Indications and Surgical Techniques. *Foot Ankle Clin* 2015;20:319–34.
- [2] Donatto KC. Arthritis and arthrodesis of the hindfoot. *Clin Orthop* 1998;349:81–92.
- [3] Easley ME, Trnka H-J, Schon LC, Myerson MS. Isolated Subtalar Arthrodesis. *J Bone Joint Surg* 2000;82:613–24.
- [4] Amendola A, Lee K-B, Saltzman CL, Such JS. Technique and early experience with posterior arthroscopic subtalar arthrodesis. *Foot Ankle Int* 2007;28:298–302.
- [5] Lee K-B, Park C-H, Seon J-K, Kim M-S. Arthroscopic subtalar arthrodesis using a posterior 2-Portal approach in the prone position. *Arthrosc J Arthrosc Relat Surg* 2010;26:230–8.
- [6] Carranza-Bencano A, Tejero-García S, Del Castillo-Blanco G, Fernández-Torres JJ, Alegrete-Parra A. Isolated subtalar arthrodesis through minimal incision surgery. *Foot Ankle Int* 2013;34:1117–27.
- [7] Flemister AS, Infante AF, Sanders RW, Walling AK. Subtalar arthrodesis for complications of intra-articular calcaneal fractures. *Foot Ankle Int* 2000;21:392–9.
- [8] Albert A, Deleu P-A, Leemrijse T, Maldague P, Devos Bevernage B. Posterior arthroscopic subtalar arthrodesis: Ten cases at one-year follow-up. *Orthop Traumatol Surg Res* 2011;97:401–5.
- [9] Davies MB, Rosenfeld PF, Stavrou P, Saxby TS. A comprehensive review of subtalar arthrodesis. *Foot Ankle Int* 2007;28:295–7.
- [10] Mann RA, Baumgarten M. Subtalar fusion for isolated subtalar disorders. Preliminary report. *Clin Orthop* 1988;226:260–5.
- [11] Rungprai C, Phisitkul P, Femino JE, Martin KD, Saltzman CL, Amendola A. Outcomes and complications after open versus posterior arthroscopic subtalar arthrodesis in 121 patients. *J Bone Joint Surg Am* 2016;8:636–46.
- [12] Jones CP, Coughlin MJ, Shurnas PS, Prospective CT. scan evaluation of hind-foot nonunions treated with revision surgery and low-intensity ultrasound stimulation. *Foot Ankle Int* 2006;4:229–35.
- [13] Thauat M, Bajard X, Boisrenoult P, Beaufils P, Oger P. Computer Tomography assessment of the fusion rate after posterior arthroscopic subtalar arthrodesis. *Int Orthop* 2011;5:1005–10.
- [14] Dorsey ML, Liu PT, Roberts CC, Kile TA. Correlation of arthrodesis stability with degree of joint fusion on MDCT. *Am J Roentgenol* 2009;2:496–9.
- [15] Van Dijk CN, Scholten PE, Krips R. A 2-portal endoscopic approach for diagnosis and treatment of posterior ankle pathology. *Arthroscopy* 2000;8:871–6.
- [16] Kitaoka HB, Alexander JJ, Adelaar RS, Nunley JA, Myerson MS, Sanders M. Clinical rating systems for the ankle-hindfoot, midfoot, hallux, and lesser toes. *Foot Ankle Int* 1994;7:349–53.
- [17] Forero CG, Vilagut G, Adroher ND, Alonso J. Multidimensional item response theory models yielded good fit and reliable scores for the Short Form-12 questionnaire. *J Clin Epidemiol* 2013;7:790–801.
- [18] Odom CL, Finney W, Woodhall B. Cervical disk lesions. *J Am Med Assoc* 1958;1:23–8.
- [19] Lintz F, Guillard C, Colin F, Marchand JB, Brilhault J. Safety and efficiency of a 2-portal lateral approach to arthroscopic subtalar arthrodesis: A cadaveric study. *Arthrosc J Arthrosc Relat Surg* 2013;7:1217–23.
- [20] Mouilhade L, Oger P, Roussignol X, Boisrenoult P, Sfez J, Duparc F. Risks relating to posterior 2-portal arthroscopic subtalar arthrodesis and articular surfaces abrasion quality achievable with these approaches: a cadaver study. *Orthop Traumatol Surg Res* 2011;97:396–400.
- [21] Roussignol X. Arthroscopic tibiotalar and subtalar joint arthrodesis. *Orthop Traumatol Surg Res* 2016;102:S195–203.