



**HAL**  
open science

## Contribution of arthroscopy in the treatment of anterior glenoid rim fractures: a comparison with open surgery

Nicolas Bonneville, Philippe Clavert, Marine Arboucalot, David Bahlau,  
Thomas Bauer, Matthieu Ehlinger

### ► To cite this version:

Nicolas Bonneville, Philippe Clavert, Marine Arboucalot, David Bahlau, Thomas Bauer, et al.. Contribution of arthroscopy in the treatment of anterior glenoid rim fractures: a comparison with open surgery. *Journal of Shoulder and Elbow Surgery*, 2019, 28 (1), pp.42-47. 10.1016/j.jse.2018.07.008 . hal-02143253

**HAL Id: hal-02143253**

**<https://hal.science/hal-02143253v1>**

Submitted on 29 May 2019

**HAL** is a multi-disciplinary open access archive for the deposit and dissemination of scientific research documents, whether they are published or not. The documents may come from teaching and research institutions in France or abroad, or from public or private research centers.

L'archive ouverte pluridisciplinaire **HAL**, est destinée au dépôt et à la diffusion de documents scientifiques de niveau recherche, publiés ou non, émanant des établissements d'enseignement et de recherche français ou étrangers, des laboratoires publics ou privés.




## Open Archive Toulouse Archive Ouverte (OATAO)

OATAO is an open access repository that collects the work of some Toulouse researchers and makes it freely available over the web where possible.

This is an author's version published in: <https://oatao.univ-toulouse.fr/23089>

**Official URL :** <https://doi.org/10.1016/j.jse.2018.07.008>

### To cite this version :

Bonnevialle, Nicolas  and Clavert, Philippe and Arboucalot, Marine and Bahlau, David and Bauer, Thomas and Ehlinger, Matthieu *Contribution of arthroscopy in the treatment of anterior glenoid rim fractures: a comparison with open surgery.* (2019) *Journal of Shoulder and Elbow Surgery*, 28 (1). 42-47. ISSN 1058-2746

Any correspondence concerning this service should be sent to the repository administrator:  
[tech-oatao@listes-diff.inp-toulouse.fr](mailto:tech-oatao@listes-diff.inp-toulouse.fr)

# Contribution of arthroscopy in the treatment of anterior glenoid rim fractures: a comparison with open surgery

Nicolas Bonnevalle, MD, PhD<sup>a,b,\*</sup>, Philippe Clavert, MD, PhD<sup>c,d</sup>,  
Marine Arboucalot, MD<sup>a</sup>, David Bahlau, MD<sup>c</sup>, Thomas Bauer, MD, PhD<sup>e</sup>,  
Matthieu Ehlinger, MD, PhD<sup>f</sup>, SOFCOT<sup>g</sup>

<sup>a</sup>Département d'Orthopédie Traumatologie du Centre Hospitalier Universitaire de Toulouse, Hôpital Riquet, Toulouse, France

<sup>b</sup>Laboratoire de Biomécanique, Institut de Mécanique des Fluides de Toulouse- Unité Mixte de Recherche-Centre National de la Recherche Scientifique, 5502, Hôpital Riquet, Toulouse, France

<sup>c</sup>Service de Chirurgie du Membre Supérieur, Centre de Chirurgie Orthopédique et de la Main, Illkirch, France

<sup>d</sup>Laboratoire ICube, Centre National de la Recherche Scientifique Unité Mixte de Recherche 7357, Illkirch, France

<sup>e</sup>Service d'Orthopédie, Ambroise Paré Hospital, Boulogne Billancourt, France

<sup>f</sup>Service de Chirurgie Orthopédique et Traumatologie, Hôpital de Hautepierre, Strasbourg, France

<sup>g</sup>Société Française de Chirurgie Orthopédique et Traumatologique (SOFCOT), Paris, France

**Background:** This study assessed the clinical and radiologic outcomes of Ideberg type IA glenoid fractures treated using conventional open surgery compared with those treated with arthroscopic surgery.

**Materials and methods:** This was a retrospective, multicenter study of anterior glenoid rim fractures (Ideberg IA) treated with conventional open surgery (group O) or arthroscopic surgery (group A). Included were 56 patients: 10 in group O and 46 in group A. The patients were reviewed after a minimum of 12 months of follow-up. The Constant score was used as an objective clinical outcome. Radiographs were reviewed to assess the quality of the postoperative reduction, fracture healing, complications, and whether osteoarthritis was present at the last follow-up.

**Results:** At a mean follow-up of 30 months (range, 12-115 months), there was no significant difference between the groups based on the Constant Score (group O: 74 points; group A: 84 points,  $P = .07$ ). None of the shoulders showed signs of instability. Conversely, the rate of postoperative complications was higher in group O than in group A (30% vs. 4%;  $P = .03$ ). Glenohumeral osteoarthritis was found in 10% of group O patients and 18% of group A patients ( $P = .65$ ).

**Conclusions:** This study shows that anterior glenoid rim fractures have similar functional outcomes, whether treated using conventional open surgery or arthroscopic surgery. Arthroscopic surgery appears to reduce the complication and reoperation rate.

The Comité D'Éthique des Facultés de Médecine, d'Odontologie, de Pharmacie, des Ecoles d'Infirmières, de Kinésithérapie, and de Maïeutique et des Hôpitaux approved this study (FC-2015-81).

\*Reprint requests: Nicolas Bonnevalle, MD, PhD, Département d'Orthopédie Traumatologie du CHU de Toulouse, Hôpital Riquet, Place Baylac, 31052 Toulouse, France.

E-mail address: [nicolasbonnevalle@yahoo.fr](mailto:nicolasbonnevalle@yahoo.fr) (N. Bonnevalle).

**Level of evidence:** Level III; Retrospective Cohort Design; Treatment Study

**Keywords:** Glenoid; fracture; shoulder; Ideberg; arthroscopy; shoulder instability

Scapula fractures with extension to the glenoid are rare. In the Ideberg classification of intra-articular fractures, type IA corresponds to an anterior glenoid rim fracture, which occurs with glenohumeral dislocation in two-thirds of cases.<sup>9</sup> When the articular fragment makes up more than 20% of the glenoid surface, reduction and stabilization may be proposed to prevent glenohumeral instability and osteoarthritis (OA) from developing over time.<sup>8,24</sup>

Arthroscopy techniques offer less invasive and, theoretically, more precise solutions than standard open surgery through the anterior deltopectoral approach for treating these intra-articular fractures.<sup>3,10-12,14,16,20-25</sup> Arthroscopy also provides an opportunity to assess and treat any associated rotator cuff tendon injuries or greater tuberosity fracture.<sup>17,24</sup>

There is currently no evidence that one surgical technique is superior for treating Ideberg IA fractures. This study assessed the clinical and radiologic outcomes of Ideberg type IA glenoid fractures treated using conventional open surgery compared with those treated with arthroscopic surgery. We hypothesized that arthroscopic surgery would reduce the complication rate and result in better clinical outcomes than open surgical treatment.

## Materials and methods

This was a retrospective study of patients treated between December 1, 2006, and January 1, 2016. Patients were included who had (1) a recent Ideberg IA<sup>9</sup> glenoid fracture (<3 weeks), (2) had been treated with standard open surgery (group O) or arthroscopic surgery (group A), and (3) had at least 12 months of follow-up consisting of clinical and radiologic assessments. Patients with Ideberg IB, II, III, IV, or V glenoid fractures were excluded.

During the study period, 74 glenoid fractures were treated surgically, and 56 were Ideberg IA fractures. One patient was lost to follow-up before the 12-month follow-up visit. Thus, 10 patients in group O and 45 in group A were available for analysis.

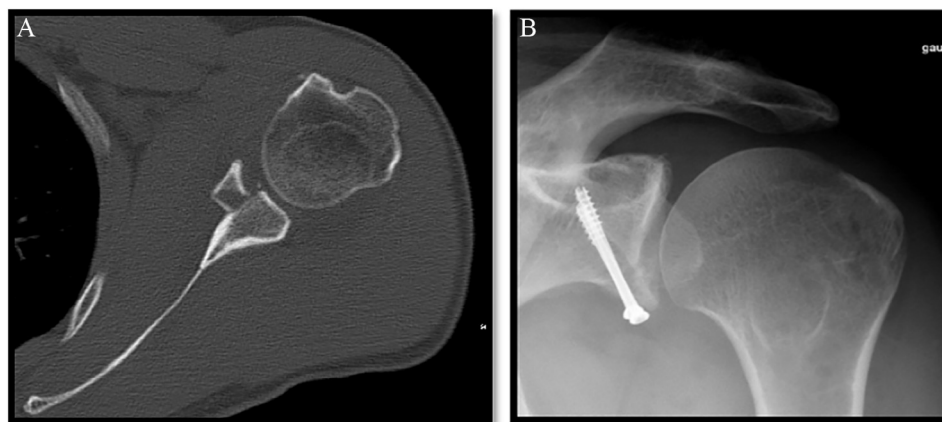
## Surgical technique

The technical choice of open or arthroscopic surgery depended on surgeon preference.

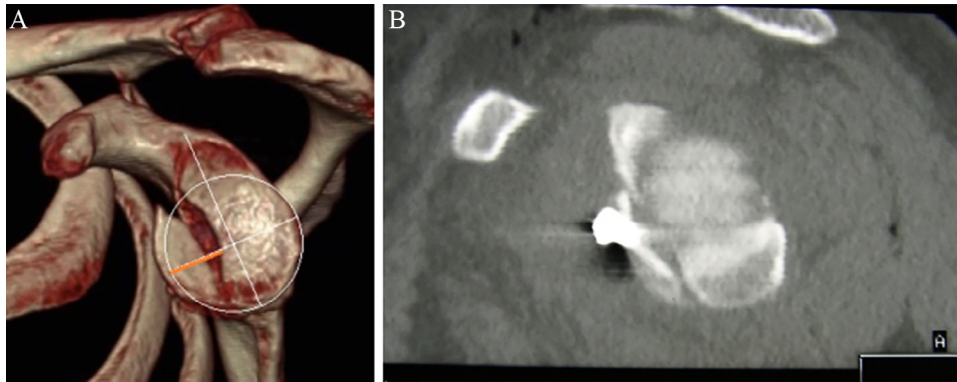
Patients in group O were operated on in the beach chair position under general anesthesia with an interscalene nerve block. A deltopectoral approach was used. Subscapular tenotomy was performed to access the glenohumeral joint. After exploring the joint and locating any osteochondral lesions, the surgeon reduced the fragment and held it in place temporarily with Kirschner wires. The fragment was secured with one or two 3.5-mm diameter cannulated screws (Fig. 1). If a proximal humeral fracture was also present, additional fixation with screws or a plate was done through the same approach.

Patients in group A were operated on in the beach chair position (n = 33) or in lateral decubitus (n = 13). One or 2 instrument portals (anterosuperior, anteroinferior) were established along with an optical portal in the posterior soft point. After draining the hemarthrosis, the joint was explored to identify any osteochondral lesions. The fracture was reduced and stabilized with anchors according to the Sugaya<sup>23</sup> technique (n = 36) or with a combination of anchors and screw fixation (n = 10) introduced via an accessory lower anterior portal through the subscapularis (Fig. 2).

The patient's operated-on arm was immobilized postoperatively with a sling in internal rotation for 4 to 6 weeks, no matter which surgical technique was used. Pendulum exercises were initiated within a few days of surgery, and active movements were allowed starting at 6 weeks, under the control of a physiotherapist.



**Figure 1** (A) Axial computed tomography slice shows an Ideberg IA glenoid fracture in a left shoulder. (B) Radiographs taken at 5 years after open reduction and internal fixation (anteroposterior view).



**Figure 2** (A) Computed tomography with 3-dimensional reconstruction and humeral head subtraction showing an Ideberg IA glenoid fracture in the left shoulder. (B) Sagittal computed tomography slice shows the arthroscopic screw fixation.

## Clinical evaluation

Patients were reviewed for clinical and radiologic follow-up assessments and to provide consent to participate in this study. Active range of motion was measured with a goniometer with the patient seated and performing anterior elevation, external rotation with the elbow at the side, and internal rotation (maximal vertebral level reached by the patient's thumb) movements. The outcomes were assessed objectively with the Constant Score and subjectively with an analog scale to determine satisfaction (excellent, good, average, or poor outcome).<sup>6</sup> Complications and reoperations were noted.

## Radiographic evaluation

Preoperatively, plain anteroposterior x-ray images and a computed tomography scan were used to classify the fracture based on the Ideberg classification.<sup>9</sup> The largest width of the fracture was measured on the computed tomography scan. Fracture healing was assessed at 6 months postoperatively on anteroposterior and lateral views. Signs of osteoarthritis were assessed at the latest follow-up according to Samilson and Prieto.<sup>18</sup>

## Statistical methods

Measurements are expressed as the mean, range, and standard deviation. The D'Agostino-Pearson test was used to analyze the data distribution. Paired values were compared using a paired *t* test, and unpaired results were compared using the Mann-Whitney test. The  $\chi^2$  or Fisher exact test was used to compare categorical data. The significance level was set at  $P < .05$ .

## Results

### Study cohort

Patients were a mean age of 46 years (range, 20-77 years), and there were 13 women and 42 men. The fracture was caused by a sports-related injury in 38% ( $n = 17$ ). Glenohumeral dislocation was associated in 87% ( $n = 48$ ). Ten patients also had a proximal humeral fracture: undisplaced greater tuberosity ( $n = 7$ ), displaced greater tuberosity ( $n = 2$ ), and 3-part fracture ( $n = 1$ ). Characteristics of the patients in groups O and A are summarized in Table I. Group O had more patients with

**Table I** Comparison of epidemiologic data for group O (open) and group A (arthroscopy)

Variable	Group O (n = 10)	Group A (n = 45)	P value
Age, yr	47 ± 12 (20-65)	41 ± 17 (22-77)	.87
Sex			.75
Male	8	34	
Female	2	11	
Sports-related injury	4	13	>.99
Work compensation	1	1	.23
Concurrent dislocation	8	40	.59
Concurrent proximal humeral fracture	4 (40)	6 (13)	.04
Glenoid fragment width, mm	9.5 ± 2.7 (7-17)	10.2 ± 2.5 (8-18)	.29
Time to surgery, d	2.5 ± 3 (0-10)	5 ± 5 (1-22)	.01

Data are presented as mean ± standard deviation (range), as number of patients, or as number (%).

**Table II** Comparison of Constant score for group O (open) and group A (arthroscopy)

Constant score	Group O (n = 10)	Group A (n = 45)	P value
Pain (/15 points)	12.5 ± 4 (5-15)	12.6 ± 3 (5-15)	.6
Activity (/20 points)	16.1 ± 6 (3-20)	18.3 ± 3 (6-24)	.4
Mobility (/40 points)	32.6 ± 11 (8-40)	34.3 ± 6 (20-40)	.4
Strength (/25 points)	13.2 ± 7 (2-25)	20.2 ± 4 (10-25)	.001
Total (/100)	74 ± 6 (20-100)	84 ± 12 (52-98)	.07
Adjusted, %	120 ± 38 (29-144)	133 ± 13 (91-142)	.06

Data are presented as mean ± standard deviation (range).

**Table III** Comparison of active range of motion for group O (open) and group A (arthroscopy)

Range of motion	Group O	Group A (n = 45)	P value
Anterior elevation, °	144 ± 30 (180-45)	164 ± 25 (180-90)	.04
External rotation, °	34 ± 18 (10-50)	49 ± 7 (10-80)	.006
Internal rotation, points	8.5 ± 3 (2-10)	8.2 ± 2 (2-10)	.84

Data are presented as mean ± standard deviation (range).

an associated humeral fracture, and they were operated on more quickly.

## Surgical data

The mean operative time was 88 ± 23 minutes (range, 60-130 minutes) in group O and 68 ± 35 minutes (range, 27-210 minutes) in group A ( $P=.09$ ). Fracture reduction was anatomic (<1 mm of gap) in 90% of patients in group O and in 67% of patients in group A ( $P = .14$ ).

## Clinical outcomes

At a mean follow-up of 30 months (range, 12-115 months), the mean Constant score was 82 ± 16 points (range, 20-100 points) in the entire cohort. Active anterior elevation was 162° ± 30° (range, 45°-180°), external rotation was 51° ± 19° (range, 10°-80°), and internal rotation was 8 ± 2 points (range, 2-10 points). The results for the 2 groups are compared in [Tables II and III](#). Patients in group A had better strength, anterior elevation, and external rotation than those in group O. There were no significant differences between the 2 groups in the absolute and adjusted Constant Score.

The presence of osteochondral glenoid lesions detected intraoperatively had a negative effect on the overall Constant Score at the final follow-up (76 points vs. 88 points;  $P = .002$ ). When humeral fractures were excluded from the analysis to make the groups more even, no significant difference was found in the average absolute and adjusted Constant Score between group O (82 patients [120%],  $P = .78$ ) and group A (84 patients [27%],  $P = .36$ ). The subjective outcome was

good or excellent in 90% of group O patients and in 91% of group A patients ( $P = .19$ ).

## Radiologic outcomes

At the last follow-up visit, all fractures had healed, regardless of the type of surgery performed. The incidence of OA is reported in [Table IV](#). There were no significant differences between groups.

## Complications

There were 5 complications (9%) in the cohort: 3 in group O (30%) and 2 in group A (4%;  $P = .03$ ). In group O, there were 2 infections and 1 case of joint stiffness requiring 3 reoperations: 2 lavage/débridement procedures with removal of hardware and 1 arthrolysis procedure with a poor result

**Table IV** Presence of glenohumeral osteoarthritis in group O (open) and group A (arthroscopy)

Variable	Group O (n = 10)	Group A (n = 45)	P value
Follow-up, mo	25 (12-72)	33 (12-115)	
Samilson OA stage <sup>22</sup>			
1	1 (10)	4 (9)	NR
2	0	3 (7)	
3	0	1 (2)	
Total	1 (10)	8 (18)	.52

OA, osteoarthritis; NR, not reported.

Data are presented as mean (range) or number (%).

at 12 months. In group A, 2 cases of joint stiffness required 2 arthrolysis procedures with removal of hardware. These 2 patients recovered full range of motion uneventfully.

## Discussion

Our initial hypothesis was partially validated: arthroscopic and conventional open surgical treatment of Ideberg IA glenoid fractures results in similar clinical outcomes at the early to midterm follow-up. However, the postoperative complication rate was significantly higher with open surgical treatment. No matter which type of surgical technique was used, the outcome was negatively affected by the presence of post-traumatic osteochondral lesions.

Kavanagh et al<sup>11</sup> reported the outcomes of a case series of 9 patients with a scapular fracture with glenoid extension treated surgically with an open procedure. One case of heterotopic ossification and 1 case of glenohumeral OA were identified after a mean of 4 years of follow-up. The largest study was reported by Mayo et al.<sup>12</sup> Of the 27 treated patients, 89% had anatomic reduction and 82% had good or excellent clinical outcomes. Only 1 infection was reported. Infections occurred in 9% of patients in the Schandelmaier et al<sup>20</sup> study, in which 22 glenoid fractures were fixed through a posterior or anterior approach. This was also the most frequent complication (2 of 10) in our series of patients treated by open surgery, whereas no infections occurred in the arthroscopy group. This difference has been reported with other types of injuries and appears to be an advantage common to every arthroscopic and minimally invasive treatment.<sup>1,7</sup>

During the open anterior surgical approach, subscapular tenotomy allowed us to verify the articular reduction of the glenoid fracture. As with surgery for chronic instability, subscapularis tenotomy can—by itself—cause the postoperative stiffness and strength deficit that we observed.<sup>4,18,19</sup> Simply splitting the subscapularis muscle may have reduced the consequences of open surgery, as recommended for a Latarjet bone block procedure.<sup>15</sup>

The arthroscopic stabilization technique described by Sugaya et al<sup>23</sup> was used most often in our cohort. In patients with chronic instability, Sugaya et al<sup>23</sup> reported the outcomes after tendon-to-bone suture repair with anchors of the anteroinferior bone fragment that ranged in size from 2% to 21% of the glenoid's diameter. We used a mixed technique to leverage the advantages associated with anchors to reduce the glenoid fragment and stiffer fixation through screw-induced compression, to achieve optimal primary stability.

Tauber et al<sup>24</sup> described the outcomes of 10 patients who underwent arthroscopic screw fixation at more than 2 years of follow-up. As in our study, they reported no serious intraoperative complications. Nevertheless, the screws had to be removed in 1 patient because of impingement with the humeral head during internal rotation.<sup>22</sup> This problem is not specific to the surgical technique but rather to screw fixation and its orientation. Absorbable screws can be used to avoid

this complication; however, their mechanical properties are controversial.<sup>2,21</sup>

Scheibel et al<sup>21</sup> found OA in 28% (6 of 21) of their patients at mean follow-up of 33 months. The presence of OA was correlated to patient age at the time of the surgery, not to the quality of the articular reduction. This correlation had previously been established in studies of chronic anterior shoulder instability.<sup>4,5,13</sup> In our study, the type of surgical technique did not affect OA development, despite the reduction being superior when an open procedure was performed (90% vs. 67%).

Our study has certain limitations related to its retrospective nature. First, the groups were not fully comparable in the number of patients and associated injuries. Glenoid fractures associated with a proximal humeral fracture were preferentially treated with open surgery. Nevertheless, the subgroup analysis found no significant effect of this parameter on the final Constant Score.

Second, reduction and healing was only assessed on plain x-ray images, which could have underestimated step-off or nonunion.

Our study's greatest strengths are (1) comparison of 2 types of surgical techniques and (2) a larger sample size than in other published studies.

## Conclusion

Surgical treatment of Ideberg IA glenoid fractures has similar early to midterm outcomes, whether performed with a conventional open technique or with arthroscopic surgery. However, range of motion seems to be better and the complication and reoperation rates are lower after the arthroscopic technique. The presence of osteochondral lesions negatively affects the outcome.

## Disclaimer

All the authors, their immediate families, and any research foundations with which they are affiliated have not received any financial payments or other benefits from any commercial entity related to the subject of this article.

## References

1. Baker DK, Perez JL, Watson SL, McGwin G, Brabston EW, Hudson PW, et al. Arthroscopic versus open rotator cuff repair: which has a better complication and 30-day readmission profile? *Arthroscopy* 2017;33:1764-9. <http://dx.doi.org/10.1016/j.arthro.2017.04.019>
2. Balestro JC, Young A, Maccioni C, Walch G. Graft osteolysis and recurrent instability after the Latarjet procedure performed with bioabsorbable screw fixation. *J Shoulder Elbow Surg* 2015;24:711-8. <http://dx.doi.org/10.1016/j.jse.2014.07.014>
3. Bauer T, Abadie O, Hardy P. Arthroscopic treatment of glenoid fractures. *Arthroscopy* 2006;22:569. <http://dx.doi.org/10.1016/j.arthro.2006.01.003>

4. Bonneville N, Mansat P, Bellumore Y, Mansat M, Bonneville P. Selective capsular repair for the treatment of anterior-inferior shoulder instability: review of seventy-nine shoulders with seven years' average follow-up. *J Shoulder Elbow Surg* 2009;18:251-9. <http://dx.doi.org/10.1016/j.jse.2008.09.007>
5. Buscayret F, Edwards TB, Szabo I, Adeleine P, Coudane H, Walch G. Glenohumeral arthrosis in anterior instability before and after surgical treatment: incidence and contributing factors. *Am J Sports Med* 2004;32:1165-72. <http://dx.doi.org/10.1177/0363546503262686>
6. Constant CR, Murley AH. A clinical method of functional assessment of the shoulder. *Clin Orthop Relat Res* 1987;(214):160-4.
7. Day M, Westermann R, Duchman K, Gao Y, Pugely A, Bollier M, et al. Comparison of short-term complications after rotator cuff repair: open versus arthroscopic. *Arthroscopy* 2018;34:1130-6. <http://dx.doi.org/10.1016/j.arthro.2017.10.027>
8. Goss TP. Fractures of the glenoid cavity. *J Bone Joint Surg Am* 1992;74:299-305.
9. Ideberg R, Grevsten S, Larsson S. Epidemiology of scapular fractures. Incidence and classification of 338 fractures. *Acta Orthop Scand* 1995;66:395-7.
10. Jiang CY, Zhu YM, Liu X, Li FL, Lu Y, Wu G. Do reduction and healing of the bony fragment really matter in arthroscopic bony Bankart reconstruction?: a prospective study with clinical and computed tomography evaluations. *Am J Sports Med* 2013;41:2617-23. <http://dx.doi.org/10.1177/0363546513499304>
11. Kavanagh BF, Bradway JK, Cofield RH. Open reduction and internal fixation of displaced intra-articular fractures of the glenoid fossa. *J Bone Joint Surg Am* 1993;75:479-84.
12. Mayo KA, Benirschke SK, Mast JW. Displaced fractures of the glenoid fossa. Results of open reduction and internal fixation. *Clin Orthop Relat Res* 1998;(347):122-30.
13. Mizuno N, Denard PJ, Raiss P, Melis B, Walch G. Long-term results of the Latarjet procedure for anterior instability of the shoulder. *J Shoulder Elbow Surg* 2014;23:1691-9. <http://dx.doi.org/10.1016/j.jse.2014.02.015>
14. Nakagawa S, Ozaki R, Take Y, Mae T, Hayashida K. Bone fragment union and remodeling after arthroscopic bony Bankart repair for traumatic anterior shoulder instability with a glenoid defect: influence on postoperative recurrence of instability. *Am J Sports Med* 2015;43:1438-47. <http://dx.doi.org/10.1177/0363546515571555>
15. Paladini P, Merolla G, De Santis E, Campi F, Porcellini G. Long-term subscapularis strength assessment after Bristow-Latarjet procedure: isometric study. *J Shoulder Elbow Surg* 2012;21:42-7. <http://dx.doi.org/10.1016/j.jse.2011.03.027>
16. Plath JE, Feucht MJ, Bangoj R, Martetschläger F, Wörtler K, Seppel G, et al. Arthroscopic suture anchor fixation of bony Bankart lesions: clinical outcome, magnetic resonance imaging results, and return to sports. *Arthroscopy* 2015;31:1472-81. <http://dx.doi.org/10.1016/j.arthro.2015.03.005>
17. Rouleau DM, Mutch J, Laflamme GY. Surgical treatment of displaced greater tuberosity fractures of the humerus. *J Am Acad Orthop Surg* 2016;24:46-56. <http://dx.doi.org/10.5435/JAAOS-D-14-00289>
18. Samilson RL, Prieto V. Dislocation arthropathy of the shoulder. *J Bone Joint Surg Am* 1983;65:456-60.
19. Sato EJ, Killian ML, Choi AJ, Lin E, Choo AD, Rodriguez-Soto AE, et al. Architectural and biochemical adaptations in skeletal muscle and bone following rotator cuff injury in a rat model. *J Bone Joint Surg Am* 2015;97:565-73. <http://dx.doi.org/10.2106/JBJS.M.01503>
20. Schandelmaier P, Blauth M, Schneider C, Krettek C. Fractures of the glenoid treated by operation. A 5- to 23-year follow-up of 22 cases. *J Bone Joint Surg Br* 2002;84:173-7. <http://dx.doi.org/10.1302/0301-620X.84B2.12357>
21. Scheibel M, Hug K, Gerhardt C, Krueger D. Arthroscopic reduction and fixation of large solitary and multifragmented anterior glenoid rim fractures. *J Shoulder Elbow Surg* 2016;25:781-90. <http://dx.doi.org/10.1016/j.jse.2015.09.012>
22. Scheibel M, Magosch P, Lichtenberg S, Habermeyer P. Open reconstruction of anterior glenoid rim fractures. *Knee Surg Sports Traumatol Arthrosc* 2004;12:568-73. <http://dx.doi.org/10.1007/s00167-004-0495-7>
23. Sugaya H, Moriishi J, Kanisawa I, Tsuchiya A. Arthroscopic osseous Bankart repair for chronic recurrent traumatic anterior glenohumeral instability. *J Bone Joint Surg Am* 2005;87-A:1752-60. <http://dx.doi.org/10.2106/JBJS.M.01503>
24. Tauber M, Moursy M, Eppel M, Koller H, Resch H. Arthroscopic screw fixation of large anterior glenoid fractures. *Knee Surg Sports Traumatol Arthrosc* 2008;16:326-32. <http://dx.doi.org/10.1007/s00167-007-0437-2>
25. Yamamoto N, Itoi E. Osseous defects seen in patients with anterior shoulder instability. *Clin Orthop Surg* 2015;7:425-9. <http://dx.doi.org/10.4055/cios.2015.7.4.425>