



HAL
open science

An unusual intracardiac foreign body following penetrating thoracic injury

Florence Nougarolis, Fatima-Zohra Mokrane, Laurent Brouchet, Norbert
Telmon, Hervé Rousseau, Nicolas Sans, Fabrice Dedouit

► **To cite this version:**

Florence Nougarolis, Fatima-Zohra Mokrane, Laurent Brouchet, Norbert Telmon, Hervé Rousseau, et al.. An unusual intracardiac foreign body following penetrating thoracic injury. *Diagnostic and Interventional Imaging*, 2017, 98 (12), pp.901-902. 10.1016/j.diii.2017.10.001 . hal-02143184

HAL Id: hal-02143184

<https://hal.science/hal-02143184>

Submitted on 29 May 2019

HAL is a multi-disciplinary open access archive for the deposit and dissemination of scientific research documents, whether they are published or not. The documents may come from teaching and research institutions in France or abroad, or from public or private research centers.

L'archive ouverte pluridisciplinaire **HAL**, est destinée au dépôt et à la diffusion de documents scientifiques de niveau recherche, publiés ou non, émanant des établissements d'enseignement et de recherche français ou étrangers, des laboratoires publics ou privés.




Open Archive Toulouse Archive Ouverte (OATAO)

OATAO is an open access repository that collects the work of some Toulouse researchers and makes it freely available over the web where possible.

This is an author's version published in: <https://oatao.univ-toulouse.fr/23080>

Official URL : <https://doi.org/10.1016/j.diii.2017.10.001>

To cite this version :

Nougarolis, Florence and Mokrane, Fatima-Zohra and Brouchet, Laurent and Telmon, Norbert and Rousseau, Hervé and Sans, Nicolas  and Dedouit, Fabrice *An unusual intracardiac foreign body following penetrating thoracic injury.* (2017) *Diagnostic and Interventional Imaging*, 98 (12). 901-902. ISSN 2211-5684

Any correspondence concerning this service should be sent to the repository administrator:
tech-oatao@listes-diff.inp-toulouse.fr

An unusual intracardiac foreign body following penetrating thoracic injury

Keywords Cardiac foreign body; Thoracic trauma; Pericardial sac

Foreign bodies in the heart after thoracic trauma may result in fatal outcome [1]. We report a pendant inside the pericardium after penetrating injury that did not cause major cardiac injury with a favorable outcome.

A 20-year-old woman was admitted to the hospital following a motorcycle traffic accident. She hit a metallic barrier at a speed of 30–50 km/h. Clinical examination revealed several traumatic injuries but her most severe injury was a transfixing thoracic wound. Chest X-ray revealed a right hemopneumothorax, that was subsequently drained (Fig. 1). An unidentified metallic body was detected in the projection of the thoracic spine and the right cardiac silhouette. Computed tomography (CT) showed an intrapericardial metallic foreign body, close to the right atrium. Other traumatic lesions included a longitudinal manubrium fracture, a right sternoclavicular dislocation, and a left drained

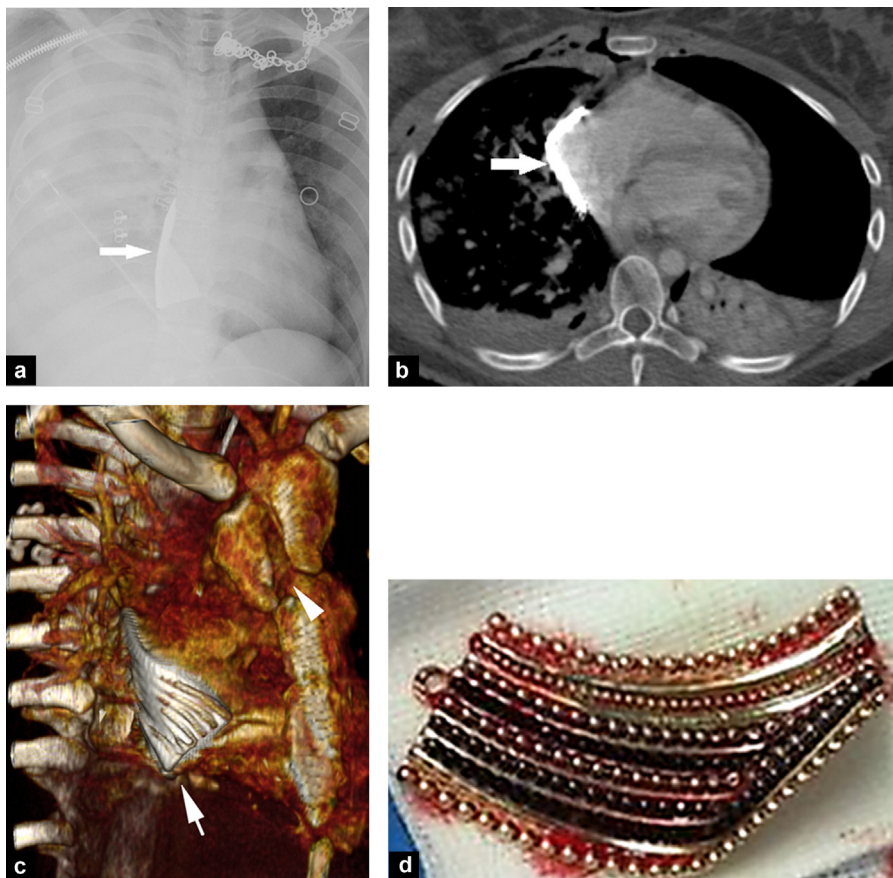


Figure 1. A 20-year-old woman with thoracic injury following motorcycle accident. a: chest X-ray shows a «white right lung» aspect associated with a dense foreign body in contact with the right cardiac border (arrow); b: computed tomography (CT) image of the thorax in the transverse plane shows a thin and regular metallic foreign body (arrow) adjacent to the right atrium accompanied by a left pneumothorax and right pulmonary contusion; c: three-dimensional CT image of the thorax reveals a linear and grooved foreign body (arrow), which is in contact with the heart, associated with a longitudinal sternal fracture (arrowhead); d: photograph shows the guilty pendant immediately after surgical removal.

hemopneumothorax. Exploratory thoracotomy revealed a foreign body nestled against the right cardiac cavities, which was responsible of a slight dissection of the right auriculoventricular junction. The foreign body was a 5-cm pendant. No complications were observed immediately after surgery. The clinical follow-up was uneventful.

Cardiac foreign bodies are rarely seen because most patients with penetrating cardiac injuries die from hemorrhagic shock or cardiac tamponade [1]. The most common foreign bodies that penetrate the heart are bullets and lawnmower projectiles [1]. Their mechanisms are known [2]. In our patient, chest fractures and wounds were due to direct impact. The handlebars of the motorcycle and/or the metallic barrier are the two potential causes of chest injury. Of interest in our patient, the impact to the pendant produced enough strength to cut the clothes, dilacerate the skin, fracture the sternum, and push the object within the anterior mediastinum. This all happened despite the slow speed. The direct impact focused the force on a specific and restricted portion of the sternum, provoking a longitudinal sternum fracture and pushing the pendant inside the thorax. However, there was no major cardiac injury. The foreign body was able to penetrate because of its position in front of an assumably weak anatomical mediastinal area. To our knowledge, only one case has been reported about a foreign body that came in contact with the auriculoventricular junction [3]. In our patient, the foreign body opened the pericardial sac and made its way next to the right heart cavities despite the existence of a large mid-thoracic wound. Our case also highlights the major role of CT in the management of trauma patient [4].

Disclosure of interest

The authors declare that they have no competing interest.

References

- [1] Leitman M, Vered Z. Foreign bodies in the heart. *Echocardiography* 2015;32:365–71.
- [2] Gunn ML, Clark RT, Sadro CT, Linnau KF, Sandstrom CK. Current concepts in imaging evaluation of penetrating transmediastinal injury. *Radiographics* 2014;34:1824–41.
- [3] Harrer J, Holubec T, Brtko M. A foreign body in the heart due to an unusual injury. *Ann Thorac Surg* 2009;88:985–7.
- [4] Daghfous A, Bouzaïdi K, Abdelkefi M, Rebai S, Zoghlemi A, Mbarek M. Contribution of imaging in the initial management of ballistic trauma. *Diagn Interv Imaging* 2015;96:45–55.

F. Nougariolis^{a,*}, F.-Z. Mokrane^b,
L. Brouchet^c, N. Telmon^a, H. Rousseau^b,
N. Sans^d, F. Dedouit^a

^a Forensic Medicine Department, Rangueil University Hospital, 1, avenue du Pr-Jean-Poulhès, TSA 50032, 31059 Toulouse, France

^b Radiology Department, Rangueil University Hospital, 1, avenue du Pr-Jean-Poulhès, TSA 50032, 31059 Toulouse, France

^c Thoracic Surgery Department, Rangueil-Larrey University Hospital, 31059 Toulouse, France

^d Radiology Department, Purpan University Hospital, place du Docteur-Baylac, TSA 40031, 31059 Toulouse, France

* Corresponding author.

E-mail address: florence.nougariolis@gmail.com
(F. Nougariolis)