HAL
open science

Hangman's fracture: Management strategy and healing rate in a prospective multi-centre observational study of 34 patients

Solène Prost, Cédric Barrey, Benjamin Blondel, Stephane Fuentes, Laurent Barresi, Benjamin Nicot, Vincent Challier, Maxime Lleu, Joël Godard, Pascal Kouyoumdjian, et al.

To cite this version:

Solène Prost, Cédric Barrey, Benjamin Blondel, Stephane Fuentes, Laurent Barresi, et al.. Hangman's fracture: Management strategy and healing rate in a prospective multi-centre observational study of 34 patients. Orthopaedics & Traumatology: Surgery & Research, 2019, 105 (4), pp.703-707. 10.1016/j.otsr.2019.03.009 . hal-02143058

HAL Id: hal-02143058

https://hal.science/hal-02143058

Submitted on 29 May 2019

HAL is a multi-disciplinary open access archive for the deposit and dissemination of scientific research documents, whether they are published or not. The documents may come from teaching and research institutions in France or abroad, or from public or private research centers.

L'archive ouverte pluridisciplinaire **HAL**, est destinée au dépôt et à la diffusion de documents scientifiques de niveau recherche, publiés ou non, émanant des établissements d'enseignement et de recherche français ou étrangers, des laboratoires publics ou privés.

Hangman's fracture: Management strategy and healing rate in a prospective multi-centre observational study of 34 patients

Solène Prost [a], Cédric Barrey [b], Benjamin Blondel [a,*], Stéphane Fuentes [a], Laurent Barresi [c], Benjamin Nicot [d], Vincent Challier [e], Maxime Lleu [f], Joël Godard [g], Pascal Kouyoumdjian [h], Nicolas Lonjon [i], Paulo Marinho [j], Eurico Freitas [b], Sébastien Schuller [k], Jérémy Allia [c], Julien Berthiller [l], Yann Philippe Charles [k], French Society for Spine Surgery (SFCR)[m]

[a] *ISM, CNRS, unité de chirurgie rachidienne, Aix-Marseille université, CHU de Timone, AP–HM, 264, rue Saint-Pierre, 13005 Marseille, France*
[b] *Service de neurochirurgie C et chirurgie du rachis, université Claude-Bernard Lyon 1, hôpital P. Wertheimer, 59, boulevard Pinel, 69003 Lyon, France*
[c] *Unité de chirurgie rachidienne, CHU de Nice, Institut universitaire de l'appareil Locomoteur et du sport, hôpital Pasteur 2, 30, voie Romaine, 06001 Nice, France*
[d] *Département de neurochirurgie, CHU de Grenoble, avenue Maquis-du-Grésivaudan, 38700 La Tronche, France*
[e] *Unité d'orthopédie-traumatologie rachis I, CHU de Bordeaux, hôpital Tripode, place Amélie-Raba-Léon, 33076 Bordeaux cedex, France*
[f] *Service de neurochirurgie, CHU de Dijon, 14, rue Paul-Gaffarel, 21000 Dijon cedex, France*
[g] *Service de neurochirurgie, hôpital Jean-Minjoz, 3, boulevard A. Fleming, 25030 Besançon cedex, France*
[h] *Service d'orthopédie-traumatologie, CHU de Nîmes, avenue du Pr. Debré, 30000 Nîmes, France*
[i] *Service de neurochirurgie, hôpital Gui de Chauliac, 80, avenue Augustin-Fliche, 34090 Montpellier, France*
[j] *Service de neurochirurgie, CHRU de Lille, hôpital Roger-Salengro, rue Emile-Laine, 59037 Lille, France*
[k] *Service de chirurgie du rachis, hôpitaux universitaires de Strasbourg, 1, place de l'Hôpital, BP 426, 67091 Strasbourg cedex, France*
[l] *Pôle IMER, hospices civils de Lyon, 162, avenue Lacassagne, 69424 Lyon cedex 03, France*
[m] *Société Française de Chirurgie Rachidienne, 56, rue Boisonnade, 75014 Paris, France*

A B S T R A C T

Background: Hangman's fractures account for 15% to 20% of all cervical spine fractures. The grading system developed by Effendi and modified by Levine and Edwards is generally used as the basis for management decisions. Nonetheless, the optimal management remains controversial. The objective of this study was to describe the treatments used in France in patients with hangman's fractures. The complications and healing rates were analysed according to the fracture type and treatment used.
Hypothesis: Among patients with hangman's fracture, those with disc damage must be treated surgically. *Material and methods:* A prospective, multi-centre, observational study was conducted under the aegis of the French Society for Spine Surgery (*Société Française de Chirurgie Rachidienne*, SFCR). Patients were included if they had computed tomography (CT) evidence of hangman's fracture. Follow-up data were collected prospectively. Fracture healing was assessed on CT scans obtained 3 and 12 months after the injury. The type of treatment and complications were recorded routinely.
Results: We included 34 patients. The fracture type according to Effendi modified by Levine and Edwards was I in 68% of patients, II in 29% of patients, and III in a single patient (3%). The treatment was non-operative in 21 (62%) patients and surgical in 11 (32%). All 28 patients re-evaluated after 1 year had evidence of fracture healing. The remaining 6 patients were lost to follow-up.
Conclusion: Hangman's fracture is associated with low rates of mortality and neurological complications. Non-operative treatment is appropriate in Type I hangman's fracture, with a 100% healing rate in our study. Types II and III are characterised by damage to the ligaments and discs requiring either anterior C2-C3 fusion or posterior C1-C3 screw fixation.
Level of evidence: III.

* Corresponding author. Spine Unit, CHU de Timone, 264, rue Saint-Pierre, 13005 Marseille, France.
E-mail address: benjamin.blondel@ap-hm.fr (B. Blondel).

1. Introduction

C2 fractures are the most common form of cervical spine injury. Their age distribution is bimodal with a peak associated with high-energy traumatic events between 20 and 30 years of age and another peak associated with lower-energy trauma between 70 and 80 years of age.

C2 fractures can be roughly divided into three categories [1]: fractures of the dens (the most common), hangman's fracture involving both pedicles, and atypical fractures (e.g., involving the vertebral body, unilateral, or complex). Hangman's fracture (or bilateral pars interarticularis fracture of C2) is caused by either hyperextension and distraction or hyperextension and compression. The term "hangman's fracture" was coined by Schneider in 1965 [2]. Hangman's fractures account for 15% to 20% of all cervical spine fractures and are often a component of combined atlanto-axial injuries [3,4].

The management strategy for hangman's fracture remains controversial. Treatment decisions are based in part on the type of fracture in the classification devised by Effendi and modified by Levine and Edwards [5,6].

Type I is the most common. Anterior displacement of C2 on C3 is less than 3 mm, and there is little or no angulation relative to the neural arch. The C2-C3 disc is intact. Neurological and vascular injuries are extremely rare. The far less common Type IA fractures constitute a specific category that was described later on as characterised by a fracture line extending into the body of C2, often through the foramen, potentially threatening the vertebral artery; anterior C2 displacement is less than 3 mm, and there is no angulation. The discs and ligaments are intact in Type I fractures.

Type II fractures are characterised by damage to the posterior longitudinal ligament and C2-C3 disc with more than 3.5 mm of anterior C2 displacement on C3 and with angulation relative to the neural arch. The C2-C3 joint capsules are intact. Neurological injuries and damage to the vertebral artery may occur in Type II fractures. Type 2A is characterised by more than 11° of angulation of the C2 body relative to the C2 neural arch and by anterior displacement of C2 on C3.

Type III is very often associated with severe neurological injuries. Destruction of the C2-C3 disc results in complete dislocation of C2 on C3. The neural arch is completely free due to damage to the posterior capsule.

The management strategy depends on the fracture type and on the patient's age and comorbidities. As a rule, non-operative treatment is used if the fracture is stable and surgery if it is unstable. The best treatment in patients with intermediate degrees of instability remains debated [7,8].

The objective of this study was to describe the treatments used in France in patients with hangman's fractures. The complications and healing rates were analysed according to the fracture type and treatment used. The working hypothesis was that, among patients with hangman's fracture, those with disc damage must be treated surgically.

2. Material and Methods

2.1. Study design and patients

This prospective multi-centre observational study of standard care was conducted under the aegis of the French Society for Spine Surgery (*Société Française de Chirurgie Rachidienne*, SFCR). Patients managed for C2 fractures at the university hospitals in Lyon, Strasbourg, Bordeaux, Marseille, Nice, Montpellier, Nîmes, Besançon, Grenoble, Lille, and Dijon (all in France) between July 2014 and October 2015 were identified. No treatment recommendations were made. The inclusion criterion was a diagnosis of hangman's fracture established by examining computed tomography (CT) images acquired with bony windowing and processed using multiplanar reformation.

2.2. Data collection

The data from all the study centres were entered into the same KEOPS database (SMAIO, Lyon, France). Standardised questionnaires were completed for each patient at admission and at the follow-up visits 6 weeks and 3, 6, and 12 months after the injury. The following data were collected prospectively:

- epidemiological data including age, sex, comorbidities, and American Society of Anesthesiology (ASA) score;
- data on the fracture including the level of the fracture (C2), whether other vertebrae were fractured also, and the values measured on the CT scan of the displacement of C2 on C3 and of the C2-C3 kyphosis;
- data on the treatment, i.e., whether the patients received non-operative treatment (Minerva brace and monitoring), immediate surgery (nature of the procedure and postoperative immobilisation method), or delayed surgery;
- data on complications categorised as general medical, infectious, neurological, and mechanical;
- mortality.

Healing was assessed 3 months after the injury by examining a thin-slice (0.6–0.8 mm) bony-windowed CT scan with coronal, sagittal, and axial views. In patients managed non-operatively, the CT findings were used to determine whether use of the Minerva brace could be discontinued. If fracture union could not be confirmed or appeared incomplete after 3 months, fracture healing on a CT scan obtained 1 year after the injury. At the 1-year time point, fracture healing was categorised as complete (no visible fracture line), incomplete (partial residual fracture line), or absent (non-union).

2.3. Statistical analysis

The statistical analysis was performed using SAS software version 9.3 (SAS Institute Inc., Cary, NC, USA). The objective was to assess fracture healing according to age, type of treatment, and type of fracture. Comparisons of qualitative variables relied on the Chi^2 test when the underlying assumptions were met and on Fisher's exact test otherwise. For normally distributed quantitative variables, groups were compared by applying Student's t test after checking equality of variances. Non-normally distributed quantitative variables were compared using the non-parametric Wilcoxon test. All tests were two-tailed, and p-values ≤ 0.05 were taken to indicate significant differences.

3. Results

3.1. Epidemiological data

Of the 417 patients included in the SFCR study of C1-C2 injuries, 34 (8%) had hangman's fractures, 22 females and 12 males with a mean age of 59.1 ± 23 (range, 19–94 years); 23 patients were younger than 70 years of age at the time of the injury. Hangman's fractures accounted for 34 (11.2%) of the 308 C2 fractures.

None of the patients had neurological deficits by physical examination at admission (Frankel E score), and none had evidence of vertebral artery injury on the initial imaging studies.

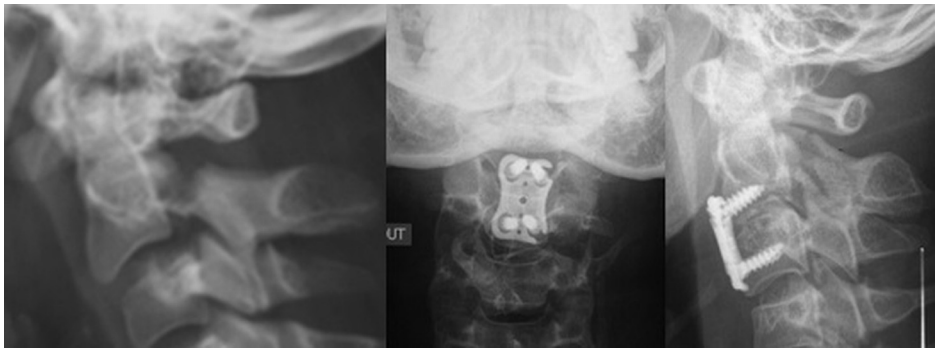

Fig. 1. Type II fracture (left) managed using anterior C2-C3 fusion by grafting and fixation.

Of the 34 patients, 12 (35.3%) had comorbidities, including 4 with heart disease, 4 with hypertension, 3 with a history of vascular events, and 1 with respiratory failure.

3.2. Fracture types

Mean anterior displacement of C2 on C3 was 1.5 ± 1.9 mm (range, 0–9 mm). In 50% of patients, the displacement was between 0 and 2 mm. Mean C2-C3 kyphosis due to the fracture was $4.1 \pm 6.9^\circ$ (range, 0–30°). In 50% of patients, C2-C3 kyphosis was between 0° and 5°. According to the Effendi-Levine/Edwards classification, the fracture type was I in 23 (68%) patients, II in 10 (29%) patients, and III in 1 (3%) patient.

3.3. Management

3.3.1. Non-operative treatment

Of the 34 patients, 21 (62%) were managed only non-operatively, by a Minerva brace with support on the sternum, chin, and occiput. A rigid brace was used in 16 (84%) and a semi-rigid brace in 3 (16%) of these patients. In this subgroup, mean anterior C2 displacement was 0.7 mm (range, 0–1 mm) and mean C2-C3 kyphosis was 0.9° (range, 0–1°). The fracture type was I in 20 patients and II in 1 patient.

3.3.2. Surgery

Surgery was the only treatment used in 11 (32%) of the 34 patients. Of these 11 patients, 8 had an ASA score ≤ 2. Mean anterior displacement of C2 was 3.7 mm (range, 2–4 mm) and mean C2-C3 kyphosis was 11.6° (range, 5–14°). The fracture type was I in 2 patients, II in 8 patients, and III in 1 patient.

In 4 (36.4%) of the 11 patients, surgery consisted in C2-C3 fusion using a cage or iliac crest graft and plate fixation via the anterior approach (Fig. 1). The remaining 7 patients were managed by posterior C1-C3 screw fixation (Fig. 2). A combined anterior and posterior approach was never used.

Fig. 2. Posterior C1-C3 fusion.

3.4. Non-operative treatment followed by surgery

During follow-up, 2 patients initially treated with Minerva bracing subsequently required anterior C2-C3 fusion. Anterior C2 displacement and C2-C3 kyphosis were 0 mm and 5° in 1 of these patients and 3.5 mm and 17° in the other.

3.5. Complications

During follow-up, 2 of the 34 patients experienced complications. In 1 of these patients, who had been managed by posterior fixation, a surgical-site infection required surgical irrigation and appropriate antibiotic therapy, which ensured a favourable outcome. The other patient experienced pulmonary oedema during the postoperative period.

No patient exhibited neurological complications during follow-up. No deaths were recorded. None of the patients managed surgically (whether by the posterior or the anterior approach) experienced mechanical issues related to the fixation material.

3.6. Healing rate

Fracture healing was assessed on a CT scan obtained 3 months after the injury. A second CT scan was obtained 1 year after the injury if the fracture was not healed after 3 months. In the overall population, the CT findings after 3 months indicated complete

healing in 10 patients, including 4 managed by anterior fusion, 4 by posterior fusion, and 2 using a Minerva brace.

After 1 year, the fracture was healed in 28 (82%) of the 34 patients. Healing was complete in 22 patients and incomplete, with partial visibility of the fracture line on the CT scan, in 6 patients. The remaining 6 patients were lost to follow-up. Healing was achieved in all the patients with non-operatively treated Type I fractures.

Due to the absence of patients with CT evidence of non-union, some statistical comparisons were not feasible. Thus, in the overall population of 28 patients re-evaluated after 1 year, fracture healing was consistently achieved, and it was therefore not possible to assess any potential effect of age ($\leq$70 vs. >70 years), initial anterior C2 displacement, type of treatment (non-operative vs. surgical), and approach (anterior vs. posterior).

4. Discussion

Hangman's fractures account for 15% to 20% of cervical spine injuries. This fracture type was first described in individuals sentenced to death by hanging but is now more often due to seatbelt loading during traffic accidents [7,9]. The mortality rate in patients with hangman's fracture due to any cause is 7% at the most [5].

Management decisions in patients with hangman's fracture are chiefly based on the findings from a CT scan of the cervical spine acquired using a bony window, which allows a detailed evaluation of the fracture type according to Effendi-Levine/Edwards [7]. The CT scan may show concomitant lesions, notably of C1 and the C1-C2 junction [3].

The current recommendation is to also obtain a magnetic resonance imaging (MRI) scan with STIR sequences in order to accurately assess damage to all tissues, including the discs and ligaments [9–11]. Furthermore, if the fracture line runs through the transverse foramen or if the anterior displacement of C2 exceeds 3.5 mm, CT-angiography is recommended to look for concomitant injuries to the vertebral arteries [12].

The evaluation of fracture stability based on the Effendi-Levine/Edwards classification guides the choice between non-operative and surgical treatment [6].

Non-operative treatment should be reserved for Type I fractures, which are stable, in patients free of neurological abnormalities. Non-operative treatment in this indication has produced good outcomes with high healing rates. The abundant blood supply to the C2 lateral masses and their chiefly cancellous composition may explain the effectiveness of non-operative treatment [7,9,13]. Several rules should be followed to optimise healing rates. Thus, Minerva bracing should be reserved for patients in whom both anterior displacement of C2 and C2-C3 kyphosis are absent or minimal. A halo can be used when there is a small anterior displacement and minimal degree of kyphosis but requires close follow-up to monitor fracture healing and to determine whether surgical treatment is required.

The surgical treatment of hangman's fractures remains poorly standardised. None of the available clinical studies showed significant differences in outcomes or complication rates between the various types of anterior and/or posterior fusion. In published studies, posterior fixation seems to have been used more often for Type II and Type IIA fractures. For Type III fractures, anterior and posterior fusion seem to have been used in similar proportions of cases [7,14–16]. In our study, the time to healing was shorter in the patients managed with anterior fusion, although the difference with posterior fusion was not statistically significant.

A biomechanical in vitro study compared the mechanical strength of posterior fusion by C2-C3 screw fixation, anterior H-plate fixation, and anterior locking plate fixation in human cadavers [17]. The constructs were subjected to cycles of flexion-extension, lateral inclination, and axial rotation, after which C2-C3 motion ranges were measured. The two anterior fusion methods were associated with greater stiffness, suggesting that posterior transpedicular fixation according to Judet may be best reserved for C2-C3 injuries with no damage to the discs or ligaments.

In our population, 4 patients were managed with anterior fusion and 7 with posterior fusion (C2-C3 or C1-C3). We found no significant difference between anterior and posterior fusion. Screw fixation of fractured and displaced C2 pedicles seems challenging and hazardous. C1-C3 fusion may be excessive and unnecessary in most cases.

Published data indicate that the anterior approach not only provides better dynamic stabilisation but also prevents delayed neurological compromise related to post-traumatic disc herniation. Other advantages include a lower risk of intra-operative vertebral artery injury [5–7,10,15,18] and preservation of C1-C2 mobility and, therefore, of most of the movements at the cervical spine [7].

Several posterior fixation techniques have been reported and are currently used. Transpedicular screw fixation of C2 is the most popular, because it is perceived as more closely restoring normal anatomy. Simple C2 transpedicular screw fixation preserves mobility at all the cervical spine segments but fails to correct C2-C3 instability. In several case-series studies, healing rates were above 90% with this technique. The main risk is injury to the vertebral artery [7,19,20]. We believe that C2 transpedicular screw fixation used alone has virtually no indications now, as the situation in which this technique is appropriate, i.e., hangman's fracture without C2-C3 instability, consistently responds to non-operative treatment.

The other posterior fixation technique is C1-C3 pedicle screw fixation. This technique is less often used because it requires a more extensive approach. It blocks the C1-C2 joint, thereby considerably restricting range of motion, particularly in rotation C1-C2 [7]. Percutaneous screw fixation techniques navigated using 3D intra-operative imaging are being developed and may prove of considerable interest for decreasing the risk of screw malposition, while also diminishing the complication rate, due to the smaller incision and muscle detachment [20,21].

The limitations of this study include the small sample size and observational design. Nevertheless, our results suggest a number of recommendations regarding the management of hangman's fractures. In patients with Type I fractures, non-operative treatment provides excellent healing rates and is therefore reasonable. Primary anterior C2-C3 fusion ensures healing in patients with Type II or III fractures.

5. Conclusion

Mortality is low and neurological complications are uncommon in patients with hangman's fractures. Surgical decisions rest on an assessment of fracture displacement and of concomitant damage to the discs and ligaments. Surgery is mandatory in patients with residual displacement after closed reduction and in those with damage to discs and/or ligaments.

Disclosure of interest

The authors declare that they have no competing interest.

Funding

Support was received from the French Society for Spine Surgery (*Société Française de Chirurgie Rachidienne*, SFCR).

Contributions

Solène Prost, Benjamin Blondel, Cédric Barrey, and Yann Philippe Charles coordinated the study and wrote the manuscript.

Stéphane Fuentes, Laurent Barresi, Benjamin Nicot, Vincent Challier, Maxime Lleu, Joel Godard, Pascal Kouyoumdjian, Nicolas Lonjon, Paolo Marinho, Eurico Freitas, Sébastien Schuller, and Jérémy Allia were the study investigators and included the patients.

Julien Berthiller performed the statistical analyses.

References

[1] Robinson A-L, Möller A, Robinson Y, Olerud C. C2 Fracture subtypes, incidence, and treatment allocation change with age: a retrospective cohort study of 233 consecutive cases. BioMed Res Int 2017:8321680.

[2] Schneider RC, Livingston KE, Cave AJ, Hamilton G. "Hangman's fracture" of the cervical spine. J Neurosurg 1965;22:141–54.

[3] Chaudhary SB, Martinez M, Shah NP, Vives MJ. Traumatic atlantoaxial dislocation with Hangman fracture. Spine J 2015;15:15–8.

[4] Morel E, Ilharreborde B, Zadegan F, Rillardon L, Guigui P. An unusual Hangman's fracture: description and surgical management. Orthop Traumatol Surg Res 2009;95:229–33.

[5] Effendi B, Roy D, Cornish B, Dussault RG, Laurin CA. Fractures of the ring of the axis. A classification based on the analysis of 131 cases. J Bone Joint Surg Br 1981;63:319–27.

[6] Levine AM, Edwards CC. The management of traumatic spondylolisthesis of the axis. J Bone Joint Surg Am 1985;67:217–26.

[7] Li X-F, Dai L-Y, Lu H, Chen X-D. A systematic review of the management of hangman's fractures. Eur Spine J 2006;15:257–69.

[8] Gleizes V, Jacquot FP, Signoret F, Feron JM. Combined injuries in the upper cervical spine: clinical and epidemiological data over a 14-year period. Eur Spine J 2000;9:386–92.

[9] Wu Y-S, Lin Y, Zhang X-L, Tian N-F, Sun L-J, Xu H-Z, et al. Management of hangman's fracture with percutaneous transpedicular screw fixation. Eur Spine J 2013;22:79–86.

[10] Duggal N, Chamberlain RH, Perez-Garza LE, Espinoza-Larios A, Sonntag VKH, Crawford NR. Hangman's fracture: a biomechanical comparison of stabilization techniques. Spine 2007;32:182–7.

[11] Ryken TC, Hadley MN, Aarabi B, Dhall SS, Gelb DE, Hurlbert RJ, et al. Management of isolated fractures of the axis in adults. Neurosurgery 2013;72:132–50.

[12] Fassett DR, Dailey AT, Vaccaro AR. Vertebral artery injuries associated with cervical spine injuries: a review of the literature. J Spinal Disord Tech 2008;21:252–8.

[13] Sherk HH, Howard T. Clinical and pathologic correlations in traumatic spondylolisthesis of the axis. Clin Orthop 1983;174:122–6.

[14] Moon MS, Moon JL, Moon YW, Sun DH, Choi WT. Traumatic spondylolisthesis of the axis: 42 cases. Bull Hosp Jt Dis 2001;60:61–6.

[15] Müller EJ, Wick M, Muhr G. Traumatic spondylolisthesis of the axis: treatment rationale based on the stability of the different fracture types. Eur Spine J 2000;9:123–8.

[16] Ferro FP, Borgo GD, Letaif OB, Cristante AF, Marcon RM, Lutaka AS. Traumatic spondylolisthesis of the axis: epidemiology, management and outcome. Acta Ortop Bras 2012;20:84–7.

[17] Arand M, Neller S, Kinzl L, Claes L, Wilke HJ. The traumatic spondylolisthesis of the axis. A biomechanical in vitro evaluation of an instability model and clinical relevant constructs for stabilization. Clin Biomech 2002;17:432–8.

[18] Samaha C, Lazennec JY, Laporte C, Saillant G. Hangman's fracture: the relationship between asymmetry and instability. J Bone Joint Surg Br 2000;82:1046–52.

[19] ElMiligui Y, Koptan W, Emran I. Transpedicular screw fixation for type II Hangman's fracture: a motion preserving procedure. Eur Spine J 2010;19:1299–305.

[20] Taller S, Suchomel P, Lukás R, Beran J. CT-guided internal fixation of a hangman's fracture. Eur Spine J 2000;9:393–7.

[21] Ould-Slimane M, Ferracci F-X, Le Pape S, Perez A, Michelin P, Gauthé R. Posterior C1C2 harms fusion with 3D surgical navigation. Orthop Traumatol Surg Res 2018;104:585–8.