



HAL
open science

Evolutionary Tinkering of the Mandibular Canal Linked to Convergent Regression of Teeth in Placental Mammals

Sérgio Ferreira-Cardoso, Frédéric Delsuc, Lionel Hautier

► **To cite this version:**

Sérgio Ferreira-Cardoso, Frédéric Delsuc, Lionel Hautier. Evolutionary Tinkering of the Mandibular Canal Linked to Convergent Regression of Teeth in Placental Mammals. *Current Biology - CB*, 2019, 29 (3), pp.468-475.e3. 10.1016/j.cub.2018.12.023 . hal-02140102

HAL Id: hal-02140102

<https://hal.science/hal-02140102>

Submitted on 27 May 2019

HAL is a multi-disciplinary open access archive for the deposit and dissemination of scientific research documents, whether they are published or not. The documents may come from teaching and research institutions in France or abroad, or from public or private research centers.

L'archive ouverte pluridisciplinaire **HAL**, est destinée au dépôt et à la diffusion de documents scientifiques de niveau recherche, publiés ou non, émanant des établissements d'enseignement et de recherche français ou étrangers, des laboratoires publics ou privés.

1 **Evolutionary tinkering of the mandibular canal linked to convergent**
2 **regression of teeth in placental mammals**

3

4 **Sérgio Ferreira-Cardoso^{1,*}, Frédéric Delsuc^{1,3} and Lionel Hautier^{1,2,*}**

5

6

7 **Author list footnotes**

8 ¹Institut des Sciences de l'Evolution de Montpellier (ISEM), CNRS, IRD, EPHE, Université de
9 Montpellier, Montpellier, France.

10 ²Mammal Section, Life Sciences, Vertebrate Division, The Natural History Museum, London,
11 UK

12 ³Lead contact

13 *Correspondence: sergio.ferreira-cardoso@umontpellier.fr and lionel.hautier@umontpellier.fr

14

15

16

17

18

19

20 **SUMMARY**

21 Loss or reduction of teeth has occurred independently in all major clades of mammals [1]. This
22 process is associated with specialized diets, such as myrmecophagy and filter feeding [2,3], and
23 led to an extensive rearrangement of the mandibular anatomy. The mandibular canal enables
24 lower jaw innervation through the passage of the inferior alveolar nerve (IAN) [4,5]. In order to
25 innervate teeth, the IAN projects ascending branches directly through tooth roots [6,5], bone
26 trabeculae [6], or bone canaliculi (i.e. dorsal canaliculi) [7]. Here, we used micro-computed
27 tomography (μ -CT) scans of mandibles, from eight myrmecophagous species with reduced
28 dentition and 21 non-myrmecophages, to investigate the evolutionary fate of dental innervation
29 structures following convergent tooth regression in mammals. Our observations provide strong
30 evidence for a link between the presence of tooth loci and the development of dorsal canaliculi.
31 Interestingly, toothless anteaters present dorsal canaliculi and preserve intact tooth innervation
32 while equally toothless pangolins do not. We show that the internal mandibular morphology of
33 anteaters has a closer resemblance to that of baleen whales [7] than to pangolins. This is
34 despite masticatory apparatus resemblances that have made anteaters and pangolins a
35 textbook example of convergent evolution. Our results suggest that early tooth loci innervation
36 [8] is required for maintaining the dorsal innervation of the mandible and underlines the dorsal
37 canaliculi sensorial role in the context of mediolateral mandibular movements. This study
38 presents a unique example of convergent redeployment of the tooth developmental pathway to a
39 strictly sensorial function following tooth regression in anteaters and baleen whales.

40 **Keywords**

41 Mandibular canal; edentulous; Convergence; Mammals; Homology.

42

43 Results

44 Evolution of dorsal canaliculi after tooth regression

45 Three-dimensional (3D) models of the mandibles, teeth, and mandibular canals of 26 species
46 were investigated (Figure 1, S1-2). Detailed anatomical descriptions of the mandibular canal in
47 each myrmecophagous species and sister taxa are provided as Supplemental Information
48 (Figures S1, Data S1). A summary description of additional species used to reconstruct the
49 ancestral condition of placental mammals is provided as Supplemental Information (Figure S2,
50 Data S1). For cetacean comparisons, we used a dataset that was recently published by Peredo
51 *et al.* [7]. All toothed mammals get teeth innervated and vascularized, but this
52 innervation/vascularization only occasionally happens through dorsal canaliculi. These canaliculi
53 correspond to narrow tubular channels that connect the mandibular canal to tooth alveoli (Figure
54 2E and F). The teeth of the giant otter shrew (*Potamogale velox*), the aardwolf (*Proteles*
55 *cristatus*) and the dog (*Canis lupus*) are rooted in close contact with the mandibular canal, with
56 alveoli often surrounded by trabecular bone (Figures 1, S1I,J and N). The investigated additional
57 species revealed similar patterns with either deeply rooted teeth or trabeculae surrounding the
58 alveoli (or both; See SI; Figure S2). These species all lack dorsal canaliculi, even for dorsally
59 implanted teeth (e.g., aardwolf molars) (Figure S1I). Dorsal canaliculi were present in three
60 (Pilosa, Cingulata and Tubulidentata) out of the 18 mammals orders sampled (including one
61 marsupial). Ancestral reconstruction unambiguously showed that the absence of dorsal
62 canaliculi likely represents the ancestral condition in placental mammals where alveolar
63 branches (IAN and inferior alveolar artery, IAA) pass through the trabecular structure of the bone
64 or directly through tooth roots. In contrast, armadillos (*Dasybus novemcinctus*, *D. pilosus*, and
65 *Priodontes maximus*), sloths (*Bradypus tridactylus* and *Choloepus hoffmanni*), and the aardvark
66 (*Orycteropus afer*), present dorsal canaliculi (Figures 1, 2E,F, 3C,D, S1, S4), the so-called
67 “dorsal branches” as previously described in baleen whales [7], whose dorsoventral length

68 increases as the tooth is implanted further from the mandibular canal (Figure 2E and F). Most of
69 these dorsal canaliculi are located in the anterior part of the mandible where teeth are reduced
70 or simply missing. In the nine-banded armadillo, we observed one anterior dorsal canaliculus
71 that divides to open in four dorsal foramina (Figures 1, S1F), while in the hairy long-nosed
72 armadillo we observed a dorsal canaliculus that divides in a plexus of three branches (Figures 1,
73 S1G). In the aardvark, three free dorsal canaliculi split and open in six dorsal foramina (Figures
74 1, S1M). Intraspecific variation was detected and described (Figure S4; see SI), but the
75 presence and pattern of dorsal canaliculi is always consistent among specimens. Ontogenetic
76 variation was studied in two species of sloths in which fetuses display dorsal canaliculi
77 associated with vestigial teeth loci (Figure 3A,B). These dorsal canaliculi are still present in
78 adults of both species despite the resorption of vestigial teeth (Figure 3C,D).

79 Surprisingly, toothless species (anteaters and pangolins) display contrasted mandibular
80 canal morphologies (Figures 1, 2). All three investigated anteater species present dorsal
81 canaliculi that open in small foramina (Figures 3A-C, S1A-C). These foramina are placed along
82 the anterior flattened dorsal margin of the mandible, which defines the dental pad, with only
83 limited intraspecific and bilateral variations among specimens of the three species (Figure S4).
84 Ontogenetic variation is equally limited, with similar patterns of dorsal canaliculi being observed
85 in both adults and juvenile giant anteaters (*M. tridactyla*, Figure S4L, M and N) and nine-banded
86 armadillos (*D. novemcinctus*, Figure S4A-F). Conversely, pangolins lack dorsal canaliculi (Figure
87 3D), with only several minute canaliculi that are parallel to the mandibular canal, both dorsally
88 and ventrally, but rarely connected to it (Figure 1). Foramina associated to these parallel
89 canaliculi are scarce, invisible to the naked eye, and only occasionally open dorsally to the
90 mandibular canal.

91

92 **Histological evidence for the passage of nerves and blood vessels in dorsal canaliculi**

93 Three-dimensional analyses were complemented by histological series, which enabled to
94 identify internal soft structures associated to the dorsal canaliculi. The LFB (see Method details
95 in STAR methods) stained histological slices of the collared anteater (*T. tetradactyla*) mandible
96 enabled us to describe the soft tissues encapsulated in the mandibular canal (Figure 4). We
97 observed dorsal canaliculi that allow for the passage of an ascending branch of the inferior
98 alveolar nerve (IANab; Figure 4C,C'), of the inferior alveolar artery (IAAab; Figure 4C), and of
99 the inferior alveolar vein (IAVab; Figure 4B'). In *T. tetradactyla*, a keratinous dental pad (pa)
100 covers the dorsal part of the mandible (Figure 4C). Ventrally, the epidermis (ep) consists of a
101 small layer (Figure 4C), which lies dorsally to a thick dermis layer (de; Figure 4C). In addition to
102 connective tissue, this dermis layer presents small blood vessels and nerve branches.
103 Histological slices of bowhead whale [9] (Figure S3) show a similar structuration of soft tissues,
104 with accessory branches and large IAN and IAA that most likely connect the mandibular canal to
105 the vestigial tooth alveoli through dorsal canaliculi. The histological section [9] suggests a
106 pronounced anterior projection of the dorsal canaliculi, similar to the pattern for the IAN
107 ascending branches in odontocetes [4].

108

109 **Discussion**

110 **Shadows of regressed tooth buds in dorsal canaliculi**

111 Enamelless sloths, armadillos, and aardvarks all present dorsal canaliculi that are associated
112 with either tooth alveoli or vestigial tooth loci in the anterior part of the mandible. The
113 corresponding nervous and vascular ascending branches should then be considered
114 homologous to alveolar branches. If the number and shape of alveolar branches can vary [6,10],
115 especially in terminal bifurcations, each main alveolar branch usually corresponds to a single
116 tooth root [6]. Establishing the direct homology between ascending and alveolar branches in
117 anteaters is hindered by the absence of teeth. However, their closest relatives, sloths and
118 armadillos, as well as the aardvark, also display some anterior dorsal canaliculi with no apparent

119 connection to tooth alveoli (Figures 1, 2, S1, S2). Long-nosed armadillos present dorsal
120 canaliculi in the anterior part of the mandible and the anterior most alveoli, while sloths present
121 minute dorsal canaliculi in cheek teeth. This suggests that dorsal canaliculi likely evolved
122 concomitantly with tooth simplification in cingulatan and pilosans. All these species have been
123 shown to display vestigial tooth buds in the anterior part of the mandible during pre-natal
124 development [11–13]. The observed pattern of anterior dorsal canaliculi in long-nosed armadillos
125 (*Dasypus*) and the armadillo roughly matches the distribution of previously described vestigial
126 teeth [12,14–16]. In nine-banded armadillos, we found dorsal canaliculi that consistently split into
127 three to six distinct dorsal foramina in the anterior part of the mandibles (Figure 1, S1F,S4A-F),
128 while Martin [12] identified five to six vestigial incisors. This difference is not surprising given the
129 frequent dental formula variation observed in nine-banded armadillos [17]. The observed
130 variation in dorsal canaliculi count of anteaters and nine-banded armadillos (Figures 1, S4) was
131 to be expected as the number and shape of alveolar branches vary in humans [6,10], both at the
132 intraspecific and bilateral levels. This variation also matches the variation observed in tooth
133 count of placentals showing a reduced dentition such as the armadillo [13], long-nosed
134 armadillos [17] and the giant armadillo [18]. Such bilateral variation in tooth number might result
135 from the lack of stabilizing selection due to an absence of strict occlusion, as hypothesized for
136 mysticetes [9]. In the armadillo [15], the lower milk dentition is normally composed of eight to ten
137 teeth, with the second generation of teeth varying from five to eight in number depending on the
138 presence of vestigial anterior premolars and canines [15,16]. We found dorsal canaliculi that
139 could correspond to two-four anterior premolars, one canine and three incisors (Figure S1M).
140 This number coincides with the deciduous dental formula of the armadillo [13]. Our observations
141 therefore provide convincing evidence for a link between the presence of teeth, vestigial or not,
142 and the development of dorsal canaliculi.

143 This developmental link was corroborated by the study of ontogenetic series of both extant
144 sloth genera. Comparisons between sloth pre- and post-natal stages allowed us to directly

145 associate one long anterior dorsal canaliculus to a vestigial tooth locus (Figure 3), which is
146 resorbed during development and is absent in adults. Based on histological sections (Figure 4),
147 we showed that ascending branches of the IAN and IAA pass through dorsal canaliculi in the
148 collared anteater (*T. tetradactyla*). Teeth innervation was likely retained after tooth resorption in
149 all pilosans, and this could extend to all xenarthrans if we consider the anterior dorsal canaliculi
150 of armadillos as representative of vestigial tooth loci. Wadu *et al.* [6] showed that human tooth
151 nerve bundles can also be retained – although slightly reduced – after tooth loss induced by
152 senescence. Our observations of histological sections of toothless whale fetuses (see [9] and SI,
153 Figure S3) suggest that vestigial tooth loci are associated to IAN and IAA ascending branches
154 during development, a situation that mirrors the condition observed in toothed cetaceans [4,5].
155 Ridgway *et al.* [4] described an elongation of the ascending branches of the inferior alveolar
156 nerve in dolphins, while an anterodorsal inclination was also reported for the dorsal canaliculi of
157 mysticetes [7]. However, the homology between alveolar branches and ascending branches
158 carried by dorsal canaliculi was recently challenged for whales [7]. Instead, Peredo *et al.* [7]
159 proposed that dorsal canaliculi and associated foramina constitute a derived character of crown
160 Mysticeti since no internal evidence of such a structure was visible in other edentulous taxa [7].
161 Our results clearly contradict this assertion, as we showed that anteaters display both foramina
162 and dorsal canaliculi. In our view, the ascending branches of IAN and IAA should be considered
163 as homologous to alveolar branches since they include identical structures and are linked to the
164 development of teeth. This implies that dorsal canaliculi evolved convergently in xenarthrans,
165 aardvarks, and baleen whales following tooth reduction.

166 Unlike the other toothless species investigated, pangolins do not present dorsal canaliculi in
167 their mandibles. The small parallel canaliculi (Figure S1D,E) present a distinct shape and
168 topology hindering a hypothetical homology with the dorsal canaliculi. Tims [19] reported the
169 presence of 13 to 14 tooth rudiments in the mandible of *M. javanica*, which he also compared to
170 hair follicles. However, the observed number of up to four tooth vestiges per coronal slice [19]

171 seems inconsistent with the position of the teeth along an anteroposterior axis. Unless *M.*
172 *javanica* presents four tooth generations, no more than two tooth buds should be expected for
173 each coronal slice [9,20]. In this context, the 13-14 teeth reported by Tims (1908) should be
174 considered with caution and might correspond to distinct structures. The lack of tooth buds [21]
175 might therefore explain the absence of dorsal canaliculi. Although an early dental lamina may be
176 present in pangolin embryos [14,19], its development appears to be drastically reduced when
177 compared to anteaters [21]. On the other hand, the lack of these structures in pangolins could
178 be explained by phylogenetic constraints. Since dorsal canaliculi are also absent in carnivorans
179 (Figures 1, S1I,J), their absence might represent the ancestral state for Ferae (Pholidota +
180 Carnivora). Additionally, complete tooth loss probably happened much earlier in pangolins than
181 in anteaters, since the almost certainly toothed most recent common ancestor (MRCA) of Pilosa
182 (~58 Mya, [22]) is much more recent than the MRCA of Ferae (~80 Mya; [23]). With the oldest
183 fossil pangolin (~45 Mya,[24]) being already toothless, the absence of dorsal canaliculi in
184 pangolins might simply reflect a more ancient tooth loss. Importantly, our study shows that the
185 external resemblances of the mandibles in anteaters and pangolins, which made them a
186 textbook example of convergent evolution, have overshadowed the complex evolution of their
187 internal morphology.

188

189 **Functional role of dorsal canaliculi in toothless species**

190 Previous studies proposed that mammalian teeth might play a sensorial role in detecting a wide
191 array of external stimuli including pressure, proprioception, and percussion [25] in addition to
192 their role for food intake. Our results suggest that the development of dorsal canaliculi might be
193 linked to the presence of tooth loci/vestigial teeth in both anteaters and baleen whales. One
194 puzzling fact however is that the development of vestigial teeth remained preserved for so long
195 during the evolutionary history of these taxa. In sloths, Hautier *et al.* [11] showed that the
196 mineralization and resorption of the vestigial teeth is an integral part of prenatal dental

197 development. Given the conservatism of sloth dental formula in the fossil record [26], they
198 proposed that these vestiges were kept for at least 30 million years [22,26], which implies that
199 there is still a strong selective pressure for developing these structures. Such a complex and
200 energetically costly developmental pathway might be the consequence of a strong
201 developmental constraint in preserving the associated innervation and vascularization of the
202 mandible. A similar developmental constraint was proposed for the initial development of a
203 normal eye in blind cavefish [27]. These fish present normal eye development before showing
204 sign of later degeneration. Given that there is no separation between cells giving rise to the
205 retina and to the forebrain at the early stage of the nervous system (neural plate stage), the
206 development of a viable embryo with a well-formed forebrain implies the early development of
207 the eyes [27]. Tooth innervation develops synchronously with tooth development, being
208 controlled by local molecular signals [8]. We therefore argue that tooth development, even in
209 initiation stages, might be required for maintaining the dorsal innervation of the mandible. As a
210 matter of fact, embryos of pygmy anteaters present early tooth development (dental lamina-tooth
211 buds) [21,28].

212 Histological slices allowed revealing the presence of dorsal projections of the IAN and IAA
213 passing through the dorsal canaliculi in a mandible of the collared anteater. We propose that
214 these structures respectively innervate and vascularize the mandibular keratinous pad that
215 covers most of the dorsal margin of the horizontal ramus (Figure 4C). The oral sensory receptors
216 that project via the IAN (a branch of the trigeminal nerve) may confer a somatosensory role to
217 the mandibular keratinous pad. In fact, the pattern of innervation of this keratinous pad
218 resembles that of bird beak [29]. Both structures display a superficial keratinous layer followed
219 dorsally by epidermis and a large dermis with blood vessels and free nerve endings [29] (Figure
220 4). Early tooth development (bud stage) was previously reported in anteaters [21]. In birds, the
221 keratinous ramphoteca was proposed to be responsible for the early interruption of
222 odontogenesis at the lamina stage [30]. An early keratinization might be the triggering event for

223 subsequent odontogenesis disruption during the development of both anteater keratinous pad
224 and bird beak. Interestingly, toothless whales also present keratinous structures (baleens) that
225 develop after odontogenesis interruption [9]. Thewissen *et al.* [9] argued that tooth development
226 is a *sine qua non* condition to the development of baleens. This is in line with both fossil and
227 molecular evidence suggesting a step-wise transition between teeth and baleen in mysticetes
228 [3]. Ekdale *et al.* [31] also recently suggested that foramina for baleen vascularization in the
229 upper jaw of toothless whales are likely homologous to tooth alveoli. Similarly, odontogenesis
230 and associated dorsal canaliculi might be a prerequisite for mandibular keratinization in
231 anteaters. Accordingly, the lack of keratinous pad and vestigial teeth might explain the absence
232 of dorsal canaliculi in pangolins.

233 In rorqual whales, the peculiar distribution of dorsal canaliculi along the mandible was
234 proposed to be related to movement coordination of lower jaws and alignment with the baleen
235 plates during filter feeding [7]. Pyenson *et al.* [32] argued that nerves passing through the most
236 anterior canaliculus connected the brain to a symphyseal organ/vibrissae system responsible for
237 mandibular motor coordination and prey detection, respectively. Given the absence of external
238 vibrissae in anteaters and the fact that they mainly use olfaction to detect their prey [33], dorsal
239 canaliculi and respective extensions of the IAN are unlikely related to prey detection. However,
240 several studies [34 and references therein] described the synchronization between tongue
241 protrusion and mandible closing during feeding in anteaters (i.e. *Myrmecophaga* and *Tamandua*)
242 as well as in ant-eating echidnas. In these groups, the mandibles rotate medio-laterally, with the
243 oral cavity widening when the tongue is retracted and narrowing when it is protruded, forming a
244 tube-like mouth to serve as physical support [34,35]. This type of integrated movement would
245 require a tactile feedback originating from the dorsal margin of the mandible, which is in contact
246 with the protruding tongue and the upper jaw. A similar hypothesis has been proposed in whales
247 [7] for the coordination between mandibles and baleens during gulping. Tooth pulp stimulation
248 was shown to trigger a response of the digastric muscle in cats [36]. Dong *et al.* [37] also

249 showed that cat teeth stimulation results in discharge signatures for different textures (e.g.,
250 rough or smooth). Furthermore, teeth are known to respond to non-painful stimuli in humans
251 [38]. We propose that the ascending branches of the IAN might be part of the somatosensory
252 system involved in mechanoreception, which could explain the convergent evolution of dorsal
253 canaliculi in the toothless mandibles of baleen whales and anteaters. In contrast, no medio-
254 lateral rotation of the mandibles was reported in pangolins [35], while the presence of a fused
255 symphysis likely helps maintaining the tube-like shape of the oral cavity while feeding [39].
256 Compared to anteaters and baleen whales, such a relatively reduced mandibular mobility could
257 potentially explain the absence of dorsal canaliculi in pangolins.

258 Our results support the hypothesis of convergent exaptation of the dorsal canaliculi in
259 anteaters and baleen whales following tooth regression. We unequivocally showed that the IAN
260 as well as blood vessels branch through the dorsal canaliculi, and argue that keratinous
261 structures and vestigial teeth have a crucial role in mandibular innervation, maintaining the
262 sensorial function associated to the presence of teeth while strong selective pressures induced
263 their loss. Despite the superficial resemblance of the masticatory apparatus between anteaters
264 and pangolins, convergent tooth loss resulted in divergent structures in the internal morphology
265 of their mandible. We propose that these differences likely reflect divergent phylogenetic
266 histories and/or divergent functional constraints. Rewiring of the mandibular canal in anteaters
267 and baleen whales provides a striking example of evolutionary tinkering linked to the regression
268 of teeth.

269

270 **Acknowledgements**

271 We thank Steffen Bock, Peter Giere, Frieder Mayer, and Detlef Willborn (MfN), Roberto Portela
272 Miguez, Louise Tomsett, Farah Ahmed, Amin Garbout, and Brett Clark (BMNH), Renaud

273 Lebrun, François Catzeflis, Pierre-Henri Fabre, and Quentin Martinez (ISEM), Guillaume Billet
274 (MNHN), and Chris Conroy (MVZ) for access to collections and assistance with μ -CT scanning.
275 We also thank Pierre-Henri Fabre, Chris Emerling, and two anonymous reviewers for helpful
276 comments on the manuscript, and Quentin Martinez, Mélanie Debiais-Thibaud, and Helder
277 Gomes Rodrigues for fruitful discussions. We acknowledge J.G.M. Thewissen and the North
278 Slope Borough Department of Wildlife Management for Figure S3A. We thank Nelly Pirot,
279 Florence Bernex, and Marion Olive (INSERM) for assistance with histology. Finally, we thank
280 Sarah Jones who helped to improve the English of the manuscript. S.F.-C., L.H. and F.D. were
281 supported by a European Research Council (ERC) consolidator grant [ConvergeAnt #683257].
282 S.F.C. benefitted from the SYNTHESYS Project (Project 312253) founded by the European
283 Community Research Infrastructure Action under the FP7 Integrating Activities Programme. L.H.
284 and F.D. were supported by Centre National de la Recherche Scientifique (CNRS). This work
285 has been supported by “Investissements d’Avenir” grants managed by Agence Nationale de la
286 Recherche Labex CEBA (ANR-10-LABX-25-01), Labex CEMEB (ANR-10-LABX-0004), and
287 Labex NUMEV (ANR-10-LABX-0020). This is contribution ISEM 2018-275 of the Institut des
288 Sciences de l’Evolution de Montpellier.

289 **Author contributions**

290 S.F.-C., L.H., F.D. collected the data, conceived the study, designed the study. S.F.-C., L.H.,
291 F.D. contributed to discussion, drafted and edited the manuscript. L.H., F.D. coordinated the
292 study. All authors gave final approval for publication.

293 **Declaration of Interests**

294 The authors declare no competing interest.

295 **References**

- 296 1. Meredith, R.W., Gatesy, J., Murphy, W.J., Ryder, O.A., and Springer, M.S. (2009).
297 Molecular decay of the tooth gene enamelin (ENAM) mirrors the loss of enamel in the
298 fossil record of placental mammals. *PLoS Genet.* 5, e1000634.
- 299 2. Meredith, R.W., Gatesy, J., and Springer, M.S. (2013). Molecular decay of enamel matrix
300 protein genes in turtles and other edentulous amniotes. *BMC Evol. Biol.* 13, 20.
- 301 3. Deméré, T.A., McGowen, M.R., Berta, A., and Gatesy, J. (2008). Morphological and
302 molecular evidence for a stepwise evolutionary transition from teeth to baleen in mysticete
303 whales. *Syst. Biol.* 57, 15–37.
- 304 4. Ridgway, S.H., Green, R.F., and Sweeney, J.C. (1975). Mandibular anesthesia and tooth
305 extraction. *J. Wildl. Diseases* 11, 415–418.
- 306 5. Gray, H. (1995). *Anatomy, descriptive and surgical* (Bristol: Parragon Book Service Ltd.).
- 307 6. Wadu, S.G., Penhall, B., and Townsend, G.C. (1997). Morphological variability of the
308 human inferior alveolar nerve. *Clin. Anat.* 10, 82–87.
- 309 7. Peredo, C., Pyenson, N., Uhen, M., and Marshall, C. (2017). Alveoli, teeth, and tooth loss:
310 understanding the homology of internal mandibular structures in mysticete cetaceans.
311 *PLoS One* 12.
- 312 8. Fried, K., Lillesaar, C., Sime, W., Kaukua, K., and Patarroyo, M. (2007). Target finding of
313 pain nerve fibers: neural growth mechanisms in the tooth pulp. *Physiol. Behav.* 92, 40–45.

- 314 9. Thewissen, J.G.M., Hieronymus, T.L., George, J.C., Suydam, R., Stimmelmayer, R., and
315 McBurney, D. (2017). Evolutionary aspects of the development of teeth and baleen in the
316 bowhead whale. *J. Anat.* 230, 549–566.
- 317 10. Kieser, J., Kieser, D., and Hauman, T. (2005). The course and distribution of the inferior
318 alveolar nerve in the edentulous mandible. *J. Craniofac. Surg.* 16, 6–9.
- 319 11. Hautier, L., Gomes Rodrigues, H., Billet, G., and Asher, R.J. (2016). The hidden teeth of
320 sloths: evolutionary vestiges and the development of a simplified dentition. *Sci. Rep.* 6,
321 27763.
- 322 12. Martin, B. (1916). Tooth development in *Dasypus novemcinctus*. *J. Morphol.* 27, 647–961.
- 323 13. Anthony, R. (1934). La dentition de l'oryctérope. Morphologie, développement, structure,
324 interprétation. *Ann. Sci. Nat. Zool.* 17, 289–322.
- 325 14. Spurgin, A.M. (1904). Enamel in the teeth of an embryo edentate (*Dasypus novemcinctus*
326 linn). *Am. J. Anat.* 3, 75–84.
- 327 15. Thomas, O. (1889). A milk dentition in *Orcyteropus*. *Proc. R. Soc. London* 47, 246–248.
- 328 16. Lönnberg, E. (1906). On a new *Orycteropus* from Northern Congo and some remarks on
329 the dentition of the Tubulidentata. *Ark. för Zool.* 3, 31–66.
- 330 17. Ciancio, M.R., Castro, M.C., Galliari, F.C., Carlini, A.A., and Asher, R.J. (2012).
331 Evolutionary implications of dental eruption in *Dasypus* (Xenarthra). *J. Mamm. Evol.* 19,
332 1–8.

- 333 18. Vizcaíno, S.F., Paleobiology, S., Summer, N., and Vizcaino, S.F. (2009). Paleontological
334 Society The Teeth of the “ Toothless ”: Novelties and Key Innovations in the Evolution of
335 Xenarthrans. *35*, 343–366.
- 336 19. Tims, H.W. (1908). Tooth-vestiges and associated mouth parts in the Manidae. *J. Anat.*
337 *Physiol.* *42*, 375–87.
- 338 20. Ishikawa, H., and Amasaki, H. (1995). Development and physiological degradation of
339 tooth buds and development of rudiment of baleen plate in southern minke whale,
340 *Balaenoptera acutorostrata*. *J. Vet. Med. Sci.* *57*, 665–670.
- 341 21. Rose, C. (1892). Beitrage zur Zahnentwicklung der Edentaten. *Anat. Anz.* *7*, 495–512.
- 342 22. Gibb, G., Condamine, F., Kuch, M., and Enk, J. (2016). Shotgun mitogenomics mrovides
343 a reference phylogenetic framework and timescale for living xenarthrans. *Mol. Biol. Evol.*
344 *33*, 621–642.
- 345 23. Meredith, R., Janečka, J., Gatesy, J., Ryder, O., Fisher, C.F., Teeling, E.C., Goodbla, A.,
346 Eizirik, E., Simão, T.L.L., and Stadler, T. (2011). Impacts of the Cretaceous terrestrial
347 revolution and KPg extinction on mammal diversification. *Science (80-.)*. *334*, 521–24.
- 348 24. Gaudin, T.J., Emry, R.J., and Wible, J.R. (2009). The phylogeny of living and extinct
349 pangolins (Mammalia, Pholidota) and associated taxa: a morphology based analysis. *J.*
350 *Mamm. Evol.* *16*, 235–305.
- 351 25. Nweeia, M.T., Eichmiller, F.C., Hauschka, P. V., Donahue, G.A., Orr, J.R., Ferguson,
352 S.H., Watt, C.A., Mead, J.G., Potter, C.W., Dietz, R., *et al.* (2014). Sensory ability in the
353 narwhal tooth organ system. *Anat. Rec.* *297*, 599–617.

- 354 26. Gaudin, T.J. (2004). Phylogenetic relationships among sloths (Mammalia, Xenarthra,
355 Tardigrada): the craniodental evidence. *Zool. J. Linn. Soc.* 140, 255–305.
- 356 27. Rétaux, S., and Casane, D. (2013). Evolution of eye development in the darkness of
357 caves: adaptation, drift, or both? *Evodevo* 4.
- 358 28. Gervais, P. (1867). *Zoologie et paléontologie générales: nouvelles recherches sur les*
359 *animaux vertébrés vivants et fossiles* A. Bertrand, ed. (Paris: La Société de Géographie).
- 360 29. Kuenzel, W.J. (2007). Neurobiological basis of sensory perception: welfare implications of
361 beak trimming. *Poult. Sci.* 86, 1273–82.
- 362 30. Louchart, A., and Viriot, L. (2011). From snout to beak: The loss of teeth in birds. *Trends*
363 *Ecol. Evol.* 26, 663–673.
- 364 31. Ekdale, E.G., Deméré, T.A., and Berta, A. (2015). Vascularization of the Gray Whale
365 Palate (Cetacea, Mysticeti, *Eschrichtius robustus*): Soft Tissue Evidence for an Alveolar
366 Source of Blood to Baleen. *Anat. Rec.* 298, 691–702.
- 367 32. Pyenson, N., Goldbogen, J., Vogl, A., and Szathmary, G. (2012). Discovery of a sensory
368 organ that coordinates lunge feeding in rorqual whales. *Nature* 485, 498–501.
- 369 33. Lubin, Y., and Montgomery, G. (1981). Defenses of *Nasutitermes* termites (Isoptera,
370 Termitidae) against *Tamandua* anteaters (Edentata, Myrmecophagidae). *Biotropica* 13,
371 66–76.
- 372 34. Naples, V. (1999). Morphology, evolution and function of feeding in the giant anteater
373 (*Myrmecophaga tridactyla*). *J. Zool.* 249, 19–41.

- 374 35. Endo, H., Ito, K., Watabe, H., Nguyen, S., and Koyabu, D. (2017). Macroscopic and CT
375 examinations of the mastication mechanism in the southern tamandua. *Mammal Study*
376 42, 89–96.
- 377 36. Boissonade, F.M., and Matthews, B. (1993). Responses of trigeminal brain stem neurons
378 and the digastric muscle to tooth-pulp stimulation in awake cats. *J. Neurophysiol.* 69,
379 174–186.
- 380 37. Dong, W.K., Chudler, E.H., and Martin, R.F. (1985). Physiological properties of intradental
381 mechanoreceptors. *Brain Res.*, 389–395.
- 382 38. Chatrian, G.E., de Lima, V.M.F., Lettich, E., Canfield, R.C., Miller, R.C., and Soso, M.J.
383 (1982). Electrical stimulation of tooth pulp in humans. II. Qualities of sensations. *Pain* 14,
384 233–246.
- 385 39. Endo, H., Nishiumi, I., Kurohmaru, M., Nabhitabhata, J., Chan-Ard, T., Nadee, N.,
386 Agungpriyono, S., and Yamada, J. (1998). The functional anatomy of the masticatory
387 muscles of the Malayan pangolin, *Manis javanica*. *Mammal Study* 23, 1–8.
- 388 40. Kumar, S., Stecher, G., Suleski, M., and Hedges, S.B. (2017). TimeTree: a resource for
389 timelines, timetrees, and divergence times. *Mol. Biol. Evol.* 34, 1812–19.

390

391

392 **Figure legends**

393 **Figure 1. Evolution of dorsal canaliculi linked to tooth regression in 28 placentals and 1**

394 **marsupial.** Circular timetree (according to Kumar *et al.* [40]) with corresponding 3D
395 reconstructions of the internal mandibular morphology with dorsal canaliculi (orange),
396 mandibular canal (cyan), mental branches (pink), and teeth (dark blue). Tree branches are
397 colored in orange (presence of dorsal canaliculi) and black (absence of dorsal canaliculi). Animal
398 silhouettes are colored in black (sampled species) and gray (species from [7]).

399

400 **Figure 2. Evolution of dorsal canaliculi after tooth regression.** (A) *Cyclopes didactylus*; (B)
401 *Tamandua tetradactyla*; (C) *Myrmecophaga tridactyla*; (D) *Manis javanica*; (E) *Orycteropus afer*;
402 (F) *Priodontes maximus*. Bone is transparent. Dorsal canaliculi – orange; mental branches –
403 purple; mandibular canal – cyan; teeth – dark blue. Scale in mm.

404

405 **Figure 3. Ontogenetic evidence of the association of dorsal canaliculi to vestigial tooth**
406 **alveoli.** 3D models of the mandibles of sloth fetuses (A) *Bradypus tridactylus* and (B) *Choloepus*
407 *didactylus*) and adults (C) *B. tridactylus* and (D) *Choloepus hoffmanni* in medial (A, C and D) and
408 lateral (B) views. Bone is transparent. B is a mirrored lateral view for a better perspective of the
409 dorsal canaliculus. Dorsal canaliculi – orange; mental branches – purple; mandibular canal –
410 cyan; teeth – dark blue. Zoomed details of the dorsal canaliculi associated with the vestigial
411 teeth are shown. Scale in mm.

412

413 **Figure 4. Histological evidence for the passage of blood vessels and nerves in dorsal**
414 **canaliculi.** (A) 3D-model of a mandible with a purple dashed rectangle indicating where the
415 sagittal cut was performed; black dashed rectangles indicate the limits of the coronal cut. (B)
416 Coronal cut showing the mandibular canal and a dorsal canaliculus; soft tissues are present
417 dorsally to the mandibular canal, the dorsal canaliculus and the external dorsal, and dorso-

418 lateral surfaces of the mandible; the red square represents the area of interest to be zoomed in
419 (B'); the purple dashed line represents the sagittal section performed on the cut portion of the
420 mandible (A). (C) Sagittal section showing the mandibular canal, two dorsal canaliculi and
421 associated soft tissues; soft tissues on the dorsal surface of the mandible are identified; the red
422 square delimits the area zoomed in (C'). (C') An ascending branch of the IAN is present in the
423 dorsal canaliculus. Abbreviations: *bo* bone; *de* dermis; *ep* epidermis; *IAA* inferior alveolar artery;
424 *IAAab* inferior alveolar artery ascending branch; *IAN* inferior alveolar nerve; *IANa* inferior
425 alveolar nerve accessory branch; *IANab* inferior alveolar nerve ascending branch; *IAV* inferior
426 alveolar vein; *IAVab* inferior alveolar vein ascending branch; *pa* keratinous dentary pad.
427

428 **Supplemental figure legends**

429 **Figure S1. 3D models of fourteen mandibles (five toothless and nine toothed) in lateral**
430 **view. Related to Figure 1.** (A) *Cyclopes didactylus* (MNHN 1986-1115); (B) *Tamandua*
431 *tetradactyla* (BMNH 34.9.2.196); (C) *Myrmecophaga tridactyla* (ISEM – 065 V); (D) *Manis*
432 *crassicaudata* (BMNH_67.4.12.298); (E) *Manis javanica* (BMNH 9.1.5.858); (F) *Dasypus*
433 *novemcinctus* (USNM 033867); (G) *Dasypus pilosus* (ZMB 19240); (H) *Priodontes maximus*
434 (ZMB 47528); (I) *Proteles cristatus* (BMNH 34.11.1.5); (J) *Canis lupus* (LAMC 23010); (K)
435 *Bradypus tridactylus* (MNHN 1999-1065); (L) *Choloepus hoffmanni* (Hautier pers. Coll.); (M)
436 *Orycteropus afer* (BMNH 27.2.11.113); (N) *Potamogale velox* (ZMB 71587). Bone is transparent.
437 Dorsal canaliculi (numbered) – orange; mental branches (mb) – purple; mandibular canal –
438 cyan; parallel canaliculi – yellow. Scale in mm.

439 **Figure S2. 3D models of 12 toothed mandibles in lateral view. Related to Figure 1.** (A)
440 *Dasyurus hallucatus* (TMM M-6921); (B) *Lemur catta* (DPC-O92); (C) *Cynocephalus volans*

441 (FMNH 56521); (D) *Procavia capensis* (UMZC H4980K); (E) *Tapirus indicus* (KUPRI 506); (F)
442 *Tenrec ecaudatus* (Martinez pers. coll.); (G) *Lepus europaeus* (DMET-RN1); (H) *Talpa europaea*
443 (Martinez pers. coll.); (I) *Tupaia montana* (FMNH 108831); (H) *Rhynchocyon petersi* (BMNH
444 55149); (K) *Rattus norvegicus* (HACB-RN1); (L) *Molossus molossus* (AMNH 234923). Bone is
445 transparent. Mental branches (mb) – purple; mandibular canal – cyan; teeth – dark blue;
446 trabeculae – green. Scale in mm.

447 **Figure S3. Histological slice of coronal sections of the mandibles of a bowhead whale and**
448 **a collared anteater. Related to Figure 4.** Coronal sections of the mandibles of (A) *Balaena*
449 *mysticetus* [9] and (B) a formalin preserved *Tamandua tetradactyla* (ISEM 778N; LFB stained).
450 For B bone tissue is colored in dark blue and soft tissues stained in different tones of blue and
451 purple. The dark blue colored myelin layers can be observed. Coronal cuts showing the
452 mandibular canal and dorsal canaliculi; soft tissues are present on mandibular canals and dorsal
453 canaliculi. *bo* bone; *IAA* inferior alveolar artery; *IAAa* inferior alveolar artery accessory branch;
454 *IAAab* inferior alveolar artery ascending branch; *IAN* inferior alveolar nerve; *IANa* inferior
455 alveolar nerve accessory branch; *IANab* inferior alveolar nerve ascending branch; *IAV* inferior
456 alveolar vein; *IAVab* inferior alveolar vein ascending branch; *vt* vestigial tooth (1st generation).

457 **Figure S4. 3D models showing intraspecific variation of dorsal canaliculi. Related to**
458 **Figures 1 and 2.** (A-F) *Dasypus novemcinctus* (USNM 033867, BMNH 11.10.27.3, LSUMZ
459 8538, LSUMZ 29160, ZMB 84-357, USNM 020920); (G-H) *Cyclopes didactylus* (MNHN 1986-
460 1115, BMNH 24.12.4.68); (I-K) *Tamandua tetradactyla* (BMNH 34.9.2.196, MVZ 153482, ISEM
461 778N); (L-N) *Myrmecophaga tridactyla* (ISEM 065V, MVZ 185238, ISEM 071N). Teeth are
462 segmented in (A) only. Bone is transparent. Dorsal canaliculi – orange; mental branches –
463 purple; mandibular canal – cyan; teeth – dark blue. Scale in mm.

464 **Figure S5. Ancestral state reconstruction of the presence/absence of dorsal canaliculi in**

465 **28 placental and one marsupial species. Related to Figure 1.** Posterior probabilities (%) for
466 the presence of dorsal canaliculi are presented for each node. Presence of dorsal canaliculi –
467 orange; absence of dorsal canaliculi – cyan.

468

469

470 **STAR * methods**

- 471 • [Key resources table](#)
- 472 • [Contact for resource sharing](#)
- 473 • [Method details](#)
- 474 • [Data and software availability](#)

475

476 **Contact for resource sharing**

477 Further information and requests for resources should be directed to, and will be fulfilled by the
478 Lead author Frédéric Delsuc (frederic.delsuc@umontpellier.fr).

479

480 **Method details**

481 [Comparative anatomy](#)

482 We present an anatomical description of the mandibles and mandibular canals of 26 species
483 (Figure 1) representing the following taxa: Vermilingua (anteaters) – *Cyclopes didactylus*,
484 *Tamandua tetradactyla*, *Myrmecophaga tridactyla* (juvenile + adult); Cingulata (armadillos) –
485 *Dasypus novemcinctus*, *Dasypus pilosus*, *Priodontes maximus*; Folivora (sloths) – *Bradypus*
486 *tridactylus* (fetus + adult); *Choloepus* spp. (fetus + adult); Tubulidentata (aardvarks) –
487 *Orycteropus afer*; Afrosoricida (tenrecs) – *Potamogale velox*, *Tenrec ecaudatus*; Macroscelidea
488 (elephant shrews) – *Rhynchocyon petersi*; Hyracoidea (hyraxes) – *Procavia capensis*; Pholidota
489 (pangolins) – *Manis crassicaudata*, *Manis javanica*; Carnivora (carnivores) – *Proteles cristatus*
490 and *Canis lupus*; Perissodactyla (odd-toed ungulates) – *Tapirus indicus*; Chiroptera (bats) –
491 *Molossus molossus*; Eulipotyphla (moles and shrews) – *Talpa europaea*; Lagomorpha (hares
492 and rabbits) – *Lepus europaeus*; Rodentia (rodents) – *Rattus norvegicus*; Primates (primates) –
493 *Lemur catta*; Dermoptera (colugos) – *Cynocephalus volans*; Scandentia (tree shrews) – *Tupaia*
494 *montana*; *Dasyuromorphia* (carnivorous marsupials) – *Dasyurus hallucatus*. Using this dataset,
495 we were able to compare the morphology of the mandibular canal and dorsal canaliculi of
496 closely related toothed and toothless taxa, as well as a wide range of species belonging to 18
497 mammalian orders. We additionally compared our results to the previously published research
498 on cetaceans and even-toed ungulates (Cetartiodactyla) by Peredo *et al.* [7]. We segmented a
499 total of five *D. novemcinctus*, three *M. tridactyla* (two adults + one juvenile), three *T. tetradactyla*,
500 and two *Cy. didactylus* in order to account for intraspecific variation. We also segmented left and
501 right hemi-mandibles of the anteater specimens to assess the level of bilateral variation in dorsal
502 canaliculi count. Both fetus and adult specimens of *B. tridactylus* and *Choloepus* spp. were
503 studied (Figure 3) in order to seek the presence of a dorsal canaliculus linked to the
504 development of vestigial teeth [11] and to confirm that there was no major variation in the
505 number of dorsal canaliculi through ontogeny. Mandibles were chosen to study dental
506 innervation patterns because they are composed by a single bone (dentary) enclosing the IAN
507 and the IAA. The mandibular canal soft tissues enter in a continuous canal posterior to the tooth

508 row and project anteriorly to its anterior end. Compared to the cranium, all branching patterns of
509 the mandibular canal are therefore more easily traceable. The mandible is, therefore, a simpler
510 model to study innervation patterns with the techniques used for this manuscript.

511 Acquisition of data

512 The studied specimens belong to the following collections: Natural History Museum, London
513 (BMNH); Muséum National d'Histoire Naturelle, Paris (MNHN); Museum für Naturkunde, Berlin
514 (ZMB); University Museum of Zoology, Cambridge (UMZ); Institut des Sciences de l'Evolution,
515 Montpellier (ISEM); Museum of Vertebrate Zoology, Berkeley (MVZ); Louisiana State University
516 Museum of Zoology (LSUMZ); United States National Museum (USNM); L.H. personal
517 collection. High-resolution microtomography (μ CT) was performed at Montpellier Rio Imaging
518 (MRI; Microtomograph RX EasyTom 150, X-ray source 40-150 kV) platform, Imaging Analysis
519 Center (BMNH; Nikon Metrology HMX ST 225, X-ray source 225 kV), and the Helmholtz
520 Zentrum Berlin (HZB, Hamamatsu L8121-3, X-ray source 40-150 kV). The scan resolution
521 differed according to the size of specimens (Table S1). Eight specimens were obtained from
522 MorphoSource (www.morphosource.org), one from Digimorph (www.digimorph.org), and one
523 from the Digital Morphology Museum (www.dmm.pri.kyoto-u.ac.jp). The left hemi-mandibles (the
524 right one was used if the left one was missing or broken) were reconstructed, with respective
525 mandibular canals and teeth. Avizo 9.4.0 (Visualization Sciences Group) was used to perform
526 the 3D reconstructions. When teeth were absent, the mental branches were distinguished from
527 the dorsal canaliculi by their larger diameter and their lateral projection to the mental foramina on
528 the lateral aspect of the mandible [5,7]. Dorsal canaliculi were defined as dorsal projections of
529 the mandibular canal opening on the dorsal surface of the mandible.

530 Histology

531 We also dissected the head of an adult specimen of *T. tetradactyla* (ISEM 778N) fixed in
532 formalin. The right mandible was extracted and its associated musculature removed. The
533 mandible was then subjected to decalcification during forty five days, following standard
534 protocols. A portion of the mandible was then cut (as shown in Figure 4A) with the use of a
535 scalpel, and fixed in paraffin. Serial slicing was performed to produce 3µm thick coronal and
536 sagittal sections of the mandible. Luxol Fast Blue (LFB) was used to stain the slices in order to
537 allow for the blue staining of the myeline sheaths insulating nerve cell axons. The LFB staining
538 protocol was composed of several phases (1-11) in which acetic acid (10%), Luxol Fast Blue
539 (0.1%), lithium carbonate (0.05%), and cresyl violet (0.1%) were used. (1) Histological sections
540 were placed in a sealed container with the Luxol Fast Blue solution and were left overnight
541 inside an oven at 58°C; (2) Sections were rinsed with ethanol (96%); (3) Sections were rinsed
542 with distilled water; (4) Sections were differentiated in a lithium carbonate solution during 30
543 seconds; (5) Sections were placed in a rack with ethanol (70%) and were then stirred manually
544 twice during periods of 15 seconds; (6) Sections were placed in a rack with distilled water and
545 were then stirred manually during one minute; (7) A counterstain was performed by placing the
546 sections in a cresyl violet solution during ten minutes; (8) Samples were quickly rinsed twice with
547 ethanol (96%); (9) Sections were placed on ethanol (100%) for two periods of two minutes each;
548 (10) Sections were placed on xylene (dimethylbenzene) for the same duration as in step (9); (11)
549 Sections were mounted with a resinous medium (Pertex). A histological slice of a coronal section
550 of the mandible of *Balaena mysticetus* (provided by J.G.M. Thewissen [22]) was used for
551 anatomical comparisons (Figure S3A).

552

553 **Supplemental item titles**

554 **Data S1.** Supplemental Text for anatomical descriptions, histological comparison of the anteater
555 and the bowhead whale, intraspecific variation, *Vermilingua* ancestral tooth pattern, and
556 ancestral state reconstruction of the internal anatomy of the mandible. Related to Results and
557 Discussion.

558 **Table S1.** Resolution of the performed μ -CT scans and scanning platform information. Related
559 to STAR methods.

KEY RESOURCES TABLE

RESOURCE	SOURCE	IDENTIFIER
Biological Samples		
<i>Proteles cristatus</i>	This paper	BMNH 34.11.1.5
<i>Canis lupus</i>	https://www.morphosource.org/Detail/SpecimenDetail/Show/specimen_id/2716	LACM 23010
<i>Manis crassicaudata</i>	This paper	BMNH 67.4.12.298
<i>Manis javanica</i>	This paper	BMNH 9.1.5.858
<i>Orycteropus afer</i>	This paper	BMNH 27.2.11.113
<i>Potamogale velox</i>	This paper	ZMB 71587
<i>Tenrec ecaudatus</i>	This paper	Martinez pers. coll.
<i>Rhynchocyon petrsi</i>	This paper	BMNH 55.149
<i>Procavia capensis</i>	https://www.morphosource.org/Detail/SpecimenDetail/Show/specimen_id/5258	UMZC H4980K
<i>Cyclopes didactylus</i>	This paper	MNH 1986-1115
<i>Cyclopes didactylus</i>	This paper	BMNH 24.12.4.68
<i>Tamandua tetradactyla</i>	This paper	BMNH 34.9.2.196
<i>Tamandua tetradactyla</i>	This paper	ISEM 788N
<i>Tamandua tetradactyla</i>	This paper	MVZ 153482
<i>Myrmecophaga tridactyla</i>	This paper	ISEM 071 N
<i>Myrmecophaga tridactyla</i>	This paper	ISEM 065 V
<i>Myrmecophaga tridactyla</i>	This paper	MVZ 185238
<i>Bradypus tridactylus</i>	This paper	ZMB 18834
<i>Bradypus tridactylus</i>	This paper	MNH 1999-1065
<i>Choloepus didactylus</i>	This paper	ZMB 4949
<i>Choloepus hoffmanni</i>	This paper	Hautier pers. coll.
<i>Dasyopus pilosus</i>	This paper	ZMB 19240
<i>Dasyopus novemcinctus</i>	This paper	USNM 033867
<i>Dasyopus novemcinctus</i>	This paper	LSUMZ 8538
<i>Dasyopus novemcinctus</i>	This paper	LSUMZ 29160
<i>Dasyopus novemcinctus</i>	This paper	BMNH 11.10.27.3
<i>Dasyopus novemcinctus</i>	This paper	ZMB 84-357
<i>Dasyopus novemcinctus</i>	This paper	USNM 020920
<i>Priodontes maximus</i>	This paper	ZMB 47528
<i>Tapirus indicus</i>	http://dmm.pri.kyoto-u.ac.jp/dmm/WebGallery/dicom/dicomProperty.html?id=506	KUPRI 506
<i>Molossus molossus</i>	https://www.morphosource.org/Detail/MediaDetail/Show/media_id/19283	AMNH 234923
<i>Talpa europaea</i>	This paper	Martinez pers. coll.
<i>Cynocephalus volans</i>	https://www.morphosource.org/Detail/MediaDetail/Show/media_id/18020	FMNH 56521
<i>Lemur catta</i>	https://www.morphosource.org/Detail/MediaDetail/Show/media_id/647	DPC-092
<i>Tupaia montana</i>	https://www.morphosource.org/Detail/MediaDetail/Show/media_id/13025	FMNH 108831
<i>Lepus europaeus</i>	https://www.morphosource.org/Detail/MediaDetail/Show/media_id/23932	DMET-LE1

<i>Rattus norvegicus</i>	https://www.morphosource.org/Detail/MediaDetail/Show/media_id/28785	HACB-RN1
<i>Dasyurus hallucatus</i>	http://digimorph.org/specimens/Dasyurus_hallucatus/	TMM M-6921
Reagents		
Acetic acid	Merck	537020
Distilled water	Aguettant	3293
Luxol Fast Blue	Georges T. GURR	B2580
Lithium carbonate	Diapath	M00188
Cresyl violet	Merck	5235
Software and Algorithms		
Avizo 9.4.0	FEI	https://www.fei.com/software/amira-avizo/
Other		
Voxel size used for 3D model segmentation	This paper	Data S1

Figure 1

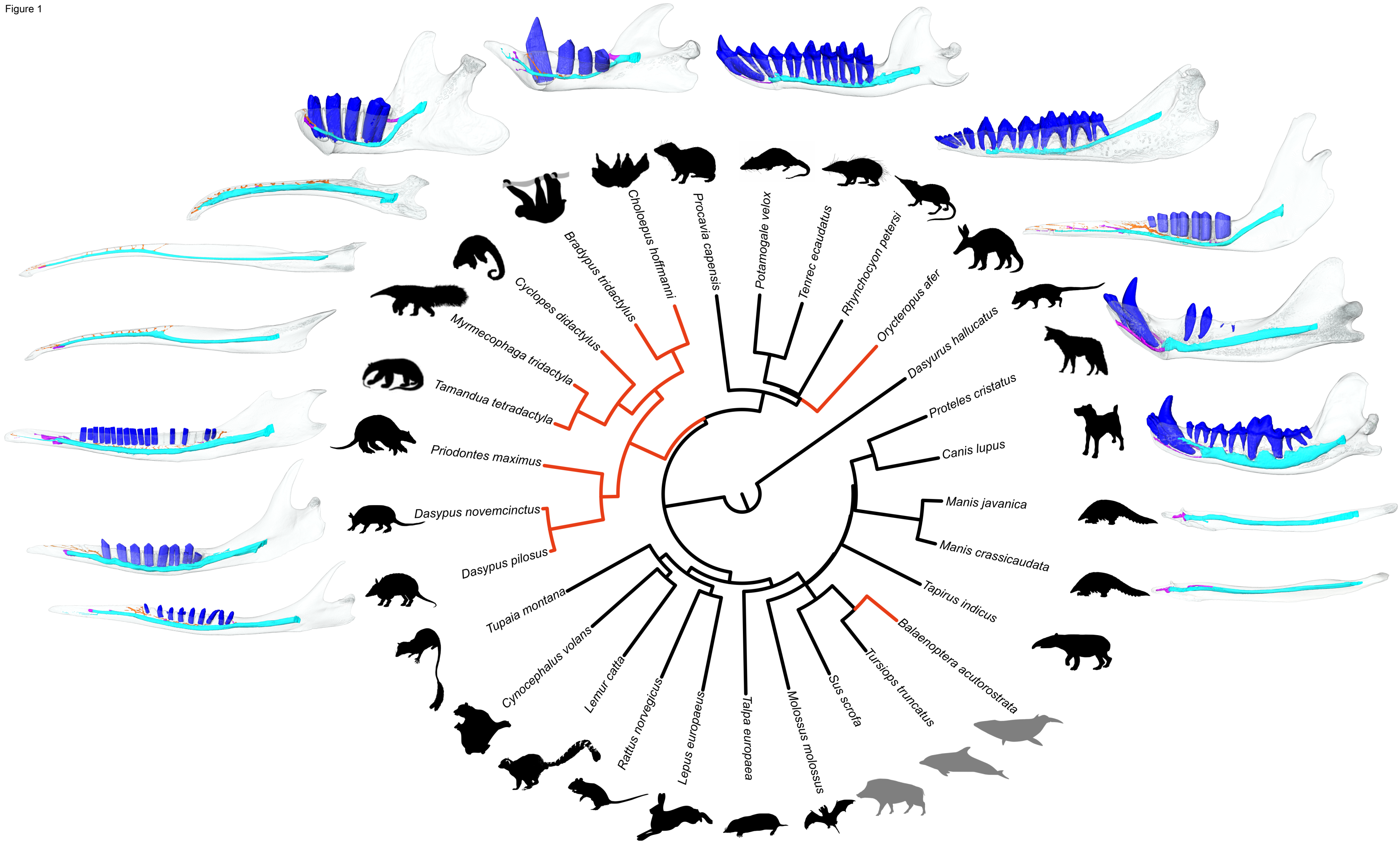


Figure 2

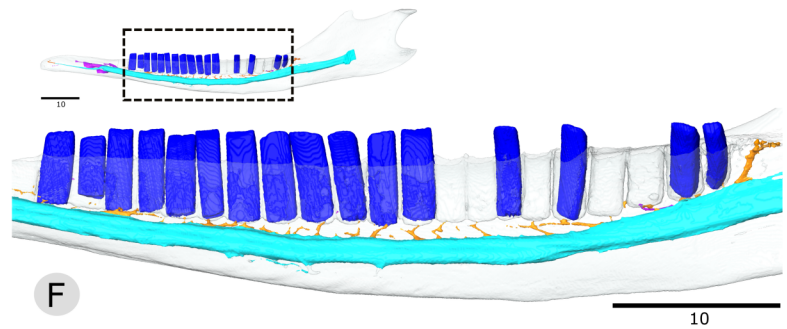
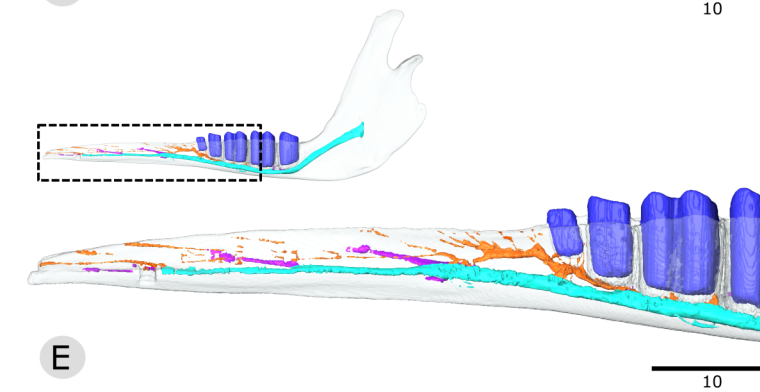
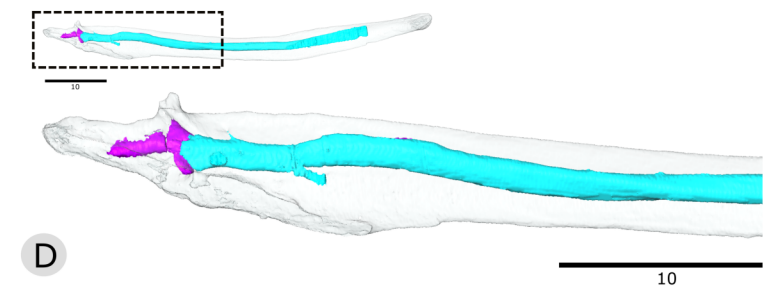
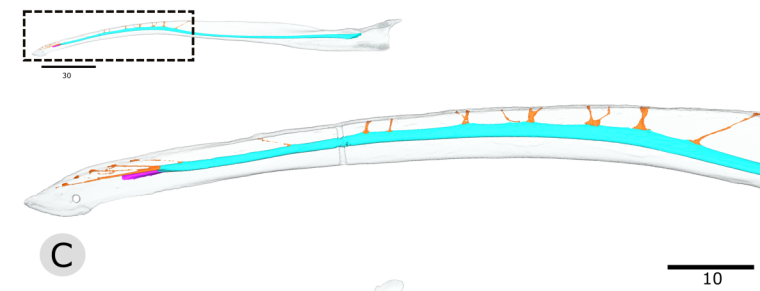
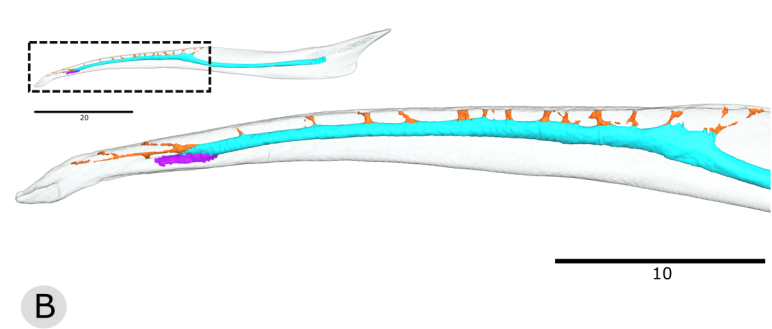
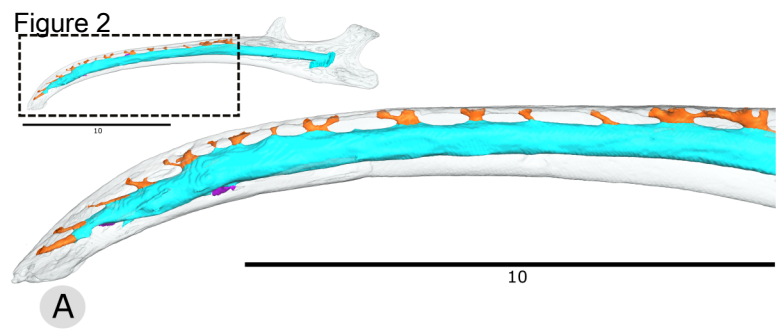
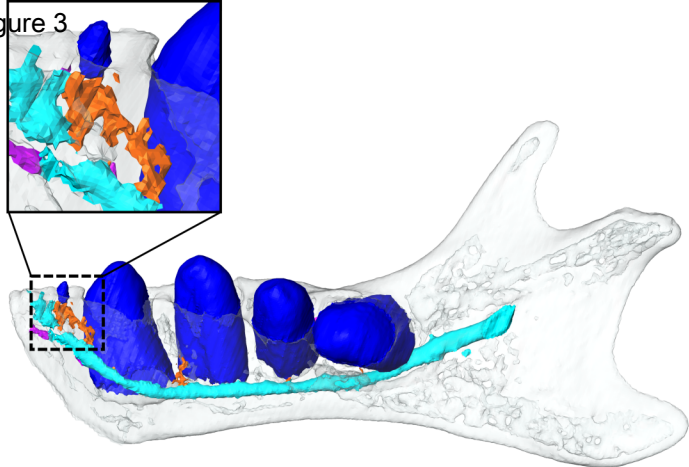
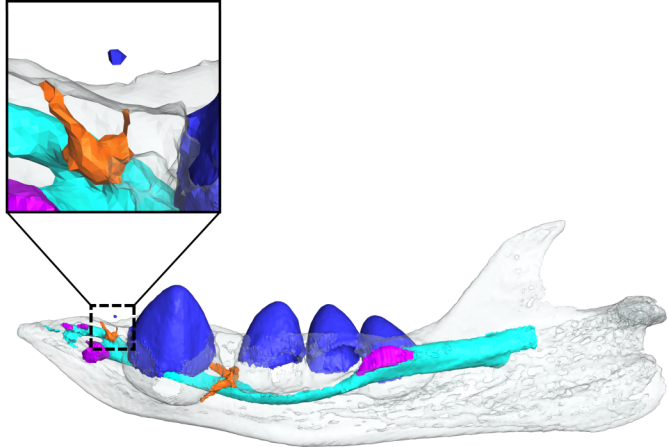


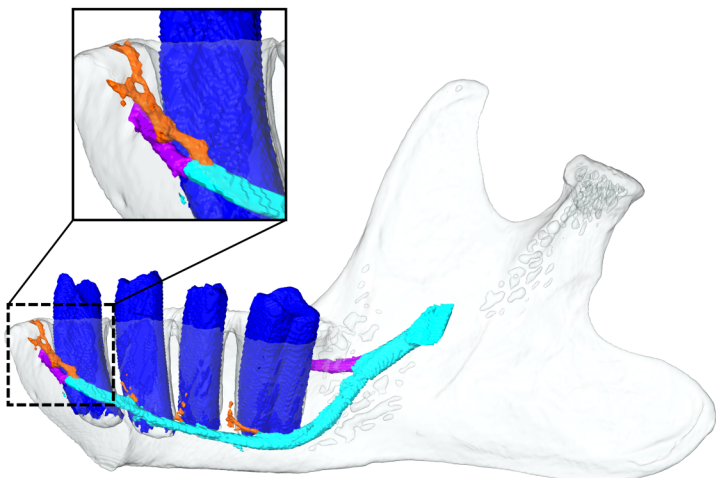
Figure 3



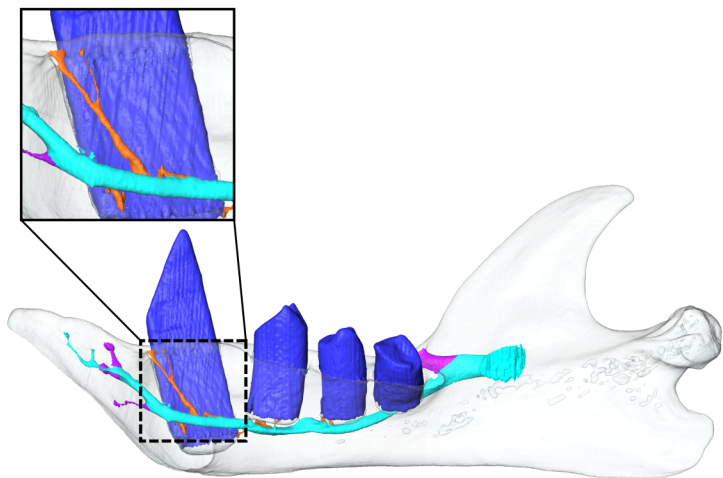
A



B

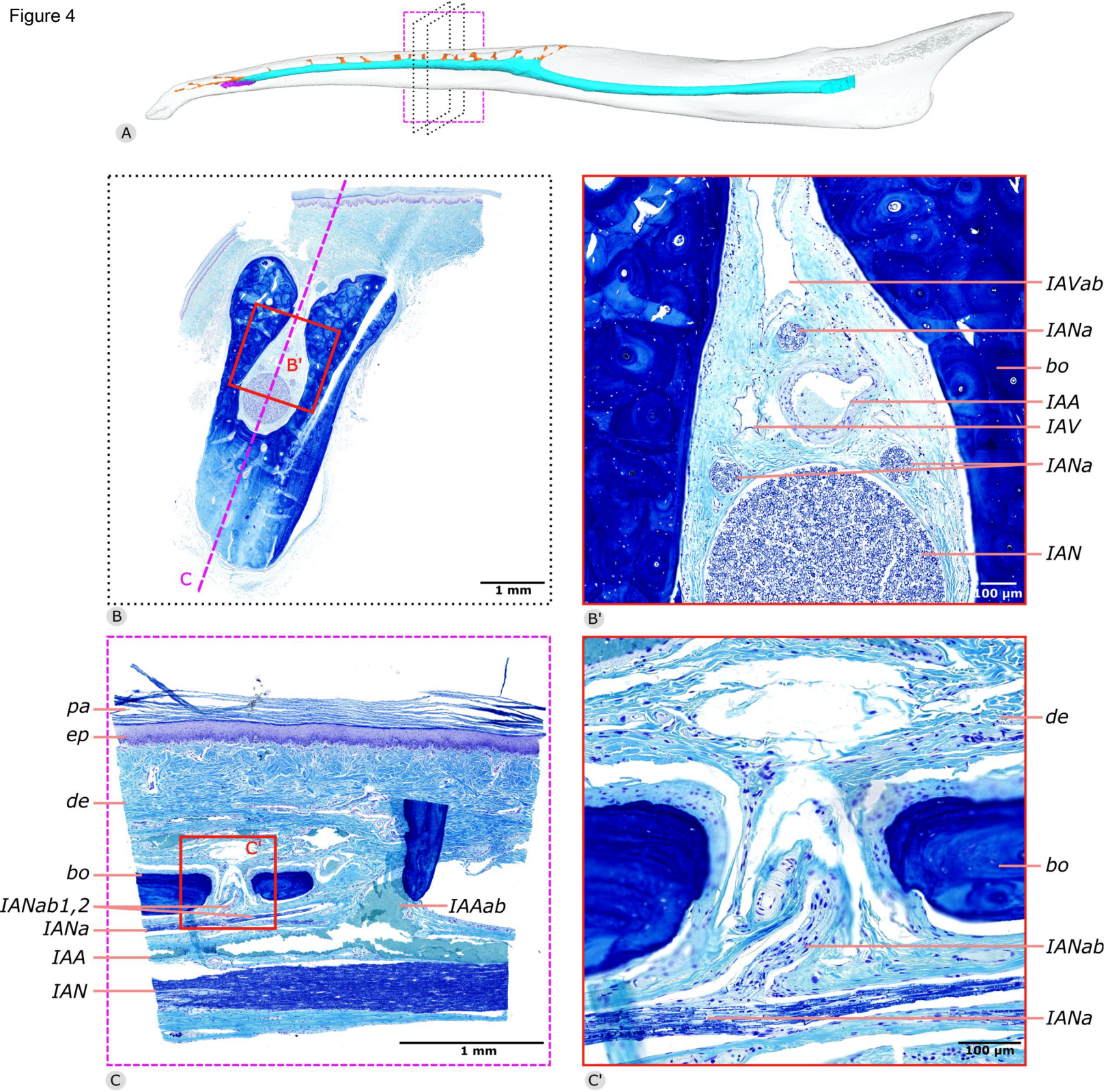


C



D

Figure 4



1 Evolutionary tinkering of the mandibular canal linked to
2 convergent regression of teeth in placental mammals

3

4

5 Sérgio Ferreira-Cardoso^{1,*}, Frédéric Delsuc^{1,3} and Lionel Hautier^{1,2,*}

6

7 **Author list footnotes**

8 ¹Institut des Sciences de l'Evolution de Montpellier (ISEM), CNRS, IRD, EPHE,

9 Université de Montpellier, Montpellier, France.

10 ²Mammal Section, Life Sciences, Vertebrate Division, The Natural History Museum,

11 London, UK

12 ³Lead contact

13 *Correspondence: sergio.ferreira-cardoso@umontpellier.fr and

14 lionel.hautier@umontpellier.fr

15

16

17

18 **Supplemental information:**

19

- 20 - 1. Anatomical descriptions
21 - 2. Homology of dorsal canaliculi between anteaters and baleen whales
22 - 3. Intraspecific and ontogenetic variation of dorsal canaliculi number
23 - 4. Insights into the ancestral number of teeth in anteaters
24 - 5. Ancestral state estimation of the tree internal nodes

25

26

27 **Supplementary text S1**

28

29 **1. Anatomical descriptions of myrmecophagous mammals and sister taxa**

30

31 **Pygmy anteater (*Cyclopes didactylus*)**

32 The mandible of *Cyclopes didactylus* is low and slender. In lateral view, the horizontal
33 ramus is thin, elongated and is highly curved with a ventral concavity, which makes it
34 distinctive from all other anteaters. The ascending ramus is extremely inclined laterally,
35 with the hook-like coronoid process projecting laterally. The mandible presents seven
36 mental foramina (Figure S1A). We here designate the flattened part of the horizontal
37 ramus of the mandible as the dentary pad. This dentary pad extends from the most
38 anterior tip of the mandible to the posterior end of the coronoid process. This pad
39 displays several dorsal foramina with foramina for dorsal canaliculi 9 to 15 forming a
40 continuous groove. Nineteen foramina are present on the left dentary pad, 20 on the
41 right mandible.

42 The mandibular canal displays a straight trajectory until it reaches the dentary
43 pad, from where it curves ventrally, accompanying the shape of the mandible. The
44 mandible has an elliptic-like section, and the major axis rotates, in anterior direction,
45 from an almost transversal plane parallel position to a coronal one. The mandibular
46 canal is positioned dorsally. The size of the mandibular canal remains constant along the
47 horizontal plane, and decreases towards the symphysis. The mandibular canal presents
48 several dorsal canaliculi (dc), which connect dorsomedially with the opening foramina. In
49 total, there are fifteen dorsal (eighteen on the right mandible) and seven mental
50 branches. Some of the dorsal canaliculi bifurcate and vary in diameter, with dc14 and
51 dc15 being the largest (Figure S1A). The first four dorsal canaliculi (dc1 to dc4) are

52 anterodorsally oriented, as well as dc12, dc13 and the anterior projections of the
53 bifurcating canaliculi. The mental branches also vary in diameter, with the most anterior
54 one (mb1) being, by far, the largest, but no specific trend observed.

55

56 **Collared anteater (*Tamandua tetradactyla*)**

57 In *Tamandua tetradactyla* the edentulous horizontal ramus is long, slightly curved
58 ventrally, and gets gradually shallower postero-anteriorly. The dentary pad is more
59 anterior, narrower in its most posterior part, and not as medially inclined as in *C.*
60 *didactylus* (Figure S1B); it is perforated by 17 foramina (Figure S1B, dc 1-15); a small
61 and shallow groove connects the most posterior ones. Only one anterior mental foramen
62 is present (Figure S1B, mb1). The ascending ramus is rather shallow and presents
63 incipient coronoid and angular processes; the condyloid process is posteriorly projected.

64 The mandibular foramen (mb1, Figure S1B) is parallel to the mandibular canal.
65 The mandibular canal opens on the medial surface of the ascending ramus and projects
66 anteriorly with a slight ventral inclination. It projects dorsally from the posterior edge of
67 the dentary pad, as is typical of toothed mammals after tooth loss [S1,S2]. Similarly to *C.*
68 *didactylus*, dorsal canaliculi are present. Each quadrant presents 15 dorsal canaliculi;
69 only dc1 and dc15 are bifurcated (Figure S1B). The canals of the dorsal canaliculi are
70 relatively narrower than those observed in *C. didactylus*. Although the most anterior
71 canals (dc1 to dc6) are slightly anteriorly oriented, this trend is not present on the most
72 posterior ones (dc7 to dc14), which display a more random inclination. The most
73 posterior canaliculus (dc15) is posteriorly inclined. Dorsal canaliculi dc1 and dc2 are
74 spatially and morphologically distinct from the remaining (Figure S1B), and highly
75 anteriorly inclined. Dc1 is extremely elongated and splits into two parts anteriorly.

76

77

78 **Giant anteater (*Myrmecophaga tridactyla*)**

79 The mandible of the adult *Myrmecophaga tridactyla* is, in many ways, similar to that of *T.*
80 *tetradactyla*. It is larger in size but presents the same general morphology, with the body
81 being elongated, transversely compressed and lacking teeth, and the ascending ramus
82 being extremely simplified when compared to toothed xenarthrans. As in *T. tetradactyla*,
83 the anterior part of the mandible is slightly curved, with the anterior tip tapering ventrally.
84 A dentary pad occupies more than half of the total length of the jaw (Figure S1C), which
85 is narrow posteriorly. Sixteen foramina are present on the dentary pad, and correspond
86 to the dorsal opening of the dorsal canaliculi. Two mental foramina are present in the
87 anterior part of the mandible, with the most anterior one (mb1, Figure S1C) opening
88 laterally at the level of dc4 and the second one (mb2, Figure S1C), much smaller,
89 opening at the level of dc5.

90 The mandibular canal opens in the medial surface of the ascending ramus, just
91 dorsally to the position of the coronoid process, with an aperture with a long antero-
92 posterior axis. A groove runs anteriorly along the canal. The latter gradually descends
93 along the lengthy horizontal ramus, until it reaches the level of the posterior margin of
94 the dentary pad (Figure S1C). It then projects dorsally to reach the level of dc5, from
95 where it maintains its position in the mandible until it opens to the mental foramen (mb1),
96 anteriorly. Along this path, thirteen main dorsal canaliculi open dorsally in the dentary
97 pad. Dc13, the longest and most posterior dorsal canaliculus projects postero-dorsally.
98 Dc12 to dc6 project dorsally, with some dorsal canaliculi displaying a simple column
99 shaped, while others bifurcate dorsally. Dc5 is anteriorly inclined and has a much
100 reduced diameter. Close to the symphysis, the first five dorsal canaliculi (dc1-5) form a
101 distinct complex of long and anteriorly inclined canaliculi, similar to *T. tetradactyla*. In
102 summary, the morphology of the mandibular canal of *M. tridactyla* is similar to *T.*

103 *tetradactyla*, except for the dorsoposteriorly oriented dorsal canaliculus (i.e. 13), and for
104 the larger number of dorsal canaliculi on the anterior complex.

105 A juvenile specimen (ISEM - 071 N) was also analysed to check on the number
106 of dorsal canaliculi. There are 16 dorsal canaliculi on the left side and 18 dorsal
107 canaliculi on the right hemi-mandible. The posterior part of the mandibular canal is not
108 well ossified and the division between branches is less clear. The posteriormost dorsal
109 canaliculus is long and posteriorly projecting and does not reach the top of the mandible.

110

111 **Indian pangolin (*Manis crassicaudata*)**

112 The mandible of *Manis crassicaudata* is greatly compressed transversely and shallow.
113 The ascending branch lack a true coronoid process as consists of a slightly dorsally
114 inclined posterior knob-like projection. Three mental foramina (Figure S1D, mb1-3) are
115 present on the anterior part of the horizontal ramus.

116 The mandibular foramen is antero-posteriorly elongated and has an anterior
117 position in the ascending ramus. The mandibular canal projects anteriorly in a straight
118 trajectory, near the dorsal margin of the mandible. From about the middle of the
119 horizontal ramus the mandibular canal trajectory accompanies the dorsal edge
120 mandible. This contrasts with anteaters, in which the mandibular canal position is ventral
121 until it drifts dorsally at the posterior part of the dentary pad. The transversal section of
122 the canal varies between a circular and an oval shape. From its most posterior part, the
123 canal displays several small canaliculi that depart from the main mandibular canal,
124 parallel to it. These parallel canaliculi are present around the mandibular canal, along its
125 entire length, both dorsally and ventrally. Their density is higher on the anterior half of
126 the horizontal ramus and the posterior part of the ascending ramus. On the anterior part
127 of the mandible, the dorso-laterally projecting pseudo-tooth displays a small foramen for
128 a parallel canaliculus and the very anterior tip of the horizontal ramus presents two of

129 these canaliculi. Most parallel canaliculi show no connection to the mandibular canal and
130 only a few open in microscopic foramina (Figure S1D). The most posterior mental
131 branch (Mb3) is short and opens in an elongated foramen just before it bifurcates. The
132 remaining two mental foramina (associated to mb2 and mb3) open laterally close to the
133 sharp anterior tip of the mandible. The small mb2 splits posteriorly to the pseudo-tooth
134 while the large and elongated mb1 drifts laterally at the level of this prong.

135

136 **Malayan pangolin (*Manis javanica*)**

137 The mandible in *Manis javanica* is shallower than in *M. crassicaudata*. It presents five
138 anterior mental foramina (Figure S1E, mb1-5), with the second most anterior (mb2)
139 being clearly larger than the remaining ones. Between the posterior end of the
140 symphysis and the pseudo-tooth, two small circular foramina open medially (Figure
141 S1E).

142 The mandibular foramen in *M. javanica* differs from *M. crassicaudata*; it displays
143 an elliptical shape with an extremely elongated antero-posterior axis. The dorsal and
144 ventral margins of the foramen fade posteriorly and its internal surface becomes
145 continuous with the medial surface of the ascending ramus.

146 Similar to its sister taxon, *M. javanica* displays a mandibular canal that presents a
147 rather homogeneous shape and position along its path. Posteriorly, it slightly descends
148 accompanying the inclination of the mandibular foramen and follows the general shape
149 of the dorsal margin of the horizontal ramus until it reaches the mental foramina. The
150 transversal section of the mandibular canal becomes slightly dorso-ventrally compressed
151 at mid-length, but immediately assumes its former shape anteriorly. As described for *M.*
152 *crassicaudata*, several parallel canals are present along the entire length of the
153 mandible. The density of these small canals is particularly high in the anterior portion of
154 the mandible as well as in the posterior part, at the level of the mandibular foramen.

155 Their morphology is in all aspects similar to the structures observed in *M. crassicaudata*,
156 including the presence of a couple of vertical canaliculi that project dorsally and open
157 through two small foramina in the pseudo-tooth, as well as the presence of a couple of
158 canaliculi that reach the mandible surface in all directions. The mandible presents five
159 mental branches: the three more posterior ones (Figure S1E, mb3-5) are short and
160 small, and open laterally in small elliptical foramina posterior to the pseudo-tooth; the
161 largest mental branch (Figure S1E, mb2) drifts antero-laterally to form a short branch at
162 the level of the prong, opening in a large diamond shaped foramen; the most anterior
163 mental branch (Figure S1E, mb1) represents the last remaining part of the main
164 mandibular canal that projects anteriorly and opens just ahead of mb2 in an low and
165 antero-posteriorly elongated foramen anterior to the pseudo-tooth.

166

167 **Nine-banded armadillo (*Dasypus novemcinctus*)**

168 *Dasypus novemcinctus* displays a thin, low and elongated horizontal ramus and a
169 slightly broader ascending ramus characterized by its high and slender coronoid
170 process. Anteriorly, the mandible is extremely low and transversely compressed, and
171 displays a short symphysis. It is higher posteriorly and becomes transversely wider at
172 the level of the tooth row. The dental formula is c 1, p 7, m 1. The anterior quarter of the
173 mandible is completely toothless but an alveolus for a canine [S3,S4] is visible at the
174 level of the first mandibular foramen (Figure S1F, mb1), and is separated from the rest of
175 the tooth row by a small diastema. The molar is not erupted. This specimen displays two
176 mental foramina: the most posterior one (mb2) is located between the second and the
177 third premolars while the anterior one (mb1) opens anteriorly to p 1.

178 Below the anterior edge of the coronoid process, a slightly elongated mandibular
179 foramen opens on the medial surface of the ascending ramus, at roughly the same
180 height of the alveoli. It projects ventrally with an inclination of around 14° until the

181 posterior end of the tooth row. The canal describes a shallow dorsal facing concavity
182 contouring the alveoli ventrally and accompanying the curvature of the ventral edge of
183 the horizontal ramus. Immediately anteriorly to the third premolar, a slightly antero-
184 dorsally inclined posterior mental foramen is present on the medial side of the mandible.
185 Anteriorly to the first molar, the main branch of the mandibular canal opens laterally in an
186 antero-posteriorly elongated mental foramen. This foramen is particularly large and
187 elongated. Anteriorly to the first molar, a dorsal canaliculus with a rather large diameter
188 is also oriented antero-dorsally in the direction of the alveolus for the canine. The
189 canaliculus opens in the alveolus and continues anteriorly – with less than half the
190 diameter – to split into two ramifications. The most posterior ramification bifurcates just
191 dorsally to mental foramen 1 and opens into two small foramina (Figure S1F, dc 1c,d) on
192 the dorsal margin of the mandible. The anterior ramification (dc 1a,b) describes a long
193 trajectory antero-ventrally to dc 1c,d, and bifurcates near the anterior tip of the mandible.
194 All bifurcation of the dorsal canaliculus (dc 1a,b,c,d) open into tiny foramina on the
195 dorsal side of the mandible.

196 In a juvenile specimen (USNM 020920), the canal does not open directly into the
197 first five premolars and the canine. Therefore, the juvenile mandible displays longer
198 dorsal canaliculi for the premolar dentition than the adults. A large dorsal canaliculus is
199 associated to the first molar, which is absent. Anterior to the canine, a dorsal canaliculus
200 projects anterodorsally, splitting in a plexus of three smaller canaliculi that open dorsally
201 in three individual foramina. The dorsal canaliculi pattern is similar to the one observed
202 in adults.

203

204 **Hairy long-nosed armadillo (*Dasybus pilosus*)**

205 The anterior part of the slender mandible is sharp and its height slightly increases at
206 mid-length of the horizontal ramus. A row of rather spaced peg-like teeth occupies the

207 second third of the mandible. *D. pilosus* presents a c 1, p 7, m 1 lower dental formula.
208 The c1 and m1 present a basic peg-like shape. The anterior four mental foramina are
209 positioned between the p 3 and the margin of the most anterior and largest mental
210 foramen (Figure S1G, mb1), at the level of the fused symphysis. The most posterior and
211 smallest of the five mental foramina is located posterior to the m 1 alveolus.

212 The symphysis is elongated, reaching the level of the anterior margin of mb1.
213 The mandibular canal is ventrally positioned at the level of the alveolar portion of the
214 mandible. The canal opens posteriorly in a high mandibular foramen and extends
215 ventrally towards the centre of the tooth row at the level of the fourth premolar. From this
216 point it projects slightly dorsally, accompanying the shape of the mandible, until the level
217 of mental foramen 3. Anterior to mb3, the mandibular canal presents a straight
218 trajectory. Immediately dorsal to the mandibular canal, the horizontal ramus displays a
219 small canal that originates in the p 6 alveolus and passes through all alveoli until p 2.
220 From this point it projects antero-dorsally, as a dorsal canaliculus, to reach the p 1
221 alveolus. From this alveolus it projects further antero-dorsally to the c 1 alveolus and
222 extends in the same direction until the level of third mental foramen. This dorsal
223 canaliculus presents a bifurcation anterior to c 1 (Figure S1G). A second dorsal
224 canaliculus arises at the level of mental foramen 3, bifurcating and ending just anteriorly.
225 Neither of these canaliculi reaches the dorsal margin of the mandible. No foramina open
226 in the anterior part of the mandible, close to the symphysis.

227

228 **Giant armadillo (*Priodontes maximus*)**

229 The mandible is long and displays a long tooth row extending for about half its total
230 length. Similarly to *D. novemcinctus* and *D. pilosus*, the mandible is narrow, transversely
231 compressed, although it is slightly more robust. As in anteaters, this mandible presents a
232 medio-lateral rotation anteriorly. The left tooth row is composed of 22 hypselodont teeth,

233 23 on its right counterpart. In lateral view, three mental foramina (Figure S1H, mb 1-3)
234 can be observed just anterior the tooth row. A fourth small one is present in the same
235 area, but appears to be an extra branching of mental foramen (mb1) with no symmetrical
236 branch on the right hemi-mandible.

237 The transversely compressed mandibular canal of *P. maximus* exhibits some
238 differences compared to the other genus of armadillo here studied. The mandibular
239 foramen is dorsoventrally elongated as in *Dasypus* but its position is more dorsal in the
240 ramus when compared to the alveolar plane. The canal extends ventrally with a weak
241 inclination ($\sim 12.2^\circ$). Posterior to mf 22, a large dorsal canaliculus (Figure S1H, dc3),
242 slightly inclined posteriorly, projects dorsally and opens into several small foramina.
243 Anteriorly, although alveoli for mf 1 and mf 2 are almost adjacent to the canal, small
244 dorsal canaliculi are visible. As the canal projects ventrally towards alveolus for mf16,
245 the dorsal canaliculi become longer. Their morphology varies, being anteriorly oriented
246 and sometimes bifurcated. These canaliculi vary in diameter and can bifurcate (e.g.,
247 below alveolus for mf 17 and mf 18, Figure S1H), with a branch projecting dorsally and
248 the other anteriorly, to merge with the immediately anterior dorsal canaliculus. Anteriorly
249 to alveolus of mf 16 the mandibular canal displays a parallel trajectory to the alveoli row
250 until alveolus for mf 9. From this point, it projects dorsally until mental foramen 1, being
251 positioned immediately ventral to the nine most anterior alveoli. Along its path to the
252 symphyseal portion of the mandible, the mandibular canal displays several minor mental
253 branches before it splits into three larger mental canals (Figure S1H, mb 1-3) anterior to
254 the first alveolus. The most posterior and smaller mental branch splits from the main
255 canal right anteriorly to alveolus for mf 1, projecting anterodorsally and then drifting
256 laterally. A second larger mental branch (mb2) splits anteriorly, departing from the
257 dorsolateral part of the mandibular canal and opening in an antero-posteriorly elongated
258 foramen. The most anterior and largest mental branch (mb1) also opens into an antero-

259 posteriorly elongated foramen. A more anterior small branch is visible on the lateral side
260 of the mandible, but corresponds to a small ramification of the largest mental branch
261 (mb1). Another canaliculus of the mandibular canal, which splits from the posterior part
262 of the mb1, continues anteriorly toward the antero-dorsal end of the mandible. This small
263 canaliculus (dc1) divides into three smaller ramifications, which open on the medial side
264 of the anterior tip of the mandible.

265

266 **Aardwolf (*Proteles cristatus*)**

267 *Proteles cristatus* displays a mandible with a relatively high horizontal ramus displaying
268 an anteriorly projected anterior margin. The specimen displays the following dental
269 formula: i 3, c 1, p 2, m 2. This mandible displays three mental foramina (Figure S1I,
270 mb1-3), with the first and second mental foramina displaying oval apertures of similar
271 size. The first mental foramen is located on the anterior margin of the mandible and the
272 second one is anterior to the canine, below the anterior end of the diastema. The third
273 mental foramen is located below the diastema, half way through the height of the
274 mandible.

275 The mandibular foramen is oval shaped, located in the middle of the ascending
276 ramus, antero-ventral to the dorsal tip of the coronoid process. The mandibular canal
277 has an oval section, being noticeably dorso-ventrally elongated from the anterior end of
278 the coronoid process to the level of the m 1. The mandibular canal projects slightly
279 ventrally until the posterior limit of the diastema. None of the four cheek teeth alveoli is
280 adjacent to the mandibular canal. The first and second molars are dorsally placed
281 relative to the canal; no dorsal canaliculus reaches their alveoli. The inferior alveolar
282 nerve and artery branches reach the teeth through the many hollow cavities of the
283 alveolar portion of the mandible. The trabecular nature of the molar area is particularly
284 evident anteriorly (Figure S1I), dorsally and posteriorly to the premolar alveoli, almost

285 reaching the dorsal edge of the mandible. Posteriorly, fused trabeculae form a sort of
286 posteriorly projecting canals, which reach the dorsally placed m 1 and m 2 alveoli.
287 Anterior to the c, below the diastema, three mental branches (Figure S1I, mb1-3) split
288 and project antero-dorsally. Mb3 projects dorsally and opens laterally right ventrally to
289 the midpoint of the diastema. Mb2 projects antero-dorsally and is laterally inclined,
290 opening latero-ventrally to the canine. Mb1 is long and projects antero-dorsally, passing
291 through the middle of i 2 and i 3 and opens in the anterior margin of the mandible.

292

293 **Dog (*Canis lupus*)**

294 *Canis lupus* presents a mandible with a high ascending ramus, with a relatively broad
295 coronoid process. The mandible presents 11 tooth loci (i 3, c 1, p 3, m 3) and contrasts
296 with *P. cristata* in its complete tooth row (no diastema), its shorter symphysis and rather
297 vertical anterior margin. Four mental foramina are present (Figure S1J, mb1-4). The first
298 mental foramen opens anteriorly, ventral to i 2. The second and largest mental foramen
299 opens laterally between p 1 and c 1. The third mental foramen opens at the level of the
300 anterior root of p 3 and the fourth mental consists of a rather small lateral aperture
301 located between the ventral tips of the anterior and posterior roots of p 4 and p 3,
302 respectively.

303 The mandibular foramen resembles *P. cristata*, yet the canal projects slightly
304 more ventrally. Just posteriorly to the anterior edge of the coronoid process, the
305 mandibular canal becomes more extended anterodorsally (Figure S1J), displaying a
306 pseudo elliptical cross section. This is a main characteristic of the mandibular canal of
307 the dog. With the exception of m 3, teeth are rooted deeply enough to be in close
308 contact with the dorsal edge of the mandibular canal. The trajectory of the mandibular
309 canal follows the shape of the ventral margin of the mandible from the level of the
310 posterior root of m 1 until p 2, where it branches (Figure S1J). The large m 1 is so deeply

311 rooted that both its roots protrude ventrally into the mandibular canal. Along its
312 trajectory, the mandibular canal is topped by a complex of trabeculae that surrounds the
313 tooth roots. From about the second m 1 cusp, the mandibular canal gradually decreases
314 in height anteriorly. All but the small fourth mental branch project anterolaterally. Mb4 is
315 a very thin branch that projects posterolaterally below the posterior edge of p 3. Mb3 is
316 comparatively larger and splits from the mandibular canal just ventrally the anterior root
317 of p 3. Mb2 is large in diameter and projects anterolaterally ventrally to p 2 to open in an
318 oval-shaped foramen between p1 and c (Figure S1J). Mb1 is a rather thin and extremely
319 long ramification of the mandibular canal that projects anteriorly to pass dorsally to the c
320 and i 1-3 roots and open in the anterior margin of the horizontal ramus. In its trajectory,
321 mb1 opens to the alveolus of i 3. Dorsally to the branching point of mb1, a relatively
322 large accessory branch of the mandibular canal projects anterodorsally. This branch is
323 medially oriented and almost reaches the symphysis, posterior to which it divides into
324 several trabeculae.

325

326 **Pale-throated three-fingered sloth (*Bradypus tridactylus*)**

327 In the adult *Bradypus tridactylus*, the mandible is characterized by a short but robust
328 horizontal ramus, bearing one caniform (Cf) and three molariform teeth (mf 1-3), and a
329 high ascending ramus. The tooth row almost occupies the entire length of the body of
330 the mandible, with teeth inclination becoming more medial along the antero-posterior
331 axis. All four teeth are tall, lack roots and are deeply rooted in the mandible. The
332 mandible presents two mental foramina with one at the anterior tip of the mandible
333 (Figure S1K, mb 1) and a larger one at the level of the mf 4 (Figure S1K, mb2).

334 The morphology of the mandibular canal is very distinct from that observed in
335 anteaters and armadillos. The mandibular foramen is elliptical in shape, with the major
336 axis oriented anteroposteriorly with a similar inclination to the condylar process. The

337 canal projects antero-ventrally from the mandibular foramen until it reaches its lowest
338 position in the mandible, at the level of the mf 3. At the same level, but higher in the body
339 of the mandible, the largest and most posterior mental branch opens on the lateral side
340 of the mandible, after branching midway between the mandibular foramen and the
341 lowest mandibular canal position. The mandibular canal then runs anteriorly and
342 gradually projects dorsally in the mandible until it reaches mental foramen 1. There is
343 one small dorsal canaliculus (dc 1-3) for each of mf 1, mf 2 and mf 3. Dc4 originates
344 ventrally to mf3 but extends anterodorsally to reach the alveolus on its anterior margin.
345 The mandibular canal runs medial to the first tooth and divides into dorsal and mental
346 branches. The mental branches follow the same direction and inclination as the main
347 branch and eventually reach the anterior tip of the mandible, lateral to the symphysis.
348 The dorsal canaliculus assumes a steep trajectory (roughly parallel to the anterior
349 margin of the mandible) and exits the mandible dorsally. This dorsal canaliculus likely
350 corresponds to a remnant of the innervation/vascularization of an additional tooth locus
351 identified in a previous work [S5] and opens anteriorly to alveolus for Cf. The juvenile
352 specimen (ZMB 18834) displays a vestigial tooth in the same position; its mandibular
353 canal of the foetus presents a similar general morphology, differing in number of mental
354 and medial branches. The foetal mandible presents four foramina for accessory
355 branches that open in the medial side of the mandible and four mental foramina. This
356 mandible is much less ossified, compared to the adult.

357

358 **Two fingered sloth (*Choloepus hoffmanni*)**

359 The mandible of *Choloepus hoffmanni* presents shallower horizontal and ascending rami
360 compared to *B. tridactylus*. The anterior tip of the horizontal ramus is shovel-shaped and
361 elongated. The mandible bears three molariform teeth (mf 1-3) and one anterior
362 caniniform tooth (cf). In total, the *C. hoffmanni* mandible presents four mental foramina,

363 a large one at the level of the root of the coronoid process and three small ones anterior
364 to the caniniform tooth.

365 Due to the differences in mandible shape, the morphology of the mandibular
366 canal is also different between the two sloth genera. Here again, the dorsal canaliculi of
367 the mandibular canal are present when the tooth alveoli are more dorsal. The canal
368 starts at the level of the dorsal edge of the horizontal ramus and runs anteriorly until it
369 reaches the level of the posterior margin of the tooth row. At this level, the mandibular
370 canal bifurcates, with a mental branch (Figure S1L, mb4) projecting antero-laterally to
371 open in a large mental foramen, just anteroventrally to the root of the coronoid process.
372 The main branch projects medially from the mandibular foramen, passing marginally
373 ventrolaterally to mf 3. A small dorsal canaliculus of the mandibular canal (Figure S1L,
374 dc 10) projects medially and allows for the innervation and vascularization of mf 3, which
375 is medially oriented. As the mandibular canal runs anteriorly, its position gradually
376 changes to a more medial one. This contrasts with the morphology of the mandible of
377 the adult *B. tridactylus*, in which the mandibular canal is medially positioned along the
378 entire length of the tooth row. Two dorsal canaliculi of the mandibular canal (df8-9) are
379 ventral to the anterior half of mf2. Three dorsal canaliculi (dc5-7) reach the alveolus for
380 mf 1. Dc5 is a small canal that splits at mid-length of the alveolus and joins the main
381 canal just anteriorly to it (Figure S1L). From this canal, three small dorsal projections
382 reach the alveolus. Two smaller additional innervation/vascularization canaliculi are
383 present posteriorly (Figure S1L, dc 6-7). Close to the symphysis, the mandibular canal
384 steadily projects dorsally. The main branch passes medially to the cf and, as in *B.*
385 *tridactylus*, its position is dorsal to the base of the alveolus. In fact, dorsal canaliculi
386 reach the alveolus of the cf. The more posterior canaliculus (Figure S1L, dc4) bifurcates
387 from the mandibular canal antero-ventrally just anterior to the alveolus for the cf.
388 Anteriorly, a small canaliculus (dc3) splits from the mandibular canal and projects

389 laterally into the same alveolus. The third canaliculus that connects to the alveolus of the
390 cf (dc1) is located just anterior to the mandibular canal steep antero-dorsal projection in
391 the direction of the anterior tip of the mandible. A long dorsal canaliculus (Figure S3B,
392 dc2) splits from the mandibular canal in the direction of the rudimentary alveolus of the
393 vestigial tooth that is observed on earlier ontogenetic stages. The vestigial alveolus,
394 located just antero-medially to the anterior edge of cf, is also innervated/vascularized,
395 with the dorsal canaliculus further splitting in two ventrally to its dorsal opening. Three
396 small mental branches (Figure S1L, mb1-3) are present in the anterior part of the
397 mandible: the most posterior (mb3) departs from the mandibular canal to open laterally
398 at the level of mb2; mb2 projects dorsolaterally near the dorsal margin of the mandible;
399 mb1 splits at about the same length as mb2, but projects anterolaterally. Anteriorly to the
400 level of the foramen for mb1, a small branch (Figure S1L, ab) reaches the mandible
401 shovel-shape projection and further divides into two small canals that open dorso-
402 medially. These canals are not present in *B. tridactylus*.

403 The mandible of the foetus of *Ch. didactylus* (ZMB 4949) presents a lower level
404 of ossification and allometric shape differences. Nevertheless, the mandibular canal of
405 the foetus presents the same branch pattern as observed in the adult.

406

407 **Aardvark (*Orycteropus afer*)**

408 This mandible consists of a transversely compressed long and shallow horizontal ramus
409 and a comparatively very high ascending ramus. The anterior half of the horizontal
410 ramus is edentulous, while its posterior half presents three molars and two premolars (i
411 0, c 0, p 2, m 3; Figure S1M). The molars are large and deeply rooted and display an
412 ob lanceolate shape in dorsal view; the premolars are much smaller, transversely
413 compressed, and are rooted more dorsally. The mandible of *Orycteropus afer* displays
414 four major mental foramina (Figure S1M, mb1-4), with six small mental branches

415 laterally positioned compared to the tooth row (Figure S1M, mb5-10). A total of seven
416 foramina for dorsal canaliculi are present. The anteriormost four foramina are aligned
417 just anteriorly to p 5 (*sensu* [S6]; dc3). Another small foramen is present anteriorly, at the
418 level of the third mental foramen (dc2). Two slightly larger and longer foramina open
419 between mental foramina 1 and 2 (dc2). The most anterior foramen (dc 1) opens
420 anteriorly in the middle of the anterior apical portion of the mandible. The dc1 foramen
421 resembles the reticular alveolar foramen of whales [S7,S8].

422 The mandibular foramen is narrow and located well above the tooth row level,
423 from where the canal projects ventrally. Between m 3 and m 1, the trajectory of the
424 mandibular canal changes as it gradually projects dorsally, accompanying the height
425 decrease of the horizontal ramus. The mandibular canal is adjacent to alveoli of m 1-3
426 and dorsal canaliculi are absent. From m 3 to p 5, only mental branches bifurcate from
427 the mandibular canal (mb 5-10). The p5 and p6 alveoli are placed more dorsally in the
428 mandible and are connected to the mandibular canal by two dorsal canaliculi, which
429 project antero-dorsally. The two canaliculi dorsal to p 5 and p 6 (dc3 and dc4) are
430 connected by a small canal parallel to the mandibular canal. Anterior to p 5, the main
431 dorsal canaliculus (dc3) steadily extends dorsally, and then divides into four small canals
432 linked to foramina dorsally. At the level of mb4, dc3 projects ventrally to merge with the
433 mandibular canal, and a new dorsal canaliculus (dc2, Figure S1M) projects antero-
434 dorsally. Dc 2 is long and presents a small diameter. It bifurcates three times: just
435 anteriorly to its origin, a small ramification projects antero-dorsally to open at the level of
436 mb4; the dorsal canaliculus continues anteriorly and bifurcates again between mb1 and
437 mb2, with one branch projecting antero-dorsally but never opening dorsally; a thin
438 branch of dc2 continues until it splits in several smaller canals near the third mental
439 foramen, with one of them opening dorsally at the level of the second mental foramen.
440 Mb2 and dc1 split near the anterior end of the mandibular canal. Dc1 bifurcates – with

441 one branch projecting antero-dorsally and the other anteriorly – before it opens in two
442 foramina. The most posterior branch of dc1 opens at the level of the second mental
443 foramen. The most anterior canaliculus reaches the anterior tip of the mandible, ending
444 in a foramen similar in position to the reticular alveolar foramen found in *rorquals*
445 [S7,S8].

446

447 **Giant otter-shrew (*Potamogale velox*)**

448 The mandible of *Potamogale velox* presents a relatively low horizontal ramus with a
449 rather long and anteriorly inclined symphysis. The ascending ramus of is high due to the
450 presence of a broad sub-triangular coronoid process. The tooth row is composed of ten
451 teeth (i 3, c 1, p 3, m 3). Three mental foramina are present in the mandible (Figure S1N,
452 mb1-3). The first mental foramen is small and opens on the anterior margin of the
453 mandible. The second and third mental foramina are relatively larger and open laterally
454 at the level of p1 and the posterior root of m1, respectively.

455 The mandibular foramen has a pseudo circular shape. Posteriorly, the
456 mandibular canal presents a slightly descending trajectory until it reaches the m 2. The
457 trajectory is then practically horizontal until the canine. Small complexes of trabeculae
458 are present dorsally to the mandibular canal. The trabeculae surround the tooth roots,
459 which are deeply implanted in the mandible. With the exception of the c and i 1-3, all
460 alveoli enter in contact of the mandibular canal. The most posterior mental branch
461 (Figure S1N, mb3) is the largest in diameter and projects laterally at the level of the tip of
462 m 1 posterior root and opens slight dorsally in an elliptical shaped foramen. At the level
463 of p 2, the trajectory of the canal drifts slightly dorsally, accompanying the small ventral
464 concavity of the ventral edge of the horizontal ramus. Two branches split from the
465 mandibular canal, dorsal to p 1, and project laterally. These branches merge into one
466 larger mental branch, opening laterally in a single foramen (Figure S1N, mb2). Mb1

467 consists of a rather long branch, small in diameter, which projects anteriorly (Fig S1N,
468 mb1). This branch passes ventrally to c alveolus and gradually projects dorsally to open
469 anteriorly, between i 2 and i 1. Two accessory branches of the mandibular canal split at
470 the level of p 1 and c. The posterior one projects anterodorsally until it divides into a
471 trabeculae complex at the level of i 3 and i 2 alveoli. The anterior one also projects
472 anterodorsally but it meets the trabeculae briefly anteriorly to its branching point. This
473 trabeculae complex is located medially in the mandible and is associated with the i 2
474 alveolus and the symphysis.

475

476 **Anatomical description of additional taxa**

477 A total of 12 species were segmented in order to reconstruct the phylogenetic history of
478 the absence/presence of dorsal canaliculi (Figure 1). One Afrosoricida (*Tenrec*
479 *eucaudatus*) and one Macroscelidea (*Rhynchocyon petersi*) were additionally
480 segmented to increase the number of species with relatively close phylogenetic affinities
481 to *Orycteropus afer* (Figure 1). Neither of the 12 species described in this section
482 presents dorsal canaliculi. With the exception of the brown rat (*Rattus norvegicus*) and
483 the velvet free-tailed bat (*Molossus molossus*), all the species present mandibular canals
484 very similar in shape (Figure S2A-I). The mandibular foramen displays a descending
485 trajectory anteriorly until the third molar (m 3). It projects anteriorly, ventrally to the tooth
486 row, with its dorsal margin that usually opens directly to adjacent post-canine tooth
487 alveoli (Figure S2). In some species (e.g., *Dasyurus hallucatus*, *Lemur catta*,
488 *Cynocephalus volans*, or *Procavia capensis*; Figure S4A-D) a large amount of trabecular
489 tissue is visible around the teeth, and connects the mandibular canal to the alveoli, only
490 when both structures are not adjacent to each other. The Malayan tapir (*Tapirus indicus*,
491 Figure S2E) constitutes the most remarkable case of innervation/vascularization via
492 trabeculae, with a mandible characterized by non-adjacent tooth alveoli and mandibular

493 canal. In almost all species, an incisor branch projects anteriorly at the level of the most
494 anterior mental branch, and usually splits into several trabeculae that wrap both canine
495 and incisor teeth. In the rock hyrax (*Procavia capensis*), however, the incisor branch
496 opens directly into the corresponding alveolus. The tailless tenrec (*Tenrec ecaudatus*,
497 Figure S2F) also presents a slightly different morphology of the incisor branch, with the
498 mandibular canal opening directly into the alveolus of the canine, with the latter being
499 connected to the following alveolus. In the brown rat (*Rattus norvegicus*, Figure S2K) the
500 incisor branch is absent, with the alveolus of the incisor tooth extending back into the
501 ascending ramus of the mandible. The innervation/vascularization of the incisor tooth
502 arrives ventral to the coronoid process, as the mandibular canal partially merges with the
503 alveolus. Although the Malayan tapir exhibits a classical incisor branching of the
504 mandibular canal, the latter differs in from other species by its extremely reduced
505 diameter (Figure S2E). The overall shape of the mandibular canal of the brown rat is
506 peculiar due to the extreme posterodorsal projection of the incisor alveolus (Figure S2K).
507 The mandibular canal merges with the incisor alveolus medially, just anteriorly to the
508 mandibular foramen. It projects anteriorly at the level of the m 3 and its trajectory follows
509 the shape of the dorsal margin of the incisor alveolus. The mandibular canal opens
510 directly to the m 3 and m 2. In the most anterior portion of the alveolar part of the
511 mandible, which corresponds to the alveolus of the m 1, the mandibular canal presents a
512 relatively ventral position relative to the first molar alveolus, the tooth being likely
513 innervated/vascularized via trabecular bone. The mandibular canal opens dorsolaterally
514 in a single mental foramen, just anteriorly to the m 1. The velvet free-tailed bat also
515 presents a distinct mandibular canal morphology (Figure S2L). Compared to other
516 species, the mandibular canal is unusually high. Here again, all pre-canine tooth alveoli
517 are adjacent to the mandibular canal. However, the mandibular canal seems to extend
518 dorsally, in between tooth roots (Figure S2). This might be a result of the scan resolution

519 compared to the reduced size of the specimen, for in other segmented placental
520 mammals, those spaces are normally filled with trabeculae (Figure S2). Apart from this
521 abnormal height, the mandibular canal of the velvet free-tailed bat resembles those of
522 other toothed species; it is positioned ventrally to the tooth row and bifurcates anteriorly,
523 with a mental branch that projects laterally while the other branch of the canal opens into
524 a trabecular system wrapping the canine and the incisors. An anterodorsally projecting
525 mental branch is also present and opens ventrally to the incisors, similar to the condition
526 observed in carnivores (Figure S2D, E).

527

528

529 **2. Homology of dorsal canaliculi between anteaters and baleen whales**

530 The trigeminal nerve originates in the pons and has two different roots, a sensory and a
531 motor root [S9]. The mandibular branch of the trigeminal is composed of both sensory
532 and motor roots and is designated by inferior alveolar nerve (IAN) [S9]. The nerve enters
533 the medial side of the mandible through the mandibular foramen, and is accompanied by
534 the inferior alveolar artery [S10]. Typically, the inferior alveolar nerve separates into four
535 types of branches [S9,S10]: the mylohyoid branch supplies the hyoid musculature; the
536 dental/inferior dental branches supply molars and premolars, each nerve branch
537 innervating one tooth; the incisor branch supplies canine and incisors. The mental
538 branch supplies the lip integument (the number of mental branches may vary between
539 taxa). Here, we will group dental and incisor branches to follow the nomenclature of
540 previous references for edentulous placentals [S7].

541 In *Tamandua tetradactyla*, the large inferior alveolar nerve (Figure 4B', IAN) is
542 placed dorsally in the mandibular canal. Two accessory branches of the IAN (Figure 4B',
543 IANa) are present dorsolaterally to the IAN. The inferior alveolar artery (Figure 4B', IAA)
544 lies dorsally to the IAN. An irregularly shaped branch of the inferior alveolar vein (Figure

545 4B', IAV) is placed laterally to the IAA. A third branch of the IAN (Figure 4B' and S3B,
546 IANa) is visible dorsally to the IAA. Dorsally to it, the ascending branch of the IAV
547 (Figure 3B' and S3B, IAVab) is present in the dorsal canaliculus of the mandibular canal.
548 A keratinous dental pad covers the dorsal part of the mandible (Figure 4C, pa). Ventrally,
549 the epidermis consists of a small layer (Figure 4C, ep) and, which lies dorsally to the
550 thick dermis layer (Figure 4C, de). In addition to connective tissue, the dermis presents
551 several blood vessels and small nerve branches. The most posterior dorsal canaliculus
552 allows for the passage of an ascending branch of the IAN (Figure 4C,C', IANab1); the
553 anterior dorsal canaliculus displays a large ascending branch of the IAA (Figure 4C,
554 IAAab) and likely features a second ascending branch of the IAN (Figure 4C, IANab2)
555 that projects anterodorsally.

556 A histological section (coronal plane) of the mandible of a bowhead whale
557 (*Balaena mysticetus*) showing the 15th vestigial tooth [S11] shows the mandibular canal
558 and associated soft tissues (inferior alveolar nerve, blood vessels) with two small canals
559 (Figure S3A, red squares) dorsally. The most dorsal small canal is most likely associated
560 to the vestigial teeth observed in the figure, while the most ventral one is associated to
561 the 14th vestigial tooth. Its position between the mandibular canal and the tooth row, plus
562 the presence of branches of the inferior alveolar artery and the inferior alveolar nerve
563 inside these small canals, highly suggest that these are homologous to the dorsal
564 canaliculi observed in the collared anteater (*T. tetradactyla*). Dorsal canaliculi are
565 anteriorly inclined in whales [S7], thus histological slices produce circular section for
566 each canaliculus.

567

568

569

570 **3. Intraspecific and bilateral variation of dorsal canaliculi**

571 Dorsal canaliculi were present in all segmented anteater (n=8) and long-nosed armadillo
572 (n=6) mandibles (Figure S4). All six long-nosed armadillos displayed an anterior dorsal
573 canaliculi plexus splitting in three to six dorsal foramina (Figure S4A-F), including the
574 juvenile (Figure S4F). A canine, as well as its corresponding dorsal canaliculus, was
575 present in two specimens (Figure S4A, F). The mandibular canal morphology was
576 similar in the six specimens. The two pygmy anteater (*C. didactylus*, n=2) mandibles
577 presented bilateral variation and showed between 15 and 17 dorsal canaliculi (MNHN
578 1986-1115, 15L/17R; BMNH 24.12.4.68, 17L/15R; Figure S4G, H). Bilateral variation
579 was observed in two collared anteaters (*T. tetradactyla*, n=3) and two giant anteaters (*M.*
580 *tridactyla*, n=3). The collared anteaters (*T. tetradactyla*) showed between 14 (MVZ
581 153482, 14L/14R) to 17 (ISEM – 788N, 17L/16R) dorsal canaliculi (Figure S4I-K). The
582 two adult giant anteaters presented 14 (ISEM – 065 V) and 13/14 (MVZ – 185238)
583 dorsal canaliculi, while the juvenile presented slightly more canaliculi with a slightly
584 larger bilateral variation (16L/18R; Figure S4L-M). Nevertheless, the observed pattern of
585 dorsal canaliculi morphology and distribution along the mandible is similar.

586

587

588 **4. Insights into the ancestral number of teeth in anteaters**

589 All known anteater fossil skulls are toothless [S12,S13]. However, our data confirmed
590 that the earliest representatives of the group were toothed, assuming the homology
591 between dorsal canaliculi and alveolar vestiges. There are, however, several limitations
592 in using the number of dorsal canaliculi to estimate tooth number: 1) it is not clear
593 whether bifurcating dorsal canaliculi would correspond to one or more alveoli– although
594 bifurcating dorsal canaliculi mostly appear to correspond to only one tooth in *P. maximus*

595 – which can lead to an overestimation of the number teeth with the present method; 2) a
596 high mandibular canal merges the lower part of the dorsal canaliculi from the posterior
597 part of the mandibular canal of the juvenile *M. tridactyla* makes it difficult to discriminate
598 dorsal canaliculi; 3) intraspecific variation may partly explained the observed number of
599 dorsal canaliculi, especially when comparing the bilateral variation to the interspecific
600 variation observed in other clades within Xenarthra (Cingulata). If we were to reconstruct
601 the dental formula based on the number of dorsal canaliculi regardless of the
602 abovementioned arguments, we would propose that each mandibular quadrant of
603 earliest Vermilinguans comprised between thirteen and seventeen teeth.

604

605

606 **5. Ancestral state estimation of the tree internal nodes**

607 Based on our dataset composed of extant species, we reconstructed the ancestral
608 condition of placental mammals concerning the presence of dorsal canaliculi (Figure
609 S5). We used the re-rooting method of Yang et al. [S14] to perform an ancestral state
610 reconstruction under a continuous time Markov chain. The posterior probabilities for the
611 presence of dorsal canaliculi are presented for each node (Figure S5). We used the
612 same tree as presented in Figure 1, obtained from www.timetree.org [S15]. This tree
613 includes 29 species and 28 internal nodes. Due to the absence of fossil taxa in the
614 analysis, all nodes presented posterior probabilities close to zero or one. The probability
615 of the presence of dorsal canaliculi was high in all nodes within Xenarthra. Excluding this
616 clade, the highest probability for the evolution of dorsal canaliculi was found in the most
617 recent common ancestor (MRCA) of cetaceans (node 12), with 4.86%. We found a
618 0.37% probability for the evolution of dorsal canaliculi in the MRCA of all placentals
619 (node 2). This suggests that the absence of dorsal canaliculi (0) likely corresponds to the

620 ancestral condition of placentals. The ancestral state reconstruction was performed with
621 the phytools package [S16] in R [S17].

622 **Supplemental references**

623

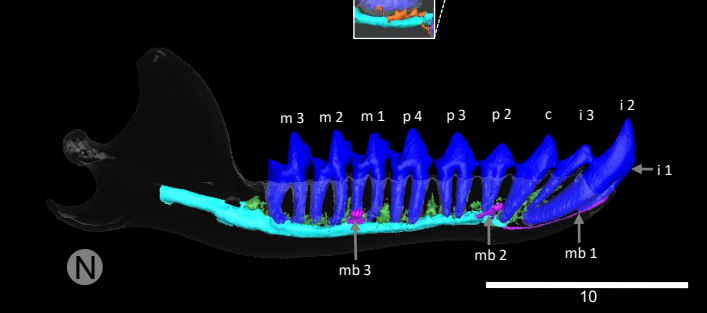
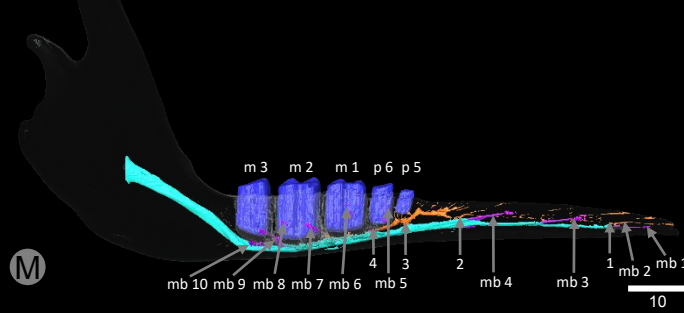
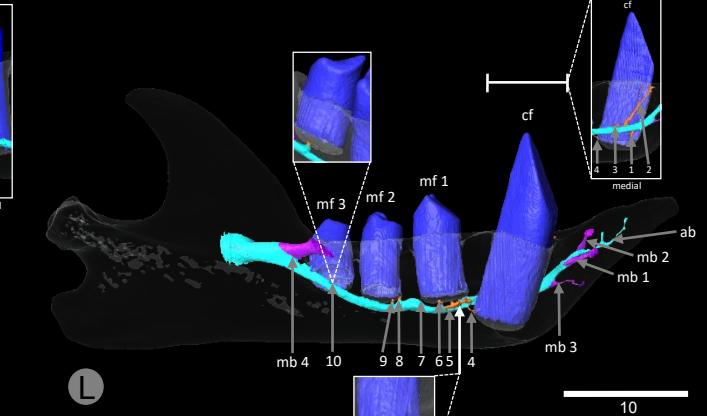
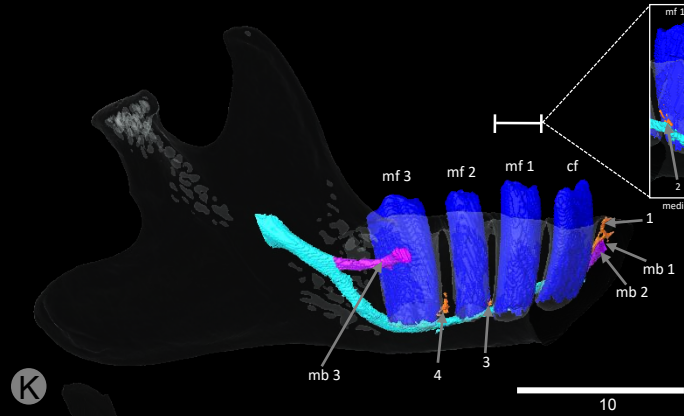
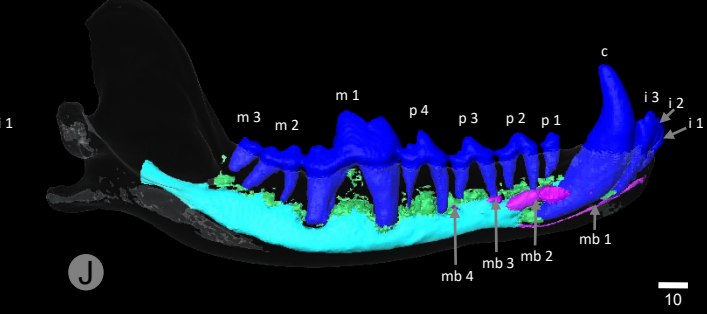
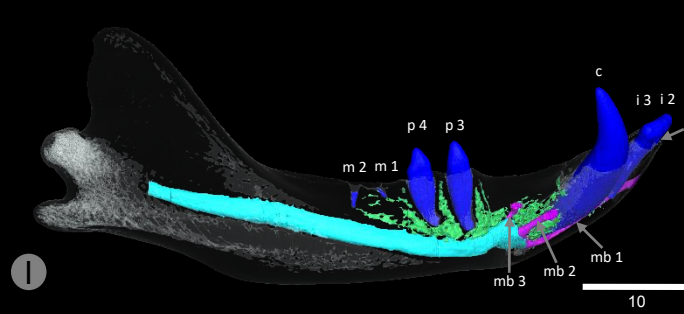
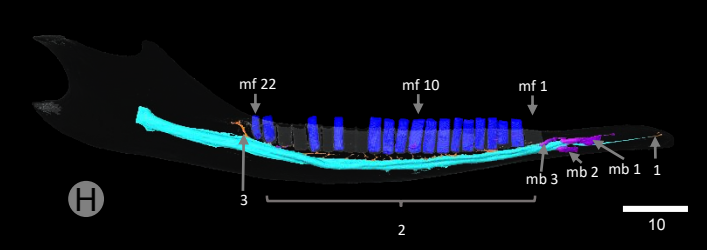
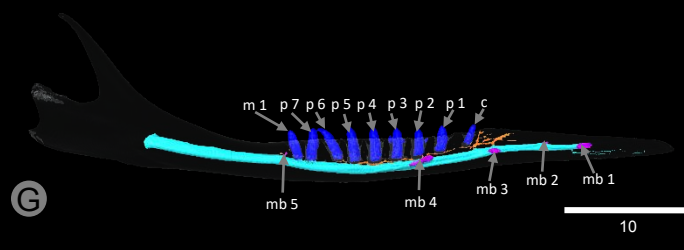
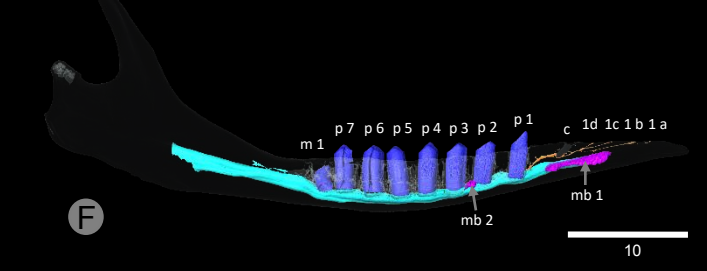
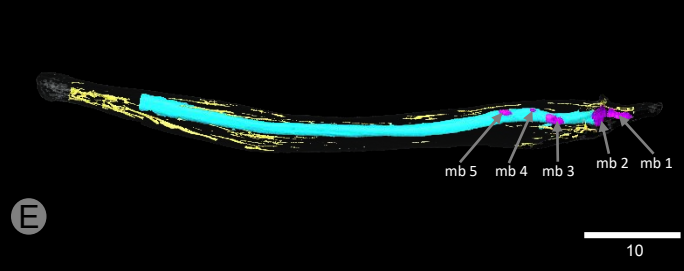

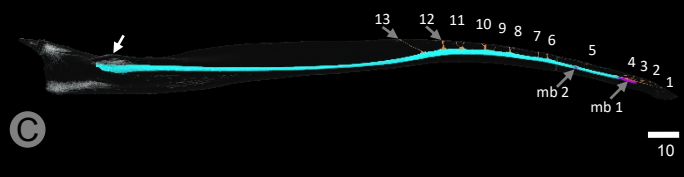
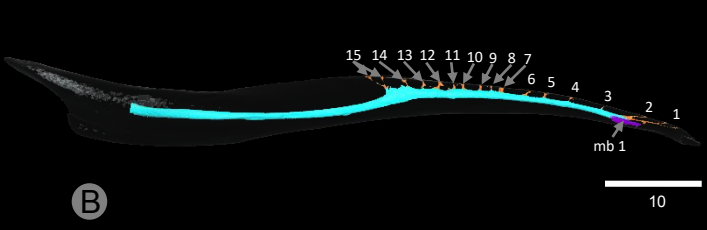
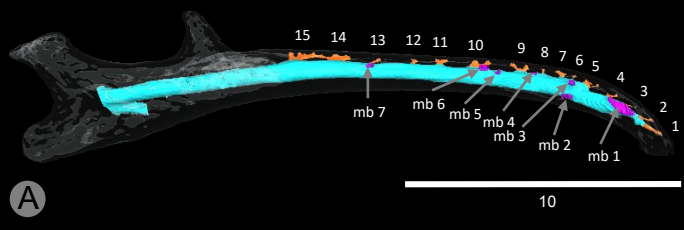
- 624 S1. Ulm, C., Kneissel, M., Hahns, M., and Solar, P. (1997). Characteristics of the
625 cancellous bone of edentulous mandibles. *Clin. oral Implant.* *8*, 125–130.
- 626 S2. Kieser, J., Kieser, D., and Hauman, T. (2005). The course and distribution of the
627 inferior alveolar nerve in the edentulous mandible. *J. Craniofac. Surg.* *16*, 6–9.
- 628 S3. Martin, B. (1916). Tooth development in *Dasypus novemcinctus*. *J. Morphol.* *27*,
629 647–961.
- 630 S4. Ciancio, M.R., Castro, M.C., Galliari, F.C., Carlini, A.A., and Asher, R.J. (2012).
631 Evolutionary implications of dental eruption in *Dasypus* (Xenarthra). *J. Mamm.*
632 *Evol.* *19*, 1–8.
- 633 S5. Hautier, L., Gomes Rodrigues, H., Billet, G., and Asher, R.J. (2016). The hidden
634 teeth of sloths: evolutionary vestiges and the development of a simplified
635 dentition. *Sci. Rep.* *6*, 27763.
- 636 S6. Anthony, R. (1934). La dentition de l'oryctérope. Morphologie, développement,
637 structure, interprétation. *Ann. Sci. Nat. Zool.* *17*, 289–322.
- 638 S7. Peredo, C., Pyenson, N., Uhen, M., and Marshall, C. (2017). Alveoli, teeth, and
639 tooth loss: understanding the homology of internal mandibular structures in
640 mysticete cetaceans. *PLoS One* *12*.
- 641 S8. Pyenson, N., Goldbogen, J., Vogl, A., and Szathmary, G. (2012). Discovery of a
642 sensory organ that coordinates lunge feeding in rorqual whales. *Nature* *485*, 498–
643 501.
- 644 S9. Greene, E.C. (1955). *Anatomy of the rat* Second Edi. (New York: Hafner
645 Publishing CO.).
- 646 S10. Gray, H. (1995). *Anatomy, descriptive and surgical* (Bristol: Parragon Book

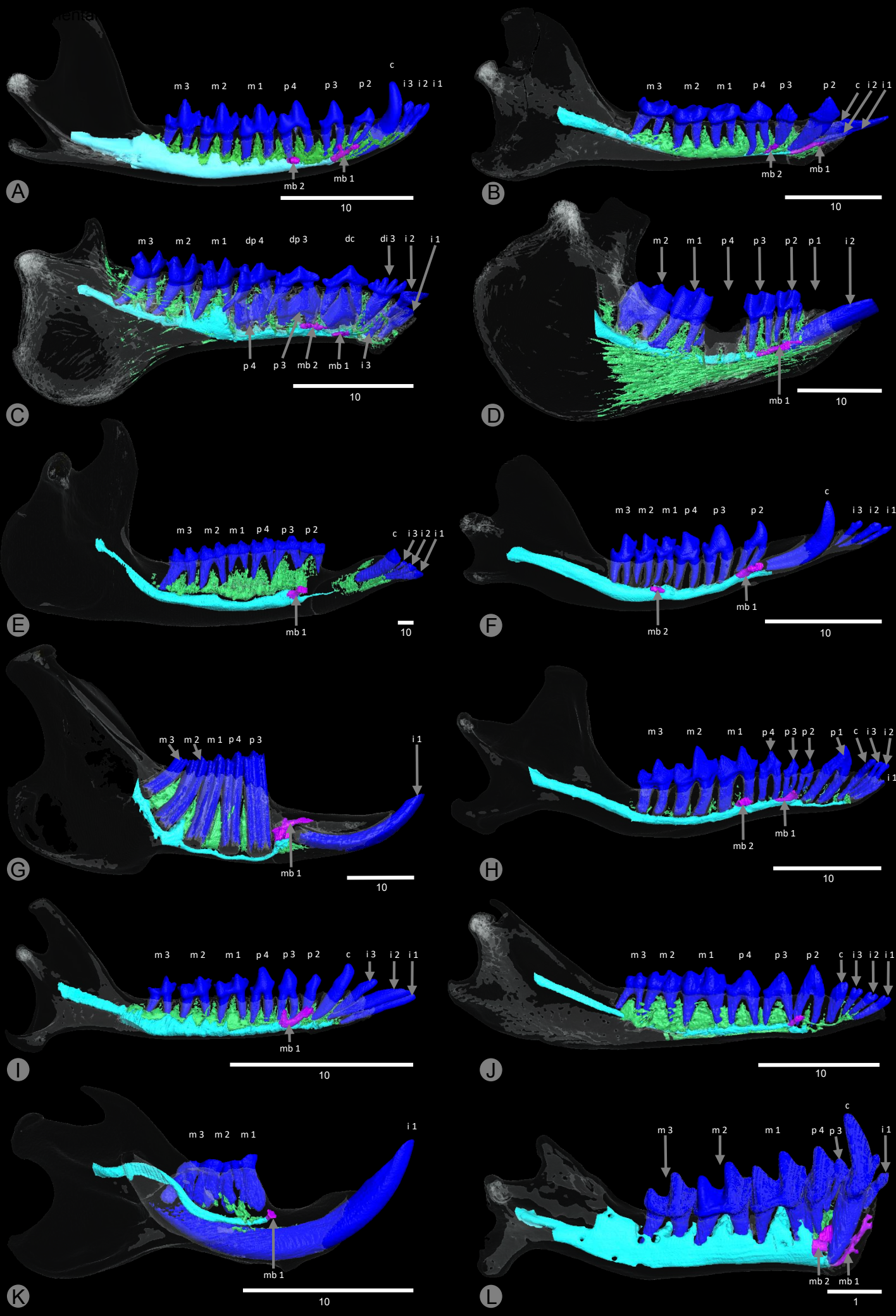
- 647 Service Ltd.).
- 648 S11. Thewissen, J.G.M., Hieronymus, T.L., George, J.C., Suydam, R., Stimmelmayer,
649 R., and McBurney, D. (2017). Evolutionary aspects of the development of teeth
650 and baleen in the bowhead whale. *J. Anat.* *230*, 549–566.
- 651 S12. Hirschfeld, S. (1976). A New Fossil Anteater (Edentata, Mammalia) from
652 Colombia, S . A . and Evolution of the Vermilingua. 419–432.
- 653 S13. Davit-Béal, T., Tucker, A., and Sire, J. (2009). Loss of teeth and enamel in
654 tetrapods: fossil record, genetic data and morphological adaptations. *J. Anat.* *214*,
655 477–501.
- 656 S14. Yang, Z., Kumar, S., and Nei, M. (1995). A new method of inference of ancestral
657 nucleotide and amino acid sequences. *Genetics* *141*, 1641–1650.
- 658 S15. Kumar, S., Stecher, G., Suleski, M., and Hedges, S.B. (2017). TimeTree: a
659 resource for timelines, timetrees, and divergence times. *Mol. Biol. Evol.* *34*, 1812–
660 19.
- 661 S16 Revell, L.J. (2012). phytools: an R package for phylogenetic comparative biology
662 (and other things). *Methods Ecol. Evol.* *3*, 217–223.
- 663 S17 Team, R.C. (2013). R: A language and environment for statistical computing.
664

Table S1. List of all studied specimens with corresponding collection number and voxel size.

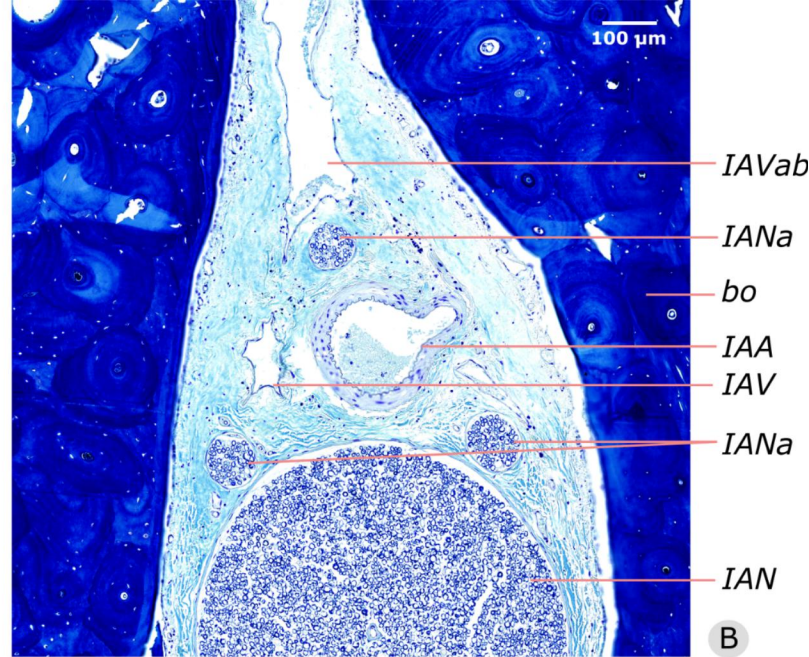
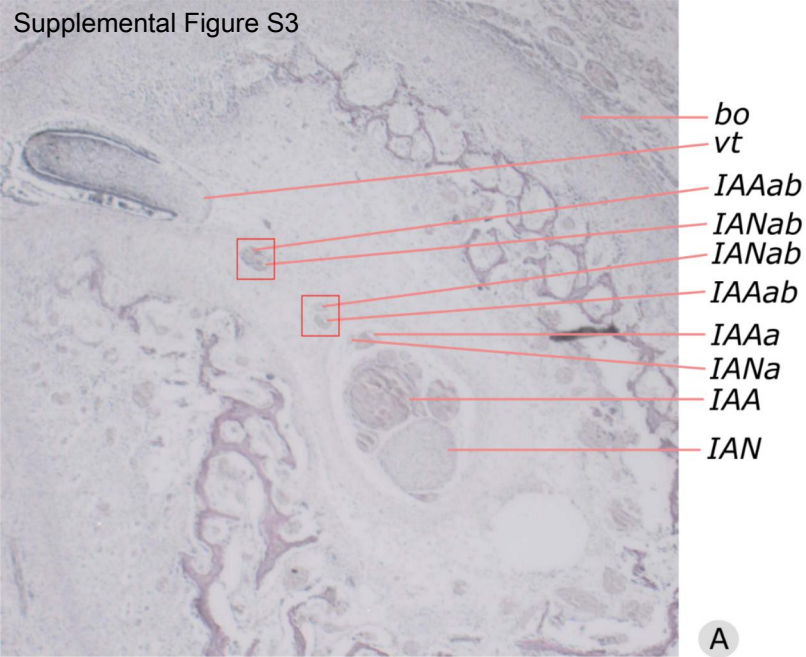
Species	Specimen	Voxel size (μm)	Scanning platform
<i>Proteles cristatus</i>	BMNH 34.11.1.5	73.6	BMNH
<i>Canis lupus</i>	LACM 23010	600.0	-
<i>Manis crassicaudata</i>	BMNH 67.4.12.298	59.2	BMNH
<i>Manis javanica</i>	BMNH 9.1.5.858	49.6	BMNH
<i>Orycteropus afer</i>	BMNH 27.2.11.113	116.5	BMNH
<i>Potamogale velox</i>	ZMB 71587	72.0	HZB
<i>Tenrec ecaudatus</i>	Martinez pers. coll.	69.4	RIO
<i>Rhynchocyon petrsi</i>	BMNH 55149	94.0	BMNH
<i>Procavia capensis</i>	UMZC H4980K	86.0	-
<i>Cyclopes didactylus</i>	MNHN 1986-1115	36.0	RIO
<i>Cyclopes didactylus</i>	BMNH 24.12.4.68	32.2	BMNH
<i>Tamandua tetradactyla</i>	BMNH 34.9.2.196	79.8	NMNH
<i>Tamandua tetradactyla</i>	ISEM 788N	57.1	RIO
<i>Tamandua tetradactyla</i>	MVZ 153482	45.1	RIO
<i>Myrmecophaga tridactyla</i>	ISEM 071 N	79.0	RIO
<i>Myrmecophaga tridactyla</i>	ISEM 065 V	74.3	RIO
<i>Myrmecophaga tridactyla</i>	MVZ 185238	63.7	RIO
<i>Bradypus tridactylus</i>	ZMB 18834	41.7	HZB
<i>Bradypus tridactylus</i>	MNHN 1999-1065	113.2	RIO
<i>Choloepus didactylus</i>	ZMB 4949	83.8	HZB

<i>Choloepus hoffmanni</i>	Hautier pers. coll.	83.9	RIO
<i>Dasyopus pilosus</i>	ZMB 19240	72	HZB
<i>Dasyopus novemcinctus</i>	USNM 033867	36.0	RIO
<i>Dasyopus novemcinctus</i>	LSUMZ 8538	36.0	RIO
<i>Dasyopus novemcinctus</i>	LSUMZ 29160	36.0	RIO
<i>Dasyopus novemcinctus</i>	BMNH 11.10.27.3	58.3	RIO
<i>Dasyopus novemcinctus</i>	ZMB 84-357	58.3	HZB
<i>Dasyopus novemcinctus</i>	USNM 020920	36.0	RIO
<i>Priodontes maximus</i>	ZMB 47528	72.0	RIO
<i>Tapirus indicus</i>	KUPRI 506	625.0(x,y)x300.0(z)	KUPRI
<i>Molossus molossus</i>	AMNH 234923	20.0	-
<i>Talpa europaea</i>	Martinez pers. coll.	89.0	RIO
<i>Cynocephalus volans</i>	FMNH 56521	65.0	-
<i>Lemur catta</i>	DPC-O92	100.0	-
<i>Tupaia Montana</i>	FMNH 108831	40.0	-
<i>Lepus europaeus</i>	DMET-LE1	137.4	-
<i>Rattus norvegicus</i>	HACB-RN1	54.0	-
<i>Dasyurus hallucatus</i>	TMM M-6921	35(x,y)x78(z)	-

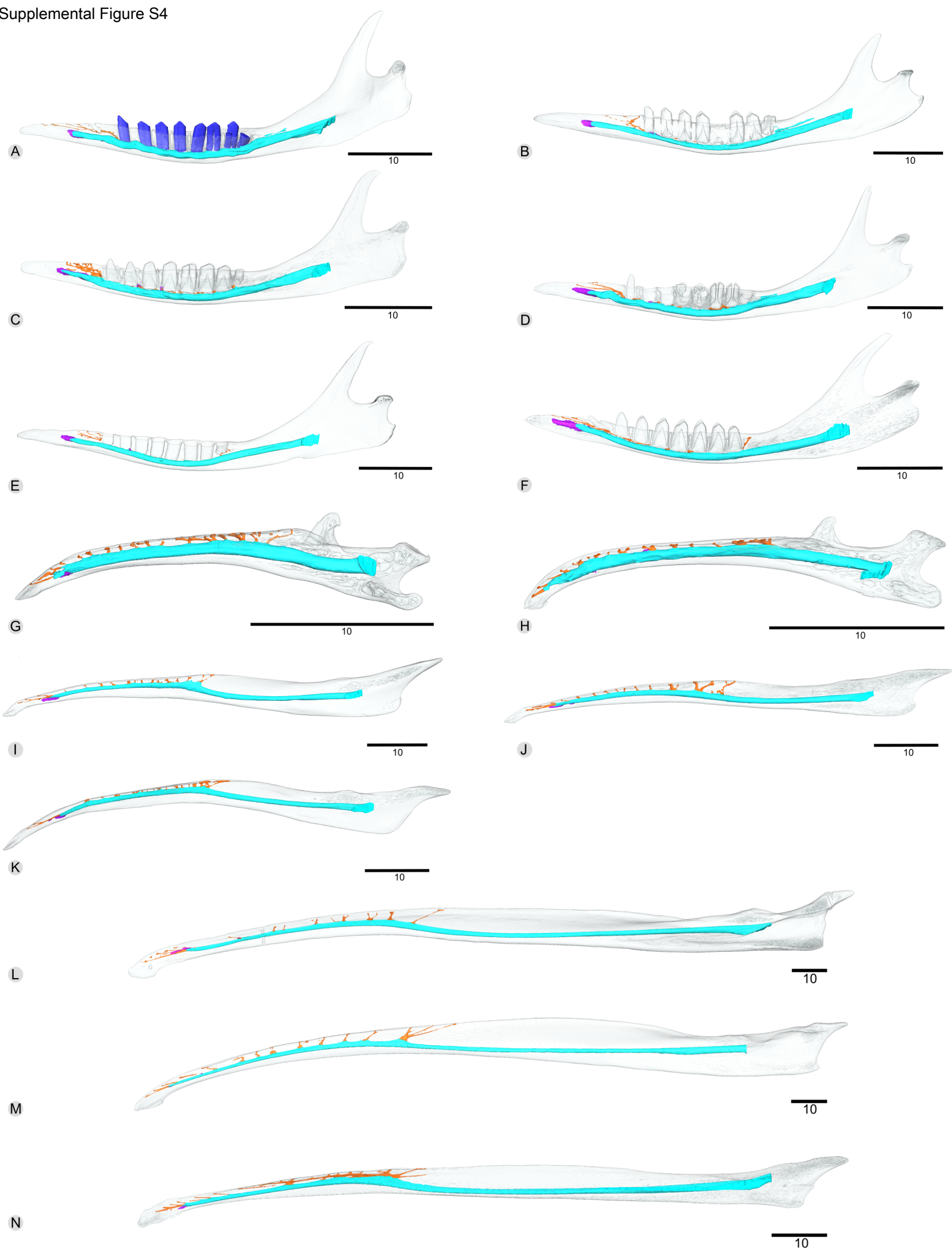




Supplemental Figure S3



Supplemental Figure S4



Supplemental Figure S5

