



HAL
open science

Feasibility of a new arthroscopic shelf acetabuloplasty technique for hip instability related to moderate dysplasia

Rémy Coulomb, Eric Wolff, Olivier Mares, Philippe Marchand, Pascal Kouyoumdjian

► To cite this version:

Rémy Coulomb, Eric Wolff, Olivier Mares, Philippe Marchand, Pascal Kouyoumdjian. Feasibility of a new arthroscopic shelf acetabuloplasty technique for hip instability related to moderate dysplasia. *Orthopaedics & Traumatology: Surgery & Research*, 2019, 105 (3), pp.441-444. 10.1016/j.otsr.2019.01.004 . hal-02137762

HAL Id: hal-02137762

<https://hal.science/hal-02137762>

Submitted on 23 May 2019

HAL is a multi-disciplinary open access archive for the deposit and dissemination of scientific research documents, whether they are published or not. The documents may come from teaching and research institutions in France or abroad, or from public or private research centers.

L'archive ouverte pluridisciplinaire **HAL**, est destinée au dépôt et à la diffusion de documents scientifiques de niveau recherche, publiés ou non, émanant des établissements d'enseignement et de recherche français ou étrangers, des laboratoires publics ou privés.

Feasibility of a new arthroscopic shelf acetabuloplasty technique for hip instability related to moderate dysplasia

Rémy Coulomb , Eric Wolff *, Olivier Mares , Philippe Marchand , Pascal Kouyoumdjian

Service de chirurgie orthopédique et traumatologique, CHU Carêmeau, place du Pr-Debré, 30029 Nîmes cedex 9, France

A B S T R A C T

Dysplasia-related hip instability causes pain and intra-articular derangement. The bone, the joint capsule, and the labrum are involved. We describe a surgical procedure of limited invasiveness that corrects the dysplasia by creating an acetabular shelf, repairs the secondary lesions by suturing the labrum and tightening the capsule, and corrects cam femoro-acetabular impingement if present.

Keywords:

Hip arthroscopy
Shelf acetabuloplasty
Hip instability
Moderate hip dysplasia

1. Introduction

The arthroscopic management of dysplasia-related hip micro-instability without osteoarthritis is challenging. Arthroscopic treatment is no longer recommended when the VCE angle is less than 15° [1–3]. In moderate or borderline dysplasia defined as a VCE angle between 20° and 25°, arthroscopic treatment of acquired lesions may produce good short-term outcomes [4]. Whereas the appropriateness of reconstructing the labrum and capsule is generally agreed on, the addition of bony procedures remains controversial. Shelf acetabuloplasty has been reported to result in good long-term outcomes in hip dysplasia with a well-centred femoral head, a VCE angle greater than 0, and minimal osteoarthritis defined as a Tönnis grade ≤ 2 [5–9]. A more invasive peri-acetabular osteotomy technique has also been advocated, despite being associated with complications in up to 10.8% of patients [10].

The objective of this cadaver study was to assess the feasibility of an original arthroscopic technique of limited invasiveness that corrects the hip dysplasia parameters by acetabular shelf augmentation, provides secondary lesion repair (labral suturing and capsulorrhaphy), and corrects cam femoro-acetabular impingement if present.

2. Operative technique

The 8 hips of 4 fresh cadavers were studied at the anatomy laboratory of the medical school in Nîmes, France. The cadavers were supine. A traction system was installed to allow access to the central compartment. We used a high-definition arthroscopy tower and a hip arthroscopy set including a 70° arthroscope (Stryker, Kalamazoo, MI, USA).

Extra-articular capsulotomy was performed with the hip flexed at 20° to obviate the need for an image amplifier [11]. The two portals used for this first step were an antero-lateral portal 1 cm anterior and proximal to the apex of the greater trochanter, for the arthroscope; and a mid-anterior portal, 5 cm distal to the antero-lateral portal, for introduction of the instruments and triangulation. Anterior and proximal mid-anterior portals served as accessory portals during the procedure (Fig. 1). The capsule was exposed using a Serfas RF XL Energy ablation probe (Stryker). An incision was made in the capsule along the axis of the femoral neck. When the incision neared the labrum, a Formula XL Blade Aggressive Plus Cutter electrical knife (Stryker) was used to avoid labral injury. The two capsular flaps were then pulled apart using PremiCron sutures (B. Braun, Melsungen, Germany) (Fig. 2). An H-shaped capsulotomy combined with medial capsulectomy provided visualisation of the entire head-neck junction.

If needed, femoroplasty was then performed using an electrical burr (Formula XL Blade 8 Flute Round Bur (Stryker)) through the antero-lateral portal. The portals were then reversed to complete the procedure. Traction was applied to expose the central compartment. The reflected tendon of the rectus femoris muscle was

* Corresponding author.

E-mail address: e.ericwolff@gmail.com (E. Wolff).

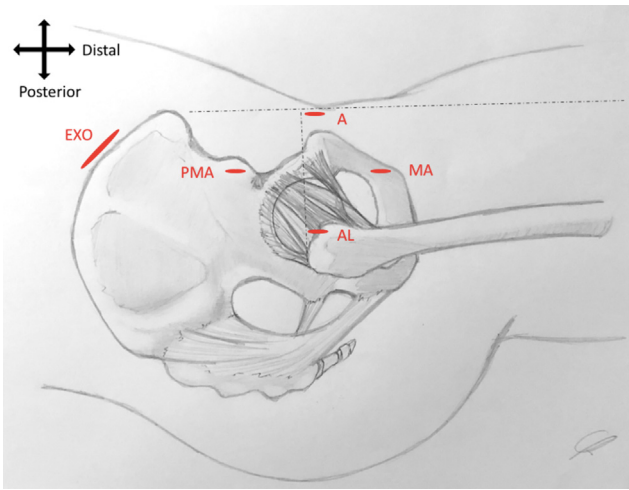


Fig. 1. Diagram showing the positions of the arthroscopy portals. AL: antero-lateral; MA: mid-anterior; PMA: proximal mid-anterior; A: anterior; EXO: exo-pelvic.

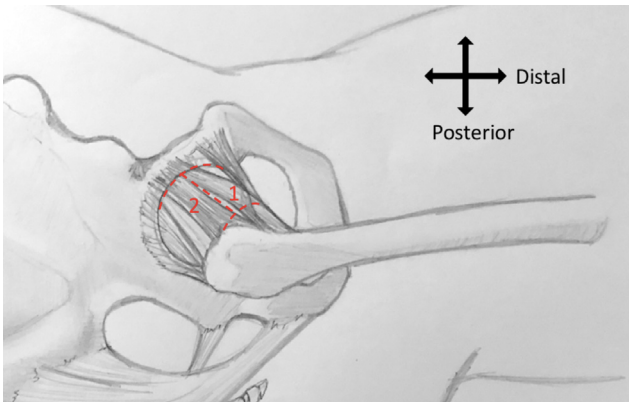


Fig. 2. Diagram of the H-shaped capsulotomy. (1) Traction suture inserted into the medial capsular flap via the anterior portal. (2) Traction suture inserted into the lateral capsular flap via the antero-lateral portal.

resected. A burr was then used to create a slot for receiving the shelf (Fig. 3); slot width was made equal to the width of the burr given that the procedure was being performed on cadaver hips free of dysplasia.

An incision centred on the gluteus medius tubercle was performed to harvest a tri-cortical graft measuring $2 \times 2 \times 1$ cm. Four tunnels were drilled into the graft: 2 vertical tunnels each 3.5 mm in diameter for the internal fixation screws and 2 horizontal tunnels each 2 mm in diameter for passing sutures from the labral repair to guide the graft into the slot (Figs. 4 and 5). To minimise the invasiveness of the procedure, the shelf harvesting approach was rasped on the exo-pelvic aspect, subperiosteally, along the iliac crest down to the roof of the acetabulum.

Labral stability, which was compromised by the acetabuloplasty, was restored by trans-osseous suturing [12]. The traction was then relaxed to check that the repaired labrum effectively sealed the joint.

The labral sutures were then threaded through the horizontal tunnels in the shelf to serve as guides as the shelf was lowered into the slot via the exo-pelvic approach. Two guidewires were inserted into the vertical tunnels to allow the implantation of compression screws (Autofix, diameter 4, Stryker) (Fig. 6). The screws were inserted antero-laterally at a 45° angle relative to the line connecting the two antero-superior iliac spines. Traction was applied

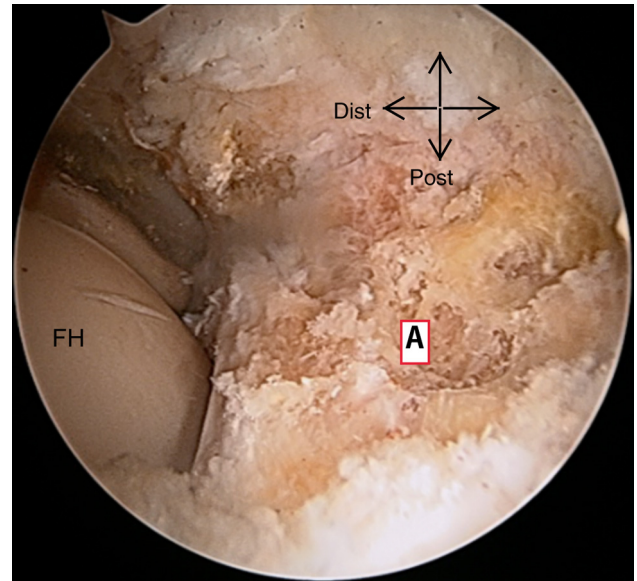


Fig. 3. Arthroscopic view of an acetabuloplasty procedure. FH: femoral head; A: acetabulum.

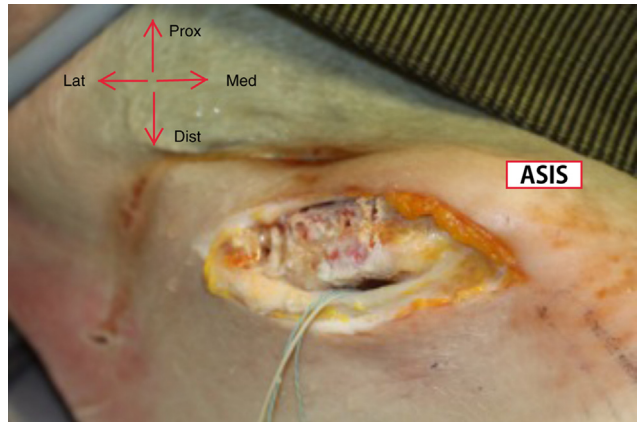


Fig. 4. Photograph of the graft harvesting site and exo-pelvic approach. ASIS: antero-superior iliac spine.

after passing the guidewires to check that no material was present within the joint.

The traction sutures placed on the medial and lateral edges of the capsular incision were recovered and knotted together in the vertical direction. This step, combined with the medial capsulectomy, served to tighten the medial capsular plane (Fig. 7).

After the procedure, the 8 hips were dissected to check that the shelf was properly positioned (Fig. 8). In all 8 hips, the shelf was flush with the labrum.

3. Discussion

This cadaver study establishes the feasibility of an arthroscopic procedure of limited invasiveness designed to correct acetabular dysplasia by creation of a shelf while also tightening the capsule and ligaments and repairing the labrum. This procedure is intended for use in patients with micro-instability of the hip related to moderate dysplasia.

Our study has several limitations. Limited tissue flexibility and absence of bleeding are inherent in cadaver studies. Tightening the capsule raised technical challenges, as the shelf hindered approximation of the tissues, thereby precluding suturing of the medial

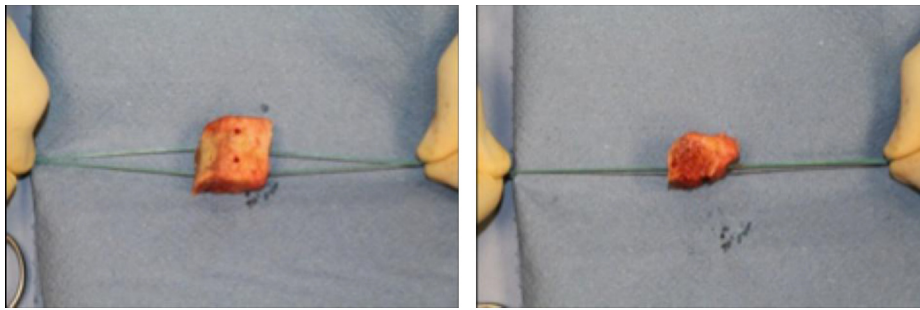


Fig. 5. Preparation of the bony shelf.

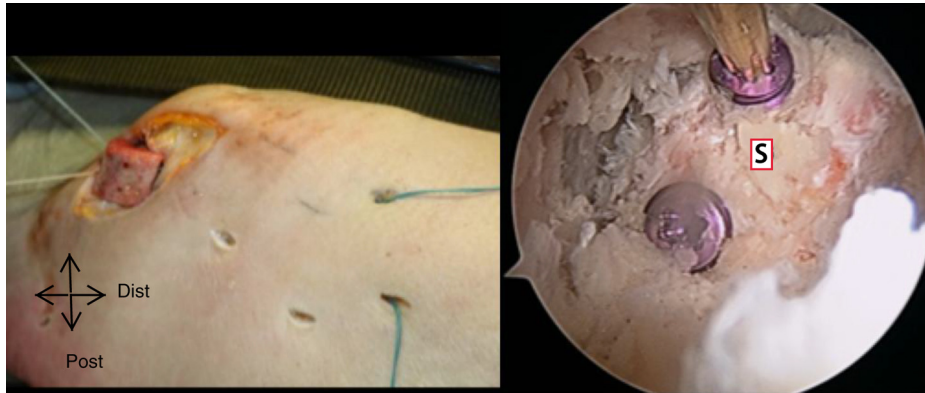


Fig. 6. Lowering of the shelf through the exo-pelvic approach along the guiding sutures (left) and arthroscopic view of the screws used for shelf fixation (right). SG: shelf graft.

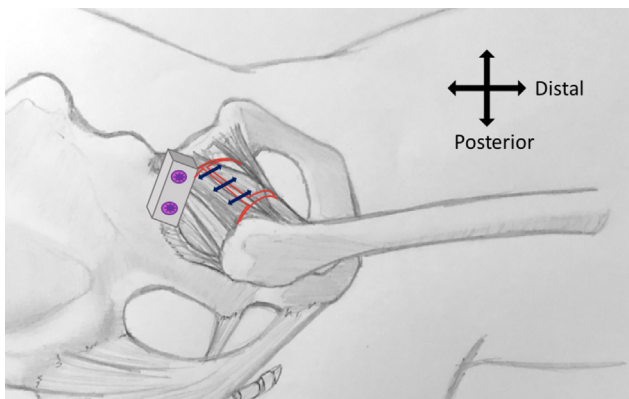


Fig. 7. Diagram of the technique used to tighten the capsule. The blue arrows represent the vertically oriented sutures.

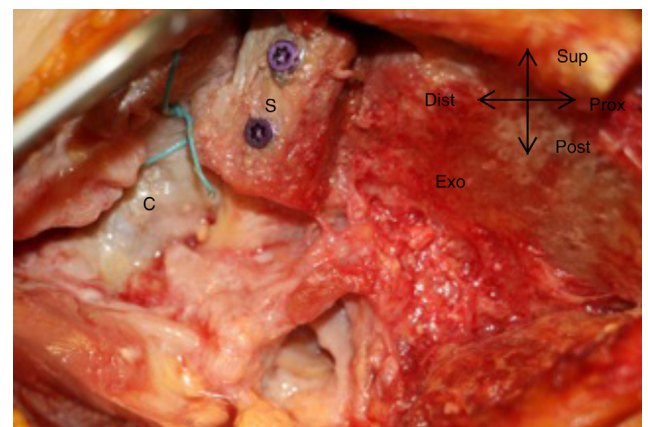


Fig. 8. Photograph of post-procedural hip dissection performed to check shelf position. S: shelf graft; C: capsule; Exo: exo-pelvic aspect of the iliac wing.

capsule. To circumvent this difficulty, we have modified the capsulotomy technique to spare the medial capsule. We now perform a T-shaped capsulotomy, which is then closed proximally on anchors while sparing the acetabular insertion of the medial flap to the extent possible. This technique is designed to minimise the risk of instability due to insufficient medial closure. Only 8 hips were studied and the procedure proved lengthy to perform. Finally, to limit the cost of the study, neither an image amplifier nor anchors were used. We do not recommend dispensing with these tools, as this adversely affects surgical accuracy and raises practical difficulties.

Shelf arthroplasty survival after at least 16 years of follow-up was 83.3% for hips without labral tears and 15.2% in those with labral lesions in an earlier study [13]. Thus, labral preservation seems crucial, and the condition of the labrum correlates with the functional outcome of shelf arthroplasty. We elected to repair the labrum using trans-osseous suturing because the cost of anchors

was difficult to justify for a cadaver study. Trans-osseous suturing is a valid fixation alternative to anchors [12,14,15] and was recently reported to be feasible using a fully endoscopic technique [16]. However, this last study has many differences with ours. Extra-articular capsulotomy obviates the need for an image amplifier, shortens the traction time, and diminishes the traction force required to perform the central step during this lengthy procedure. Nonetheless, fluoroscopic assessment of the bony corrections is indispensable. The exo-pelvic approach, in addition to offering limited anatomical invasiveness, facilitates shelf placement then allows arthroscopic verification of proper shelf position. Subperiosteal gluteal muscle detachment limits the amount of trauma, thereby decreasing the risk of heterotopic ossification [17]. The superior orientation of this approach, together with the high density of the muscles, decreases intra-articular fluid leakage. Fixation

using two compression screws may offer greater stability than simple impaction. Thus, our technique appears to occupy an intermediate position between the one described by Uchida et al. [16] and the minimally invasive technique reported by Chiron et al. [18]. In our clinical practice, we now perform shelf acetabuloplasty procedures via a minimally invasive Hueter approach under fluoroscopic guidance, with the ultimate goal of achieving a fully endoscopic technique.

4. Conclusion

Our shelf acetabuloplasty technique offers limited invasiveness while allowing the comprehensive management of hip instability related to moderate dysplasia. However, a long learning curve is required to decrease the duration of some of the more complex surgical steps.

Disclosure of interest

Rémy Coulomb and Eric Wolff declare that they have no competing interest.

Olivier Mares declares that he has no competing interest; he is a consultant for Newclip and Stryker.

Philippe Marchand and Pascal Kouyoumdjian declare that they have no competing interest; they are consultants for Stryker.

Funding

None.

The anatomy laboratory at the Nîmes school of medicine was made available at no charge. Stryker lent the equipment used for the study procedures.

Contributions of each author

Rémy Coulomb: substantial role in conceiving the research project and experimental protocol; collecting, analysing, and/or interpreting the study data; and writing and critically revising the manuscript.

Eric Wolff: substantial role in conceiving the research project and experimental protocol; collecting, analysing, and/or interpreting the study data; and writing and critically revising the manuscript.

Olivier Mares: wrote the first draft or contributed to its critical revision.

Philippe Marchand: wrote the first draft or contributed to its critical revision.

Pascal Kouyoumdjian: substantial role in conceiving the research project and experimental protocol; collecting, analysing, and/or interpreting the study data; and writing and critically revising the manuscript.

All authors read and approved the final version of the manuscript.

Appendix A. Supplementary data

Supplementary data associated with this article can be found, in the online version, at <https://doi.org/10.1016/j.otsr.2019.01.004>.

References

- [1] Mei-Dan O, McConkey MO, Brick M. Catastrophic failure of hip arthroscopy due to iatrogenic instability: can partial division of the ligamentum teres and iliofemoral ligament cause subluxation? *Arthroscopy* 2012;28:440–5.
- [2] Philippon MJ. The role of arthroscopic thermal capsulorrhaphy in the hip. *Clin Sports Med* 2001;20:817–30.
- [3] Nawabi DH, et al. Outcomes after arthroscopic treatment of femoroacetabular impingement for patients with borderline hip dysplasia. *Am J Sports Med* 2016;44:1017–23.
- [4] Domb BG, Stake CE, Lindner D, El-Bitar Y, Jackson TJ. Arthroscopic capsular plication and labral preservation in borderline hip dysplasia: two-year clinical outcomes of a surgical approach to a challenging problem. *Am J Sports Med* 2013;41:2591–8.
- [5] Kerboul M. General therapeutic indications in congenital hip dislocation in adults. *Acta Orthop Belg* 1990;56:407–13.
- [6] Migaud H, Chantelot C, Giraud F, Fontaine C, Duquenois A. Long-term survivorship of hip shelf arthroplasty and Chiari osteotomy in adults. *Clin Orthop* 2004;418:81–6.
- [7] Migaud H, Spiers A, Gougeon F, Pierchon F, Fontaine C, Duquenois A. Outcome of hip shelf arthroplasty in adults after a minimum of 15 years of follow-up. Long-term results and analysis of failures of 56 dysplastic hips. *Rev Chir Orthop Reparatrice Appar Mot* 1995;81:716–23.
- [8] Rosset P, Heudel B, Laulan J, Garaud P, Favard L. Long-term evolution following shelf procedure for hip dysplasia in adults. Shelf survival analysis in 68 cases and retrospective review of 44 with at least 26 years follow-up. *Acta Orthop Belg* 1999;65:315–26.
- [9] Hirose S, Otsuka H, Morishima T, Sato K. Long-term outcomes of shelf acetabuloplasty for developmental dysplasia of the hip in adults: a minimum 20-year follow-up study. *J Orthop Sci* 2011;16:698–703.
- [10] Clohisy JC, et al. Patient-reported outcomes of periacetabular osteotomy from the prospective ANCHOR cohort study. *J Bone Joint Surg Am* 2017;99:33–41.
- [11] Horisberger M, Brunner A, Herzog RF. Arthroscopic treatment of femoroacetabular impingement of the hip: a new technique to access the joint. *Clin Orthop* 2010;468:182–90.
- [12] Pérez-Carro L, et al. Transosseous acetabular labral repair as an alternative to anchors. *Arthrosc Tech* 2015;4:e407–10.
- [13] Berton C, Bocquet D, Krantz N, Cotten A, Migaud H, Girard J. Shelf arthroplasties long-term outcome: influence of labral tears. A prospective study at a minimal 16 years' follow up. *Orthop Traumatol Surg Res* 2010;96:753–9.
- [14] Wheeler DJ, et al. Biomechanical comparison of transosseous versus suture anchor repair of the subscapularis tendon. *Arthroscopy* 2010;26:444–50.
- [15] Lertwanich P, Ejinisman L, Philippon MJ. Comments on "labral base refixation in the hip: rationale and technique for an anatomic approach to labral repair". *Arthroscopy* 2011;27:303–4.
- [16] Uchida S, et al. Endoscopic shelf acetabuloplasty combined with labral repair, cam osteochondroplasty, and capsular plication for treating developmental hip dysplasia. *Arthrosc Tech* 2014;3:e185–91.
- [17] Firoozabadi R, O'Mara TJ, Swenson A, Agel J, Beck JD, Routt M. Risk factors for the development of heterotopic ossification after acetabular fracture fixation. *Clin Orthop Relat Res* 2014;472:3383–8.
- [18] Chiron P, Laffosse JM, Bonnevielle N. Shelf arthroplasty by minimal invasive surgery: technique and results of 76 cases. *Hip Int* 2007;17:S72–82.