



HAL
open science

Denervation of the wrist with two surgical incisions. Is it effective? A review of 33 patients with an average of 41 months' follow-up

Stéphanie Delclaux, Fanny Elia, Cindy Bouvet, Costel Aprédoaei, Michel Rongières, Pierre Mansat

► To cite this version:

Stéphanie Delclaux, Fanny Elia, Cindy Bouvet, Costel Aprédoaei, Michel Rongières, et al.. Denervation of the wrist with two surgical incisions. Is it effective? A review of 33 patients with an average of 41 months' follow-up. *Hand Surgery and Rehabilitation*, 2017, 36 (4), pp.281-285. 10.1016/j.hansur.2017.04.003 . hal-02135805

HAL Id: hal-02135805

<https://hal.science/hal-02135805v1>

Submitted on 21 May 2019

HAL is a multi-disciplinary open access archive for the deposit and dissemination of scientific research documents, whether they are published or not. The documents may come from teaching and research institutions in France or abroad, or from public or private research centers.

L'archive ouverte pluridisciplinaire **HAL**, est destinée au dépôt et à la diffusion de documents scientifiques de niveau recherche, publiés ou non, émanant des établissements d'enseignement et de recherche français ou étrangers, des laboratoires publics ou privés.




Open Archive Toulouse Archive Ouverte (OATAO)

OATAO is an open access repository that collects the work of some Toulouse researchers and makes it freely available over the web where possible.

This is an author's version published in: <https://oatao.univ-toulouse.fr/23108>

Official URL : <https://doi.org/10.1016/j.hansur.2017.04.003>

To cite this version :

Delclaux, Stéphanie and Elia, Fanny and Bouvet, Cindy and Aprédoaei, Costel and Rongières, Michel and Mansat, Pierre  *Denervation of the wrist with two surgical incisions. Is it effective? A review of 33 patients with an average of 41 months' follow-up.* (2017) *Hand Surgery and Rehabilitation*, 36 (4). 281-285. ISSN 2468-1229

Any correspondence concerning this service should be sent to the repository administrator:

tech-oatao@listes-diff.inp-toulouse.fr

Denervation of the wrist with two surgical incisions. Is it effective? A review of 33 patients with an average of 41 months' follow-up

*La dénervation du poignet par 2 voies d'abord est-elle efficace ?
À propos de 33 patients revus à 41 mois de recul moyen*

S. Delclaux, F. Elia, C. Bouvet, C. Aprédoaei, M. Rongièrès, P. Mansat *

Département d'orthopédie et traumatologie-urgences mains hôpital Pierre-Paul-Riquet, hôpital universitaire de Toulouse, place du Dr-Baylac, 31059 Toulouse cedex, France

A B S T R A C T

The goal of wrist denervation is to decrease pain at the wrist, whether caused by an intra or extra articular problem or even when the reason for the pain is unknown. It is an alternative to partial or total arthrodesis and proximal row carpectomy. Our hypothesis was that wrist denervation with a two incision technique was a reliable and efficient way to treat painful degenerative wrists. Thirty three patients, 48 years old on average, were included in this study. Indications were scapholunate advanced collapse (SLAC) in 18 cases, scaphoid nonunion advanced collapse (SNAC) in 10, distal radius fracture sequelae with advanced radiocarpal osteoarthritis in 4, and post traumatic ulnocarpal impingement in 1 case. At 41 months' follow up (12 161), there was a 75% reduction in pain levels, decreasing from 7.1 to 1.8 on a visual analog scale (VAS). There were no modifications related to wrist range of motion or grip strength. The QuickDASH averaged 23 points (5 to 70). Radiographic evaluation showed progression of intracarpal degeneration in 6 patients. All but 2 patients returned to their previous work. Persistent dysesthesia was observed in 7 patients; it resolved in 3 cases and persisted in 4. One patient developed complex regional pain syndrome (CRPS). A midcarpal arthrodesis with scaphoidectomy was performed in one patient because of disabling pain 5 months after surgery. Wrist denervation with a two incision technique for post traumatic osteoarthritis led to satisfactory results in 75% of cases with reduction in pain, preservation of range of motion and grip strength. However, this technique does not stop the progression of osteoarthritis. It can be discussed as a therapeutic alternative to proximal row carpectomy or intracarpal arthrodesis to treat degenerative painful wrists.

Type of study/level of evidence: Therapeutic IV.

Keywords:
Denervation
Degenerative wrist
SLAC
SNAC

R É S U M É

Le but d'une dénervation du poignet est de diminuer la symptomatologie douloureuse. Il s'agit d'une alternative à l'arthrodèse partielle ou totale, ou à la résection de la rangée proximale du carpe. Notre hypothèse était que la dénervation du poignet réalisée par 2 voies d'abord permet d'obtenir des résultats satisfaisants et reproductibles dans le traitement des poignets dégénératifs. Trente trois patients, d'âge moyen 48 ans, ont été inclus dans cette étude. Les indications étaient des séquelles de lésion du ligament scapho lunaire (SLAC wrist) dans 18 cas, de pseudarthrose du scaphoïde (SNAC wrist) dans 10 cas, de fracture articulaire de l'extrémité distale du radius dans 4 cas, et une arthrose par conflit ulnocarpien dans 1 cas. À 41 mois de recul moyen (12 161), l'amélioration de la douleur était de 75 %, l'intensité passant de 7,1 à 1,8 sur une échelle visuelle analogique (EVA). La mobilité du poignet et la force de la poigne n'étaient pas modifiées. Le score QuickDASH était de 23 points (5 à 70). L'évaluation

Mots clés :
Dénervation
Arthrose du poignet
SLAC
SNAC

* Corresponding author.

E-mail addresses: mansat.p@chu-toulouse.fr, pierre.mansat@univ-tlse3.fr (P. Mansat).

radiographique montrait une progression des lésions dégénératives intracarpienne dans 6 cas. Tous les patients, sauf 2, ont pu reprendre leur activité professionnelle. Des dysesthésies persistaient chez 7 patients ; 3 étaient transitoires et 4 ont persisté. Un patient a développé un syndrome douloureux régional complexe. Une arthrodèse médiocarpienne avec scaphoïdectomie a été nécessaire chez un patient pour persistance des douleurs 5 mois après la dénervation. Dans le cadre de poignet dégénératif, la dénervation du poignet réalisée par 2 voies d'abord permet d'obtenir des résultats satisfaisants dans 75 % des cas, avec diminution de l'intensité des douleurs et conservation des amplitudes articulaires et de la force de la poigne. Cependant elle ne stoppe pas l'évolution de l'arthrose. Cette technique peut être discutée par rapport aux autres options thérapeutiques classiques : résection de la rangée proximale du carpe, et arthrodèse partielle ou totale du carpe.

Type d'étude/Niveau d'évidence. Thérapeutique, IV.

1. Introduction

The goal of wrist denervation is to decrease pain at the wrist, whether caused by an intra or extra articular problem or even when the reason for the pain is unknown [1]. It is an alternative therapeutic option to intracarpal procedures such as partial or total arthrodesis [2] and proximal row carpectomy (PRC) [3]. The original surgical technique used eight approaches to resect all 10 articular nerve branches responsible for pain transmission [1]. An anatomic study performed by Dubert et al. [4] showed that wrist denervation could be performed through only three surgical approaches. Berger et al. [5] proposed a single posterior approach to resect the posterior interosseous nerve (PIN) and anterior interosseous nerve (AIN). However, this technique has a risk of pronator quadratus muscle denervation [6].

Wrist denervation through two approaches has been used in our department for many years. Our hypothesis was that this surgical technique was a reliable and efficient way to treat painful degenerative wrists.

2. Material and methods

2.1. Patients

A retrospective study was conducted in our Orthopedic and Traumatology Department at a University Hospital. Institutional review board approval was not required for this study. All patients were informed about the use of their personal data for this study. Included were all patients who underwent isolated wrist denervation through two approaches between 1995 and 2010, with at least 1 year of follow up. Excluded were all patients who underwent wrist denervation with associated procedures, or with a different surgical technique, or with less than 1 year of follow up.

Between January 1995 and May 2010, 33 patients who were 48 years old on average (range 23 to 68 years) fulfilled the inclusion criteria and were included in this study. The dominant side was involved in 17 patients. Fifteen patients were manual laborers.

Indications for wrist denervation were scapholunate advanced collapse (SLAC) in 18 cases and scaphoid nonunion advanced collapse (SNAC) in 10. In 4 cases, wrist denervation was performed for distal radius fracture sequelae with advanced radiocarpal osteoarthritis. Finally, wrist denervation was performed in one case for post traumatic ulnocarpal impingement.

3. Methods

Preoperative pain assessed with a visual analog scale (VAS) was 7.1 on average (4 to 10). Preoperative range of motion assessed

with a goniometer found wrist flexion of 51.6° (30° to 70°) and wrist extension of 50.8° (20° to 70°). Preoperative wrist strength measured with a Jamar[®] dynamometer was 33 kg (13 to 50 kg).

Preoperative posteroanterior and lateral views of the wrist with CT exam was available for all patients. Degenerative changes of the carpus were classified according to Watson and Ballet [7] and Alnot [8] (Table 1).

3.1. Surgical technique

Two different hand surgeons performed all procedures under regional anesthesia. A tourniquet at the arm was used in all cases.

A dorsal skin incision was performed between the 3rd and 4th extensor compartments. Subcutaneous dissection was performed to the radial styloid to resect all articular nerves branches of the superficial branch of the radial nerve and the lateral cutaneous nerve of the forearm. Then dissection was directed to the ulnar head to resect all articular nerves branches of the dorsal branch of the ulnar nerve and posterior cutaneous nerve of the forearm. Depth of soft tissue dissection was then limited at the extensor retinaculum level dorsally. The extensor retinaculum was then transected between the 3rd and 4th extensor compartment to locate the terminal branch of the PIN and to resect it on 3 cm. The extensor retinaculum was then repaired.

A volar arcuate incision was then performed parallel to the radial artery and parallel to the distal radius articular surface. Dissection around the radial artery was then performed to identify the pair of venæ comitantes, which were coagulated and resected 3 to 4 cm. The distal part of the pronator quadratus muscle was then identified. It was incised transversely distally and a periosteal elevator was used to remove the undersurface of the muscle from the bone, blindly transecting the terminal articular branches of the AIN. This volar approach did not include deflection of the palmar branch of median nerve.

Patients were immobilized in a splint for 2 weeks, and then were allowed to move their wrist. No therapy was prescribed.

3.2. Evaluation methods

All patient records were review retrospectively. The mean follow up was 41 months (range, 12 to 161 months). Clinical evaluation was based on the VAS pain rating. Pain at rest and during exercise was also specified. Wrist range of motion in flexion/extension was measured with a goniometer. Grip strength was measured with a Jamar[®] dynamometer. Functional evaluation of the upper limb was performed using the QuickDASH questionnaire [9]. At the last follow up, posteroanterior and lateral views of the wrist were taken to look for progression of intracarpal degenerative lesions.

4. Results

4.1. Complications and revisions

In the immediate postoperative period, dysesthesia was observed in 7 patients: 3 in the ulnar nerve territory and 4 in the radial nerve territory. Three cases were self limiting and 4 persisted (1 in the ulnar nerve territory and 3 in the radial nerve territory). One patient developed complex regional pain syndrome (CRPS).

One patient continued to have disabling pain 4 months after surgery. This patient had a stage 3 SLAC wrist. Midcarpal arthrodesis with scaphoidectomy was performed 5 months after the denervation procedure. Another patient with stage 2 SLAC had not improved at the 2 year follow up with VAS of 5. No revision was performed but midcarpal arthrodesis was discussed. Radiolunate osteoarthritis appeared in a third patient with post traumatic ulnocarpal impingement; radiolunate arthrodesis was performed in combination with distal ulna resection.

4.2. Clinical results

For the 33 patients reviewed, the mean VAS was 1.8 (0 to 8) with a mean VAS of 1.1 (0 to 4) at rest and 2.6 (0 to 10) during exercise. The pain level was reduced 75% compared to the preoperative level. Postoperative range of motion was 44° (20° to 70°) in flexion and 49° (30° to 70°) in extension. Grip strength was 35.4 kg (26 to 55 kg). The QuickDASH averaged 23 points (5 to 70). There was no significant difference in the clinical outcome related to the indications.

Eight patients had at least 5 years' follow up 8 years on average (5 to 14 years). All these patients were very satisfied with the surgery. Mean VAS was 1.6 at rest and 2.4 during effort. The QuickDASH averaged 19.8 points (7 to 45).

4.3. Functional results

Fifteen patients worked in heavy manual labor jobs at the time of the denervation procedure. For these patients, average pain was 2.5 on VAS during effort. All but two patients returned to their previous work.

4.4. Radiological results

Of the 33 patients reviewed, 6 had progression of the intracarpal degenerative lesions, without recurrence or increased pain (Fig. 1, Table 1). In the group of patients with 5 years' minimum follow up, no patients had increased signs of radiographic osteoarthritis.

5. Discussion

Degenerative lesions of the wrist are often post traumatic and affect young patients. Therapeutic options for advanced osteoarthritis are partial or total wrist fusion [2], PRC [3] or wrist denervation [1,4,5]. The advantage of wrist denervation is its effect on pain symptoms without impairment of wrist motion. Strength is often preserved or increased. The disadvantage is that the underlying osteoarthritis is not treated and tends to progress over time.

In similar published studies, the reduction of pain symptoms averaged 72% (range, 62 to 81%) (Table 2). Usually, results are gradual and reach a plateau at the end of the first year [14]. Range of motion is unchanged or slightly improved. Wrist strength tends to increase after denervation of the wrist, while remaining lower than the healthy contralateral side. However, follow up with radiographs revealed worsening of osteoarthritic lesions in most

Table 1
Change in the radiological classification of SLAC/SNAC wrists preoperatively and at the last follow-up.

Preoperative	Last follow-up	Worsening of degenerative lesions
SNAC (10 patients)		
1 stage 1	0 stage 1	2 patients
3 stage 2A	3 stage 2A	
4 stage 2B	5 stage 2B	
2 stage 4	2 stage 4	
SLAC (18 patients)		
4 stage 1	2 stage 1	4 patients
8 stage 2	8 stage 2	
6 stage 3	8 stage 3	

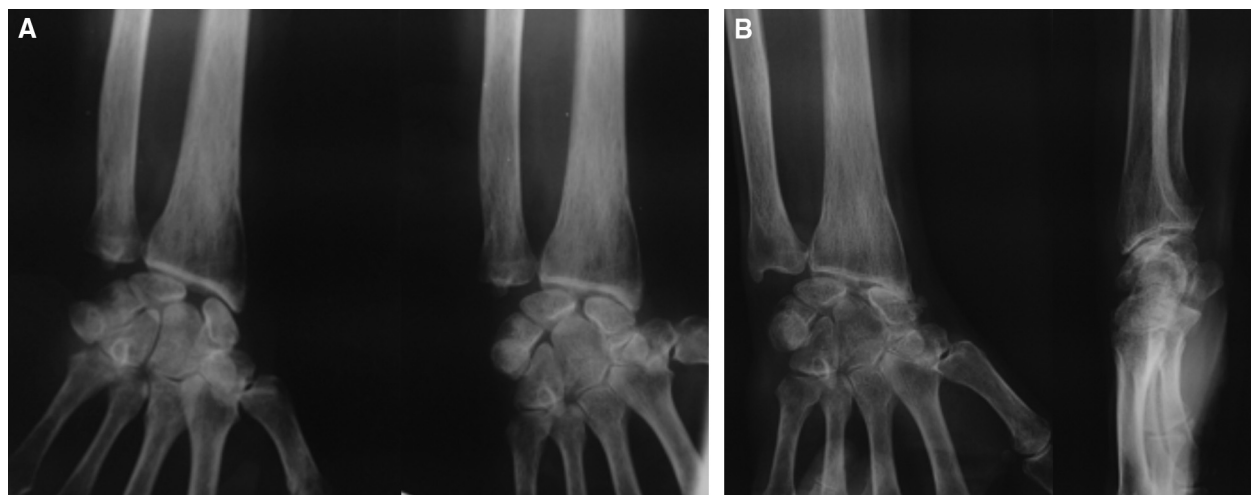


Fig. 1. Example of a patient with stage 1 SLAC preoperatively (A) and stage 2 at 3 years after wrist denervation (B).

Table 2
Review of the most recent literature on the results obtained after wrist denervation.

Authors	N	Number of incisions	Follow-up (month)	Results (% with pain reduction)
Hofmeister (2006) [10]	50	1	28	51%
Rothe et al. (2006) [11]	32	–	76	62.5%
Schweizer et al. (2006) [12]	71	5	113	67%
Radu et al. (2010) [13]	29	–	51	70%
Braga-Silva (2011) [14]	49	4	72	79 ± 4%
Storey (2011) [15]	37	1	18	60%
Hohendorff (2012) [16]	30	5	120	73%
Simon et al. (2012) [17]	27	3	77	81%
Riches et al. (2014) [18]	14	1	22	42%
Our study (2016)	33	2	41	75%

cases [14,17], with recurrence of pain in some cases [11,13]. Based on the literature, it seems that better results can be obtained for SLAC lesions, distal radius fracture sequelae [12,13] or Kienböck disease [19] in terms of grip strength, range of motion, and pain relief. However, like Simon et al. [17], we could not find any differences in outcomes by the indications in our study. Our study confirmed previous studies showing 75% reduction in pain. Worsening of degenerative intracarpal lesions was observed in 6 out of 33 patients in our study without clinical changes at follow up.

Total wrist denervation was initially described by Wilhelm et al. [1]. They described 10 nerve branches responsible for joint pain transmission. Five incisions were recommended to divide all these branches. The surgical procedure was technically difficult with unreliable results. Side effects were reported such as loss of skin sensibility and wrist proprioception [20]. However, in a cadaveric study, Dubert et al. [4] found that some branches described by Wilhelm appear inaccessible because they were closely located to other motor branches (deep branches of the ulnar nerve). Furthermore, some branches were not found in their dissections: branchlets from the palmar branch of the median nerve and direct branches of the ulnar nerve. They recommended using only three incisions to perform complete wrist denervation: dorsal, palmar and at the first web space to resect the articular nerves of the first interosseous space. Later Berger et al. [5] described the possibility of doing partial denervation of the wrist by resecting the AIN and PIN through a single posterior approach. At an average of 2.5 years postoperatively, they reported that 80% of patients had a decrease in pain, 45% normal or increased grip strength, and 73% of employed patients had returned to work [21]. However, Grafe et al. [22] and Lin et al. [6] described a serious risk of completely denervating the pronator quadratus muscle when using this surgical technique. Therefore, AIN resection should be performed close to the distal margin of the pronator quadratus muscle. More recently, Van de Pol et al. [23] found that the main innervation to the wrist capsule and periosteal nerve network came from the AIN, lateral antebrachial cutaneous nerve, and PIN. The palmar branch of the median nerve, the deep branch of the ulnar nerve, the superficial branch of the radial nerve, and the dorsal branch of the ulnar nerve also were found to have connections with the capsule. Based on these findings they proposed denervating the wrist by making only two incisions one palmar and one dorsal to disconnect the periosteum from the capsule and interrupt the majority of the capsular nerve branches. In our study, only two incisions were made and this led to reliable results like other studies with different surgical techniques.

Few complications have been reported after wrist denervation. Braga Silva et al. [14] reviewed 49 patients treated with Wilhelm's technique and found neuromas associated with the radial dorsal digital nerve of the index finger; most patients reported transient

hypoesthesia in the territory of the superficial branch of the radial nerve. Simon et al. [17], using a three incision procedure, reported 4 cases of transient hypoesthesia in the territory of the superficial branch of the radial nerve out of 29 patients. One required a revision procedure with resection of the neuroma. Seven cases of dysesthesia were observed in our study out of 33 patients: 3 were self limiting and 4 persisted.

Neurotrophic degeneration of the wrist joint has been theoretically described as a possible complication of wrist denervation. However, radiographic changes that could be attributed to neurotrophic degeneration have not been reported in any published studies, with all changes being attributed to progression of the osteoarthritis.

6. Conclusion

At an average of 41 months' follow up, wrist denervation with a two incision technique for post traumatic osteoarthritis led to satisfactory results in 75% of cases with reduction of pain levels, preservation of range of motion and wrist strength. The complication rate was low and mainly related to persistent dysesthesia. However, this technique does not stop the progression of radiological signs of osteoarthritis.

Funding

No funding was received related to this study.

Disclosure of interest

The authors declare that they have no competing interest.

References

- [1] Wilhem A. Denervation of the wrist. *Tech Hand Up Extrem Surg* 2001;5:14–30.
- [2] Delclaux S, Mansat P, Rongières M, Aprédoai C, Bonneville P. Résultats cliniques et radiologiques à 10 ans de moyenne de l'arthrodèse capito-lunaire. Série monocentrique de 12 patients. *Chir Main* 2013;32:310–6.
- [3] Delclaux S, Israel D, Aprédoai C, Rongières M, Mansat P. Proximal row carpectomy on manual workers: 17 patients followed for an average of 6 years. *Hand Surg Rehabil* 2016;35:401–6.
- [4] Dubert T, Oberlin C, Alnot JY. Articular nerves of the wrist. Implications on wrist denervation technique. *Ann Chir Main Memb Super* 1990;9:15–21.
- [5] Berger R. Partial denervation of the wrist: a new approach. *Tech Hand Up Ext Surg* 1998;2:25–35.
- [6] Lin DL, Lenhart MK, Farber GL. Anatomy of the anterior interosseous innervation of the pronator quadratus: evaluation of structures at risk in the single dorsal incision wrist denervation technique. *J Hand Surg Am* 2006;31:904–7.
- [7] Watson HK, Ballet FL. The SLAC wrist: scapholunate advanced collapse pattern of degenerative arthritis. *J Hand Surg Am* 1984;9:358–65.
- [8] Alnot JY. Les différents stades de pseudarthrose. In: « Symposium : fracture et pseudarthrose du scaphoïde carpien ». *Rev Chir Orthop Reparatrice Appar Mot* 1988;74:114–7.
- [9] Dubert T, Voche P, Dumontier C, Dinh A. The DASH questionnaire. French translation of a trans-cultural adaptation. *Chir Main* 2001;20:294–302.

- [10] Hofmeister EP, Moran SL, Shin AY. Anterior and posterior interosseous neurectomy for the treatment of chronic dynamic instability of the wrist. *Hand* 2006;1:63–70.
- [11] Rothe M, Rudolf KD, Partecke BD. Long term results following denervation of the wrist in patients with stages II and III SLAC/SNAC wrist. *Handchir Mikrochir Plast Chir* 2006;38:261–6.
- [12] Schweizer A, von Känel O, Kammer E, Meuli-Simmen C. Long term follow-up evaluation of denervation of the wrist. *J Hand Surg Am* 2006;31:559–64.
- [13] Radu CA, Schachner M, Tränkle M, Germann G, Sauerbier M. Functional results after wrist denervation. *Handchir Mikrochir Plast Chir* 2010;42:279–86.
- [14] Braga-Silva J, Román JA, Padoin AV. Wrist denervation for painful conditions of the wrist. *J Hand Surg Am* 2011;36:961–6.
- [15] Storey PA, Lindau T, Jansen V, Woodbridge S, Bainbridge LC, Burke FD. Wrist denervation in isolation: a prospective outcome study with patient selection by wrist blockade. *Hand Surg* 2011;16:251–7.
- [16] Hohendorff B, Mu?hldorfer-Fodor M, Kalb K, von Schoonhoven J, Prommersberger KJ. Long-term results following denervation of the wrist. *Unfallchirurg* 2012;115:343–52.
- [17] Simon E, Zemirline A, Richou J, Hu W, Le Nen D. La dénervation totale du poignet : une étude rétrospective de 27 cas au recul moyen de 77 mois. *Chir Main* 2012;31:306–10.
- [18] Riches PL, Elherik FK, Breusch SJ. Functional and patient-reported outcome of partial wrist denervation versus the Mannerfelt wrist arthrodesis in the rheumatoid wrist. *Arch Orthop Trauma Surg* 2014;134:1037–44.
- [19] Buck-Gramcko D. Wrist denervation procedures in the treatment of Kienbock's disease. *Hand Clin* 1993;9:517–20.
- [20] Ferreres A, Suso S, Foucher G, Ordi J, Llusà M, Ruano D. Wrist denervation. Surgical considerations. *J Hand Surg Br* 1995;20:769–72.
- [21] Weinstein LP, Berger RA. Analgesic benefit, functional outcome, and patient satisfaction after partial wrist denervation. *J Hand Surg Am* 2002;27:833–9.
- [22] Grafe MW, Kim PD, Rosenwasser MP, Strauch RJ. Wrist denervation and the anterior interosseous nerve: anatomic consideration. *J Hand Surg Am* 2005;30:1221–5.
- [23] Van de Pol GJ, Koudstaal MJ, Schuurman AH, Bleys RL. Innervation of the wrist joint and surgical perspectives of denervation. *J Hand Surg Am* 2006;31:28–34.