



Functional outcomes after non-operative treatment of irreparable massive rotator cuff tears: Prospective multicenter study in 68 patients

Charles Agout, Julien Berhouet, Clément Spiry, Nicolas Bonneville, Thierry Joudet, Luc Favard

► To cite this version:

Charles Agout, Julien Berhouet, Clément Spiry, Nicolas Bonneville, Thierry Joudet, et al.. Functional outcomes after non-operative treatment of irreparable massive rotator cuff tears: Prospective multicenter study in 68 patients. *Orthopaedics & Traumatology: Surgery & Research*, 2018, 104 (8), pp.S189-S192. 10.1016/j.otsr.2018.08.003 . hal-02135785

HAL Id: hal-02135785

<https://hal.science/hal-02135785>

Submitted on 21 May 2019

HAL is a multi-disciplinary open access archive for the deposit and dissemination of scientific research documents, whether they are published or not. The documents may come from teaching and research institutions in France or abroad, or from public or private research centers.

L'archive ouverte pluridisciplinaire **HAL**, est destinée au dépôt et à la diffusion de documents scientifiques de niveau recherche, publiés ou non, émanant des établissements d'enseignement et de recherche français ou étrangers, des laboratoires publics ou privés.



Open Archive Toulouse Archive Ouverte (OATAO)

OATAO is an open access repository that collects the work of some Toulouse researchers and makes it freely available over the web where possible.

This is an author's version published in: <https://oatao.univ-toulouse.fr/23093>

Official URL : <https://doi.org/10.1016/j.otsr.2018.08.003>

To cite this version :

Agout, Charles and Berhouet, Julien and Spiry, Clément and Bonneville, Nicolas[✉] and Joudet, Thierry and Favard, Luc *Functional outcomes after non-operative treatment of irreparable massive rotator cuff tears: Prospective multicenter study in 68 patients.* (2018) *Orthopaedics & Traumatology: Surgery & Research*, 104 (8). S189-S192. ISSN 1877-0568

Any correspondence concerning this service should be sent to the repository administrator:

tech-oatao@listes-diff.inp-toulouse.fr

Functional outcomes after non-operative treatment of irreparable massive rotator cuff tears: Prospective multicenter study in 68 patients

Charles Agout^{a,*}, Julien Berhouet^a, Clément Spiry^a, Nicolas Bonneville^b, Thierry Joudet^c, Luc Favard^a, the French Arthroscopic Society^d

^a Service de chirurgie orthopédique et traumatologique, hôpital Trousseau, CHRU de Tours, avenue de la République, 37170 Chambray-lès-Tours, France

^b Département d'orthopédie traumatologie, hôpital Riquet, CHU de Toulouse, 31059 Toulouse, France

^c Clinique chirurgicale du Libournais, 119, rue de la Marne, 33500 Libourne, France

^d 15, rue Ampère, 92500 Rueil-Malmaison, France

ABSTRACT

Background: Massive rotator cuff tears (RCTs) account for 10% to 40% of all RCTs and over 80% of re-tears. The objectives of this prospective study were to assess functional outcomes 6 and 12 months after starting non-operative therapy for an irreparable massive RCT and to identify predictors of good outcomes of non-operative treatment.

Hypothesis: Non-operative treatment deserves to be tried because it can produce improvements in patients with irreparable massive RCTs.

Material and methods: A prospective multicenter (12 centres) study was conducted between March 2015 and March 2016. Consecutive patients managed non-operatively for RCTs involving two or more tendons including one with a fatty infiltration score greater than 2 were included. Non-operative treatment consisted in rehabilitation and sub-acromial corticosteroid injections. Functional outcomes were assessed based on the Constant score and Subjective Shoulder Value (SSV) after 3, 6, and 12 months.

Results: Of 71 included patients, 3 underwent surgery during the study year, leaving 68 patients for the analysis of 12-month outcomes. Significant improvements were noted after 12 months in the Constant score (from 40.7 at baseline to 57.7 after 6 months and 57.1 after 12 months), in each of its items except force, and in the SSV. Constant score values after 6 and 12 months were not significantly different. No significant differences in functional outcomes were found across initial tear type.

Conclusion: Non-operative treatment produces significant functional gains in patients with irreparable massive RCTs. These gains are obtained after 6 months. Surgery can therefore be considered if the outcome is unsatisfactory after 6 months.

Level of evidence: III, prospective study.

Keywords:

Massive rotator cuff tear
Non-operative treatment
Clinical outcome

1. Introduction

Over the last few decades, arthroscopic repair techniques for rotator cuff tears (RCTs) have gained popularity based on reports of excellent functional and anatomic outcomes [1–6]. Arthroscopic repair of small RCTs is easily performed and produces good results. In contrast, in patients who have large tears with tendon retraction, fatty infiltration, and tendon delamination, the procedure is more challenging and the outcomes less predictable [7–12].

Massive RCTs account for 10% to 40% of all RCTs and 80% of re-tears [13–15]. Not all patients with massive RCTs are eligible for surgical repair. Reasons for non-eligibility include limited functional impairment, comorbidities contra-indicating surgery, and tears considered upon evaluation to be irreparable. In this situation, several studies indicate that non-operative treatments can produce satisfactory outcomes in terms of pain and mobility [16–19]. However, these studies are few in number.

The objectives of this prospective study were to assess functional outcomes 6 and 12 months after starting non-operative therapy for an irreparable massive RCT and to identify predictors of good outcomes of non-operative treatment. The working hypothesis was that non-operative treatment deserves to be tried because

* Corresponding author.

E-mail address: agout.c@hotmail.fr (C. Agout).

it can produce improvements in patients with irreparable massive RCTs.

2. Patients and methods

2.1. Study design

The protocol for this study carried out for the French Society of Arthroscopy (Société francophone d'arthroscopie, SFA) symposium was approved by the appropriate ethics committee (#04-415). A prospective multicenter design was used. The 12 study centres included consecutive patients managed non-operatively for irreparable massive RCTs between May 1, 2015 and May 1, 2016. Inclusion criteria were full-thickness RCT involving two or more tendons, and Goutallier fatty infiltration score [20] greater than 2 for at least one of the torn tendons. Patients were excluded if they had gleno-humeral osteoarthritis, shoulder stiffness, a history of surgery on the affected shoulder, or less than 12 months of follow-up.

Non-operative treatment methods included analgesics, anti-inflammatory drugs, rehabilitation, and sub-acromial corticosteroid injections. The choice of the methods used was at the discretion of the surgeon and was based on a subjective interpretation of the clinical and imaging-study findings.

2.2. Data collection

For each patient, the following pre-operative data were recorded: epidemiological data (age, gender, side, dominant side, sports activities, and history of trauma), clinical criteria (visual analogue scale [VAS] score for pain, motion ranges, Constant score [21], and Subjective Shoulder Value [SSV] [22]), standard radiography data (acromio-humeral interval and Hamada classification [23]), and slice imaging data (site of the tear categorised as antero-superior, postero-superior, or antero-posterior and, on MRI scans, Fuch fatty infiltration score [24]).

Each patient had follow-up visits scheduled 3, 6, and 12 months after the start of non-operative treatment. At each visit, the following were assessed: motion ranges, Constant score [21], SSV [22], and VAS pain score.

2.3. Statistical analyses

The data were described as mean \pm SD. Quantitative variables were compared by applying the non-parametric Kruskal-Wallis and Mann-Whitney tests and qualitative data by contingency tables and Fisher's exact test. Values of $p < 0.05$ were considered significant. The statistical analyses were performed using StatView 5.0 software (Abacus Concepts, Berkeley, CA, USA, 1992).

3. Results

Of 71 initially eligible patients scheduled for non-operative treatment, none were lost to follow-up. Surgery was performed in 3 patients within the first 3 months (partial RCT repair in 2 and long head of biceps tenotomy in 1). These 3 patients were classified as failures of non-operative treatment and were not included in the analyses of 6- and 12-month outcomes. The remaining 68 patients were included in the study and assessed after 12 months. Table 1 reports their main characteristics. There were 38 females and 30 males with a mean age at baseline of 70.9 ± 7.2 (range: 54–87) years. The dominant side was involved in 56 (82%) patients. Of the 68 patients, 47 (69.1%) were unemployed or retired and 21 (30.9%) were in work, including 5 (7.4%) in heavy manual labour. The RCT was an occupational condition

Table 1
Main features of the study patients.

Number of patients	68
Age, years, mean \pm SD (range)	70.9 ± 7.2 (54–87)
Males/females, <i>n</i>	38/30
RCT on dominant side, <i>n</i> (%)	56 (82%)
Smokers, <i>n</i> (%)	7 (10%)
History of trauma, <i>n</i> (%)	20 (29%)
Symptom duration, years, mean \pm SD (range)	2.9 ± 4.1 (0.1–16.1)
Work injury or occupational condition, <i>n</i> (%)	5 (7%)
Activity grade in the SFA classification, <i>n</i> (%)	
Grade I	9 (13%)
Grade II	11 (16%)
Grade III	17 (25%)
Grade IV	7 (10%)
Unknown	24 (35%)
Type of non-operative treatment, <i>n</i> (%)	
Rehabilitation	34 (50%)
Local steroid injection	21 (31%)
Both	17 (25%)

RCT: rotator cuff tear; SFA: French Society of Arthroscopy.

in 5 (7%) patients. Mean symptom duration was 2.9 ± 4.1 (range: 0.1–16.1) years. A trauma preceded the development or worsening of the symptoms in 20 (29%) patients. Tear sites were as follows: antero-superior (supra-spinatus and sub-scapularis), $n = 5$ (7.4%); postero-superior (infra-spinatus and supra-spinatus), $n = 35$ (51.5%); and antero-posterior (sub-scapularis, supra-spinatus, and infra-spinatus), $n = 24$ (35.3%); in the remaining 4 (5.9%) patients, the imaging studies failed to accurately locate the tear.

The non-operative treatment methods used were as follows: rehabilitation programme, $n = 34$ (50%); sub-acromial corticosteroid injections, $n = 21$ (31%), and both, $n = 17$ (25%).

In the 68 patients evaluated after 12 months, significant improvements versus baseline were seen for the mean Constant score (40.7 ± 17.0 [range: 9–75] to 57.1 ± 15.3 [range: 20–86]), mean weighted Constant score ($54.9\% \pm 22.7\%$ [range: 13–103] to $76.8\% \pm 0.2\%$ [range: 31–120]), and mean SSV ($39.0\% \pm 15.8$ [range: 0%–80%] to $65.2\% \pm 15.8$ [20%–99%]) (Table 2). Of the four Constant score items, pain, mobility, and activity were significantly improved, whereas force was not. Among motion ranges, active forwards elevation improved significantly, from $112.2^\circ \pm 45.1^\circ$ [range: 20° – 180°] to $137.4^\circ \pm 33.1^\circ$ [range: 60° – 180°].

Both the mean Constant score and active forward elevation were significantly improved versus baseline after 3 and 6 months. Neither improved significantly between 6 and 12 months (Figs. 1 and 2).

No significant correlations were found between functional outcomes or final motion ranges and tear type (antero-superior, postero-superior, or antero-posterior) (Table 3).

4. Discussion

This study confirms the short-term usefulness of non-operative treatment in patients with irreparable massive RCTs. Thus, the mean Constant score improved by 14 points from baseline to last follow-up after 1 year. The final functional outcomes and motion ranges were obtained within 6 months of starting non-operative treatment. The site of the initial tear was not significantly associated with the functional outcomes or motion ranges at last follow-up. These findings confirm our hypothesis that non-operative treatment deserves to be tried in patients with irreparable massive RCTs.

Table 2
Function before and after non-operative treatment.

	Before non-operative treatment	At last follow-up after non-operative treatment	p-value
Active forwards elevation	112.2 ± 45.1 (20–180)	137.4 ± 33.1 (60–180)	< 0.001
Active external rotation	27.8 ± 20.7 (–20 to 70)	29.9 ± 21.3 (–10 to 70)	0.581
Pain	5.1 ± 3.9 (0–15)	9.8 ± 4.2 (0–15)	< 0.0001
Activity	9.1 ± 3.7 (2–16)	13.8 ± 4.3 (5–20)	< 0.0001
Mobility	22.4 ± 11.3 (4–40)	28.3 ± 8.4 (8–40)	0.001
Force	3.7 ± 4.6 (0–17)	5.3 ± 5.1 (0–17)	0.069
Total Constant score	40.7 ± 17.0 (9–75)	57.1 ± 15.3 (20–86)	< 0.0001
Weighted Constant score	54.9 ± 22.7 (13–103)	76.8 ± 20.2 (31–120)	< 0.0001
SSV	39.0 ± 15.8 (0–80)	65.2 ± 15.8 (20–99)	< 0.0001

SSV: Subjective Shoulder Value.

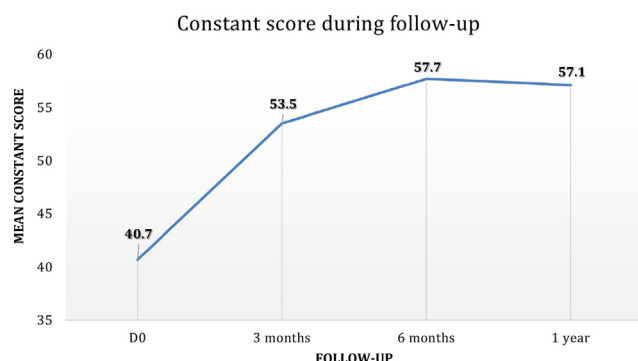


Fig. 1. Change in Constant score value during non-operative treatment.

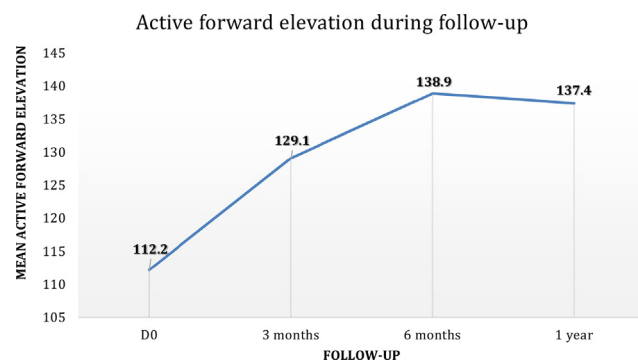


Fig. 2. Change in active forwards elevation during non-operative treatment.

A fatty infiltration score of 3 or more is a generally accepted contra-indication to tendon repair [25,26] in patients with massive RCTs. Therefore, at least initially, the surgeon may recommend non-operative treatment, which may include analgesics, anti-inflammatory drugs, local corticosteroid injections under ultrasound or fluoroscopy guidance, and rehabilitation therapy. No consensus exists about non-operative treatment modalities, notably the indications, methods, and duration. A meta-analysis of data on the non-operative treatment of RCTs identified 10 non-randomised studies and highlighted the lack of high-quality studies [27]. Of the 10 studies, only 4 focussed on massive RCTs and none produced definitive conclusions.

Collin et al. [16] recently reported a prospective study of 45 patients with irreparable massive RCTs manifesting clinically as pseudo-paralysis of the shoulder. The study used a specific rehabilitation programme designed to alleviate the pain, decrease scapulo-thoracic dyskinesia, correct faulty humeral head centring,

strengthen the scapular stabilisers, and restore proprioception and movement automatism. Among these 45 patients, those with postero-superior tears (supra-spinatus and infra-spinatus) achieved excellent functional outcomes, whereas those with complete antero-superior tears (sub-scapularis and supra-spinatus) obtained no improvements. Thus, non-operative treatment is most likely to succeed in patients with excellent sub-scapularis and teres minor function.

The limitations of our study include the absence of a control group and short follow-up. However, this is the only study providing data on function and motion range recovery over time during non-operative treatment of irreparable massive RCTs. This distinctive feature of our study adds new information about the indications of non-operative and surgical treatment. Non-operative treatment always deserves to be tried unless the patient has an antero-superior tear with pseudo-paralysis.

Table 3
Functional outcomes according to cuff tear site.

	Antero-superior (supra-spinatus and subscapularis) n = 5 (7.4%)	Postero-superior (infra-spinatus and supra-spinatus) n = 35 (51.5%)	Antero-posterior (subscapularis, supra-spinatus, and infra-spinatus)c n = 24 (35.3%)	p-value
Active forwards elevation	155.0 ± 25.2 (120–180)	145.0 ± 32.5 (60–180)	126.8 ± 32.8 (70–180)	0.0799
Active external rotation	42.5 ± 18.9 (30–70)	23.0 ± 21.9 (–10 to 60)	36.6 ± 18.8 (0–70)	0.1125
Pain	6.5 ± 3.0 (4.5–10)	10.9 ± 3.8 (1–15)	8.8 ± 4.6 (0–15)	0.0785
Activity	10.3 ± 2.5 (8–13)	14.1 ± 4.6 (6–20)	13.8 ± 4.2 (5–20)	0.2899
Mobility	36.7 ± 2.3 (34–38)	28.3 ± 8.6 (8–40)	27.5 ± 8.4 (10–40)	0.2135
Force	8.0 ± 7.8 (3–17)	4.7 ± 4.0 (0–12)	5.6 ± 6.2 (0–16)	0.5634
Total Constant score	61.5 ± 9.5 (56–73)	58.0 ± 16.0 (29–86)	55.8 ± 15.8 (20–79)	0.7512
Weighted Constant score	81.1 ± 6.3 (75–87)	76.9 ± 20.3 (37–120)	77.2 ± 22.3 (31–114)	0.9419
SSV	58.3 ± 16.1 (40–70)	61.9 ± 13.4 (30–90)	68.7 ± 17.7 (20–99)	0.1200

SSV: Subjective Shoulder Value.

5. Conclusion

Non-operative treatment provides significant functional improvements in patients with irreparable massive RCTs. The functional improvements are achieved within the first 6 months. Surgery can be considered in patients with no or insufficient improvements after 6 months.

Funding

None.

Contributions of each author

Charles Agout conceived and designed the study; collected, analysed, and interpreted the data; drafted, revised, and approved the manuscript.

Julien Berhouet and Clément Spiry collected, analysed, and interpreted the data.

Nicolas Bonneville, Thierry Joudet and Luc Favard conceived and designed the study; analysed and interpreted the data; revised and approved the manuscript.

Disclosure of interest

The authors declare that they have no competing interest.

References

- [1] Fealy S, Kingham TP, Altchek DW. Mini-open rotator cuff repair using a two-row fixation technique: outcomes analysis in patients with small, moderate, and large rotator cuff tears. *Arthroscopy* 2002;18:665–70.
- [2] Gartsman GM. Arthroscopic rotator cuff repair. *Clin Orthop Relat Res* 2001;390:95–106.
- [3] Lo IKY, Burkhart SS. Double-row arthroscopic rotator cuff repair: re-establishing the footprint of the rotator cuff. *Arthroscopy* 2003;19:1035–42.
- [4] Millstein ES, Snyder SJ. Arthroscopic evaluation and management of rotator cuff tears. *Orthop Clin North Am* 2003;34:507–20.
- [5] Severud EL, Ruotolo C, Abbott DD, Nottage WM. All-arthroscopic versus mini-open rotator cuff repair: a long-term retrospective outcome comparison. *Arthroscopy* 2003;19:234–8.
- [6] Waltrip RL, Zheng N, Dugas JR, Andrews JR. Rotator cuff repair. A biomechanical comparison of three techniques. *Am J Sports Med* 2003;31:493–7.
- [7] Agout C, Berhouet J, Bouju Y, Godenèche A, Collin P, Kempf J-F, et al. Clinical and anatomic results of rotator cuff repair at 10 years depend on tear type. *Knee Surg Sports Traumatol Arthrosc* 2018;26:2490–7.
- [8] Collin P, Matsumura N, Lädermann A, Denard PJ, Walch G. Relationship between massive chronic rotator cuff tear pattern and loss of active shoulder range of motion. *J Shoulder Elbow Surg* 2014;23:1195–202.
- [9] Galatz LM, Ball CM, Teefey SA, Middleton WD, Yamaguchi K. The outcome and repair integrity of completely arthroscopically repaired large and massive rotator cuff tears. *J Bone Joint Surg Am* 2004;86:219–24.
- [10] Kim JR, Cho YS, Ryu KJ, Kim JH. Clinical and radiographic outcomes after arthroscopic repair of massive rotator cuff tears using a suture bridge technique: assessment of repair integrity on magnetic resonance imaging. *Am J Sports Med* 2012;40:786–93.
- [11] Le BTN, Wu XL, Lam PH, Murrell GAC. Factors predicting rotator cuff retears: an analysis of 1000 consecutive rotator cuff repairs. *Am J Sports Med* 2014;42:1134–42.
- [12] Thès A, Hardy P, Bak K. Decision-making in massive rotator cuff tear. *Knee Surg Sports Traumatol Arthrosc* 2015;23:449–59.
- [13] Burkhart SS. Arthroscopic treatment of massive rotator cuff tears. Clinical results and biomechanical rationale. *Clin Orthop Relat Res* 1991;267:45–56.
- [14] Denard PJ, Jiwani AZ, Lädermann A, Burkhart SS. Long-term outcome of arthroscopic massive rotator cuff repair: the importance of double-row fixation. *Arthroscopy* 2012;28:909–15.
- [15] Lo IKY, Burkhart SS. Arthroscopic revision of failed rotator cuff repairs: technique and results. *Arthroscopy* 2004;20:250–67.
- [16] Collin PG, Gain S, Nguyen Huu F, Lädermann A. Is rehabilitation effective in massive rotator cuff tears? *Orthop Traumatol Surg Res* 2015;101:S203–5.
- [17] Zingg PO, Jost B, Sukthankar A, Buhler M, Pfirrmann CWA, Gerber C. Clinical and structural outcomes of nonoperative management of massive rotator cuff tears. *J Bone Joint Surg Am* 2007;89:1928–34.
- [18] Bokor DJ, Hawkins RJ, Huckell GH, Angelo RL, Schickendantz MS. Results of non-operative management of full-thickness tears of the rotator cuff. *Clin Orthop Relat Res* 1993;294:103–10.
- [19] Itoi E, Tabata S. Conservative treatment of rotator cuff tears. *Clin Orthop Relat Res* 1992;275:165–73.
- [20] Goutallier D, Postel JM, Bernageau J, Lavau L, Voisin MC. Fatty muscle degeneration in cuff ruptures. Pre- and postoperative evaluation by CT scan. *Clin Orthop Relat Res* 1994;304:78–83.
- [21] Constant CR, Murley AH. A clinical method of functional assessment of the shoulder. *Clin Orthop Relat Res* 1987;214:160–4.
- [22] Gilbert MK, Gerber C. Comparison of the subjective shoulder value and the Constant score. *J Shoulder Elbow Surg* 2007;16:717–21.
- [23] Hamada K, Yamanaka K, Uchiyama Y, Mikasa T, Mikasa M. A radiographic classification of massive rotator cuff tear arthritis. *Clin Orthop Relat Res* 2011;469:2452–60.
- [24] Fuchs B, Weishaupt D, Zanetti M, Hodler J, Gerber C. Fatty degeneration of the muscles of the rotator cuff: assessment by computed tomography versus magnetic resonance imaging. *J Shoulder Elbow Surg* 1999;8:599–605.
- [25] Gerber C, Fuchs B, Hodler J. The results of repair of massive tears of the rotator cuff. *J Bone Joint Surg Am* 2000;82:505–15.
- [26] Goutallier D, Postel J, Lavau L, Bernageau J. Influence de la dégénérescence musculaire du supra- et de l'infraspinatus sur le pronostic des réparations chirurgicales de la coiffe des rotateurs. *Acta Orthop Belg* 1998;64:41–5.
- [27] Ainsworth R, Lewis JS. Exercise therapy for the conservative management of full-thickness tears of the rotator cuff: a systematic review. *Br J Sports Med* 2007;41:200–10.