



HAL
open science

Gartland types IIB and III supracondylar fractures of the humerus in children: is Blount's method effective and safe?

Thuy-Trang Pham, Franck Accadbled, Abdelaziz Abid, Aissa Ibnoulkhatib, Xavier Bayle-Iniguez, Matthieu Wargny, Jérôme Sales de Gauzy

► To cite this version:

Thuy-Trang Pham, Franck Accadbled, Abdelaziz Abid, Aissa Ibnoulkhatib, Xavier Bayle-Iniguez, et al.. Gartland types IIB and III supracondylar fractures of the humerus in children: is Blount's method effective and safe?. *Journal of Shoulder and Elbow Surgery*, 2017, 26 (12), pp.2226-2231. 10.1016/j.jse.2017.05.018 . hal-02135777

HAL Id: hal-02135777

<https://hal.science/hal-02135777>

Submitted on 21 May 2019

HAL is a multi-disciplinary open access archive for the deposit and dissemination of scientific research documents, whether they are published or not. The documents may come from teaching and research institutions in France or abroad, or from public or private research centers.

L'archive ouverte pluridisciplinaire **HAL**, est destinée au dépôt et à la diffusion de documents scientifiques de niveau recherche, publiés ou non, émanant des établissements d'enseignement et de recherche français ou étrangers, des laboratoires publics ou privés.





Open Archive Toulouse Archive Ouverte (OATAO)

OATAO is an open access repository that collects the work of some Toulouse researchers and makes it freely available over the web where possible.

This is an author's version published in: <https://oatao.univ-toulouse.fr/23119>

Official URL : <https://doi.org/10.1016/j.jse.2017.05.018>

To cite this version :

Pham, Thuy-Trang and Accadbled, Franck  and Abid, Abdelaziz and Ibnoukhatib, Aissa and Bayle-Iniguez, Xavier and Wargny, Matthieu and Sales de Gauzy, Jérôme  *Garland types IIB and III supracondylar fractures of the humerus in children: is Blount's method effective and safe?* (2017) *Journal of Shoulder and Elbow Surgery*, 26 (12). 2226-2231. ISSN 1058-2746

Any correspondence concerning this service should be sent to the repository administrator:

tech-oatao@listes-diff.inp-toulouse.fr

Gartland types IIB and III supracondylar fractures of the humerus in children: is Blount's method effective and safe?

Thuy-Trang Pham, MD^{a,*}, Franck Accadbled, MD, PhD^a, Abdelaziz Abid, MD^a, Aissa Ibnoulkhatib, MD^a, Xavier Bayle-Iniguez, MD^b, Matthieu Wargny, MD^c, Jérôme Sales de Gauzy, MD^a

^aService de chirurgie orthopédique et traumatologique pédiatrique, Hôpital des Enfants, CHU Toulouse, Toulouse, France

^bService de chirurgie orthopédique et traumatologique, Hôpital Pierre Paul Riquet, CHU Toulouse, Toulouse, France

^cService d'Epidémiologie, CHU Toulouse, Toulouse, France

Background: Blount's method is controversial for the treatment of Gartland types IIB and III supracondylar fracture of the humerus (SCFH) in children. The purpose of this study was to evaluate the clinical and radiologic outcomes and the failure and complication rates.

Methods: All types IIB and III SCFH treated with Blount's method from 2003-2013 were included in this retrospective single-center study. Clinical assessment was performed according to Flynn criteria. Baumann angle, anteversion angle, anterior humeral line, and humeroulnar angle were measured for radiographic assessment.

Results: Among 447 children with types IIB and III SCFH, 339 were treated according to Blount's method. There were 173 boys (51%), and the mean age was 6.3 years (1-14 years); 71% were type III. Mean time to surgery was 5.7 hours. According to Flynn criteria, results were satisfactory in 91% of cases. No compartment syndrome was encountered. There were 16 (4.7%) secondary displacements requiring surgical revision. Five (1.9%) children developed a cubitus varus deformity. At latest follow-up, the mean Baumann angle was 74.7° (95% confidence interval, 74.1-75.3), the mean anteversion angle was 39.9° (95% confidence interval, 39.5-40.3), the anterior humeral line was normal in 87.6% of cases, and the mean humeroulnar angle was 8.7°.

Conclusion: Blount's method is appropriate to manage types IIB and III SCFH, provided anatomic and stable reduction is obtained.

Level of evidence: Level IV; Case Series; Treatment Study

Keywords: Blount's method; supracondylar fracture; Gartland IIB and III; closed reduction; children; elbow

Ethical approval was waived by the Institutional Review Board.

*Reprint requests: Thuy-Trang Pham, MD, Service de chirurgie orthopédique et traumatologique pédiatrique, Hôpital des Enfants, CHU Toulouse, 31059 Toulouse Cedex 9, France.

E-mail address: francethuytrang@yahoo.fr (T.-T. Pham).

Supracondylar fracture of the humerus (SCFH) is the most frequent fracture of the elbow in children. Extension type represents 96% of SCFH.⁸ Closed reduction and immobilization of the elbow in flexion were popularized by W.P. Blount in 1954 in his classic textbook, *Fractures in Children*.⁵ The

fracture is stable in flexion only if the posterolateral periosteum is intact.

The management of displaced SCFH type IIB and type III according to the Wilkins-modified Gartland classification is difficult because of the frequent swelling that may cause vascular compression or even compartment syndrome and instability when the posterolateral periosteum is torn.^{13,17,25} Blount's method was condemned in France in the 1960s after the report from Lagrange and Rigault because of the high risk of compartment syndrome in case of malreduction.¹⁷ The method was later reintroduced thanks to the shorter delays in treatment, allowing less swollen elbows.

Most authors recommend pin fixation to prevent compartment syndrome and to improve stability.^{6,11,18,19,22,27} However, complications can occur with surgical treatment, including pin track infections, joint stiffness, neurologic injuries, and secondary displacement.^{6,24} Our hypothesis was that Blount's method is adequate for types IIB and III SCFH, provided stable and satisfactory reduction is obtained. The aim was to evaluate the clinical and radiologic outcomes, failure rate, and complications.

Materials and methods

This was a single-center retrospective consecutive series. All extension-type IIB and III SCFH treated with Blount's method from 2003-2013 were included. Among 447 children with Gartland type IIB or III SCFH, 98 (22%) were treated surgically and 349 (78%) were treated with Blount's method.

We retrospectively reviewed the hospital records of the study cohort, including personal data, preoperative clinical examinations and associated lesions, time from injury to surgery, operative notes, postoperative evaluations, duration of immobilization, presence of complications, need for further surgery, and clinical assessment at final follow-up visit. Patients returned for clinical examination and radiographs in 57% of cases.

Clinical evaluation and overall rating at latest follow-up were performed according to Flynn criteria¹² (Table I). Anteroposterior and lateral radiographs of the elbow were analyzed using Baumann angle and distal humerus anteversion angle postoperatively, at 1 week, at the time of bone consolidation, and at latest follow-up. Humero-ulnar angle was measured at latest follow-up.

Statistical analysis was performed using Statistique R version 2.14.1 software (The R Foundation for Statistical Computing, Vienna, Austria). The χ^2 statistic was used for qualitative variables and Student

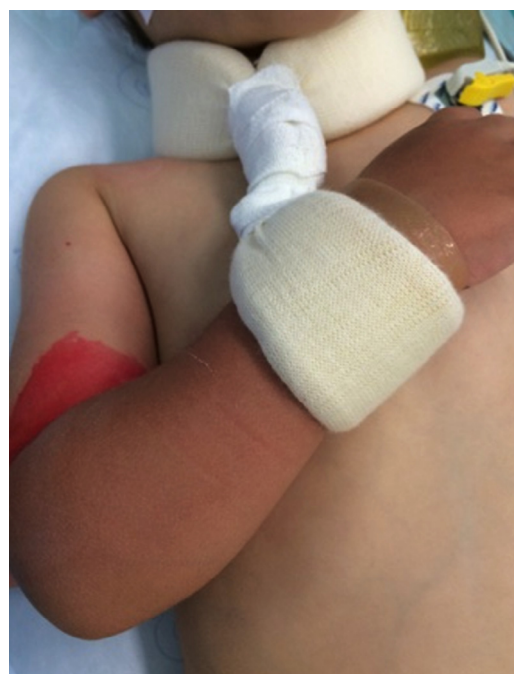

Figure 1 Collar and cuff bandage.

t-test for quantitative variables. Results are displayed with raw values and percentages for qualitative variables and with means, medians, standard deviations, and interquartile ranges for quantitative variables. *P* was considered significant if $< .05$.

Description of Blount's method

Under general anesthesia, the patient was positioned supine with the affected limb placed on the image intensifier. Closed manipulation consisted of traction, pronation or supination, and then elbow flexion, respectively. Elbow flexion was maintained at about 120° by a collar and cuff bandage (Fig. 1) for 4 weeks. In case of an unstable reduction in elbow flexion, pin fixation was performed. If closed reduction was unsuccessful, open reduction and pin fixation were performed. Radial pulse and capillary refill time in the fingertips were checked, and pulse oximetry at the middle finger was monitored systematically immediately after reduction in elbow flexion. Immediate postoperative anteroposterior and lateral radiographs of the elbow were performed systematically (Fig. 2). Parents were given basic care and observation guidelines. Clinical and radiologic control was scheduled in the outpatient clinic within 10 days from hospital discharge. No physiotherapy was prescribed. Sport activities were allowed after 3 months.

Results

The records of 447 children with Gartland type IIB or III SCFH were analyzed, of whom 98 (22%) were treated surgically with pin fixation because of the following reasons: open fracture in 12 cases (12%), failed closed reduction in 28 cases (28.5%), instability of the fracture in elbow flexion in 20 cases (20.5%), and distal ischemia in elbow flexion because of edema in 38 cases (39%).

Table I Flynn criteria for grading of outcome

Result	Rating	Cosmetic factor Loss of carrying angle (°)	Functional factor Loss of motion (°)
Satisfactory	Excellent	0-5	0-5
	Good	6-10	6-10
	Fair	11-15	11-15
Unsatisfactory	Poor	>15	>15

The lower of the ratings is the overall rating, and an elbow that has a varus deformity is automatically graded poor.

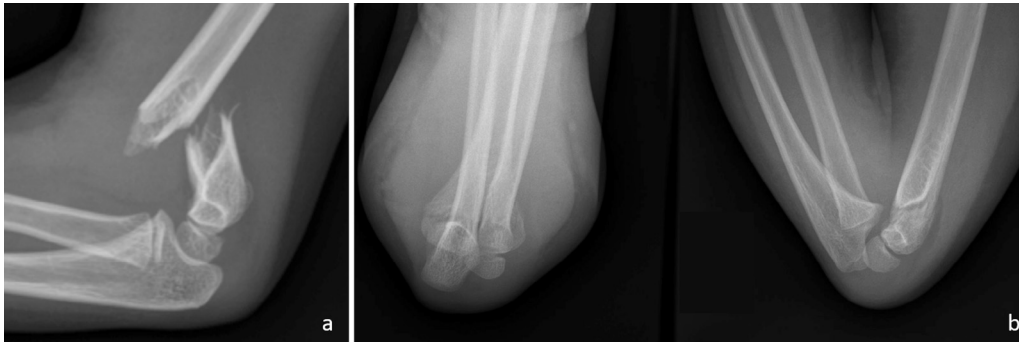

Figure 2 (A) Preoperative elbow radiograph, lateral view: Gartland type III supracondylar fracture of the humerus. (B) Elbow radiographs, anteroposterior and lateral views, immediately after reduction and immobilization in elbow flexion.

Preoperative associated lesions	No.
Ipsilateral fractures (3.5%)	12
Buckle fracture distal radius	5
Salter-Harris type II physeal injury distal radius	4
Forearm fracture	3
Cutaneous (18.9%)	64
Severe swelling and bruising	53
Gustilo type I open fracture	7
Subcutaneous bone extremity	4
Neurologic (13.3%)	45
Median nerve	13
Anterior interosseous nerve	19
Radial nerve	12
Radial and ulnar nerves	1
Vascular (1.8%)	6
Pulselessness resolved after fracture reduction	6

A total of 349 patients were treated with Blount's method: 243 type III (71.7%) and 96 type IIB fractures (28.3%). There were 173 boys (51%) and 166 girls (49%) with a mean age of 6.3 years (1-14 years). The left side was affected in 197 cases (58.1%) and the right in 142 (41.9%; dominant side in 44.4% of cases). The fracture was sustained on the occasion of a sports injury in 207 cases (61%), a fall from standing height in 74 cases (22%), a household accident in 40 cases (11.7%), a motor vehicle accident in 5 cases (1.5%), and an undocumented cause in 13 cases (3.8%). Average time to management was 5.7 hours (23 minutes–20 hours). Associated lesions were recorded in 127 cases (Table II).

Mean operative time (reduction + collar and cuff bandage) was 11.6 minutes (95% confidence interval [CI], 11.11-12.07). Mean hospital stay was 1.6 days (95% CI, 1.49-1.64). Mean immobilization time in a collar and cuff bandage was 26.2 days (95% CI, 25.42-27.02). According to 1 surgeon's preference, 96 patients (28%) had an additional immobilization in a 90° elbow flexion cast for 16.6 days on average (95% CI, 15.55-17.7).

Ten patients were lost to follow-up. Sixteen patients had a secondary displacement managed with repeated reduction and pin fixation 7 days postoperatively, leaving 323 patients

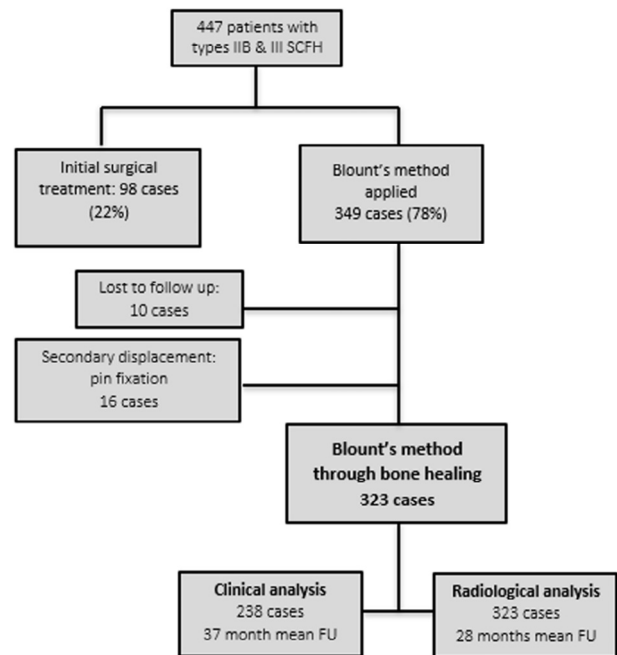


Figure 3 Flow chart of the cohort. SCFH, supracondylar fracture of the humerus; FU, follow-up.

for radiologic analysis at 45 days of follow-up. There were 238 patients who were clinically examined at a mean 36.8 months of follow-up (2.1-134.9 months) (Fig. 3).

Clinical outcome

Results were satisfactory in 97% of cases (excellent or good in 95% of cases) according to Flynn criteria (Table III). Including the 16 patients who underwent surgical revision and who were considered to have poor outcome, results were satisfactory in 91% of cases (n = 231/254).

Mean range of motion of the elbow in flexion-extension was 140.3° (100°-160°), with mean flexion of 138.2° (95% CI, 137.5-138.8) and mean extension of +2.1° (95% CI, 1.3-2.9). Mean loss of extension compared with the contralateral side was 9.8° (5°-30°). Range of motion in pronation-supination was

Table III Clinical outcome according to Flynn criteria

	Flynn criteria		Loss of carrying angle		Loss of motion	
	n = 238	%	n = 238	%	n = 238	%
Excellent	205	86.2	214	89.9	225	94.5
Good	21	8.8	16	6.7	9	3.9
Fair	5	2.1	2	0.9	3	1.2
Poor	7	2.9	6	2.5	1	0.4

symmetric. Mean humeroulnar angle was $+7.3^\circ$ (95% CI, 6.73-7.81).

Five patients (1.9%) had cubitus varus with a clinical carrying angle of -10° (-5° to -15°), loss of the humeroulnar angle of 17° (10° - 20°) compared with the contralateral side, and Baumann angle of 93.6° (80° - 104°). None reported a functional or cosmetic complaint. All patients with initial nerve palsy had fully recovered at latest follow-up. Parents were very satisfied in 98.8% of cases.

Seven patients had fair results, 6 functionally (restricted range of motion) and 1 cosmetically (loss of carrying angle). Mean range of motion in the 6 functionally impaired patients was 124° (100° - 140°). Mean loss of extension compared with the contralateral side was 17.5° (10° - 25°). One patient had a painful elbow affecting daily activities. This 14-year-old boy had a type III fracture complicated by periarticular ossifications causing severe stiffness (range of motion of 25°). Despite surgical release 3 months postoperatively, his elbow remained relatively stiff (range of motion of 100°) and painful at latest follow-up. The patient with a fair cosmetic result had a loss of carrying angle of 20° without functional consequences.

Radiologic results

Baumann angle was 75.7° (95% CI, 75.3-76.2) postoperatively and 74.7° (95% CI, 74.1-75.3) at latest follow-up ($P = .00025$). Mean distal humerus anteversion angle was 39.7° (95% CI, 39.3-40.1) postoperatively and 39.9° (95% CI, 39.5-40.3) at latest follow up ($P = .30$).

At latest follow-up, 20 patients (6.4%) had an abnormal Baumann angle, of which 17 were above 81° (mean, 84.9° ; 95% CI, 80.25-89.53) and 3 were below 64° (mean, 60°). Anteversion angle was above 40° (mean, 45.1° ; 95% CI, 44.3-45.8) in 63 patients (19%). Mean humeroulnar angle was 8.7° at latest follow-up (95% CI, 7.84-9.62).

Secondary displacement

There were 36 cases of secondary displacement (10.6%) at the first-week visit. Sixteen (4.7%) were managed with surgical revision. A continued conservative treatment of the remaining 20 patients with secondary displacement was chosen by the surgeon, who considered that it was not clinically

significant. This matter was always explained to the patient and family, who accepted this decision.

Of the 20 patients managed with conservative treatment, 3 (15%) had a fair outcome and 1 had a poor outcome (5%) according to Flynn criteria. Three patients had cubitus varus with a Baumann angle above 90° , of whom 2 had an excessive anteversion. One patient had a fair outcome with 15° loss of motion.

Complications

Five patients (1.5%) presented with a skin sore at the wrist and 3 (0.9%) at the elbow, necessitating local care with dressings. One patient (0.3%) had his bandage loosen after a fall. There was 1 case of ulnar nerve palsy due to excessive tightness of the bandage, which recovered spontaneously when the bandage was removed. Two patients suffered from a type I complex regional pain syndrome. No compartment syndrome was noted.

Discussion

Remodeling of SCFH is mild as the chondroepiphysis of the distal humerus provides only 20% of the longitudinal bone growth. The aim of treatment is therefore to maintain anatomic reduction to allow normal function and range of motion, along with satisfactory cosmesis. The recommended method for treatment must be as simple as possible and reliable while bearing a low risk of complication. Most publications advocate pin fixation for SCFH types IIB and III, with various preferred constructs.^{6,11,18,19,22,27}

Blount's method, initially described in 1954, relies on the continuity of the posterior periosteum, which provides the necessary stability to maintain the reduction in elbow flexion.^{5,7} Application to types IIB and III remains controversial because of the risk of compartment syndrome and fracture instability. The author did not recommend the method in case of neurovascular compromise or marked swelling.⁵ We extended the use of the method to types IIB and III SCFH, except for unstable or unreducible fractures and in case of vascular compromise persisting after fracture reduction. Neurologic deficit did not influence our decision. Severe swelling was a relative contraindication, at the discretion of the surgeon in charge.

The posterior periosteum is torn in about 50% of type III SCFH.¹⁷ Yet, Blount's method is based on an intact posterior periosteum. In other words, about half of type III cases are eligible for this method of immobilization. The current series demonstrated that 66% of such fractures were successfully managed using Blount's method, whereas Akakpo-Numado et al reported 70% and Williamson and Cole reported 60%.^{2,26}

Clinical results were satisfactory in 91% of cases according to Flynn criteria, which is consistent with the literature. De Gheldere and Bellan,⁹ in a series of 74 children,

reported 94% excellent and good results according to Flynn criteria for type II and 73% for type III. Results of type III were influenced by the direction of displacement: fractures remained stable in 88% of posterior displacements, 58% of posteromedial displacements, and only 36% of posterolateral displacements.⁹ Kinkpé et al observed 100% stable fractures and 100% good results in 67 type III fractures. Time to treatment (mean time to referral, 30 hours; mean time to treatment, 46 hours) did not influence anatomic and clinical results.¹⁵

We did not proceed with a comparative study as our indications for Blount's method and pin fixation were different. However, Sigge et al have reported better results with Blount's method than with pin fixations.²¹ Kennedy et al obtained similar results in both groups and concluded that immobilization in elbow flexion was effective when stable reduction was obtained in Gartland types II and III SCFH. No correlation existed between the type of treatment and poor results. However, surgical treatment was associated with the risk of superficial infection.¹⁴

Compartment syndrome incidence varies from 0.1% to 0.3%.³ The combination of the SCFH with ipsilateral forearm fracture represents a major risk factor. Blakemore et al reported 3 cases (7%) among 33 such combined lesions.⁴ Ipsilateral forearm fracture and marked swelling did not contraindicate Blount's method in our series. None of our patients sustained a compartment syndrome, yet this complication is the main argument against Blount's method in the literature.

Secondary displacement occurred in 36 cases (10.6%), of which 16 (4.5%) were managed with repeated reduction and pin fixation. Nonetheless, 16 of the remaining 20 patients had excellent results according to Flynn criteria, 3 had cubitus varus and remained asymptomatic at latest follow-up, and 1 patient had a 15° loss of elbow motion. Clavert et al recorded 7 secondary displacements in a 120-case series (5.8%), of which 6 involved type IV fractures and 1 involved a type III according to the Lagrange and Rigault classification.¹⁷ Kinkpé et al applied Blount's method to 67 Gartland III SCFH and described only 2 (3%) secondary displacements.¹⁵ Akakpo-Numado et al had a 25% rate of secondary displacement, also with Blount's method.²

Our surgical revision rate was similar to those of pin fixation series from the literature.^{6,11,18,19,22,27} Moreover, Blount's method has several advantages over pin fixation: it is simple and cheap, with a low risk of infection and low risk of nerve injury, and it avoids another procedure for pin removal. The absence of circular immobilization facilitates postoperative care and observation.

Cubitus varus was observed in 5 (1.9%) of our patients vs. 3% to 58% of cases in the literature.^{10,16} In 4 cases, this deformity resulted from a wrong indication or wrong management: 3 presented with a secondary displacement managed conservatively, and 1 had an insufficient initial reduction (40% rotation). Blount's method should not be used in case of an insufficient fracture reduction because of the low bone remodeling potential at the distal humerus. Close observation

is necessary, and surgical revision should be decided in a timely manner in case of secondary displacement. Cubitus varus results from a medial angulation at the fracture site, with or without rotation deformity, rather than from a growth disturbance at the distal humerus.^{11,23} It has been thought in the past that only cosmesis and a lesser degree of function were at stake in cubitus varus. Williamson and Cole obtained 95% excellent results with Blount's method despite 22.7% cubitus varus.²⁶ However, long-term complications, such as ulnar nerve palsy and posterolateral instability of the elbow, are now clearly admitted.^{1,20}

Six patients (2.5%) had a poor clinical result according to Flynn criteria, with a mean elbow range of motion of 124° (100°-140°) and a mean loss of extension of 17.8° (10°-25°). One presented with periarticular ossifications and was affected in his daily activities. This patient was aged 14 years at the time of the fracture, and initial pin fixation should have been selected.

We acknowledge some limitations to this study, related to its retrospective and noncomparative nature. Data analyses relied on patients' records in only 57% of cases.

Conclusion

We were able to use Blount's method to successfully treat 78% of presented cases of type IIB and III supracondylar humeral fractures in children. However, among the original cohort, 8.5% of the patients showed distal ischemia when placed in elbow flexion, and 10.7% did not maintain fracture reduction. In such situations, pin fixation is warranted. In carefully selected cases, Blount's method is a reasonable option for treating type IIB and III supracondylar humeral fractures in children. Close monitoring is necessary.

Disclaimer

The authors, their immediate families, and any research foundations with which they are affiliated have not received any financial payments or other benefits from any commercial entity related to the subject of this article.

References

1. Abe M, Ishizu T, Shirai H, Okamoto M, Onomura T. Tardy ulnar nerve palsy caused by cubitus varus deformity. *J Hand Surg Am* 1995;20:5-9.
2. Akakpo-Numado GK, Mal-Lawane M, Belouadah M, Kabore B, Lefort G, Daoud S. [Management of Lagrange and Rigault stage IV extension type supracondylar fracture of the humerus in children]. *Rev Chir Orthop Reparatrice Appar Mot* 2005;91:664-70. [http://dx.doi.org/10.1016/s0035-1040\(05\)84471-x](http://dx.doi.org/10.1016/s0035-1040(05)84471-x)
3. Battaglia TC, Armstrong DG, Schwend RM. Factors affecting forearm compartment pressures in children with supracondylar fractures of the humerus. *J Pediatr Orthop* 2002;22:431-9. <http://dx.doi.org/10.1097/01241398-200207000-00004>

4. Blakemore LC, Cooperman DR, Thompson GH, Wathey C, Ballock RT. Compartment syndrome in ipsilateral humerus and forearm fractures in children. *Clin Orthop Relat Res* 2000;376:32-8.
5. Blount WP. *Fractures in children*. Baltimore: Williams & Wilkins; 1954. p. 26-42.
6. Brauer CA, Lee BM, Bae DS, Waters PM, Kocher MS. A systematic review of medial and lateral entry pinning versus lateral entry pinning for supracondylar fractures of the humerus. *J Pediatr Orthop* 2007; 27:181-6. <http://dx.doi.org/10.1097/bpo.0b013e3180316cf1>
7. Clavert JM, Lecerf C, Mathieu JC, Buck P. [Retention in flexion of supracondylar fracture of the humerus in children. Comments apropos of the treatment of 120 displaced fractures]. *Rev Chir Orthop Reparatrice Appar Mot* 1984;70:109-16.
8. Damsin J, Langlais J. Fractures supracondyliennes. Symposium sur les fractures du coude chez l'enfant (sous la direction de J.-C. Pouliquen). *Rev Chir Orthop Reparatrice Appar Mot* 1987;73:421-36.
9. De Gheldere A, Bellan D. Outcome of Gartland type II and type III supracondylar fractures treated by Blount's technique. *Indian J Orthop* 2010;44:89. <http://dx.doi.org/10.4103/0019-5413.58612>
10. Dowd GS, Hopcroft PW. Varus deformity in supracondylar fractures of the humerus in children. *Injury* 1979;10:297-303. [http://dx.doi.org/10.1016/0020-1383\(79\)90047-0](http://dx.doi.org/10.1016/0020-1383(79)90047-0)
11. Flynn JC. Displaced supracondylar fracture of the humerus in children: technique of closed reduction and percutaneous pinning. *Oper Tech Orthop* 1993;3:121-7.
12. Flynn JC, Matthews JG, Benoit RL. Blind pinning of displaced supracondylar fractures of the humerus in children. Sixteen years' experience with long-term follow-up. *J Bone Joint Surg Am* 1974; 56:263-72.
13. Gartland JJ. Management of supracondylar fractures of the humerus in children. *Surg Gynecol Obstet* 1959;109:145-54.
14. Kennedy JG, El Abed K, Soffe K, Kearns S, Mulcahy D, Condon F, et al. Evaluation of the role of pin fixation versus collar and cuff immobilisation in supracondylar fractures of the humerus in children. *Injury* 2000;31:163-7.
15. Kinkpé CV, Dansokho AV, Niane MM, Chau E, Sales de Gauzy J, Clement JL, et al. Children distal humerus supracondylar fractures: the Blount Method experience. *Orthop Traumatol Surg Res* 2010;96:276-82. <http://dx.doi.org/10.1016/j.otsr.2009.12.010>
16. Labelle H, Bunnell WP, Duhaime M, Poitras B. Cubitus varus deformity following supracondylar fractures of the humerus in children. *J Pediatr Orthop* 1982;2:539-46.
17. Lagrange J, Rigault P. Les fractures de l'extrémité inférieure de l'humérus de l'enfant. *Rev Chir Orthop Reparatrice Appar Mot* 1962;48:334-414.
18. Maity A, Saha D, Roy DS. A prospective randomised, controlled clinical trial comparing medial and lateral entry pinning with lateral entry pinning for percutaneous fixation of displaced extension type supracondylar fractures of the humerus in children. *J Orthop Surg Res* 2012;7:6. <http://dx.doi.org/10.1186/1749-799X-7-6>
19. Mazda K, Boggione C, Fitoussi F, Penneçot GF. Systematic pinning of displaced extension-type supracondylar fractures of the humerus in children. A prospective study of 116 consecutive patients. *J Bone Joint Surg Br* 2001;83:888-93.
20. O'Driscoll SW, Spinner RJ, McKee MD, Kibler WB, Hastings H, Morrey BF, et al. Tardy posterolateral rotatory instability of the elbow due to cubitus varus. *J Bone Joint Surg Am* 2001;83-A:1358-69.
21. Sigge W, Behrens K, Roggenkamp K, Würtenberger H. [Comparison of Blount's sling and Kirschner wire fixation in the treatment of a dislocated supracondylar humeral fracture in childhood]. *Unfallchirurgie* 1987;13:82-90.
22. Skaggs DL, Cluck MW, Mostofi A, Flynn JM, Kay RM. Lateral-entry pin fixation in the management of supracondylar fractures in children. *J Bone Joint Surg Am* 2004;86-A:702-7.
23. Smith L. Deformity following supracondylar fractures of the humerus. *J Bone Joint Surg Am* 1960;42-A:235-52.
24. Taniguchi Y, Matsuzaki K, Tamaki T. Iatrogenic ulnar nerve injury after percutaneous cross-pinning of supracondylar fracture in a child. *J Shoulder Elbow Surg* 2000;9:160-2.
25. Wilkins K. Fractures and dislocations of the elbow region. In: Rockwood CA, Wilkins KE, King RE, editors. *Fractures in children*. 3rd ed. Philadelphia: JB Lippincott; 1991. p. 509-828.
26. Williamson DM, Cole WG. Treatment of selected extension supracondylar fractures of the humerus by manipulation and strapping in flexion. *Injury* 1993;24:249-52.
27. Woratanarat P, Angsanuntsukh C, Rattanasiri S, Attia J, Woratanarat T, Thakkinstian A. Meta-analysis of pinning in supracondylar fracture of the humerus in children. *J Orthop Trauma* 2012;26:48-53. <http://dx.doi.org/10.1097/BOT.0b013e3182143de0>