



HAL
open science

Physical therapy under hypnosis for the treatment of patients with type 1 complex regional pain syndrome of the hand and wrist: retrospective study of 20 cases

Julie Lebon, Michel Rongières, Costel Aprédoaei, Stéphanie Delclaux, Pierre Mansat

► To cite this version:

Julie Lebon, Michel Rongières, Costel Aprédoaei, Stéphanie Delclaux, Pierre Mansat. Physical therapy under hypnosis for the treatment of patients with type 1 complex regional pain syndrome of the hand and wrist: retrospective study of 20 cases. *Hand Surgery and Rehabilitation*, 2017, 36 (3), pp.215-221. 10.1016/j.hansur.2016.12.008 . hal-02135771

HAL Id: hal-02135771

<https://hal.science/hal-02135771>

Submitted on 21 May 2019

HAL is a multi-disciplinary open access archive for the deposit and dissemination of scientific research documents, whether they are published or not. The documents may come from teaching and research institutions in France or abroad, or from public or private research centers.

L'archive ouverte pluridisciplinaire **HAL**, est destinée au dépôt et à la diffusion de documents scientifiques de niveau recherche, publiés ou non, émanant des établissements d'enseignement et de recherche français ou étrangers, des laboratoires publics ou privés.




Open Archive Toulouse Archive Ouverte (OATAO)

OATAO is an open access repository that collects the work of some Toulouse researchers and makes it freely available over the web where possible.

This is an author's version published in: <https://oatao.univ-toulouse.fr/23098>

Official URL : <https://doi.org/10.1016/j.hansur.2016.12.008>

To cite this version :

Lebon, Julie and Rongières, Michel and Aprédoaei, Costel and Delclaux, Stéphanie and Mansat, Pierre  *Physical therapy under hypnosis for the treatment of patients with type 1 complex regional pain syndrome of the hand and wrist: Retrospective study of 20 cases.* (2017) *Hand Surgery and Rehabilitation*, 36 (3). 215-221. ISSN 2468-1229

Any correspondence concerning this service should be sent to the repository administrator:

tech-oatao@listes-diff.inp-toulouse.fr

Physical therapy under hypnosis for the treatment of patients with type 1 complex regional pain syndrome of the hand and wrist: Retrospective study of 20 cases

Rééducation sous protocole HKM (hypnothérapie combinée à la kinésithérapie ± Meopa) : une solution thérapeutique pour la prise en charge du syndrome douloureux complexe de type 1 de la main et du poignet. Étude rétrospective à propos de 20 cas

J. Lebon*, M. Rongières, C. Apredoaei, S. Delclaux, P. Mansat

Unité d'orthopédie et traumatologie de Purpan, institut de l'appareil locomoteur, CHU de Toulouse, place du Dr-Baylac, 31059 Toulouse cedex, France

ABSTRACT

Keywords:

Complex pain regional syndrome
Hypnosis
Therapy
Wrist
Hand

Type 1 complex regional painful syndrome (CRPS 1) has a complex physiopathology. The aim of this study was to evaluate the effectiveness of physical therapy under hypnotherapy to treat this condition. Twenty patients with CRPS 1 at the wrist and hand were evaluated retrospectively: 13 women and 7 men with an average age of 56 years (34-75). Thirteen patients were in the inflammatory phase and 7 in the dystrophic phase. The main endpoints were pain (VAS, analgesic use), stiffness (wrist and finger range of motion), and strength (pinch and grasp). Secondary endpoints were functional scores (QuickDASH, PWRE), patient satisfaction, return to work, and side effects. Results were satisfactory in all cases after 5.4 sessions on average. VAS decreased by 4 points, PWRE pain by 4.1 points, and analgesic use was limited to paracetamol upon request. Finger and wrist range of motion increased and the QuickDASH decreased by 34 points, PRWE function by 3.8 points, pinch strength increased 4 points, and grasp strength by 10 points. Return to work was possible in 80% of the cases. All patients were satisfied or very satisfied with the treatment. Physical therapy under hypnosis appears to be an effective treatment for CRPS 1 at the wrist and hand no matter the etiology.

RÉSUMÉ

Mots clés :

Syndrome douloureux régional complexe
Hypnose
Rééducation
Poignet
Main

Le syndrome douloureux régional complexe de type 1 (SDRC 1) est lié à une physiopathologie complexe. L'objectif de cette étude était d'évaluer l'efficacité de séances de kinésithérapie sous hypnose pour la prise en charge de ce syndrome. Vingt patients présentant un SDRC 1 au niveau de la main et du poignet ont été évalués de manière rétrospective : 13 femmes et 7 hommes de 56 ans en moyenne (34-75). Treize patients étaient en phase inflammatoire et 7 en phase dystrophique. Le critère de jugement principal était l'efficacité, évaluée par la douleur (échelle visuelle analogique [EVA], la consommation d'antalgiques), la raideur (mobilités du poignet et des doigts) et la force (pince et poigne). Les critères de jugement secondaires étaient les scores fonctionnels (QuickDASH, PWRE), la satisfaction du patient, la reprise du travail et les effets indésirables. Les résultats étaient satisfaisants dans tous les cas après 5,4 séances en moyenne. La douleur évaluée par l'EVA diminuait de 4 points, le score PWRE douleur de 4,1 points, et la consommation d'antalgique était limitée au paracétamol à la demande. Les amplitudes articulaires étaient toujours augmentées, le score QuickDASH moyen diminuait de 34 points, le score PWRE fonction de 3,8 points, la force de pince augmentait de 4 points et la force de poigne de 10 points.

* Corresponding author.

E-mail address: julie-lebon@hotmail.fr (J. Lebon).

Quatre vingt pour cent des patients ont pu reprendre leur travail au même poste. Tous les patients se disaient satisfaits ou très satisfaits. L'hypnose associée à la kinésithérapie semble être un moyen efficace pour la prise en charge du SDRC 1 main poignet quelle que soit sa phase évolutive.

1. Introduction

After many years of obscurity, we now have some insight into the pathophysiology of type 1 complex regional pain syndrome (CRPS 1): overexcited sympathetic nervous system, perturbations of the body map and contribution of psychological factors [1 3]. Despite better understanding of this disease, its treatment is long and difficult with unpredictable results. There is a significant socioeconomic impact due to its incidence (25/100,000 people).

There are multiple treatment options (corticosteroids, anti psychotics, antidepressants) that have varying degrees of effectiveness. To this day, few treatments that make use of psychological mediation have been validated. Hypnotherapy is being used increasingly to address pain, particularly chronic pain, and various psychological disorders. Since 2006, our surgery department has been providing patients suffering from CRPS 1 of the hand and wrist with physical therapy under hypnosis ± MEOPA (50% nitrous oxide 50% oxygen mixture).

The goal of this study was to specifically evaluate the effects of this strategy. We hypothesized that hypnotic suggestion reduces the activity of certain cerebral areas stimulated during painful treatment procedures, thereby resulting in better progression during rehabilitation.

2. Materials and methods

2.1. Materials

This was a retrospective study of data collected prospectively and continuously in the orthopedic and trauma surgery department of a French University hospital. Between May 1, 2014 and April 30, 2015, all patients with CRPS 1 of the hand and/or wrist were included in the study, no matter the etiology, time elapsed before treatment, prior treatments and disease phase (acute inflammatory, dystrophic, atrophic). The diagnosis of CRPS 1 was confirmed based on the presence of the International Association for the Study of Pain (IASP) criteria described by Merskey in 1994, as modified by Harden in 2007 [4]. Since the IASP criteria do not include a bone scan, it was not performed regularly.

Patients were excluded if this treatment strategy was not applicable to them, if they could not speak French reasonably well, were hard of hearing or refused hypnotherapy. All patients provided written consent.

2.2. Protocol and PT H method

Once the diagnosis had been made, the enrolled patients were asked to return to the pain clinical at the hospital, which is managed by anesthesiologists. The goals of this initial visit were to have an introductory meeting between the patient and hypnotherapist (nurse anesthetist with hypnotherapy training), to take the mystery out of hypnosis and to explain the details of application, and to collect all the pretreatment clinical data. All patients received care from a hypnotherapist and physiotherapist team. The same hypnotherapist worked with all patients, while two different physiotherapists cared for the patients.

All patients underwent a full clinical examination by the same examiner before the first PT H session and after the last session. The following clinical parameters were assessed:

- pain (daytime and nighttime VAS);
- wrist and finger range of motion (ROM): wrist flexion/extension, pronation/supination and ulnar/radial deviation; finger flexion/extension of the metacarpophalangeal (MCP) and proximal/distal interphalangeal (PIP, DIP) joints (retained value was the mean of the values in all four fingers);
- functional scores: QuickDASH, PWRE, and a subjective evaluation of the overall function of the hand and wrist called the simple hand value (SHV);
- pinch strength and grip strength.

Each PT H session took place as follows:

- first, an induction phase that allowed the patient to dissociate and protect themselves from pain;
- second, a treatment phase during which the physical therapist performed pain relieving modalities, lymphatic drainage massage and passive mobilization of the wrist and fingers in all directions.

Each session lasted an average of 45 to 60 minutes. One session was performed every week or two, depending on the availability of the patient, hypnotherapist and physical therapist. Between the PT H sessions, patients participated in a standard rehabilitation program with three sessions per week that combined pain relieving modalities, contrast baths, and gradual increase of the range of motion below the pain threshold. The sessions ended when the patients decided that they had recovered enough strength and ROM to do activities of daily living with no or minimal pain.

2.3. Endpoints

The primary endpoint was efficacy evaluated through pain (daytime and nighttime VAS, analgesic consumption), stiffness (finger and wrist ROM) and strength (pinch and grip). The secondary endpoints were the functional scores (QuickDASH, PWRE, SHV), return to work and hypnosis related side effects.

2.4. Statistical analysis

The qualitative variables were described with sample sizes and percentages associated with the various parameters of the study population. The quantitative variables were described with means and standard deviations (along with median and minimum, maximum), since the distribution of the quantitative variables met the normality assumptions. Student's *t* test was used to compare two measurements of a quantitative variable in the same patient at different time points. The difference between two variables was considered significant when $P < 0.05$ (5% threshold). No subgroup analysis was performed due to the small sample size (20 patients).

3. Results

3.1. Patient characteristics

Twenty patients were included: 13 women (65%) and 7 men (35%) with an average age of 56.6 years (34 75) (Table 1). None of

Table 1
Description of study population.

Population characteristics	Number/%
Sex	
Male	7 cases (35%)
Female	13 women (65%)
Age	
Mean (\pm std. dev.)	56.6 years (\pm 8.7 years)
Median	56.5 years
Min–Max	34–75 years
Dominant hand affected	10 cases (50%)
History of CRPS-1	0 cases (0%)
High-risk psychological background	10 cases (50%)
Work-related injury	3 cases (15%)
Smoker	4 cases (20%)
Etiology of CRPS-1	
Postoperative	18 cases (90%)
No surgical procedure	2 cases (10%)
IASP criteria present	20 cases (100%)
Confirmation by bone scan	9 cases (45%)
Phase of CRPS-1	
Acute inflammatory (I)	13 cases (65%)
Dystrophic (II)	7 cases (35%)
Atrophic (III)	0 cases (0%)
Time to diagnosis	
Mean (\pm std. dev.)	4 months (\pm 5 months)
Median	2 months
Min–Max	0.5–22 months
Time between diagnosis and PT-H treatment	
Mean (\pm std. dev.)	10 weeks (\pm 10 weeks)
Median	7 weeks
Min–Max	2–44 weeks

CRPS-1: type 1 complex regional painful syndrome.

the patients had a history of complex regional pain syndrome, however 10 patients (50%) had a fragile psychological background. Six patients had a recent major episode of depression or anxiety provoking event (bereavement, separation) and 4 patients had highly anxious and/or highly stressed personality. The patients had various occupations and less than half were manual laborers. At inclusion, 13 of the 15 employed patients were on sick leave (87%) for an average of 6.5 months (range 2.5–24). Although the CRPS had various causes in our cohort, 90% of cases occurred following surgery (18 patients). Only two patients had not undergone surgery: one non displaced fracture of the scaphoid and one contusion to the dorsal side of the hand.

The IASP criteria were positive in 100%, confirming the presence of CRPS 1. As the diagnosis was uncertain in 9 patients (45%), a bone scan was also performed to confirm the diagnosis. At the time of inclusion, most patients (13 cases, 65%) were in the acute inflammatory stage. The mean time to diagnosis was 4 months (median 2 months, range 15 days to 22 months). The mean time to treatment once the diagnosis was made was 10 weeks (median 7 weeks, range 2–44 weeks).

At the time of inclusion, various treatments had already been performed. Analgesics with physical therapy below the pain threshold had been used in 100% of patients. Fifteen patients (75%) also had contrast baths and then a variety of other treatments: homeopathy, acupuncture, corticosteroid injections, essential oils, electrostimulation, osteopathy, ultrasound.

3.2. Pre PT H clinical assessment

A complete bilateral clinical assessment was done in all patients before the first PT H session (Table 2). All patients had moderate to severe pain with an average daytime VAS of 6.2/10 and average PWRE pain of 6.9/10. The active ROM of the wrist and fingers was clearly reduced relative to the contralateral side: nearly 50% reduction in the flexion/extension range of the wrist MCP, DIP and PIP joints. Pain associated with stiffness resulted in a loss of pinch

Table 2
Pre-PT-H clinical evaluation.

	Affected side Mean (\pm std. dev.) Median Min–Max	Healthy side Mean (\pm std. dev.) Median Min–Max
Daytime VAS (out of 10)	6.2 \pm 1.6 6 3–9	
Nighttime VAS (out of 10)	3 \pm 3.2 3 0–10	
SHV (%)	35 \pm 16 32.5 0–60	
QuickDASH (out of 100)	62 \pm 18 64 23–100	
PWRE-pain (out of 10)	6.9 \pm 1.5 7.1 3.1–9.2	
PWRE-function (out of 10)	5.7 \pm 1.8 5.2 2.8–9.5	
Wrist FE ROM (degrees)	68 \pm 31 67 20–120	114 \pm 15 110 85–140
Wrist PS ROM (degrees)	133 \pm 22 140 90–170	154 \pm 7 140 90–170
Wrist URD ROM (degrees)	36 \pm 16 40 0–60	50 \pm 7 50 35–65
Finger MCP FE ROM (degrees)	53 \pm 19 60 10–90	87 \pm 5 90 80–95
Finger PIP FE ROM (degrees)	61 \pm 25 60 5–110	115 \pm 7 117 100–120
Finger DIP FE ROM (degrees)	28 \pm 12 30 10–50	51 \pm 5 50 45–60
Pinch strength (kg)	8.5 \pm 5 7.5 0–21	15.5 \pm 7 14.5 5–33
Grip strength (kg)	9 \pm 6 9 0–19	26.5 \pm 9.5 23.5 17–50

VAS: visual analog scale; SHV: simple hand value (subjective function according to patient of affected hand out of 100%); FE: flexion/extension; PS: pronation/supination; URD: ulnar/radial deviation; MCP: metacarpophalangeal joint; PIP: proximal interphalangeal joint; DIP: distal interphalangeal joint.

strength and especially grip strength, which was an average of three times lower than the contralateral side. The general and specific functional scores were altered: the SHV in the affected hand was 35% on average related to a “normal” hand, QuickDASH of 62/100 on average and PWRE function of 5.7/10.

All patients had already received suitable analgesic and rehabilitation treatments, typically including pain relieving physical therapy modalities and contrast baths. Despite these treatment, many symptoms of CRPS were present before the PT H sessions started: pain (100%), stiffness (85%), edema (70%), hypoesthesia/paresthesia (55%), muscle weakness (50%), hot skin (50%), dry skin (50%), cold/cyanotic skin (30%), involvement of integumentary system (25%), skin redness (20%), excessive perspiration (10%).

Analgesic intake was high and 87% of patients were on sick leave at the time of inclusion (13/15 employed patients).

3.3. Post PT H clinical assessment

Sessions were done once per week or every 15 days. MEOPA was needed in 12 patients (60%) during the initial sessions to control pain during passive mobilization. Once the treatment goals had

been achieved (minimal or no pain, ability to carry out activities of daily living), the PT H sessions were stopped. Patients participated in an average of 5.4 (± 1.5) sessions (median 5, range 3–9). The mean treatment time was 6.5 (± 2) weeks (median 6 weeks, range 3–12 weeks).

Once the last PT H session had been completed, the full clinical assessment was repeated (Table 3). In most patients, edema and sympathetic symptoms were the first to disappear, typically within one or two sessions (Fig. 1). Pain was minimal or completely gone with an average daytime VAS of 2.2/10 and average PWRE pain of 2.8/10. Active wrist and finger ROM were clearly improved in all directions. The pinch and grip strength were similarly improved. Consequently, the general and specific functional scores for the hand were also improved: the SHV in the affected hand was 75% on average relative to a “normal” hand, QuickDASH of 28/100 on average and PWRE function of 1.9/10.

Some symptoms of CRPS persisted but were minimally disruptive: stiffness (90%), pain (40%), paresthesia (10%), edema (10%), cutaneous disorders (5%), muscle weakness (5%). The intake of analgesics was nearly zero and 80% of the patients who had been on sick leave (10 patients) at the time of inclusion were back to

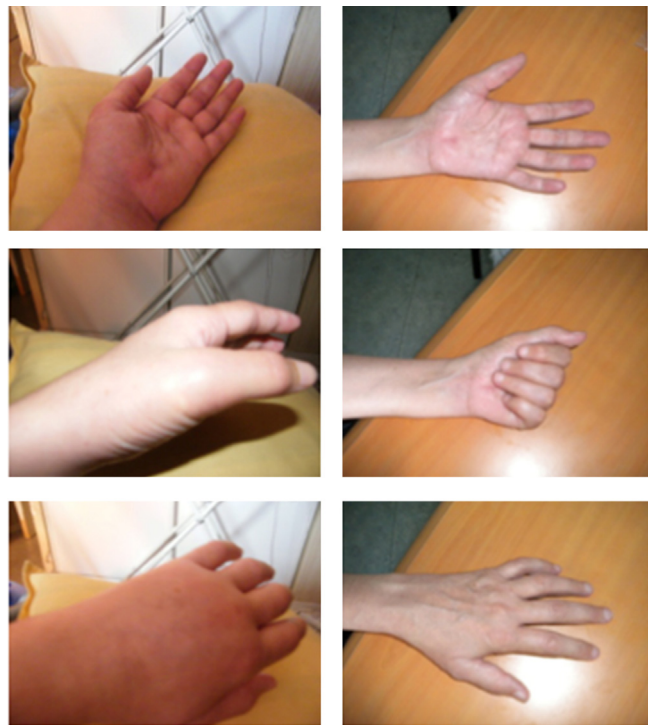

Fig. 1. A 39-year-old female patient with type 1 complex regional painful syndrome (CRPS-1) who has significant swelling in her hand before the PT-H sessions (left photos) and whose hand is normal after 5 sessions (right photos). She had CRPS-1 secondary to open carpal tunnel release. She developed CRPS-1 at 2 months postoperative and the left photos show her hand after 7 months of standard treatment (light physical therapy, contrast baths, analgesics). After five PT-H sessions, the patients stopped taking all analgesics and returned to work. Before the PT-H sessions, she took morphine daily.

Table 3
Post-PT-H clinical evaluation.

	Affected side Mean (\pm std. dev.) Median Min–Max	Healthy side Mean (\pm std. dev.) Median Min–Max
Daytime VAS (out of 10)	2.2 \pm 1.1 2.5 0–4	
Nighttime VAS (out of 10)	0.3 \pm 0.9 0 0–3	
SHV (%)	75 \pm 9 75 60–95	
QuickDASH (out of 100)	28 \pm 10 30 11–45	
PWRE-pain (out of 10)	2.8 \pm 1.2 2.6 0.8–4.5	
PWRE-function (out of 10)	1.9 \pm 0.8 2 0.6–3	
Wrist FE ROM (degrees)	105 \pm 17 102 75–130	115 \pm 15 110 95–140
Wrist PS ROM (degrees)	150 \pm 12 150 120–170	153 \pm 9 150 130–170
Wrist URD ROM (degrees)	47 \pm 7 50 35–55	50 \pm 6 50 35–60
Finger MCP FE ROM (degrees)	80 \pm 9 80 65–90	87 \pm 5 90 80–100
Finger PIP FE ROM (degrees)	94 \pm 15 100 65–110	115 \pm 6 115 100–120
Finger DIP FE ROM (degrees)	43 \pm 7 45 30–60	51 \pm 6 50 45–60
Pinch strength (kg)	12.5 \pm 5 11.5 5–21	14.5 \pm 5 14 6–25
Grip strength (kg)	19 \pm 6 18.5 12–33	26 \pm 9 24 15–50

VAS: visual analog scale; SHV: simple hand value (subjective function according to patient of affected hand out of 100%); FE: flexion/extension; PS: pronation/supination; URD: ulnar/radial deviation; MCP: metacarpophalangeal joint; PIP: proximal interphalangeal joint; DIP: distal interphalangeal joint.

work in the same job, immediately after the sessions ended. However, because of the persistence of some symptoms at the final assessment, all patients continued the rehabilitation protocol with two or three gentle physical therapy sessions per week until complete pain relief was achieved and full ROM was restored. As of May 2016, no relapses had occurred.

3.4. Evaluation of endpoints

3.4.1. Primary endpoint: efficacy

There was a statistically significant improvement in pain between the pre and post PT H as evidenced by the daytime and nighttime VAS and the PWRE pain score (Figs. 2 and 3).

Analgesic use was also significantly reduced: 12 patients (60%) did not use any analgesics after the hypnotherapy versus 0 before ($P < 0.001$). There was a significant improvement in all the joint ROM directions (Fig. 4). Pinch and particularly the grip strength were also significantly increased (Fig. 5).

3.4.2. Secondary endpoints

The ROM, analgesia and strength were significantly improved, as were the three functional scores; the SHV had more than doubled (35% to 75%) (Fig. 6). Of the 15 patients who were still working, 2 (13%) had returned to work before the PT H sessions versus 12 (80%) after the PT H sessions. Of the three patients who could not return to work, two were heavy manual laborers and one did an occupation that required delicate, precise hand motions that had not yet been recovered.

All the patients were either satisfied or very satisfied with this treatment. The following adverse effects were documented: fatigue for a few hours after the PT H sessions in 8 cases (40%) and minor vertigo in 2 cases (10%). Seventy percent of patients said

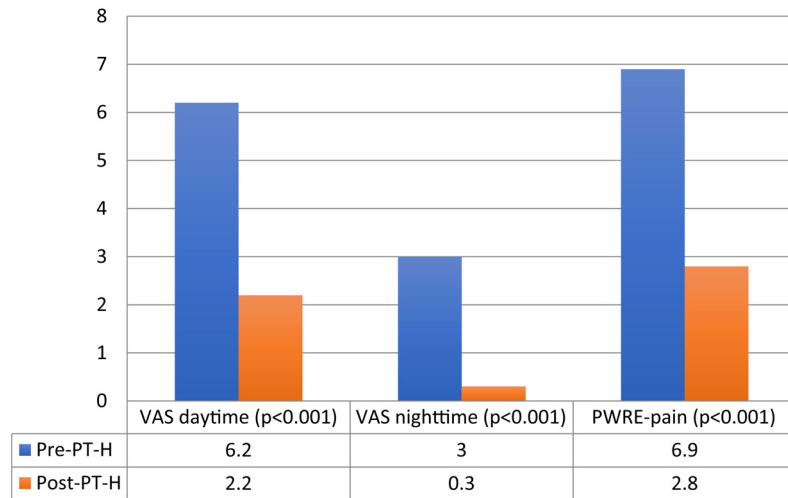


Fig. 2. Outcomes in terms of pain.

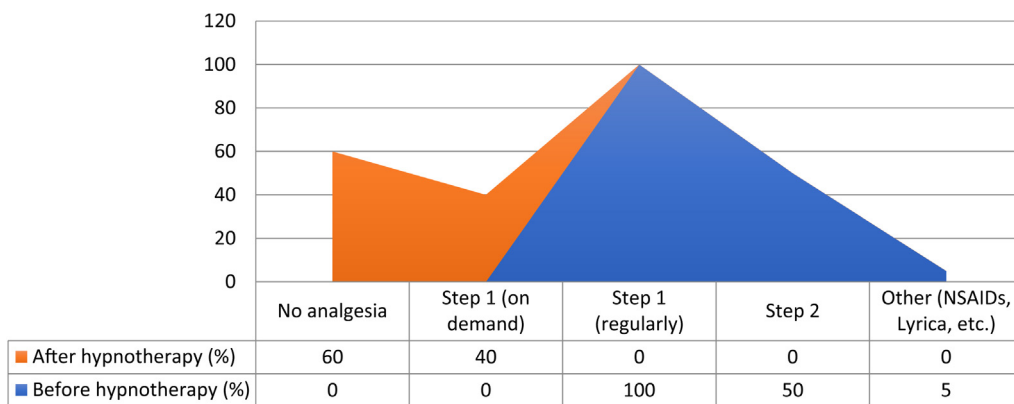


Fig. 3. Outcomes in terms of analgesic use.

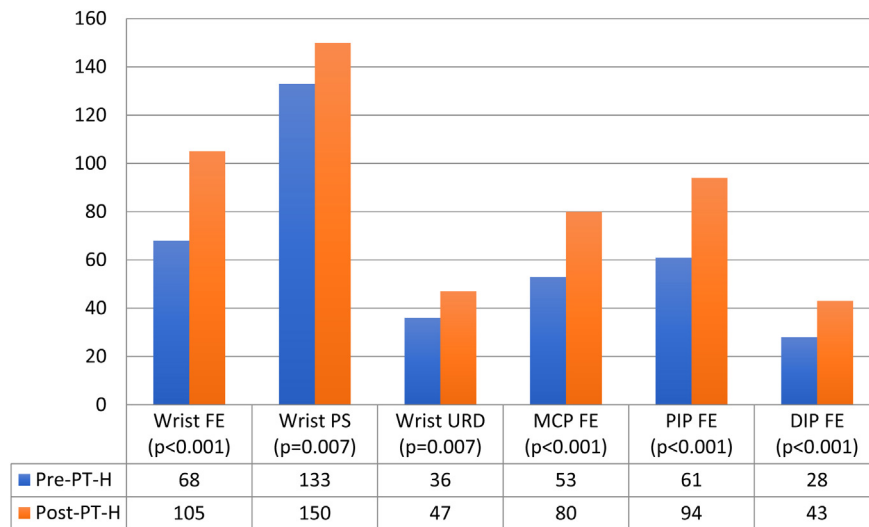


Fig. 4. Outcomes in terms of range of motion (ROM). FE: flexion-extension; PS: pronation-supination; URD: ulnar/radial deviation; MCP: metacarpophalangeal joint; IPP: proximal interphalangeal joint; IPD: distal interphalangeal joint.

they were deeply relaxed and even mildly sedated after the sessions.

4. Discussion

CRPS was first described by Ambroise Paré in the 17th century. Various names have been used to describe it since then: causalgia,

algodystrophy, reflex sympathetic dystrophy, Sudeck's syndrome [2]. Typically, CRPS is characterized by disproportionate chronic pain, significant stiffness, involvement of the autonomic nervous system and sensory motor symptoms [5]. Type 1 corresponds to the absence of underlying nerve damage. Although many paraclinical methods can be used to confirm the diagnosis, the diagnosis is a clinical one based on the IASP criteria published in

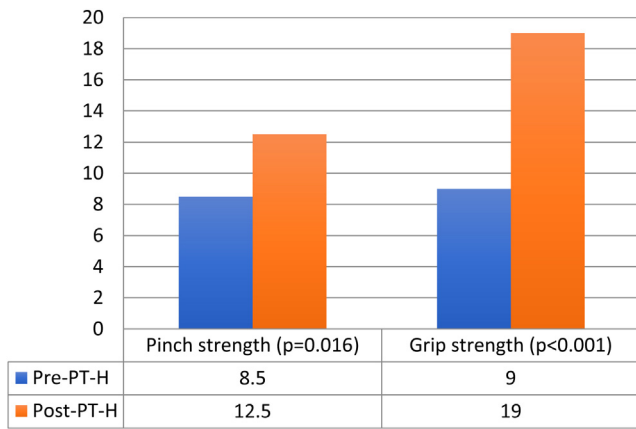


Fig. 5. Outcomes in terms of strength.

2004 [1,4]. René Leriche in 1916 1923 and Evans in 1947 1948 developed the “sympathetic” theory of CRPS. Since the mid 1990s, the development of neuroscience has led to a better understanding of the pathophysiology of CRPS with overexcitation of the sympathetic nervous system, perturbations of the body map and contribution of psychological factors [3,4]. Recent neurophysiology studies have been consistent in finding that central mechanisms not peripheral ones have an essential role. The appearance of a prolonged reaction of the sympathetic nervous system at the periphery of an injured area is physiological, however it is the persistence and overexcitation that are pathological [6,7]. Patients have an abnormal cortical body map of the affected limb and its movements. This leads to perturbation in the recording of parietal activity in the motor and premotor areas [6,7].

Various treatments have been used to treat CRPS 1: NSAIDs, anticonvulsants, antidepressants, sodium channel blockers, vaso dilators. The efficacy of these treatments varies, although none has been able to quickly and effectively cure CRPS 1 [1 3]. These treatments are used in combination with pain relieving physical therapy modalities and contrast baths; however, no physical therapy modality has been demonstrated to be effective.

Up to now, few treatment strategies that use psychological mediation have been evaluated and no study on the psychological profile of patients has revealed any reliable preoperative risk factors.

In recent years, hypnosis has been used to treat pain and various psychological disorders [5,8]. Hypnosis acts both at the cortical

areas for pain and at the medullary level on the RIII or nociceptive flexion reflex [9]. This effect is not specific to CRPS: it contributes to all types of pain, whether acute or chronic. The hypnotic effect helps patients focus their attention on their representation of pain, thereby altering its perception [9].

This led us in 2006 to implement a PT H strategy in CRPS patients. The results were very good, particularly in terms of analgesic use, sympathetic symptoms and stiffness, although all patients were treated whether they had type 1 or type 2 CRPS, in the upper limb or lower limb. We wanted to validate our clinical observations with a scientific study focused on CRPS 1 in the hand and wrist.

In our study, all patients benefited from the hypnotherapy as evidenced by the significant improvement in pain, ROM and strength. The improvement in the joint ROM of the fingers resulted in better finger curling, thus better gripping ability and significant improvement in grip strength. The combined improvement in pain, stiffness and strength led to a reduction in analgesic use and return to work in many cases.

No matter the etiology, the wait before treatment initiation, prior treatments, sex, and age, the PT H strategy was effective and required about 6 weeks (average of 5.4 sessions) to achieve a satisfactory result, versus 6 months to 2 years with typical treatment strategies.

Moreover, early diagnosis and treatment are important factors in determining the outcomes of CRPS treatments [10]. In our study, there was a trend towards better clinical outcomes and shorter treatment time when CRPS 1 was diagnosed earlier (during the acute inflammatory phase). However, our cohort was too small to carry out subgroup analysis or a comparative study.

Our study has certain limitations: small sample size, inclusion of all CRPS 1 cases independent of the disease phase or the disease duration. Continuing the standard treatment at the same time as the PT H strategy is also a source of bias, as it may have falsely improved the outcomes.

Despite these good outcomes, all patients had to continue receiving light physical therapy in the following weeks to fully recover the last degrees of ROM that were missing. The PT H strategy was essentially able to surpass the hyperalgesic and highly symptomatic threshold typical of CRPS.

This strategy is relevant for the patient and the physician as it is a concrete solution to a condition that currently does not really have a treatment. But the mechanism of action that makes hypnosis effective has not been explained.

There are no published studies of hypnosis being used as a treatment for CRPS; however, there are many articles on the use

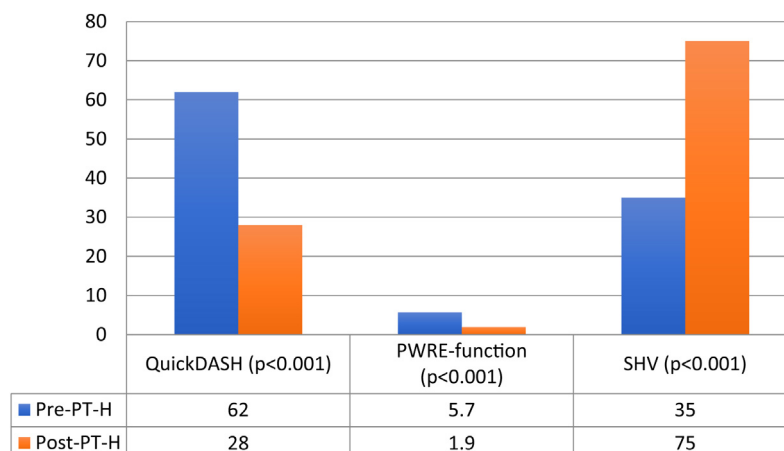


Fig. 6. Outcomes in terms of functional scores.

of hypnosis to relieve chronic pain [11–15]. Hypnotic suggestion therapy reduces the activity of certain brain areas that are generally stimulated during painful treatments. It also allows virtual activation of a pathological limb that stimulates the same brain areas activated during true limb mobilization: frontal premotor cortex, supplementary motor area and motor cortex. Voluntary movements during hypnotic suggestion do not act on the same brain areas as during simple mobilization; in particular, the posterior frontal premotor areas are activated. These topographic areas coincide with the altered ones in patients with CRPS [16,17]. Stimulation of the premotor areas, due to activation of the canonical neurons and mirror neurons, is one of the keys to rehabilitation of the phantom limb and it has been applied successfully to CRPS [18]. The brain projects the action before it is performed (mirror neurons) by reproducing either an acquired movement or an imitated movement. The canonical neurons are the preliminary stage in the brain, for example when seeing an object, and will become systemically excited [19].

Hypnosis is closely akin to other techniques that have already been validated for the treatment of CRPS such as the Moseley mirror therapy [16] and vibration therapy [4]. The objective is to recreate the illusion of movement: using the symmetry of the mirror in which the contralateral limb appears, by proprioceptive routes excited by vibration or hypnotic induction, which will provoke the illusion of movement. There are different models of movement induction but all have the same goal: recreate the illusion of movement to disrupt the blockage and exclusion of the affected limb segment, thereby freeing the patient from pain and functional disability.

Moreover, hypnosis acts on the affective/emotional component of pain by reducing its unpleasant nature and the perception of its intensity. Lastly, it allows the release of suppressed emotions. In fact, patients have an easier time confiding and in most cases, find a notable fact or event that coincided with the development of CRPS, such as loss of job, break up, bereavement, or even old fears or childhood trauma. Such emotional releases are frequently observed during the sessions and often give the patient immediate relief. Thus, it seems essential to integrate this psychological dimension in the overall treatment strategy for CRPS.

These various aspects of hypnosis explain the importance of this practice in the context of CRPS 1, both for performing potentially painful physical therapy procedures and for allowing pain and dysautonomia symptoms to disappear. This method now provides us with a safe and effective tool for treating CRPS; however, a large, multicenter, prospective study is needed to confirm our findings.

5. Conclusion

Hypnotherapy combined with physical therapy appears to be an effective treatment strategy for CRPS 1 in the hand and wrist, no matter the disease stage. It can be used with all patients and had no noteworthy side effects.

Disclosure of interest

The authors declare that they have no competing interest.

References

- [1] Gay AM, Béréni N, Legré R. Type I complex regional pain syndrome. *Chir Main* 2013;32:269–80.
- [2] Coderre TJ. Complex regional pain syndrome: what's in a name? *J Pain* 2011;12:2–12.
- [3] Bussa M, Guttilla D, Lucia M, Mascaro A, Rinaldi S. Complex regional pain syndrome type I: a comprehensive review. *Acta Anaesthesiol Scand* 2015;59:685–97.
- [4] Gay A, Paratte S, Salazard B, Guinard D, Pham T, Legré R, et al. Proprioceptive feedback enhancement induced by vibratory stimulation in complex regional pain syndrome type I: an open comparative pilot study in 11 patients. *Joint Bone Spine* 2007;74:461–6.
- [5] Marinus J, Van Hilten JJ. Clinical expression profiles of complex regional pain syndrome, fibromyalgia and a-specific repetitive strain injury: more common denominators than pain? *Disabil Rehabil* 2006;28:351–62.
- [6] Jänig W, Baron R. Complex regional pain syndrome: mystery explained? *Lancet Neurol* 2003;2:687–97.
- [7] Barber A, Moreni A. Place de l'hypnose dans le traitement du SDRC. *Kinesither Rev* 2015;15:45–9.
- [8] Molton IR, Graham C, Stoelb BL, Jensen MP. Current psychological approaches to the management of chronic pain. *Curr Opin Anaesthesiol* 2007;20:485–9.
- [9] Faymonville ME, Boly M, Laureys S. Functional neuroanatomy of the hypnotic state. *J Physiol Paris* 2006;99:463–9.
- [10] Perez RS, Zollinger PE, Dijkstra PU, Thomassen-Hilgersom IL, Zuurmond WW, Rosenbrand KC, et al. Evidence based guidelines for complex regional pain syndrome type 1. *BMC Neurol* 2010;10:20.
- [11] Tan G, Rintala DH, Jensen MP, Fukui T, Smith D, Williams W. A randomized controlled trial of hypnosis compared with biofeedback for adults with chronic low back pain. *Eur J Pain* 2015;19:271–80.
- [12] Gainer MJ. Hypnotherapy for reflex sympathetic dystrophy. *Am J Clin Hypn* 1992;34:227–32.
- [13] Elkins G, Jensen MP, Patterson DR. Hypnotherapy for the management of chronic pain. *Int J Clin Exp Hypn* 2007;55:275–87.
- [14] Artimon HM. Hypnotherapy of a pain disorder: a clinical case study. *Int J Clin Exp Hypn* 2015;63:236–46.
- [15] Jensen M, Patterson DR. Hypnotic treatment of chronic pain. *J Behav Med* 2006;29:95–124.
- [16] Moseley GL. Graded motor imagery is effective for long-standing complex regional pain syndrome: a randomised controlled trial. *Pain* 2004;108:192–8.
- [17] Schwartzman RJ, Erwin KL, Alexander GM. The natural history of complex regional pain syndrome. *Clin J Pain* 2009;25:273–80.
- [18] McCabe CS, Haigh RC, Ring EFJ, Halligan PW, Wall PD, Blake DR. A controlled pilot study of the utility of mirror visual feedback in the treatment of complex regional pain syndrome (type 1). *Rheumatol (Oxford)* 2003;42:97–101.
- [19] Desmurget M, Reilly KT, Richard N, Szathmari A, Mottolese C, Sirigu A. Movement intention after parietal cortex stimulation in humans. *Science* 2009;324:811–3.