



HAL
open science

Selective versus hyperselective posterior fusions in Lenke 5 adolescent idiopathic scoliosis: comparison of radiological and clinical outcomes

Brice Ilharreborde, Emmanuelle Ferrero, Audrey Angelliaume, Yan Lefèvre, Franck Accadbled, Anne-Laure Simon, Jérôme Sales de Gauzy, Keyvan Mazda

► To cite this version:

Brice Ilharreborde, Emmanuelle Ferrero, Audrey Angelliaume, Yan Lefèvre, Franck Accadbled, et al.. Selective versus hyperselective posterior fusions in Lenke 5 adolescent idiopathic scoliosis: comparison of radiological and clinical outcomes. *European Spine Journal*, 2017, 26 (6), pp.1739-1747. 10.1007/s00586-017-5070-2 . hal-02135745

HAL Id: hal-02135745

<https://hal.science/hal-02135745>

Submitted on 21 May 2019

HAL is a multi-disciplinary open access archive for the deposit and dissemination of scientific research documents, whether they are published or not. The documents may come from teaching and research institutions in France or abroad, or from public or private research centers.

L'archive ouverte pluridisciplinaire **HAL**, est destinée au dépôt et à la diffusion de documents scientifiques de niveau recherche, publiés ou non, émanant des établissements d'enseignement et de recherche français ou étrangers, des laboratoires publics ou privés.





Open Archive Toulouse Archive Ouverte (OATAO)

OATAO is an open access repository that collects the work of some Toulouse researchers and makes it freely available over the web where possible.

This is an author's version published in: <https://oatao.univ-toulouse.fr/23125>

Official URL : <https://doi.org/10.1007/s00586-017-5070-2>

To cite this version :

Ilharreborde, Brice and Ferrero, Emmanuelle and Angelliaume, Audrey and Lefèvre, Yan and Accadbled, Franck  and Simon, Anne-Laure and Sales de Gauzy, Jérôme  and Mazda, Keyvan *Selective versus hyperselective posterior fusions in Lenke 5 adolescent idiopathic scoliosis: comparison of radiological and clinical outcomes.* (2017) *European Spine Journal*, 26 (6). 1739-1747. ISSN 0940-6719

Any correspondence concerning this service should be sent to the repository administrator:

tech-oatao@listes-diff.inp-toulouse.fr

Selective versus hyperselective posterior fusions in Lenke 5 adolescent idiopathic scoliosis: comparison of radiological and clinical outcomes

B. Ilharreborde¹ · E. Ferrero¹ · A. Angelliaume² · Y. Lefèvre² · F. Accadbled³ · A. L. Simon¹ · J. Sales de Gauzy³ · K. Mazda¹

Abstract

Purpose Recent literature has reported that the progression risk of Lenke 5 adolescent idiopathic scoliosis (AIS) during adulthood had been underestimated. Surgery is, therefore, proposed more to young patients with progressive curves. However, choice of the approach and fusion levels remains controversial. The aim of this study was to analyze the influence of the length of posterior fusion on clinical and radiological outcomes in Lenke 5 AIS.

Methods All Lenke 5 AIS operated between 2008 and 2012 were included with a minimum 2-year follow-up. Patients were divided into two groups according to the length of fusion. In the first group (selective), the upper instrumented level (UIV) was the upper end vertebra of the main structural curve and distally the fusion was extended to the stable and neutral vertebra, according to Lenke's classification. In the second group (hyperselective), shorter fusions were performed and the number of levels fused depended on the location of the apex of the curve (at maximum, 2 levels above and below, according to Hall's criteria). Apart from the fusion level selection, the surgical procedure was similar in both groups. Radiological outcomes and SRS-22 scores were reported.

Results 78 patients were included (35 selective and 43 hyperselective). The number of levels fused was significantly higher in the first group (7.8 ± 3 vs 4.3 ± 0.6). None of the patients was fused to L4 in selective group. No correlation was found between length of fusion and complication rate. Eight patients had adding-on phenomenon among which 6 (75%) had initially undergone hyperselective fusions and had significantly higher postoperative lower instrumented vertebra (LIV) tilt. In the adding-on group, LIV was located above the last touching vertebra (LTV) in 62.5% of the cases and above the stable vertebra (SV) in 87.5%. Patients in the selective group reported a significantly lower score in the SRS function domain.

Conclusion Coronal alignment was restored in both groups. Hyperselective posterior fusions can be considered in Lenke 5 AIS, preserving one or two mobile segments, with similar clinical and radiological outcomes. However, selection of the LIV according to SV and LTV need to be accurately analyzed in order to avoid adding-on during follow-up.

Keywords Adolescent idiopathic scoliosis · Lenke 5 · Selective fusion · Short segment

✉ B. Ilharreborde
brice.ilharreborde@aphp.fr

¹ Department of Paediatric Orthopaedics, Robert Debré Hospital, AP HP, Paris Diderot University, 48 Boulevard Serurier, 75019 Paris, France

² Department of Paediatric Orthopaedics, Pellegrin University Hospital, Place Amelie Raba Leon, 33076 Bordeaux, France

³ Department of Paediatric Orthopaedics, Purpan University Hospital, Place du Docteur Baylac, 31059 Toulouse, France

Introduction

Recent literature has reported that the progression risk of Lenke 5 adolescent idiopathic scoliosis (AIS) during adulthood had been underestimated and that curves greater than 35° should be carefully followed after skeletal maturity. As a matter of fact, Pesenti et al. reported that 50% of these curves demonstrated significant progression after 20 years of follow-up [1]. Surgery is, therefore, more often considered in AIS patients with progressive curves greater

than 40°, especially in case of clinical imbalance or cosmetic demand. However, the choice of the approach, the selection of fusion levels and more specifically the length of arthrodesis remain controversial. Some authors reported a greater loss of function with long fusions ending below L3 [2–5], but postoperative functional outcomes similar to those of asymptomatic subjects of the same age have also been found at 2-year follow-up [6–9].

Lenke 5 AIS correction can be addressed through posterior or anterior approach. In the latter, surgeons usually tend to fuse less mobile segments, following Hall's recommendations and, therefore, sometimes accept a residual lower instrumented vertebra (LIV) tilt in order to reduce the risk of future adjacent segment degeneration [10–13]. In the past decade, the posterior correction of Lenke 5 has regained popularity due to the development of all-screw constructs and direct vertebral derotation technique. In most of the cases, fusions are selective, sparing the thoracic spine, but extend from the upper end to the lower end vertebrae of the main structural curve (selective fusion) [10]. Fusions down to L4 are, therefore, sometimes necessary, especially when the apex is located below L2, leaving only two mobile discs below the fusion mass [12]. No long-term study has ever compared short segment anterior and selective posterior fusions. In fact, the feasibility of such a comparison can be questioned due to the bias represented by the different approaches.

Recently, some surgeons have tended to reduce their fusion length in posterior procedures as well (hyperselective fusion), using the criteria initially described for anterior surgery, because they strongly believed in the 3D correction potential of pedicle screws and were concerned about the future risk of adjacent degeneration [10, 14]. The aim of this study was, therefore, to compare the clinical and radiological outcomes of selective and hyperselective fusions in Lenke 5 AIS operated via posterior approach.

Materials and methods

Patients

After IRB approval, all consecutive patients with Lenke 5 AIS operated through posterior approach in two departments (5 senior surgeons) between July 2008 and October 2012 were included. Clinical, surgical and radiological data were collected with a minimum 2-year follow-up. Patients with previous spine surgery or significant lower limb deformity affecting the frontal pelvic tilt were excluded.

Operative procedure

Patients were divided into two groups according to the surgical strategy. In center 1 (selective group), fusions were performed aiming to optimize the restoration of both coronal and sagittal alignments [13, 15]. The upper instrumented vertebra (UIV) was the upper end vertebra of the main structural curve. Attention was paid to stop the fusion below the apex of the thoracic kyphosis (below T6) in order to avoid proximal junctional kyphosis. The vertebra selected as LIV had to be neutral on standing films, crossed between its pedicles by the center sacral vertical line (CSVL) and located above a mobile disc on bending films [16]. Fusions were never extended below L4, leaving at least two mobile discs under the fusion mass.

Short-segment fusions were performed in center 2 (hyperselective group), following the rules initially described for short-segment anterior fusion by John Hall [17]. When the apex was located on a vertebral body, fusion extended one vertebra above and one vertebra below; while if the apex was located on a disc, fusion extended from two vertebrae above to two vertebrae below (Fig. 1).

Apart from the fusion level selection, the surgical procedures were similar in both centers, using 5.5 Titanium rods and lumbar pedicular screws (Legacy Medtronic,

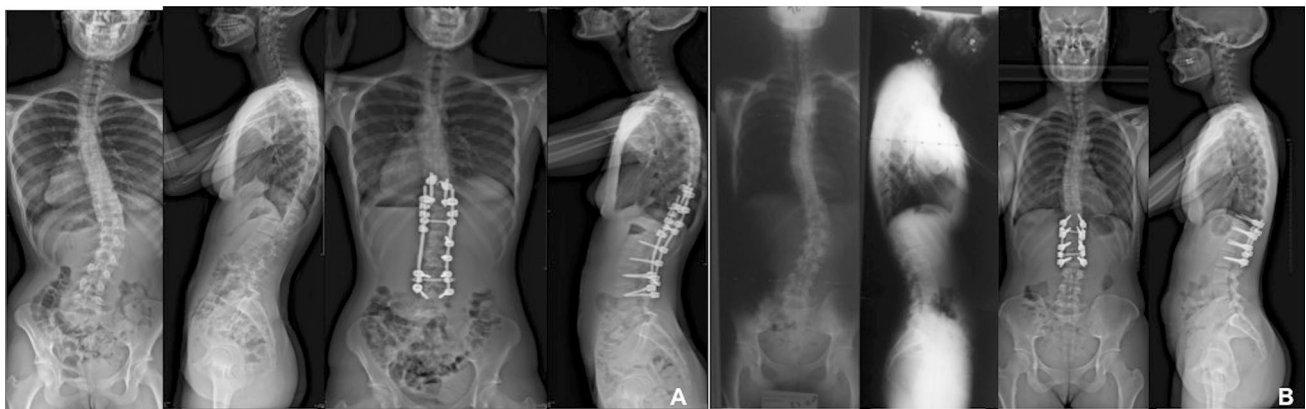

Fig. 1 Pre and postoperative X rays of patient of selective (a) and hyperselective group (b)

Minneapolis, MN, USA), sometimes supplemented by sublaminar bands (Jazz Implanet, Bordeaux, France) at thoracic levels. The proximal fixation was either performed by supralaminar hooks or pedicle screws, depending on surgeon's preference. Rod derotation and in situ bending were the main techniques used for correction. Arthroctomy was performed at each fusion level. No patient underwent anterior release. The same perioperative blood saving strategy was used in all patients, associating intraoperative cell saver and tranexamic acid. Spinal cord monitoring was systematically performed.

Radiological parameters

Patients underwent low-dose biplanar radiographs using the EOS system (EOS imaging, Paris, France) preoperatively, postoperatively (within 1 month) and at latest follow-up, as previously described [18]. Spinal measurements were performed using the dedicated SterEOS software, by an experienced independent spinal surgeon. Coronal parameters included Cobb angles of the main and thoracic curves, LIV tilt (angle between the lower endplate of the LIV and the horizontal line), ilio-lumbar angle (ILA, angle between the lower endplate of L4 and the line joining the 2 sacroiliac joints) and the offset between the vertical line from the center of the sacral endplate (center sacral vertical line, CSVL) and the center of C7 (Fig. 2). Location of the last touching vertebra (LTV, the most proximal lumbar vertebra that touches the CSVL) was determined according to Lenke's definition on standing films [19].

On sagittal radiographs, the following parameters were measured: T4T12 thoracic kyphosis (TK), L1S1 lumbar lordosis (LL) and pelvic parameters (pelvic incidence (PI), sacral slope (SS), pelvic tilt (PT)). The sagittal vertical axis (SVA, distance between the vertical line from the center of C7 and the posterosuperior corner of S1) was also analyzed. SVA was considered positive if directed forwards and negative if directed backwards.

As described by Berjano et al., lumbar lordosis was considered adapted to the pelvic incidence if values respected the following equation: $LL = PI \pm 9^\circ$ [20–22].

Functional outcomes and complications

Functional outcomes were assessed at follow-up using the Scoliosis Research Society SRS-22 questionnaires [23]. All clinical and radiological complications, including unplanned surgeries, were recorded. Adding-on was defined as a progression greater than 5° of the LIV frontal tilt [24], while proximal junctional kyphosis (PJK) was defined by a progression of the sagittal Cobb angle between the lower endplate of the UIV and the upper endplate of the UIV +1 greater than 10° [25, 26].

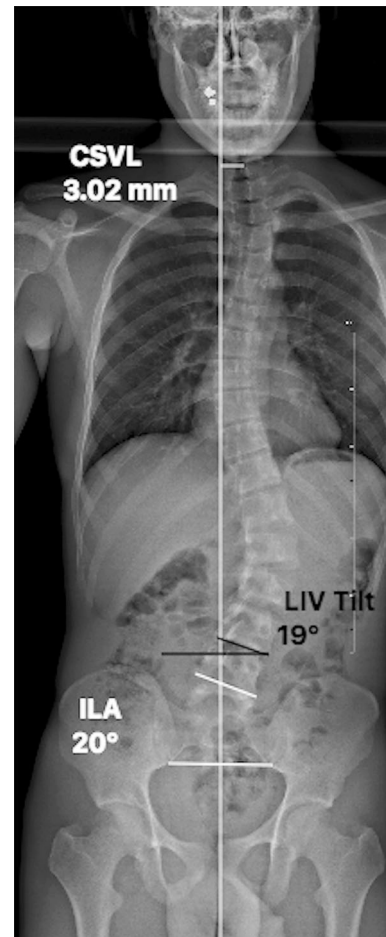


Fig. 2 Illustration of central sacral vertical line measurements (CSVL), lower instrumented vertebra tilt (LIV tilt) and ilio lumbar angle (ILA)

Statistical analysis

Statistical analysis was performed using SPSS software, version 20 (IBM, Armonk, New York, USA). Normality of the distribution was appreciated using Shapiro Wilk Test. Continuous variables were expressed as means and standard deviations. Radiological and clinical parameters were compared between groups using Student *t* tests. Chi square or Fisher tests were used as appropriate to compare categorical variables. Pearson's tests were performed to evaluate the correlation between radiological parameters and SRS-22 scores. A $p < 0.05$ was considered statistically significant.

Results

Patients

Seventy-eight patients were included (35 selective and 43 hyperselective), with a mean follow-up of 55 ± 22 months

Table 1 Demographic and surgical data (mean \pm SD)

	Selective (n 35)	Hyperselective (n 43)	<i>p</i>
Age (years old)	15.6 \pm 2	16.5 \pm 2	0.03
Sex	F 30, M 5	F 39, M 4	0.49
Risser	3.0 \pm 1	3.8 \pm 1	0.11
Number of instrumented level	7.8 \pm 3	4.3 \pm 0.6	<0.001
Follow up (months)	55 \pm 15	55 \pm 29	0.32

F female, M male, SD standard deviation

Table 2 LIV selection in regard to the location of the (a) SV and (b) LTV

	Selective (n 35)	Hyperselective (n 43)
(a)		
SV 3	0	4
SV 2	3	32
SV 1	15	7
SV	17	0
SV +1	0	0
SV +2	0	0
(b)		
LTV 3	0	0
LTV 2	0	6
LTV 1	3	30
LTV	15	7
LTV +1	11	0
LTV +2	6	0

(Table 1). As expected, the number of levels fused was significantly higher in the selective group (7.8 \pm 3 vs 4.3 \pm 0.6 in hyperselective fusions) (p < 0.01). In the latter, most of the patients (85.7%) had an UIV between T10 and T7, while five patients had an UIV located at T11 and T12. In the hyperselective group, the UIV was T10, T11 or T12 in all cases.

Most of the selective patients (26, 74.3%) were fused to L4, while nine fusions ended in L3 (25.7%). None of the patients was fused to L4 in the short-segment group. In the latter, the most frequent LIV was L3 (29, 67%), while 14 patients (33%) were only fused to L2. The selection of the LIV in regard to the location of the LTV and the stable vertebra (SV) is reported in Table 2a, b. In the selective group, the LIV was located in most of the cases (91%) on the SV or 1 level above (SV-1), while the most frequent selected LIV (74%) was SV-2 in hyperselective cases. Most of the selective fusions (91%) were extended to

the LTV or below, while 84% of the short segment fusions ended proximal to the LTV.

Operative time was significantly shorter in hyperselective fusions (140 \pm 41 vs 210 \pm 35 min, p = 0.01), but the average blood loss was not significantly different (Table 1).

Coronal radiological parameters

Preoperative parameters are reported in Table 3. The postoperative correction of the main curve was significantly greater in the selective group (63 vs 55%, p = 0.02). Similarly, the spontaneous correction of the proximal thoracic contra-curve was significantly greater after longer fusion (45 vs 23%, p = 0.02). However, satisfactory coronal balance (<20 mm) was obtained in both groups postoperatively, and no significant difference was found regarding residual ILA and LIV tilts, immediately after surgery and at latest follow-up (Table 2). The number of patients with a residual postoperative tilt >5° was 15 (34%) in the hyperselective group and 18 (51%) in the selective one without significant difference (p = 0.08).

Sagittal radiological parameters

Both groups were comparable preoperatively. The surgical procedure did not significantly modify the LL or the TK in any of the groups (Table 3). However, TK significantly increased in both groups during the follow-up period (average 10° in selective patients, and 8° in hyperselective cases). Of note, preoperatively, 62% of the patients had a LL adapted to their PI; however, 21 patients (27%) had PI-LL < -9° and 8 (10%) had PI-LL > 9°. Postoperatively, 69% of the patients had a LL adapted to PI (66 and 70% in selective and hyperselective groups, respectively). At final follow-up, only 49% of the patients had a LL adapted to their PI (28 and 59% in selective and hyperselective groups, respectively). All the patients with a PI-LL > 9°, showing a postoperative hypolordosis, were in the selective group (n = 5). In the hyperselective group, all the patients with unadapted LL (n = 18) were hyperlordotic postoperatively, with PI-LL < -9° (Table 4).

Functional outcomes

No significant difference was found between the groups regarding SRS-22 total scores at follow-up. However, the function domain score was significantly better after short-segment fusions (p = 0.03, Table 5). SRS-pain scores at latest examination were greater than 4 in both groups, without significant influence of the fusion length.

Table 3 Radiographic coronal measurements and comparisons between the two groups

	Preoperative			Postoperative			Last follow-up			Correction between preoperative and last follow-up		
	Selective (n = 35)	Hypersselective (n = 43)	p	Selective (n = 35)	Hypersselective (n = 43)	p	Selective (n = 35)	Hypersselective (n = 43)	p	Selective (n = 35)	Hypersselective (n = 43)	p
	Main curve (°)	48 ± 11	42 ± 9	0.005	14 ± 10	9 ± 6	0.009	18 ± 11	18 ± 9	0.92	30 ± 14	23 ± 11
PF	73%	67%	0.31	-	-	-	-	-	-	-	-	-
Thoracic curve (°)	25 ± 10	26 ± 8	0.45	12 ± 6	18 ± 8	<0.001	14 ± 7	20 ± 8	<0.001	11 ± 10	6 ± 7	0.02
ILA (°)	18 ± 7	18 ± 8	0.96	5 ± 5	6 ± 4	0.32	7 ± 5	8 ± 4	0.57	10 ± 7	10 ± 6	0.72
LIV tilt (°)	20 ± 7	22 ± 6	0.49	7 ± 5	5 ± 4	0.03	8 ± 6	7 ± 5	0.37	12 ± 8	14 ± 7	0.22
CSVl (mm)	13 ± 13	22 ± 11	<0.001	8 ± 14	19 ± 10	<0.001	6 ± 9	11 ± 7	0.006	7 ± 12	10 ± 10	0.17

PF preoperative flexibility, ILA ilio-lumbar angle, LIV last instrumented vertebra, CSVL central sacral vertical line

Table 4 Radiographic sagittal measurements and comparisons between the two groups

	Preoperative			Postoperative			Last follow-up			Correction between preoperative and last follow-up		
	Selective (n = 35)	Hypersselective (n = 43)	p	Selective (n = 35)	Hypersselective (n = 43)	p	Selective (n = 35)	Hypersselective (n = 43)	p	Selective (n = 35)	Hypersselective (n = 43)	p
	T4T12 kyphosis (°)	26 ± 10	27 ± 10	0.72	27 ± 17	29 ± 11	0.63	36 ± 13	35 ± 11	0.75	10 ± 10	8 ± 11
L1S1 lordosis (°)	54 ± 10	57 ± 11	0.24	51 ± 10	55 ± 11	0.18	57 ± 12	59 ± 12	0.41	3 ± 9	3 ± 9	0.77
SVA (mm)	-2 ± 24	-11 ± 25	0.12	5 ± 24	-12 ± 31	0.006	-5 ± 22	-5 ± 22	0.94	-3 ± 21	-7 ± 22	0.69
PI (°)	53 ± 10	51 ± 13	0.55	-	-	-	-	-	-	-	-	-
PI-LL	0.5 ± 10	-5.7 ± 10	0.007	-	-	-	-5.5 ± 11	-7.7 ± 11	0.40	-	-	-

SVA sagittal vertical axis, PI pelvic incidence, LL lumbar lordosis, n number of patients

Table 5 Functional outcomes comparison between the two groups (scoliosis research society score)

	Selective (n = 35)	Hyperselective (n = 43)	<i>p</i>
SRS 22 Total score	3.9 ± 0.4	4.1 ± 0.6	0.18
SRS 22 Function	3.7 ± 0.7	4.1 ± 0.7	0.03
SRS 22 Pain	4 ± 0.6	4.2 ± 0.9	0.51
SRS 22 Self image	4.1 ± 0.4	4.1 ± 0.6	0.98
SRS 22 Mental health	3.6 ± 0.8	3.9 ± 0.8	0.14
SRS 22 Satisfaction	4.4 ± 0.5	4.5 ± 0.6	0.38

Complications

The overall complication rate was 7.7%, without difference between the groups. Two early surgical site infections and two mechanical failures (proximal hook dislodgement) required revisions. In addition, asymptomatic radiological PJK were observed in 15 patients (19%) (Table 6). Eight patients (10.2%) developed an adding-on during follow-up, among which six (75%) had initially undergone hyperselective fusions and two had selective fusions. In the adding-on group, the LIV was located above the LTV in five cases (62.5%), with 1 LTV-2 and 4 LTV-1. Similarly, the LIV was located above the SV in 87.5% (1 SV-3, 3 SV-2 and 3 SV-1). Postoperative LIV tilt was significantly higher in the adding-on group ($12^\circ \pm 2$ vs $7^\circ \pm 1$, $p = 0.02$). However, the incidence of AO was not correlated to postoperative frontal balance nor residual LIV tilt ($r < 0.100$, $p > 0.05$).

Discussion

Results of the current study show that short-segment posterior fusions can be considered in Lenke 5 AIS in order to preserve motion segments, without impairing postoperative balance. No significant difference was found between groups regarding the residual LIV tilt, but more adding-on cases were observed at follow-up after hyperselective fusion, especially if the LIV was located above the SV.

Goals of surgery

While risk factors for Lenke 5 AIS progression in adulthood are better understood [1, 13, 15, 27], the selection of

fusion levels remains controversial when surgery is considered. Predictive factors of good radiological long-term outcomes include a postoperative LIV tilt $<5^\circ$, a greater reduction rate of the main structural lumbar curve and global coronal balance [27]. The aim of surgery, was, therefore, to satisfy these parameters, while preserving a maximal number of mobile segments.

Surprisingly, only 42% of the patients had postoperative LIV tilt $<5^\circ$ and 55% had good coronal balance, without any difference between groups. However, the overall functional outcomes at 5-year follow-up were in accordance with previous literature. But no significant correlations between residual LIV tilt and SRS22 score were observed ($r < 0.150$, $p > 0.05$).

In the present study, patients who developed adding-on had significantly higher postoperative LIV tilt ($12^\circ \pm 2$ vs $7^\circ \pm 1$, $p = 0.02$). Of note, all the patients with a wedged (5°) postoperative disc did not develop adding-on at last follow-up (Fig. 3). Global coronal alignment, LIV position in regard to SV and LTV did not impact adding-on occurrence.

Radiological outcomes

Sagittal and coronal alignments were both restored postoperatively in each group [28]. Cobb angle correction of the main and the proximal contra-curves were significantly better in the selective group. LIV tilt and ILA were significantly reduced postoperatively, without loss of correction at follow-up. No difference was observed between hyperselective and selective procedure in terms of LIV tilt and ILA correction and postoperatively, number of patients with a LIV tilt $>5^\circ$ was not significantly different between groups (20 in the selective group and 23 in hyperselective group). Moreover, LIV selection in regard to SV and LTV

Table 6 Clinical and radiological complications

	Selective (n = 35)	Hyperselective (n = 43)	<i>p</i>
Number of radiologic PJK	8	7	0.67
Number of adding on	3	5	0.66
Number of mechanical failure	2	0	0.11
Wound infection	0	2	0.20

PJK proximal junction kyphosis

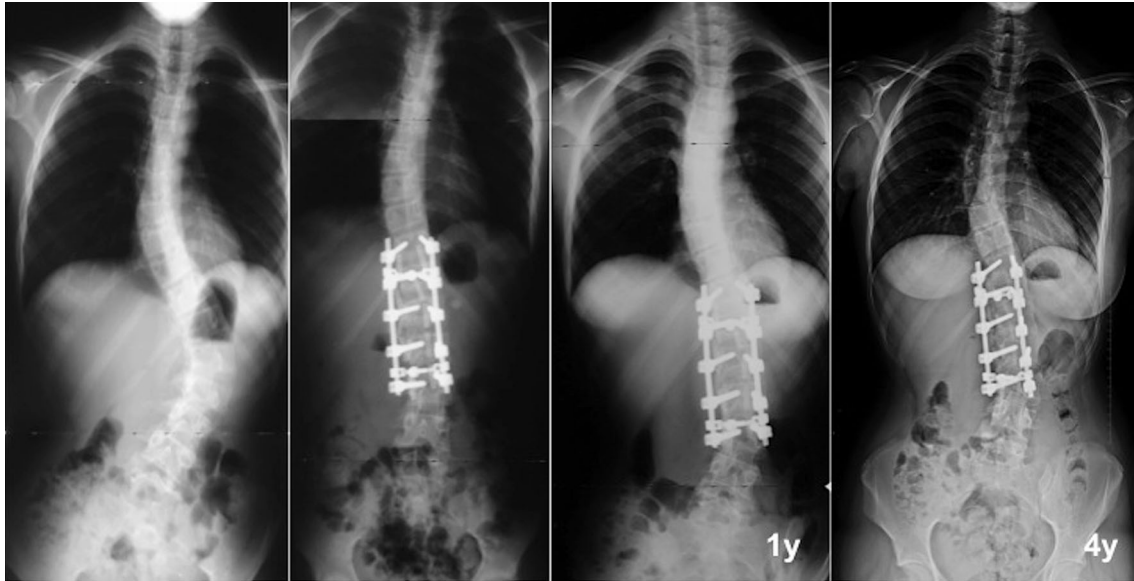


Fig. 3 Radiographic example of adding on phenomenon

did not impact the postoperative residual LIV tilt in hyperselective group. Therefore, fusion to L4 did not provide more efficient LIV tilt correction or better global coronal alignment, although more segments were fused. Nevertheless, the risk of adding-on was not different between groups. Other authors reported the importance of SV, LTV, LIV tilt analysis in the choice of LIV [29–31]. However, longer follow-up might be necessary to observe occurrence of disc degeneration below fusion [32, 33].

Moreover, neither selective nor hyperselective fusions significantly affected postoperative LL, which is in accordance with previous literature [14]. However, five patients from the selective group had lumbar hypolordosis at follow-up (although these normative values were obtained from adult patients). This lack of lordosis might be explained by a previous tendency, noticed in center 1, to overbend the lumbar rods that led to more PJK in the past. Indeed, since 2/3 of the lumbar lordosis is below L4, surgeons must pay attention not to give too much lordosis in the instrumented proximal lumbar spine, leading to a posterior shift of the fusion mass [34]. The significant increase in TK between the postoperative and the last follow-up in both groups was not reported in other study [32, 35, 36]. Larger TK might be explained by a functional adaptation above the fixed lumbar spine, explaining the 15 asymptomatic PJK (without any differences between groups).

Nevertheless, postoperative SVA in both groups remained within normative range ($-20\text{ mm} < \text{SVA} < 20\text{ mm}$) [37], consequently one can conclude that selective fusion does not alter global sagittal alignment.

Functional outcomes

In the current study, functional outcomes were very good according to the SRS-22 scores (selective group: 4.1 ± 0.4 ; hyperselective group: 4.0 ± 0.6). Despite no difference in terms of SRS-22 total scores, function was significantly better in short-segment fusions (selective 3.7 ± 0.7 vs 4.2 ± 0.9 , $p = 0.03$). Eventhough 74% of the patients were fused to L4 in the selective group, the pain level at follow-up was not significantly higher (4 ± 0.6 vs 4.2 ± 0.9 , $p = 0.51$), which is in accordance with previous literature [3, 6, 9, 37–39]. As a matter of fact, Sanchez-Raya et al. suggested that the amount of residual mobility and the LIV location had a moderate influence on long-term patients' quality of life after long fusions, in opposition to others variables such as age, preoperative functional status and time from surgery [4]. Nevertheless, literature remains sparse about LIV selection in Lenke 5 AIS curves and few studies analyzed long-term adjacent segment degeneration according to the fusion length of fusion in such patients. The only relevant study is a recent analysis from Ding et al. [9], who compared fusions to L3 and those to L4 at 3-year follow-up. No significant difference was found regarding postoperative Oswestry Disability Index (ODI), SRS-22, Short-Form 36 (SF-36) and Visual Analogical Scale (VAS) scores. However, only ten patients with Lenke 5 curves were included. While these findings suggest that extending a fusion to L4 can be considered safely, longer follow-up regarding radiological outcomes and SRS function scores remain necessary.

Limitations

This series is to date one of the largest dedicated to posterior surgery in Lenke 5 AIS with modern instrumentation, but several limitations can be mentioned. First, it is retrospective and a prospective randomized study would have provided a higher level of evidence. However, it is difficult to change a surgeon's preference regarding fusion levels selection and prospective studies are, therefore, difficult to carry on when comparing surgical techniques. Second, only 24% of the patients had more than 5-year follow-up. Nevertheless, results of this study need to be further confirmed with longer follow-up to compare occurrence of adjacent segment degeneration and clinical outcomes between groups [33]. Third, while our study analysed the location of the LIV in regard to SV and LTV, the preoperative flexibility and orientation of the discs were not assessed, and this parameter might play a key role in the development of adjacent complications when a fusion to L4 has to be considered.

Therefore, hyperselective posterior fusions can be considered in Lenke 5 AIS, preserving one or two mobile segments, with similar clinical and radiological outcomes than longer fusions. However, the selection of the LIV according to SV and LTV need to be accurately analyzed in order to avoid adding-on during follow-up.

Compliance with ethical standards

Conflict of interest All authors declared that they have no potential conflict of interest.

References

1. Pesenti S, Jouve J L, Morin C, Wolff S, Sales de Gauzy J, Chalopin A et al (2015) Evolution of adolescent idiopathic scoliosis: results of a multicenter study at 20 years' follow up. *Orthop Traumatol Surg Res* 101:619 622
2. Ilharborde B, Morel E, Mazda K, Dekutoski MB (2009) Adjacent segment disease after instrumented fusion for idiopathic scoliosis: review of current trends and controversies. *J Spinal Disord Tech*. 22(7):530 539
3. Danielsson AJ, Nachemson AL (2003) Back pain and function 23 years after fusion for adolescent idiopathic scoliosis: a case control study part II. *Spine* 28(18):E373 E383
4. Sanchez Raya J, Bago J, Pellise F, Cuxart A, Villanueva C (2012) Does the lower instrumented vertebra have an effect on lumbar mobility, subjective perception of trunk flexibility, and quality of life in patients with idiopathic scoliosis treated by spinal fusion? *J Spinal Disord Tech* 25(8):437 442
5. Paonessa KJ, Engler GL (1992) Back pain and disability after Harrington rod fusion to the lumbar spine for scoliosis. *Spine* 17(8 Suppl):S249 S253
6. Pérez Grueso FS, Fernández Baíllo N, Arauz de Robles S, García Fernández A (2000) The low lumbar spine below Cotrel Dubousset instrumentation: long term findings. *Spine* 25(18):2333 2341
7. Takayama K, Nakamura H, Matsuda H (2009) Quality of life in patients treated surgically for scoliosis: longer than sixteen year follow up. *Spine* 34(20):2179 2184
8. Helenius I, Remes V, Yrjönen T, Ylikoski M, Schlenzka D, Helenius M et al (2002) Comparison of long term functional and radiologic outcomes after Harrington instrumentation and spondylodesis in adolescent idiopathic scoliosis: a review of 78 patients. *Spine* 27(2):176 180
9. Ding R, Liang J, Qiu G, Shen J, Li Z (2014) Evaluation of quality of life in adolescent idiopathic scoliosis with different distal fusion level: a comparison of L3 versus L4. *J Spinal Disord Tech*. 27(5):E155 E161
10. Hall JE (1972) The anterior approach to spinal deformities. *Orthop Clin North Am* 3(1):81 98
11. Yu B, Wang Y, Qiu G, Zhang J, Shen J, Li Q et al (2009) Comparison of correction outcomes after anterior or posterior approach with lowest and vertebra instrumentation in adolescent idiopathic thoracolumbar/lumbar scoliosis. *Zhonghua Yi Xue Za Zhi* 89(37):2621 2625
12. Matsumoto M, Watanabe K, Hosogane N, Kawakami N, Tsuji T, Uno K et al (2013) Postoperative distal adding on and related factors in Lenke type 1A curve. *Spine* 38(9):737 744
13. Koller H, Meier O, Hitzl W (2014) Criteria for successful correction of thoracolumbar/lumbar curves in AIS patients: results of risk model calculations using target outcomes and failure analysis. *Eur Spine J* 23(12):2658 2671
14. Kim S S, Lim D J, Kim J H, Kim J W, Um K S, Ahn S H et al (2014) Determination of the distal fusion level in the management of thoracolumbar and lumbar adolescent idiopathic scoliosis using pedicle screw instrumentation. *Asian Spine J* 8(6):804
15. Li J, Hwang SW, Shi Z, Yan N, Yang C, Wang C et al (2011) Analysis of radiographic parameters relevant to the lowest instrumented vertebrae and postoperative coronal balance in Lenke 5C patients. *Spine* 36(20):1673 1678
16. Nash CL, Moe JH (1969) A study of vertebral rotation. *J Bone Jt Surg Am* 51(2):223 229
17. Bernstein RM, Hall JE (1998) Solid rod short segment anterior fusion in thoracolumbar scoliosis. *J Pediatr Orthop Part B*. 7(2):124 131
18. Faro FD, Marks MC, Pawelek J, Newton PO (2004) Evaluation of a functional position for lateral radiograph acquisition in adolescent idiopathic scoliosis. *Spine* 29(20):2284 2289
19. Lenke LG, Betz RR, Harms J, Bridwell KH, Clements DH, Lowe TG et al (2001) Adolescent idiopathic scoliosis: a new classification to determine extent of spinal arthrodesis. *J Bone Jt Surg Am* 83A(8):1169 1181
20. Berjano P, Cecchinato R, Damilano M, Morselli C, Sansone V, Lamartina C (2013) Preoperative calculation of the necessary correction in sagittal imbalance surgery: validation of three predictive methods. *Eur Spine J* 22(Suppl 6):S847 S852
21. Lamartina C, Berjano P, Petrucci M, Sinigaglia A, Casero G, Cecchinato R et al (2012) Criteria to restore the sagittal balance in deformity and degenerative spondylolisthesis. *Eur Spine J* 21(Suppl 1):S27 S31
22. Vialle R, Levassor N, Rillardon L, Templier A, Skalli W, Guigui P (2005) Radiographic analysis of the sagittal alignment and balance of the spine in asymptomatic subjects. *J Bone Jt Surg Am* 87(2):260 267
23. Lonjon G, Ilharborde B, Odent T, Moreau S, Glorion C, Mazda K (2014) Reliability and validity of the French Canadian version of the scoliosis research society 22 questionnaire in France. *Spine* 39(1):E26 E34
24. Wang Y, Bünger CE, Zhang Y, Wu C, Li H, Hansen ES (2013) Distal adding on in Lenke 1A scoliosis: how to more effectively determine the onset of distal adding on. *Spine* 38(6):490 495

25. Helgeson MD, Shah SA, Newton PO, Clements DH, Betz RR, Marks MC et al (2010) Evaluation of proximal junctional kyphosis in adolescent idiopathic scoliosis following pedicle screw, hook, or hybrid instrumentation. *Spine* 35(2):177 181
26. Kim Y C, Lenke LG, Bridwell KH, Hyun S J, You K H, Kim Y W et al (2016) Results of revision surgery for proximal junctional kyphosis following posterior segmental instrumentation: minimum 2 year post revision follow up. *Spine* 41:E1444 E1452
27. Marty Poumarat C, Scattin L, Marpeau M, Garreau de Loubresse C, Aegerter P (2007) Natural history of progressive adult scoliosis. *Spine* 32(11):1227 1234 (**discussion 1235**)
28. Jackson RP, McManus AC (1994) Radiographic analysis of sagittal plane alignment and balance in standing volunteers and patients with low back pain matched for age, sex, and size. A prospective controlled clinical study. *Spine* 19(14):1611 1618
29. Chang DG, Yang JH, Suk SI, Suh SW, Kim YH, Cho W et al (2016) Importance of distal fusion level in major thoracolumbar and lumbar adolescent idiopathic scoliosis treated by rod derotation and direct vertebral rotation following pedicle screw instrumentation. *Spine (Phila Pa 1976)*. doi:[10.1097/BRS.0000000000001998](https://doi.org/10.1097/BRS.0000000000001998)
30. Yang C, Zhao Y, Zhai X, Li J, Zhu X, Li M (2016) Coronal balance in idiopathic scoliosis: a radiological study after posterior fusion of thoracolumbar/lumbar curves (Lenke 5 or 6). *Eur Spine J*. doi:[10.1007/s00586 016 4844 2](https://doi.org/10.1007/s00586 016 4844 2)
31. Lee CS, Ha J K, Hwang CJ, Lee D H, Kim TH, Cho JH (2016) Is it enough to stop distal fusion at L3 in adolescent idiopathic scoliosis with major thoracolumbar/lumbar curves? *Eur Spine J* 25(10):3256 3264
32. Sudo H, Ito M, Kaneda K, Shono Y, Abumi K (2013) Long term outcomes of anterior dual rod instrumentation for thoracolumbar and lumbar curves in adolescent idiopathic scoliosis: a twelve to twenty three year follow up study. *J Bone Jt Surg Am*. 95(8):e49
33. Green DW, Lawhorne TW, Widmann RF, Kepler CK, Ahern C, Mintz DN et al (2011) Long term magnetic resonance imaging follow up demonstrates minimal transitional level lumbar disc degeneration after posterior spine fusion for adolescent idiopathic scoliosis. *Spine* 36(23):1948 1954
34. Xu X M, Wang F, Zhou X Y, Liu Z X, Wei X Z, Bai Y S et al (2015) Sagittal balance in adolescent idiopathic scoliosis: a radiographic study of spinopelvic compensation after selective posterior fusion of thoracolumbar/lumbar (Lenke 5C) curves. *Medicine (Baltimore)* 94(45):e1995
35. La Maida GA, Zottarelli L, Mineo GV, Misaggi B (2013) Sagittal balance in adolescent idiopathic scoliosis: radiographic study of spino pelvic compensation after surgery. *Eur Spine J* 22(S6):859 867
36. Yang X, Liu L, Song Y, Zhou C, Zhou Z, Wang L et al (2015) Pre and postoperative spinopelvic sagittal balance in adolescent patients with Lenke Type 5 idiopathic scoliosis. *Spine* 40(2):102 108
37. Potter BK, Lenke LG, Kuklo TR (2004) Prevention and management of iatrogenic flatback deformity. *J Bone Jt Surg Am* 86A(8):1793 1808
38. Green DW, Lawhorne TW, Widmann RF, Kepler CK, Ahern C, Mintz DN et al (2011) Long term magnetic resonance imaging follow up demonstrates minimal transitional level lumbar disc degeneration after posterior spine fusion for adolescent idiopathic scoliosis. *Spine* 36(23):1948 1954
39. Cochran T, Irstam L, Nachemson A (1983) Long term anatomic and functional changes in patients with adolescent idiopathic scoliosis treated by Harrington rod fusion. *Spine* 8(6):576 584