



HAL
open science

Degenerative subtalar joints complicated by medial plantar intraneural cysts

Pierre Laumonerie, Franck Lapègue, Nicolas Reina, Meagan E. Tibbo, Michel Rongièrès, Marie Faruch, Pierre Mansat

► **To cite this version:**

Pierre Laumonerie, Franck Lapègue, Nicolas Reina, Meagan E. Tibbo, Michel Rongièrès, et al.. Degenerative subtalar joints complicated by medial plantar intraneural cysts. *The Bone & Joint Journal (BJJ)*, 2018, 100-B (2), pp.183-189. 10.1302/0301-620X.100B2.BJJ-2017-0990.R1 . hal-02135719

HAL Id: hal-02135719

<https://hal.science/hal-02135719>

Submitted on 21 May 2019

HAL is a multi-disciplinary open access archive for the deposit and dissemination of scientific research documents, whether they are published or not. The documents may come from teaching and research institutions in France or abroad, or from public or private research centers.

L'archive ouverte pluridisciplinaire **HAL**, est destinée au dépôt et à la diffusion de documents scientifiques de niveau recherche, publiés ou non, émanant des établissements d'enseignement et de recherche français ou étrangers, des laboratoires publics ou privés.




Open Archive Toulouse Archive Ouverte (OATAO)

OATAO is an open access repository that collects the work of some Toulouse researchers and makes it freely available over the web where possible.

This is an author's version published in: <https://oatao.univ-toulouse.fr/23099>

Official URL : <https://doi.org/10.1302/0301-620X.100B2.BJJ-2017-0990.R1>

To cite this version :

Laumonerie, Pierre and Lapègue, Franck and Reina, Nicolas and Tibbo, Meagan E. and Rongières, Michel and Faruch, Marie and Mansat, Pierre  *Degenerative subtalar joints complicated by medial plantar intraneural cysts*. (2018) *The Bone & Joint Journal*, 100-B (2). 183-189. ISSN 2049-4394

Any correspondence concerning this service should be sent to the repository administrator:

tech-oatao@listes-diff.inp-toulouse.fr

Degenerative subtalar joints complicated by medial plantar intraneural cysts

CUTTING THE CYSTIC ARTICULAR BRANCH PREVENTS RECURRENCE

P. Laumonerie,
F. Lapègue,
N. Reina,
M. Tibbo,
M. Rongièrès,
M. Faruch,
P. Mansat

From Hôpital Pierre-Paul Riquet,
Toulouse, France

■ P. Laumonerie, MD, Orthopaedic Surgeon
■ F. Lapègue, MD, Radiologist
■ N. Reina, MD, PhD, Orthopaedic Surgeon
■ M. Rongièrès, MD, Orthopaedic Surgeon
■ M. Faruch, MD PhD, Radiologist
Institut Locomoteur, Hôpital Pierre-Paul Riquet, Allée Jean Dausset, Toulouse 31059, France.

■ M. Tibbo, MD, Orthopaedic Surgeon
Mayo Clinic, 200 First Street SW, Rochester, Minnesota 55905, USA.

■ P. Mansat, MD PhD, Orthopaedic Surgeon
Institut Locomoteur, Hôpital Pierre-Paul Riquet, Allée Jean Dausset, Toulouse, 31059, France.

Correspondence should be sent to P. Laumonerie; email: laumonerie.pierre@hotmail.fr

Aims

The pathogenesis of intraneural ganglion cysts is controversial. Recent reports in the literature described medial plantar intraneural ganglion cysts (mIGC) with articular branches to subtalar joints. The aim of the current study was to provide further support for the principles underlying the articular theory, and to explain the successes and failures of treatment of mIGCs.

Patients and Methods

Between 2006 and 2017 five patients with five mIGCs were retrospectively reviewed. There were five men with a mean age of 50.2 years (33 to 68) and a mean follow-up of 3.8 years (0.8 to 6). Case history, physical examination, imaging, and intraoperative findings were reviewed. The outcomes of interest were ultrasound and/or MRI features of mIGC, as well as the clinical outcomes.

Results

The five intraneural cysts followed the principles of the unifying articular theory. Connection to the posterior subtalar joint (pSTJ) was identified or suspected in four patients. Re-evaluation of preoperative MR imaging demonstrated a degenerative pSTJ and denervation changes in the abductor hallucis in all patients. Cyst excision with resection of the articular branch (four), cyst incision and drainage (one), and percutaneous aspiration/steroid injection (two) were performed. Removing the connection to the pSTJ prevented recurrence of mIGC, whereas medial plantar nerves remained cystic and symptomatic when resection of the communicating articular branch was not performed.

Conclusion

Our findings support a standardized treatment algorithm for mIGC in the presence of degenerative disease at the pSTJ. By understanding the pathoanatomic mechanism for every cyst, we can improve treatment that must address the articular branch to avoid the recurrence of intraneural ganglion cysts, as well as the degenerative pSTJ to avoid extraneural cyst formation or recurrence.

The pathogenesis of intraneural ganglion cysts (IGC) has been the subject of speculation for two centuries; the most well-known theory is that of *de novo* formation within the layers of the peripheral nerve.^{1,2} In 2003, Spinner et al³ proposed the unifying articular theory, which was subsequently supported by a recent systematic review which included more than 50 cases of IGC arising in the foot and ankle region.⁴ IGC follow predetermined dynamic phases of propagation:^{2,4-7} Phase I, primary ascent, in which a cyst propagates from a synovial joint up its articular branch and then proximally along the parent nerve; Phase II,

crossover, a point at the level of the main trunk where the cyst takes on a more circumferential configuration in the common epineurial sheath and can ascend further up (or descend) the common trunk; and Phase III, descend down the parent nerve. Understanding the pathogenesis has simplified treatment; identifying and resecting the connection between the joint and ganglion has eliminated recurrence of IGC after surgery.¹⁻¹²

Recent reports in the literature, including four case reports describing IGCs of the medial plantar nerve with articular branches to degenerative subtalar joints (STJ), provide further

Table I. Main characteristics of patient-reported outcomes

Characteristic	Case 1	Case 2	Case 3	Case 4	Case 5
Gender	Male	Male	Male	Male	Male
Age, yrs	33	51	46	40	70
History of repetitive ankle sprains (> 3)	Yes	No	Yes	Yes	No
Preoperative imaging: cyst					
Nerve(s) involved	Distal tibial; lateral plantar; medial plantar	Distal tibial; medial plantar	Distal tibial; medial plantar	Distal tibial; medial plantar	Medial plantar
Size (mm) in axial plane: anterior-posterior × superior-inferior	27 × 10	23 × 6	90 × 100	36 × 10	26 × 7
Communicating articular branch (from the medial plantar nerve to the posterior subtalar joint)	Yes	Yes*	Yes	Yes*	No
Arthrosis of posterior subtalar joint	Yes	Yes	Yes	Yes	Yes
Denervation changes found in the muscles:					
Abductor hallucis	Yes	Yes	Yes	Yes	Yes
Flexor digitorum brevis	Yes	No	Yes	No	No
Treatment					
Resection of the communicating articular branch	Yes	Yes	No	Yes	Yes
Percutaneous aspiration and steroid injection	Yes	No	Yes	No	No
Recurrence (at time of last follow-up)	No (0.83 yrs)	No (3 yrs)	Yes (6 yrs)	No (4 yrs)	No (5 yrs)

*not clearly identified but suspected

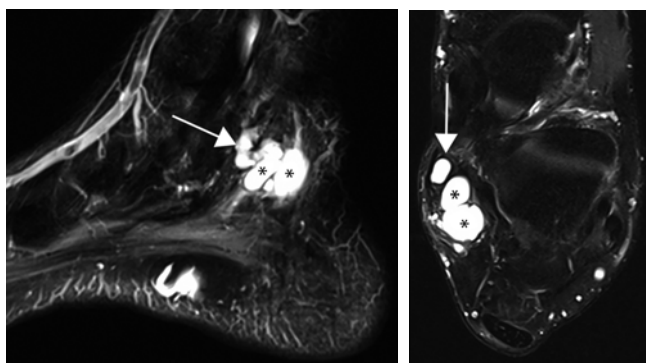


Fig. 1a

Fig. 1b

MRI images depicting the third recurrence of a left tarsal tunnel intraneural cyst. a) Sagittal cuts and b) axial T2-weighted fat-saturated images. The cyst is multiloculated, hyperintense on T2 (*); it invades the distal tibial nerve and the origin of the medial plantar nerve in the proximal tarsal tunnel. We note the articular branch that communicates with the posterior subtalar joint (arrows).

support to the phasic propagation portion of the articular theory.^{4,5-7,12-14} We speculate that failure to divide the joint-ganglion connection could be associated with a high rate of IGC recurrence.^{2-4,9-11,15}

The present study comprises an institutional series of IGCs involving the medial plantar nerve treated in various ways. The aim of the current study was to provide further support for the principles underlying the articular theory, and to explain the successes and failures of various treatment options.

Patients and Methods

Patients. Patients with IGC of the medial plantar nerve, treated between 2006 and 2017 at our institution, were ret-

respectively reviewed. Records pertaining to consultations, hospitalizations, and surgical interventions, in addition to laboratory examination data (nerve conduction studies/electromyography (NCS/EMG), ultrasound, MRI, and arthro-CT scan), were reviewed for each patient both by an orthopaedic surgeon (PL) and musculoskeletal radiologist (FL), respectively with experience in peripheral nerve surgery and imaging.

In all five patients, all men, with a medial plantar intraneural cyst were identified for the study. Their mean follow-up time was 3.8 years (0.8 to 6). The mean age at surgery was 50.2 years (33 to 68). The characteristics of the patients are reported in Table I.

Results

Case 1 . A 33-year-old athletic, previously healthy man sustained repeated left ankle sprains (Fig. 1, supplementary video 1). He developed progressively increasing numbness on the plantar skin overlying the left metatarsal heads. In addition he experienced intermittent paraesthesia in the same distribution while walking. His neurological examination revealed a positive Tinel's sign over the tarsal tunnel.¹⁶ No weakness or obvious asymmetry in foot muscle bulk was observed.

The NCS/EMG demonstrated compression of the medial plantar nerve within tarsal tunnel. CT arthrography and MRI showed an IGC within the medial and lateral plantar, and distal tibial nerves. It also revealed an articular nerve branch that communicated with the posterior subtalar joint (pSTJ), which itself was noted to be affected by degenerative disease and be impinging posteriorly. Denervation changes in the abductor hallucis and the flexor digitorum brevis were also identified.

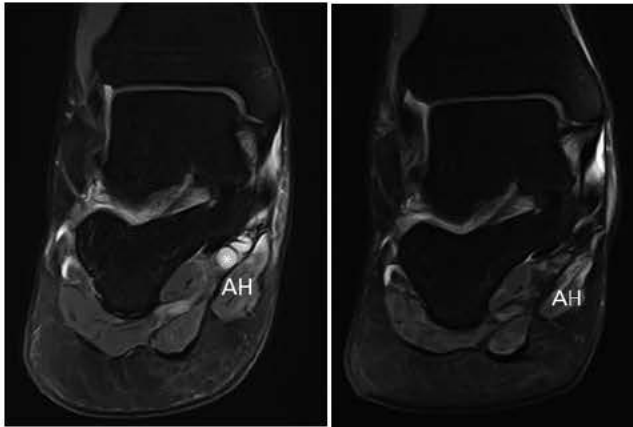


Fig. 2a

Fig. 2b

a) Coronal T2 fat-saturated MRI image demonstrates an intraneural (*) cyst of the medial plantar nerve at the level of the distal tarsal tunnel and the deep aspect of the abductor hallucis (AH). The cyst was described as hyperintense on T2. We note oedema (hyperintensity on T2) of denervation of the AH. b) Coronal T2-weighted MRI image after fat-saturated processing demonstrates an absence of recurrence of the medial plantar intraneural cyst three years after resection of the articular branch of the nerve. We note persistence of the hyperintensity (oedema) and atrophy of the AH.

The patient underwent five successive procedures for treatment of the IGC between 2011 and 2016. These included two cyst excisions by a neurosurgeon (2011) and an orthopaedic surgeon (2013) not specializing in peripheral nerve surgery, and one percutaneous aspiration and steroid injection (2012) by a musculoskeletal radiologist (FL). The articular branch was not identified by those undertaking the surgical interventions and the patient's symptoms recurred within the first six months postoperatively.

Two years after the third procedure failed, the patient presented with paraesthesia over the plantar aspect of all five metatarsal heads, most notably during the single-leg stance phase on the left foot; he required crutches in order to walk. At that time, an ultrasound-guided aspiration of the cyst was performed in an effort to reduce the symptoms. During the ultrasound examination, an articular nerve branch was identified. One week later, the patient underwent neurolysis of the distal tibial nerve and its two terminal branches (medial and lateral plantar nerves), in addition to resection of the cystic articular branch that communicated with the pSTJ. No specimen was sent for histopathological examination. At review ten months postoperatively, the patient no longer had paraesthesia, and MRI showed no evidence of IGC recurrence. The patient was able to participate fully in all sporting activities; however, the decreased sensation in area of the metatarsal heads persisted.

Case 2. A healthy 55-year-old man, with no history of ankle trauma, presented with two years of slowly progressive numbness over the plantar aspect of the metatarsal head of the right great toe which subsequently progressed to complete anaesthesia (Fig. 2). His neurological examination

revealed a Tinel's sign at the level of the tarsal tunnel without weakness of ankle or forefoot.

NCS/EMG were consistent with a medial plantar neuropathy. MRI and ultrasound revealed an IGC within the medial plantar nerve and very distal portion of tibial nerve, in addition to degeneration of the pSTJ and associated valgus flat foot deformity. Due to the low-resolution MR imaging due to 4 mm width cuts, an articular nerve branch could not be definitively identified, although coronal imaging was highly suggestive of its presence. Changes consistent with denervation of the abductor hallucis were also identified.

Surgery was performed three years after the onset of the patient's symptoms; neurolysis of the distal tibial and medial plantar nerves was performed at the tarsal tunnel, and the articular branch of the medial plantar nerve to the posterior subtalar joint was resected. The patient had experienced a full clinical recovery by three years postoperatively; repeat MRI at that time showed no evidence of recurrent IGC despite worsening degeneration of the pSTJ. **Case 3.** A 55-year-old man, with a history of repetitive ankle sprains developed progressive paraesthesia in the tibial nerve distribution while walking (Fig. 3). His neurological examination revealed a positive Tinel's sign at the level of the tarsal tunnel and no motor deficit.

The NCS/EMG demonstrated compression of the medial plantar nerve within the tarsal tunnel. MRI revealed an IGC within the distal tibial and medial plantar nerves, which communicated with degenerative pSTJ. Denervative changes of the abductor hallucis muscle and the flexor digitorum brevis were also identified.

Five years after the onset of the paraesthesia, an ultrasound-guided aspiration and steroid injection of the intraneural cyst was performed by a musculoskeletal radiologist (FL). Within the three first months after aspiration, the patient experienced complete resolution of his symptoms, but reported persistent pain at the injection site. Unfortunately, his symptoms recurred during the fifth month following the intervention and MRI demonstrated persistence of the intraneural cyst which measured 55 mm × 7 mm. Six years after percutaneous cyst aspiration, the distal tibial and medial plantar nerves were still clearly cystic; however, the patient had a marked decline in his paraesthesia, which allowed him to walk more comfortably.

Case 4. A 40-year-old athletic man, who played rugby, had experienced repetitive left ankle sprains. He presented with a palpable mass under the medial malleolus associated with a ten year history of nocturnal paraesthesia involving the plantar aspect of the metatarsal heads (Fig. 4). This progressed to numbness of the whole forefoot. He had no associated back pain, radicular symptoms, or weakness in the lower limb.

MRI and ultrasound demonstrated a distal tibial and medial plantar IGC that communicated with a degenerative pSTJ. The proximity and extent of cyst infiltration into the plantar nerve and STJ did not allow clear identification of a

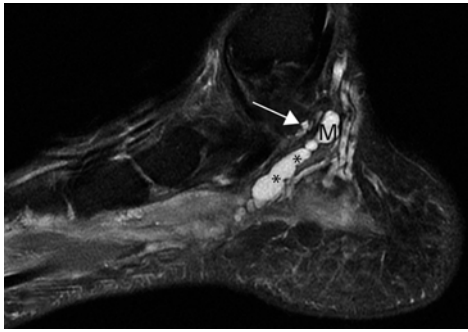


Fig. 3a

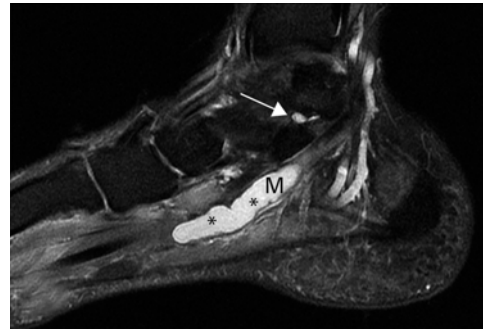


Fig. 3b

Sagittal T2 fat-saturated MR images are depicted. The intraneural medial plantar (M) cyst (*) is characterized by hyperintensity on T2 fat-saturated image and localized to the level of the distal tarsal tunnel. Sagittal MRI cuts demonstrate cystic infiltration of the articular branch of the medial plantar nerve (arrows) at the level of the subtalar articulation.

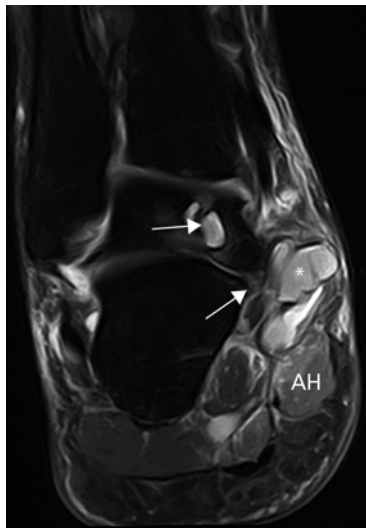


Fig. 4

Transverse T2 fat-saturated MRI image demonstrating an arthrosis of the posterior subtalar joint with talar pincement (solid arrow) and nodular remodeling (hollow arrow) of the talus are present. We also note the T2 hyperintensity of the medial plantar intraneural cyst (*) at the level of the tarsal tunnel and the denervation changes in the abductor hallucis (AH).

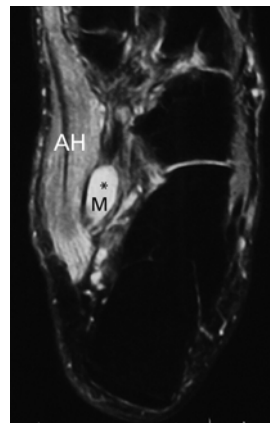


Fig. 5a

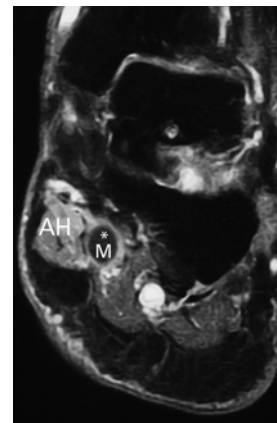


Fig. 5b

a) Transverse T2 and b) coronal T1 post-gadolinium fat-saturated MR images demonstrating a medial plantar (M) intraneural cyst at the level of the distal tarsal tunnel. The cyst was described as hyperintense on T2 (a) and hypointense on T1 (b) without enhancement after gadolinium injection. Denervation changes are notable in the medial plantar nerve distribution with T2 hyperintensity (a) and post-contrast enhancement (b) of the abductor hallucis (AH).

communicating articular branch on the available low resolution MRI. However, additional coronal imaging was highly suspicious for an articular branch between the medial plantar nerve and the STJ. Denervative changes in the abductor hallucis muscle were also identified.

Decompression of the enlarged distal tibial and medial plantar nerves and resection of the articular branch of the medial plantar nerve to the pSTJ were performed. Four years after surgery, the patient had a complete resolution of his forefoot symptoms. no additional imaging was performed after surgery.

Case 5. This 68-year-old male presented with a five-year history of paraesthesia in the territory of the left medial plantar nerve (Fig. 5). Neurological examination revealed a

Tinel's sign at the tarsal tunnel level without weakness of the ankle or forefoot. Despite treatment with antiepileptic medication for two years, the neuropathy followed an unusually aggressive clinical course leading to anaesthesia of the plantar skin overlying the two first metatarsal heads and pain over the plantar surface of the forefoot severe enough to cause sleep disturbance.

Conventional MRI and ultrasound demonstrated an IGC within the medial plantar nerve associated with a degenerative posterior STJ; amyotrophy of the abductor hallucis was also identified. There was no description of a cystic articular branch on low-resolution ankle MR imaging.

At surgery, neurolysis of the distal tibial and medial plantar nerves and resection of the articular branch of the medial plantar nerve to the pSTJ were performed. At most recent follow-up (five years after surgery), the patient had no foot pain or paraesthesia. An ultrasound obtained five years after surgery confirmed resolution of the cyst.

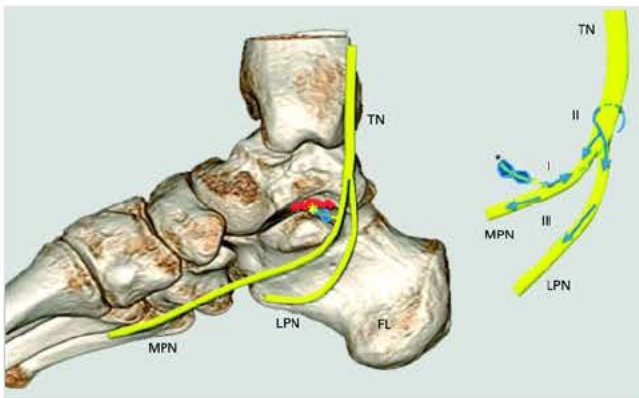


Fig. 6

Artistic rendering of the anatomy of the tarsal tunnel (degenerative (*) subtalar joint in red) and the underlying mechanism of the medial plantar intraneural ganglion cyst according to the unifying synovial theory supported by Spinner et al.² TN, tibial nerve; MPN, medial plantar nerve; LPN, lateral plantar nerve.

Discussion

The unifying articular theory applies to medial plantar intraneural ganglion cysts complicating degenerative pSTJ.² Resection of the articular branch of the medial plantar nerve appears to prevent recurrence of IGCs (Fig. 2).

A recent meta-analysis revealed over 35 cases of IGC affecting the distal tibial nerve ($n = 20$), the tibial and medial plantar nerves ($n = 2$), and the isolated medial ($n = 12$) or lateral ($n = 1$) plantar nerves.⁴ When presented collectively, all were consistent with chronic tarsal tunnel syndrome, as demonstrated by the similarities in symptoms and relative consistency of anatomy.¹⁷⁻¹⁹ In all cases, neuropathy of the medial plantar nerve was prominent, with related denervation changes including atrophy of abductor hallucis (Figs 2, 4, and 5). This was consistent with the MR images shown in the case report by Isaacs et al.⁶ The five cases we have reported shared a unique mechanism of formation. Therefore, it seems reasonable to invoke one unifying synovial theory to explain all cases as suggested in the literature.^{2,4,5,8,12,13} Spinner et al.,^{3,5} Desy et al.,⁴ and Isaacs et al.⁶ demonstrated that IGC of the medial plantar nerve follow propagation principles described in the dynamic phase of the unifying theory (Fig. 6).

Primary ascent (Fig. 6, phase I) occurs from a synovial joint up its articular branch and then proximally along the medial plantar nerve (parent nerve). Crossover (Fig. 6, phase II) occurs at the level of the main tibial trunk within the tarsal tunnel; at the crossover point, cysts take on a more circumferential configuration in the common epineurial sheath. Cysts can then ascend further up the distal tibial nerve or descend (Fig. 6, phase III) down the lateral and medial plantar nerves.^{2,5,6,8} The crossover phenomenon could explain the finding of multiple interconnected cysts of the distal posterior tibial nerve and its branches (Case 1). The small sample size of the present series did not allow us

to confirm the dynamic propagation of the cyst affecting the medial plantar nerve according to the unifying synovial theory. We speculate that each case is also a snapshot of the dynamic nature of IGC propagation, and may explain the variety of clinical presentations reported in the literature.^{4,5,6,8,10,14,19}

Despite the fact that histopathological findings help to explain historical and radiological features, treatment derived from the principles of the universal unifying theory was not prospectively applied to two patients (Cases 1 and 3). The joint connection, which we believe existed,^{4,6,14,20} was identified or suspected in four patients (Cases 1 to 4), and not identified on preoperative imaging in one patient (Case 5) (Table I).

The use of conventional MRI with a slice thickness of 4 mm limited our ability to identify this connection to the STJ. We suggest that failure to identify with certainty a communicating branch between the medial plantar nerve and the joint, could also be attributed to the nerve's small size as well as its anatomical proximity, at the level of the tarsal tunnel, to both the medial plantar nerve and the STJ itself. It has been proposed that a new MR pulse sequence, known as CUBE, or 3D fast spin-echo extended echo-train acquisition, is superior to the conventional 2D fast spin-echo MRI with respect to identifying the communicating articular nerve branch of IGC.²¹ For the two remaining patients (Cases 1 and 3) with a clearly identified cystic branch by MRI (Figs 1 and 3), the IGCs were found to originate systematically from the articular branch to the posterior STJ. This was concordant with other reports in the literature.^{4,6,9,14,15,17,19,20,22,23} We agree that the resolution of ultrasound imaging is sufficient to identify a deep and small structure such as the articular branch within the tarsal tunnel and is accordingly the technique of choice to map and guide percutaneous aspiration of IGC (supplementary video 1).²⁴ We believe that clear identification of a communicating articular branch with ultrasound would allow for percutaneous, image-guided resection of the branch, as an alternative to surgical intervention.²⁵ Additional studies exploring the feasibility of this alternative procedure are required.

Despite the fact that surgeons specializing in peripheral nerve procedures are aware of its existence, identifying the articular branch of the medial plantar nerve remains a challenge.⁶ We speculate that the small size of the articular branch, and the distal propagation of the cyst along the lateral and medial plantar nerves, may mislead surgeons intraoperatively.^{4,16} Our case series illustrates the importance of removing the articular nerve branch to prevent the recurrence of IGC of the medial plantar nerve.^{1,3,4,6,8,9,11,19,22} According to Desy et al.,⁴ failure to resect the articular branch or address the articular pathology was associated with a statically significant risk of cyst recurrence. Limited decompression of the cyst affords an immediate neural decompression but is not sufficient for definitive treatment.^{4,11} Percutaneous

aspiration alone allows for reduction in tarsal tunnel symptoms, but this should not be considered adequate alone, given the high rate of cyst recurrence related to this treatment.⁴ Furthermore, iterative reintervention exposes patients to increased risk of scar formation and should be avoided. When the articular branch cannot be identified, we recommend complete neurolysis of the distal tibial and medial plantar nerves to permit disconnection from the subtalar articulation. The articular branches of the medial plantar nerve supply both tarsal and metatarsal articulations.^{20,23} It is therefore possible that intraneural medial plantar cysts could arise from a more distal joint, although none have been reported in the recent literature.⁴

Our series supports the theory that medial plantar IGC originate from the degenerative posterior STJ. Posterior ankle impingement and repetitive trauma could cause joint degeneration and capsular defects that permit extravasation of cyst fluid.^{11,14} Degenerative arthrosis of the STJ was either pauci or asymptomatic in all the patients in our series and as such, no medical or surgical interventions were pursued. We believe that the articular branch should be addressed, ideally simultaneously to treatment of the joint lesion. For recurrent extraneural cysts, Kawakatsu et al¹⁴ have recommend a free periosteal graft as the ultimate surgical solution.


We recognize that the limitations include the retrospective nature of our investigation, with a risk of data loss and bias. Due to the small number of patients with limited follow-up, specific recommendations for treatment cannot be established. The imaging available for review offered lower than ideal spatial resolution with 4 mm thick MRI cuts being insufficient to allow clear identification of the articular branch of the medial plantar nerve. However, with knowledge of the relevant anatomy, nature of the presentation and pertinent findings, allowed the cyst propagation patterns to be determined.^{26,27} We recognize that no postoperative MRI was performed in two patients. Ultrasound examination allowed us to exclude recurrence of the IGC in Case 5. Case 4 experienced complete clinical recovery; therefore, postoperative MRI was not indicated.

Review of our five patients with IGC offers support to the concept of a standard surgical treatment algorithm for IGC of the medial plantar nerve. By understanding the pathoanatomical mechanism for every IGC, we can improve treatment which must address both the articular branch and the degenerative STJ to avoid recurrence.

Take home message:

- The unifying articular theory applies to medial plantar intraneural ganglion cysts
- Resection of the articular branch of the medial plantar nerve appears to prevent recurrence of intraneural cyst
- Medial plantar intraneural ganglion cyst originate from the degenerative posterior Subtalar joint

Supplementary material

 A video showing an ultrasound-guided aspiration of the medial plantar intraneural cyst is available alongside the online version of this article at www.bjj.boneand-joint.org.uk

Twitter

- Follow P. Laumonerie @
- Follow F. Lapègue @
- Follow N. Reina @
- Follow M. Tibbo @
- Follow M. Rongièrès @
- Follow M. Faruch @
- Follow P. Mansat @

References

1. Spinner RJ, Vincent J-F, Wolanskyj AP, Scheithauer BW. Intraneural ganglion cyst: a 200-year-old mystery solved. *Clin Anat* 2008;21:611–618.
2. Spinner RJ, Scheithauer BW, Amrami KK. The unifying articular (synovial) origin of intraneural ganglia: evolution-revelation-revolution. *Neurosurgery* 2009;65(Suppl):A115–A124.
3. Spinner RJ, Atkinson JL, Tiel RL. Peroneal intraneural ganglia: the importance of the articular branch. A unifying theory. *J Neurosurg* 2003;99:330–343.
4. Desy NM, Wang H, Elshiekh MAI, et al. Intraneural ganglion cysts: a systematic review and reinterpretation of the world's literature. *J Neurosurg* 2016;125:615–630.
5. Spinner RJ, Amrami KK, Wolanskyj AP, et al. Dynamic phases of peroneal and tibial intraneural ganglia formation: a new dimension added to the unifying articular theory. *J Neurosurg* 2007;107:296–307.
6. Isaacs AM, Midha R, Desy NM, Amrami KK, Spinner RJ. The mechanism underlying combined medial and lateral plantar and tibial intraneural ganglia in the tarsal tunnel. *Acta Neurochir (Wien)* 2016;158:2225–2229.
7. Prasad N, Amrami KK, Yangi K, Spinner RJ. Occult isolated articular branch cyst of the lateral plantar nerve. *J Foot Ankle Surg* 2017;56:78–81.
8. Spinner RJ, Carmichael SW, Wang H, et al. Patterns of intraneural ganglion cyst descent. *Clin Anat* 2008;21:233–245.
9. Desy NM, Lipinski LJ, Tanaka S, et al. Recurrent intraneural ganglion cysts: pathoanatomic patterns and treatment implications. *Clin Anat* 2015;28:1058–1069.
10. Wilson TJ, Hébert-Blouin M-N, Murthy NS, et al. The nearly invisible intraneural cyst: a new and emerging part of the spectrum. *Neurosurg Focus* 2017;42:E10.
11. Zuckerman SL, Spinner RJ. Understanding the dynamics and compartments in joint-related ganglion cysts. *J Foot Ankle Surg* 2017;56:415–416.
12. Choi J-S, Kim K-H, Kwak J-H, Park H-G, Lee S-W. Intraneural ganglion cyst in foot and ankle. *J Korean Foot Ankle Soc* 2011;15:223–231.
13. Davis GA, Cox IH. Tibial intraneural ganglia at the ankle and knee: incorporating the unified (articular) theory in adults and children. *J Neurosurg* 2011;114:236–239.
14. Kawakatsu M, Ishiko T, Sumiya M. Tarsal tunnel syndrome due to three different types of ganglion during a 12-year period: a case report. *J Foot Ankle Surg* 2017;56:379–384.
15. Wilson TJ, Hébert-Blouin MN, Murthy NS, Amrami KK, Spinner RJ. Recognition of peroneal intraneural ganglia in an historical cohort with “negative” MRIs. *Acta Neurochir (Wien)* 2017;159:925–930.
16. Fujita I, Matsumoto K, Minami T, et al. Tarsal tunnel syndrome caused by epineural ganglion of the posterior tibial nerve: report of 2 cases and review of the literature. *J Foot Ankle Surg* 2004;43:185–190.
17. Champetier J. Innervation of the tibiotarsal joint (articulatio talocruralis). *Acta Anat (Basel)* 1970;77:398–421. (in French).
18. Hirose CB, Coughlin MJ, Stevens FR. Arthritis of the Foot and Ankle In: Coughlin MJ, Saltzman CL, Anderson RB, eds. *Mann's Surgery of the Foot and Ankle*. Eighth ed. Philadelphia, PA: Mosby Inc. 2007:867–1007.
19. Spinner RJ, Dellon AL, Rosson GD, Anderson SR, Amrami KK. Tibial intraneural ganglia in the tarsal tunnel: is there a joint connection? *J Foot Ankle Surg* 2007;46:27–31.

20. **Sarrafian SK, Kelikian AS.** Nerves. In: Kelikian AS, ed. *Sarrafian's Anatomy of the Foot and Ankle: Descriptive, Topographic, Functional*. Third ed. Philadelphia: Wolters Kluwer Health/Lippincott Williams & Wilkins, 2011:423–426.
21. **Shahid KR, Spinner RJ, Skinner JA, et al.** Evaluation of intraneural ganglion cysts using three-dimensional fast spin echo-cube. *J Magn Reson Imaging* 2010;32:714–718.
22. **Spinner RJ.** Re: Tarsal tunnel syndrome caused by epineural ganglion of the posterior tibial nerve. *J Foot Ankle Surg* 2005;44:74–75.
23. **Mentzel M, Fleischmann W, Bauer G, Kinzl L.** Ankle joint denervation. Part 1: Anatomy—the sensory innervation of the ankle joint. *J Foot Ankle Surg* 2007;46:27–31.
24. **Samarawickrama D, Therimadasamy AK, Chan YC, Vijayan J, Wilder-Smith EP.** Nerve ultrasound in electrophysiologically verified tarsal tunnel syndrome. *Muscle Nerve* 2016;53:906–912.
25. **Lapègue F, André A, Meyrignac O, et al.** US-guided percutaneous release of the trigger finger by using a 21-gauge needle: a prospective study of 60 Cases. *Radiology* 2016;280:493–499.
26. **Kothari A, Bhuva S, Stebbins J, Zavatsky AB, Theologis T.** An investigation into the aetiology of flexible flat feet: the role of subtalar joint morphology. *Bone Joint J* 2016;98-B:564–568.
27. **Krause F, Barandun A, Klammer G, et al.** Ankle joint pressure changes in high tibial and distal femoral osteotomies: a cadaver study. *Bone Joint J* 2017;99-B:59–65.

Author contributions:

P. Laumonerie: Conception and design of the study, Acquiring, analyzing, and interpreting the data, Critically revising the manuscript, Reviewing the submitted version of the manuscript, Statistical analysis, Supervising the study.

F. Lapègue: Acquiring, analyzing, and interpreting the data, Critically revising the manuscript, Reviewing the submitted version of the manuscript.

N. Reina: Analyzing and interpreting the data, Critically revising the manuscript, Reviewing the submitted version of the manuscript.

M. Rongières: Analyzing and interpreting the data, Critically revising the manuscript, Reviewing the submitted version of the manuscript.

M. Faruch: Analyzing and interpreting the data, Critically revising the manuscript, Reviewing the submitted version of the manuscript.

M. Tibbo: Analyzing and interpreting the data, Critically revising the manuscript, Reviewing the submitted version of the manuscript.

P. Mansat: Conception and design of the study, Analyzing and interpreting the data, Critically revising the manuscript, Reviewing the submitted version of the manuscript, Approving the final version of the manuscript on behalf of all authors, Providing administrative, technical, and material support.

Funding statement:

No benefits in any form have been received or will be received from a commercial party related directly or indirectly to the subject of this article..