



HAL
open science

Correction of hypokyphosis in thoracic adolescent idiopathic scoliosis using sublaminar bands: a 3D multicenter study

Brice Ilharreborde, Sébastien Pesenti, Emmanuelle Ferrero, Franck Accadbled, Jean-Luc Jouve, Jérôme Sales de Gauzy, Keyvan Mazda

► To cite this version:

Brice Ilharreborde, Sébastien Pesenti, Emmanuelle Ferrero, Franck Accadbled, Jean-Luc Jouve, et al.. Correction of hypokyphosis in thoracic adolescent idiopathic scoliosis using sublaminar bands: a 3D multicenter study. *European Spine Journal*, 2018, 27 (2), pp.350-357. 10.1007/s00586-017-5166-8. hal-02135714

HAL Id: hal-02135714

<https://hal.science/hal-02135714v1>

Submitted on 21 May 2019

HAL is a multi-disciplinary open access archive for the deposit and dissemination of scientific research documents, whether they are published or not. The documents may come from teaching and research institutions in France or abroad, or from public or private research centers.

L'archive ouverte pluridisciplinaire **HAL**, est destinée au dépôt et à la diffusion de documents scientifiques de niveau recherche, publiés ou non, émanant des établissements d'enseignement et de recherche français ou étrangers, des laboratoires publics ou privés.



Open Archive Toulouse Archive Ouverte (OATAO)

OATAO is an open access repository that collects the work of some Toulouse researchers and makes it freely available over the web where possible.

This is an author's version published in: <https://oatao.univ-toulouse.fr/23121>

Official URL : <https://doi.org/10.1007/s00586-017-5166-8>

To cite this version :

Ilharreborde, Brice and Pesenti, Sébastien and Ferrero, Emmanuelle and Accadbled, Franck and Jouve, Jean-Luc and Sales de Gauzy, Jérôme and Mazda, Keyvan *Correction of hypokyphosis in thoracic adolescent idiopathic scoliosis using sublaminar bands: a 3D multicenter study.* (2018) *European Spine Journal*, 27 (2). 350-357. ISSN 0940-6719

Any correspondence concerning this service should be sent to the repository administrator:

tech-oatao@listes-diff.inp-toulouse.fr

Correction of hypokyphosis in thoracic adolescent idiopathic scoliosis using sublaminar bands: a 3D multicenter study

Brice Ilharreborde¹ · Sébastien Pesenti² · Emmanuelle Ferrero¹ · Franck Accadbled³ · Jean-Luc Jouve² · Jérôme Sales De Gauzy³ · Keyvan Mazda¹

Abstract

Introduction The comparison of implants and correction methods remain controversial in AIS. Excellent frontal and axial correction rates have been reported with all-screw constructs, but at the expense of sagittal alignment, which has a tendency to flatten postoperatively. Posteromedial translation using hybrid constructs seems to preserve and improve thoracic kyphosis (TK), but no series exist to date with a significant number of hypokyphotic patients. In addition, the measures of TK in 2D are often wrong in severe AIS due to axial rotation. The goals of this study were therefore to analyze the 3D radiological outcomes of a group of hypokyphotic AIS patients operated with sublaminar bands.

Methods 35 consecutive AIS hypokyphotic patients (T4T12 <15°) operated in three centers were included, with a minimum 2-year follow-up. The surgical technique was similar in all centers, associating lumbar pedicle screws and thoracic sublaminar bands. Posteromedial translation was the main correction technique, and no patient underwent prior anterior release. 3D spinal reconstructions were

performed preoperatively, postoperatively and at the latest follow-up by an independent observer using SterEOS (EOS imaging, Paris, France), and 2D and 3D measurements were compared. In addition, a new 3D parameter [sagittal shift of the apical vertebra (SSAV)], reflecting the translation of the apical vertebra of the main curve in the patient sagittal plane, was described and reported.

Results The age of the cohort was 16 years and the number of sublaminar bands used for correction averaged 6 (± 1.5). T1T12 and T4T12 sagittal Cobb angles appeared to be overestimated on 2D postoperatively (3°, $p = 0.002$ and 4°, $p < 0.001$, respectively). Hence, only 3D measurements were kept for the quantitative analysis of the postoperative correction. T4T12 TK significantly increased after surgery (average $8^\circ \pm 7^\circ$, $p < 0.001$), but 11 patients (31.4%) remained hypokyphotic. Seven out of the eight patients (87.5%) who presented a thoracic lordosis (i.e., T4T12 <0°) preoperatively were corrected after surgery (mean gain $16^\circ \pm 4^\circ$). A posterior shift (positive SSAV) of the apical vertebra was reported in 24 patients (68.6%). In this subgroup, the mean SSAV was +2 cm (± 1). Good correlation was found between the SSAV and the postoperative change in 3D T4T12 kyphosis ($r = 0.62$).

Conclusion Measures in 2D tend to overestimate sagittal alignment and are not sufficient to evaluate postoperative correction. SSAV is a new 3D parameter reflecting the TK change that needs to be further investigated and used in the future. This series confirms that sublaminar bands should be considered in hypokyphotic patients, since thoracic sagittal alignment was restored in 68.6% of the cases.

✉ Brice Ilharreborde
i brice@hotmail.com

¹ Pediatric Orthopaedic Department, CHU Robert Debré, AP HP, Paris Diderot University, Paris, France

² Pediatric Orthopaedic Department, Timone Children Hospital, Aix Marseille University, Marseille, France

³ Pediatric Orthopaedic Department, Children Hospital, CHU Toulouse, France

Keywords Adolescent idiopathic scoliosis · Hypokyphosis · Sagittal alignment · Stereoradiography · 3D analysis

Introduction

The goal of adolescent idiopathic scoliosis (AIS) surgery is to achieve a 3D correction of the deformity and prevent curve progression of the unfused spine, while improving the overall cosmetic aspect of the trunk and preserving enough mobility for daily activities [1]. Correction has been reported with numerous systems, but the most popular technique currently relies on pedicle screws, with a recent emphasis on the axial correction of the deformity using direct vertebral derotation techniques [2]. However, all-screw constructs have been associated with higher hospital charges (27.6% annually in the USA) and with a tendency to flatten the thoracic spine, not observed with hybrid constructs in matched patients [3–6]. Maintaining or restoring thoracic sagittal balance is essential not only to avoid future junctional degeneration (proximal or distal), but also theoretically to improve pulmonary function, even if relevant clinical evidence is still lacking [7–9].

Analysis of the current existing literature regarding the consequences of AIS surgery on thoracic sagittal alignment is difficult due to multiple biases. First, most of the series include different Lenke-type curves, while the sagittal flattening of the spine mostly occur in Lenke 1 and Lenke 2 curves (single structural thoracic and double structural thoracic, respectively). Second, the analysis of postoperative results, even in this subgroup of thoracic structural curves (Lenke 1 and 2), is also biased by the distribution of the three Lenke's sagittal modifiers (–, N or +). As a matter of fact, hyperkyphotic patients (sagittal modifier +) tend to increase the mean postoperative thoracic kyphosis of the series, therefore leading to an overestimation of the surgical gain, while the number of the most challenging patients (sagittal modifier –, i.e., sagittal T4T12 Cobb <10°) is very often limited or not even reported. Last, radiological outcomes are usually assessed in 2D, and the value of such measurements in severe AIS is questionable due to apical rotation [10].

While some authors advocate the use of larger diameter rods, higher screw density on the concave side or multiple facetectomies to optimize the correction of thoracic sagittal misalignment, several studies have recently emphasized the efficacy and safety of the posteromedial translation technique using sublaminar bands, even in stiff curves, with no need for previous thoracoscopic anterior release [11–14]. Since the EOS low-dose system is now accessible in routine clinical use, the goal of this multicenter study was to analyze the 3D radiological outcomes of a consecutive subgroup of hypokyphotic thoracic AIS patients, operated with sublaminar bands.

Materials and methods

Patients

Following institutional review board approval, a consecutive series of 43 hypokyphotic patients, operated for progressive Lenke 1 or 2 AIS in three university hospitals between June 2011 and May 2014 were retrospectively analyzed. Thoracic hypokyphosis was defined by a preoperative sagittal T4T12 Cobb angle <15° in both 2D and 3D measurements. A minimum 2-year follow-up was required. All patients were evaluated preoperatively in the early postoperative period (within 1 month) and at the latest follow-up. None of the patients had prior spinal surgery.

Surgical procedure

Fusion levels, implants number and localization at thoracic levels were selected according to the same criteria in all three centers. The only difference between departments regarding the operative strategy was the type of rod material used for correction (CoCr in center 1 and Ti in centers 2 and 3). All patients underwent posterior spinal fusion using hybrid constructs, combining lumbar pedicle screws [ISS (Implanet, Bordeaux, France) or Legacy (Medtronic, Minneapolis, USA)], concave thoracic sublaminar bands [Jazz (Implanet, Bordeaux, France)] and proximal hooks with 5.5 mm diameter rods (Fig. 1). No patient underwent prior anterior release before posterior fusion and no posterior osteotomy was performed during correction. The same perioperative blood saving strategy was used in all centers, associating intraoperative cell saver and tranexamic acid. Posteromedial translation was the main technique used for thoracic correction, using the progressive tension transmitted by the polyester bands to the laminae to bring the thoracic spine to the rods, manually precontoured in the sagittal plane. Spinal cord monitoring was systematically recorded.

Radiological measurements

All patients underwent low-dose stereoradiographs using the EOS system (EOS imaging, Paris, France) preoperatively, postoperatively (within 1 month), and at the latest follow-up, as previously described [15]. Spinal measurements were first performed in 2D (Kodak Carestream, Rochester, NY, USA) by an experienced independent spinal surgeon, and then 3D reconstructions were performed using SterEOS software (EOS imaging, Paris, France) by an independent Imaging reconstruction service (EOS 3DServices, Montreal, Canada). Inter- and intraobserver reliabilities of both

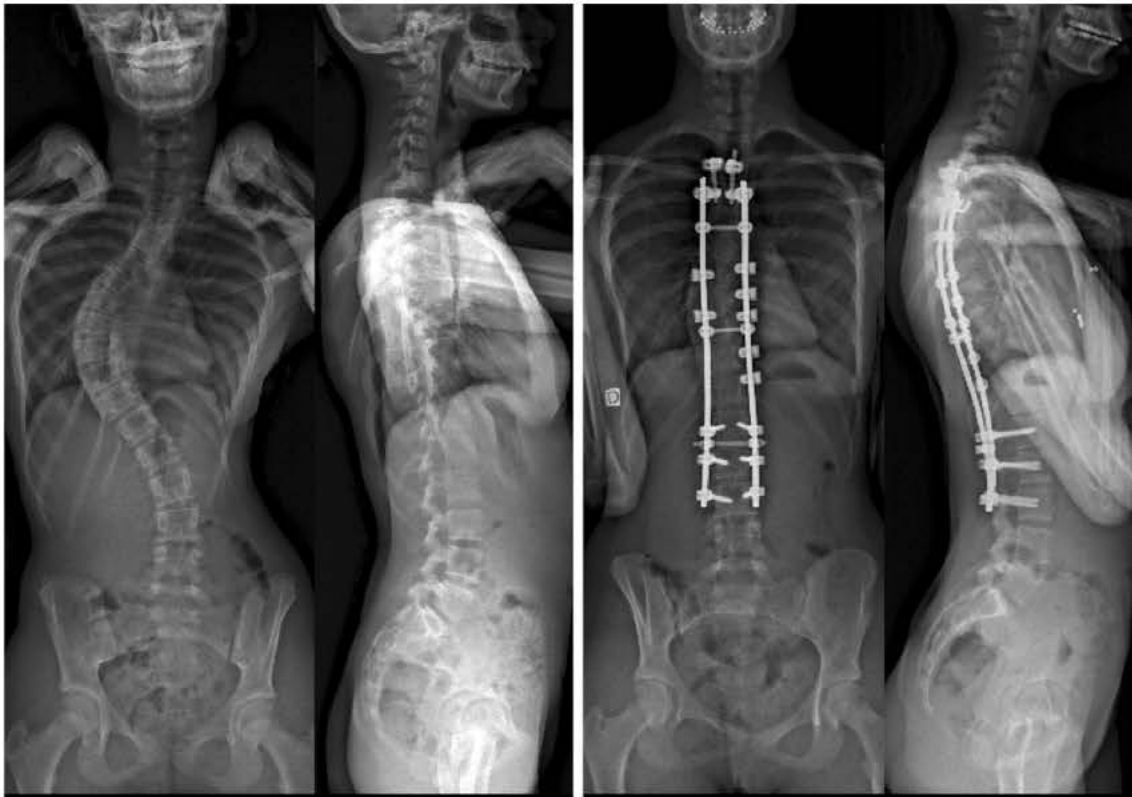


Fig. 1 Preoperative and postoperative low dose radiographs of a Lenke 1 AIS patient treated by T3L3 posterior fusion using a hybrid construct with seven sublaminar bands

methods have been previously reported [15, 16]. The following coronal radiographic parameters were recorded: Cobb angles of the main curve and contra-curves and T1 tilt (measured between the horizontal reference line and the upper endplate of T1). Sagittal parameters included T1T12 and T4T12 thoracic kyphosis (TK), L1S1 lumbar lordosis (LL), and pelvic parameters. 2D and 3D parameters were compared, and only hypokyphotic patients (i.e., sagittal T4T12 Cobb $<15^\circ$) on preoperative 3D reconstructions were kept for analysis.

In addition, a new parameter [sagittal shift of the apical vertebra (SSAV)] was calculated from 3D reconstructions to illustrate the posterior translation of the thoracic spine. The SSAV corresponded to the projection in the axial plane (3D top view in patient's reference) of the sagittal translation of the anatomic center of the apical vertebra of the main thoracic curve, in reference to the central hip vertical axis (CHVA) (Fig. 2). A positive value was given in case of posterior translation of the apex, while a negative value produced an anterior shift of the apical vertebra.

Statistical analysis

Paired-samples Student's *t* tests were used to analyze differences between 2D and 3D radiological measurements

and to evaluate surgical outcomes. Pearson correlation test was used to compare the 3D postoperative gain in T4T12 kyphosis and the SSAV. All statistical tests were two-tailed, and a *p* value <0.05 was considered significant. All statistical analyses were conducted using SPSS version 12.0 (SPSS Inc, Chicago, IL, USA).

Results

Demographic and operative data

Among the 43 consecutive Lenke 1 and 2 hypokyphotic AIS patients identified on 2D measurements, 8 were excluded because the personalized 3D reconstructions were not feasible. The reason was the existence of a lumbosacral transitional anomaly (lumbarized S1 or sacralized L5) altering vertebrae numbering on SterEOS software. The mean age of the 35 patients, therefore, kept for analysis was 16 years (± 2). There were 11 boys and 24 girls, with a mean follow-up of 34 months (± 8). Lenke 1 curves were the most frequent (30 cases, 85%), while Lenke 2 curves were identified in five patients (15%). The number of fused vertebrae averaged 12.5 (± 1), and all fusions extended to L1 or below. The upper instrumented level (UIV) was T1

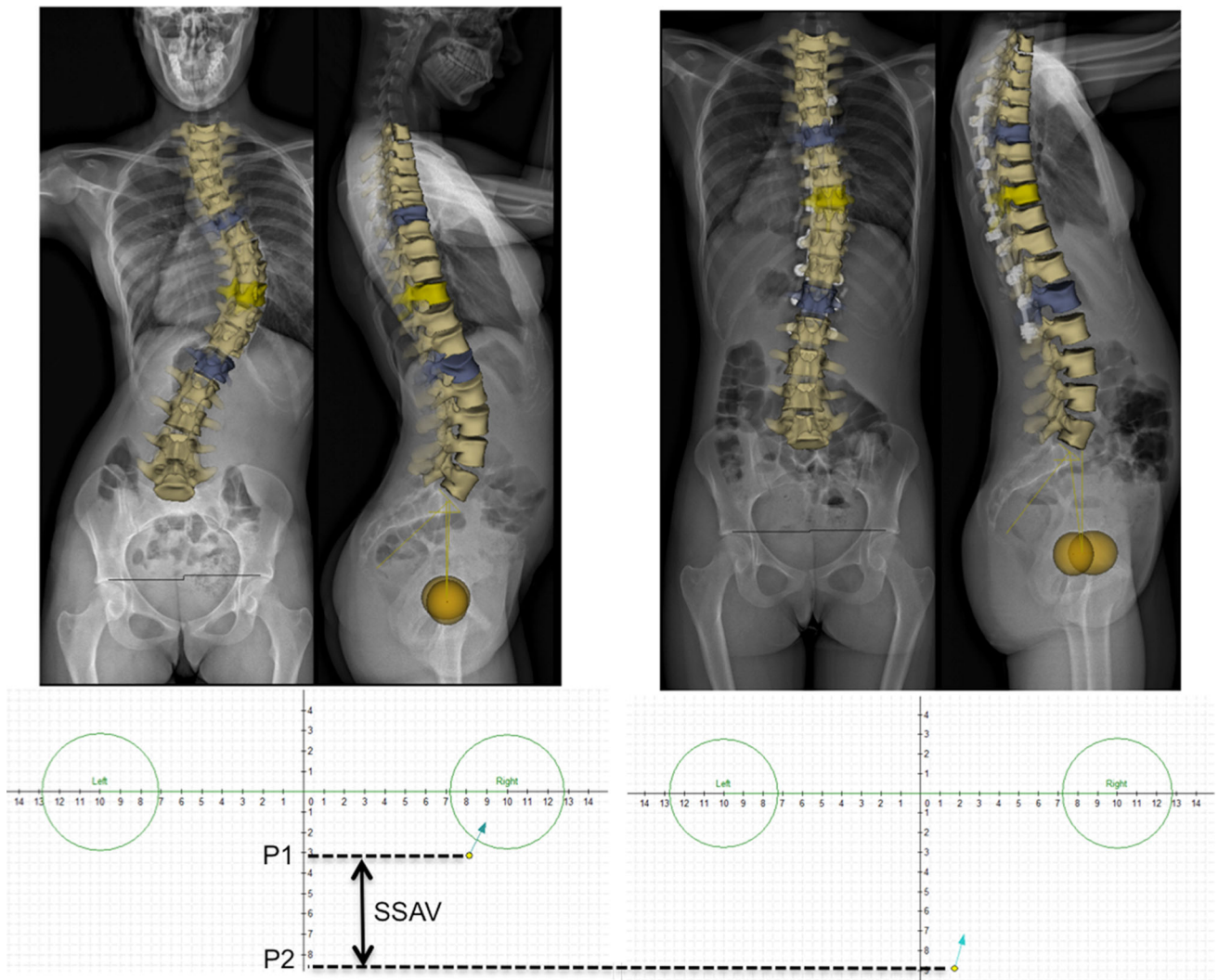


Fig. 2 Preoperative and postoperative 3D reconstructions of a Lenke 1 AIS curve, showing the posterior shift of the apical vertebra [positive SSAV (P2 - P1) of T10]

Table 1 Preoperative comparison between 2D and 3D measurements ($N = 35$)

	2D measurements		3D measurements		<i>p</i>
	Mean	SD	Mean	SD	
Main curve (°)	56	11	53	10	0.090
Proximal contra curve (°)	30	8	25	9	0.003
Distal contra curve (°)	33	12	33	9	0.469
T1 tilt (°)	3	5	2	7	0.288
L1S1 lordosis (°)	40	14	46	11	0.001
T4T12 kyphosis (°)	5	8	6	9	0.432
T1T12 kyphosis (°)	11	10	13	9	0.154
T1 slope (°)	8	6	8	8	0.077
Pelvic incidence (°)	51	14	50	10	0.610
Sacral slope (°)	41	9	41	8	0.961
Pelvic tilt (°)	11	7	10	7	0.051

Bold indicates significant *p* values

in 1 case (2.9%), T2 in 12 cases (34.2%), T3 in 20 patients (57.1%) and T4 in 2 cases (5.8%). The mean number of sublaminar bands used for correction at thoracic levels was six (± 1.5).

Radiological measurements

Preoperative radiological values are reported in Table 1. The Cobb angle of the proximal thoracic curve appeared to be overestimated in 2D (average 5° , $p = 0.003$). The only significant difference between 2D and 3D measurements regarding preoperative sagittal alignment was the L1S1 lordosis, which was underestimated in 2D (mean 6° , $p < 0.001$). The same finding was reported after surgical correction (Table 2). However, both T1T12 and T4T12 sagittal Cobb angles appeared to be overestimated in 2D postoperatively (3° , $p = 0.002$ and 4° , $p < 0.001$, respectively). Hence, only 3D measurements were kept for the quantitative analysis of the postoperative correction (Table 3). T4T12 thoracic kyphosis significantly increased after the procedure (average $8^\circ \pm 7^\circ$, $p < 0.001$), but 11 patients (31.4%) still remained hypokyphotic according to Lenke's classification (i.e., T4T12 $< 10^\circ$) (Fig. 3). However, seven out of the eight patients (87.5%) who presented a preoperative thoracic lordosis (i.e., T4T12 $< 0^\circ$) were corrected after surgery (mean gain $16^\circ \pm 4^\circ$). No significant difference was found between CoCr and Ti rods.

A posterior shift (positive SSAV) of the apical vertebra was reported in 24 patients (68.6%). In this subgroup, the mean SSAV was $+2$ cm (± 1). Good correlation was found between the SSAV and the postoperative change in 3D T4T12 kyphosis ($r = 0.62$, Fig. 4). Significant spontaneous increases in T4T12 and T1T12 sagittal Cobb angles were observed during the follow-up ($p = 0.002$ and $p < 0.001$, respectively), with a subsequent increase in the lumbar lordosis ($p = 0.006$) (Table 3). Similarly, the apex

of the main thoracic curve significantly shifted posteriorly, while a significant loss of correction was also observed in the frontal plane (average 3° for the main curve and 4° for the proximal thoracic curve).

Discussion

While many surgeons currently advocate the use of thoracic pedicle screws for optimal care in AIS, sometimes associated with multiple Ponte osteotomies, sublaminar bands should be considered in hypokyphotic patients to reduce complication rates and in particular the risk of intraoperative concave screw failure due to pull-out forces [17, 18].

Thoracic sagittal alignment correction

Since modern implants have proved their efficacy to restore the frontal alignment in AIS, the residual challenges are axial and sagittal corrections. The axial component mostly has a consequence on the cosmetic aspect, reducing the rib hump, while correcting the thoracic hypokyphosis reduces the risk of future proximal junctional kyphosis (PJK), improves cervical balance and increases the overall thoracic volume [19–21].

Watanabe et al. have recently showed on 3D models that derotation maneuvers alter sagittal alignment. As a matter of fact, the anterior and convex overgrown vertebral walls become anterior, increasing the length of the anterior column at the expense of kyphosis [22]. This might explain why many studies have reported a lordosing effect of pedicle screws at thoracic levels, which was not found when screws were used with posteromedial translation techniques [23, 24]. More than the implants, the correction technique therefore appears to be the most important

Table 2 Postoperative comparison between 2D and 3D measurements ($N = 35$)

	2D measurements		3D measurements		<i>p</i>
	Mean	SD	Mean	SD	
Main curve ($^\circ$)	17	6	16	7	0.021
Proximal contra curve ($^\circ$)	18	6	15	7	0.195
Distal contra curve ($^\circ$)	8	6	9	6	0.806
T1 tilt ($^\circ$)	4	5	5	5	0.396
L1S1 lordosis ($^\circ$)	41	13	44	11	0.003
T4T12 kyphosis ($^\circ$)	17	7	13	8	0.001
T1T12 kyphosis ($^\circ$)	24	7	21	8	0.002
T1 slope ($^\circ$)	14	8	15	7	0.850
Pelvic incidence ($^\circ$)	50	12	50	11	0.827
Sacral slope ($^\circ$)	38	9	39	7	0.159
Pelvic tilt ($^\circ$)	15	12	12	8	0.021

Bold indicates significant *p* values

Table 3 Comparison between preoperative, postoperative and final follow up 3D parameters (*N* = 35)

	Preoperative measurements		Postoperative measurements		Follow up measurements	
	Mean	SD	Mean	SD	Mean	SD
Main curve (°)	53	10	16*	7	19**	7
Proximal contra curve (°)	25	9	15*	7	19**	8
Distal contra curve (°)	33	9	9*	6	9	7
T1 tilt (°)	2	7	5*	5	5	6
L1S1 lordosis (°)	46	11	44	11	51**	11
T4T12 kyphosis (°)	6	9	13*	8	18**	8
T1T12 kyphosis (°)	13	9	21*	8	27**	9
T1 slope (°)	8	8	15*	7	18**	7
CHVA apex sag (mm)	1.4	2	1.8	3	3**	2
CHVA apex coronal	5	2	0.8*	1	1.4**	1
Pelvic incidence (°)	50	10	50	11	50	11
Sacral slope (°)	41	8	39*	7	41	8
Pelvic tilt (°)	10	7	12*	8	9	8

* Significant difference between the pre and postoperative measurements

** Significant difference between the postoperative and final follow up measurements

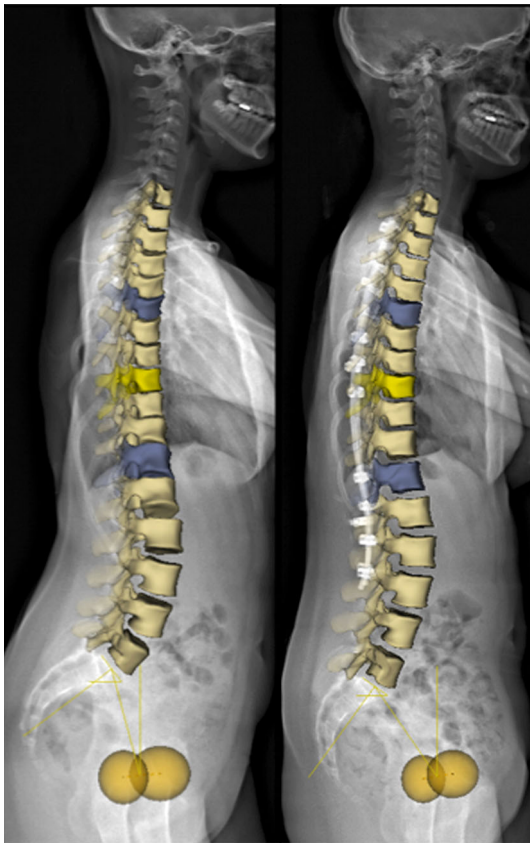


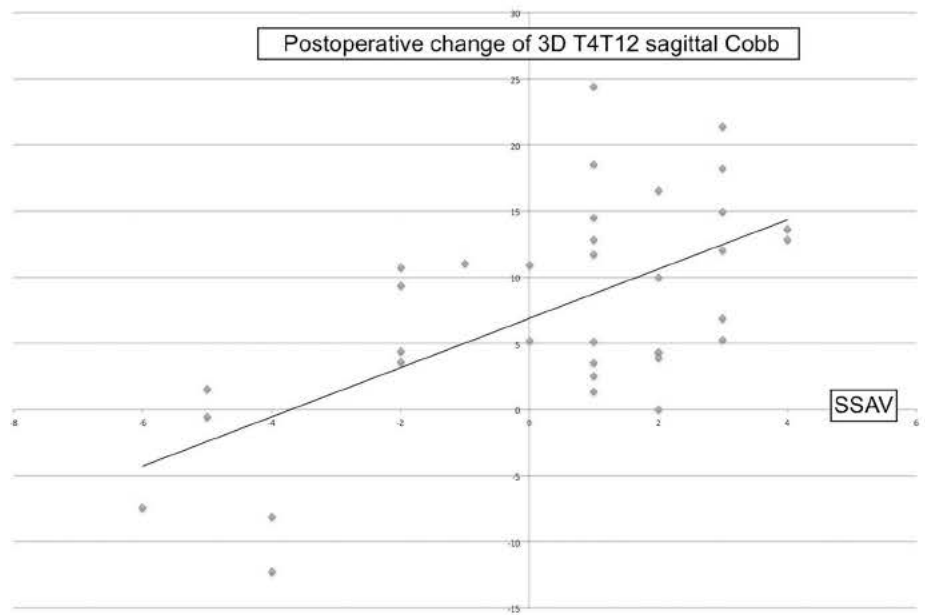
Fig. 3 Preoperative and postoperative lateral views of 3D reconstructions of a Lenke 1 AIS patient treated by T3L3 hybrid posterior fusion, showing the restoration of the thoracic sagittal alignment and the subsequent effect on the cervical spine

parameter to restore sagittal alignment. The results of this study focused on severe hypokyphotic AIS and confirmed that sublaminar bands used with posteromedial translation were able to correct the thoracic hypokyphosis in 68.6% of the cases, with a mean gain of 8°. In the 11 patients who remained hypokyphotic, the lack of correction can be explained by a lower tension applied on the bands, an insufficient sagittal contouring of the rods, or a greater stiffness of the spinal segments in the sagittal plane. Another hypothesis could be a greater axial correction, shifting the taller anterior and convex walls in the ventral direction of the spine, thus increasing the length of the anterior column; but this parameter was not evaluated in this study.

3D measurements

The main advantage of the current study is that only 3D measurements were kept for analysis. As a matter of fact, Newton et al. have demonstrated that most of the 2D sagittal Cobb measurements were biased and clearly underestimated the real thoracic spine flattening [10]. The comparison of postoperative 2D and 3D values also confirmed these findings in our cohort, with four extra degrees on average in 2D. Standing position 3D measurements should therefore become the gold standard for sagittal balance assessment, while respecting the “as low as reasonably achievable” (ALARA) concept to reduce radiation exposure [25]. They are more reliable and accurate than the

Fig. 4 Correlation between postoperative change (in degrees) of 3D T4T12 sagittal Cobb and sagittal shift of the apical vertebra (SSAV), measured in centimeters. A positive value for postoperative change in T4T12 Cobb corresponded to an increase in thoracic kyphosis



projection in a random sagittal plane of the 3D deformity. The reference used in the current study was the so-called “patient’s plane”, based on the position of the hips and therefore consistent because of not being influenced by the patient’s position in the cabin. Newton et al. have proposed preferring an addition of segmental planes, in which the local kyphosis is measured between each vertebra, but this method seems to be less relevant for clinical decisions [10].

A new 3D parameter (SSAV) was also reported here for the first time. The 3D reconstructions allowed localizing the position of the apical vertebra in the patient’s sagittal reference plane, and the shift of this vertebra was calculated postoperatively. The SSAV helped clearly understand the posterior translation of the thoracic spine, and therefore reflected the clinical impact of the procedure on sagittal balance. As a matter of fact, an increase of T1T12 sagittal Cobb without positive SSAV might only represent a biased measure or even a PJK in some cases, since the surgical procedure would not have successfully pulled the spine posteriorly.

Limitations

This study presents some limitations. Indeed, patients were operated in three distinct centers by four different senior surgeons, using different tools for clinical assessment of the rib hump. Ti rods were used in two institutions, while the third one chose to perform the posteromedial translation technique with CoCr rods. However, no significant difference was found between the two types of rods in this specific population, and this cohort represents one of the largest series of hypokyphotic patients, who are very often underrepresented in AIS literature. In addition, all

measurements were performed in 3D using a reproducible software, and the reference plane was given by the position of the patient’s hips for optimal accuracy and reliability. The spontaneous improvement of the thoracic sagittal alignment in an instrumented zone also needs to be further explored. Whether it is primitive or secondary to a physiological adaptation of the uninstrumented lumbar spine remains unclear. Longer follow-up remains necessary to make sure that fusion will occur without further loss of correction, but no rod breakage or implant loosening was reported in this series. Finally, the correlation between the new 3D parameter, apical axial corrections, the functional outcomes, and in particular pulmonary function, as investigated by Yaszay et al., needs to be assessed in the future [7].

Compliance with ethical standards

Conflict of interest The authors declare that they have no competing interests.

Funding Brice Ilharreborde, Keyvan Mazda and Jérôme Sales de Gauzy have received consultancy fees (unrelated to this study) from Implanet (Implanet, Bordeaux, France).

References

1. Winter RB, Lonstein JE, Denis F (2007) How much correction is enough? *Spine (Phila Pa 1976)* 32:2641–2643
2. Pankowski R, Roclawski M, Ceynowa M, Mikulicz M, Mazurek T, Kloc W (2016) Direct vertebral rotation versus single concave rod rotation: low dose intraoperative computed tomography evaluation of spine derotation in adolescent idiopathic scoliosis. *Spine (Phila Pa 1976)* 41:864–871

3. Lowenstein JE, Matsumoto H, Vitale MG, Weidenbaum M, Gomez JA, Lee FY, Hyman JE, Roye DP Jr (2007) Coronal and sagittal plane correction in adolescent idiopathic scoliosis: a comparison between all pedicle screw versus hybrid thoracic hook lumbar screw constructs. *Spine (Phila Pa 1976)* 32:448 452
4. Hwang SW, Samdani AF, Tantorski M, Cahill P, Nydick J, Fine A, Betz RR, Antonacci MD (2011) Cervical sagittal plane decompensation after surgery for adolescent idiopathic scoliosis: an effect imparted by postoperative thoracic hypokyphosis. *J Neurosurg Spine* 15:491 496
5. Martin CT, Pugely AJ, Gao Y, Mendoza Lattes SA, Ilgenfritz RM, Callaghan JJ, Weinstein SL (2014) Increasing hospital charges for adolescent idiopathic scoliosis in the United States. *Spine (Phila Pa 1976)* 39:1676 1682
6. Newton PO, Yaszay B, Upasani VV, Pawelek JB, Bastrom TP, Lenke LG, Lowe T, Crawford A, Betz R, Lonner B, Harms Study Group (2010) Preservation of thoracic kyphosis is critical to maintain lumbar lordosis in the surgical treatment of adolescent idiopathic scoliosis. *Spine (Phila Pa 1976)* 35:1365 1370
7. Yaszay B, Bastrom TP, Bartley CE, Parent S, Newton PO (2016) The effects of the three dimensional deformity of adolescent idiopathic scoliosis on pulmonary function. *Eur Spine J* 26(6):1658 1664. doi:10.1007/s00586 016 4694 y
8. Johnston CE, Richards BS, Sucato DJ, Bridwell KH, Lenke LG, Erickson M, Spinal Deformity Study Group (2011) Correlation of preoperative deformity magnitude and pulmonary function tests in adolescent idiopathic scoliosis. *Spine (Phila Pa 1976)* 36(14):1096 1102
9. Ran B, Fan Y, Yuan F, Guo K, Zhu X (2016) Pulmonary function changes and its influencing factors after preoperative brace treatment in patients with adolescent idiopathic scoliosis: a retrospective case control study. *Medicine (Baltimore)* 95(43):e5088
10. Newton PO, Fujimori T, Doan J, Reighard FG, Bastrom TP, Misaghi A (2015) Defining the “Three Dimensional Sagittal Plane” in thoracic adolescent idiopathic scoliosis. *J Bone Jt Surg Am* 97:1694 1701
11. Lamerain M, Bachy M, Delpont M, Kabbaj R, Mary P, Vialle R (2014) CoCr rods provide better frontal correction of adolescent idiopathic scoliosis treated by all pedicle screw fixation. *Eur Spine J* 23:1190 1196
12. Sudo H, Abe Y, Kokabu T, Ito M, Abumi K, Ito YM, Iwasaki N (2016) Correlation analysis between change in thoracic kyphosis and multilevel facetectomy and screw density in main thoracic adolescent idiopathic scoliosis surgery. *Spine J* 16:S1529 S9930
13. Ferrero E, Pesenti S, Blondel B, Jouve JL, Mazda K, Ilharreborde B (2014) Role of thoracoscopy for the sagittal correction of hypokyphotic adolescent idiopathic scoliosis patients. *Eur Spine J* 23:2635 2642
14. Ilharreborde B, Sebag G, Skalli W, Mazda K (2013) Adolescent idiopathic scoliosis treated with posteromedial translation: radiologic evaluation with a 3D low dose system. *Eur Spine J* 22:2382 2391
15. Ilharreborde B, Steffen JS, Nectoux E, Vital JM, Mazda K, Skalli W, Obeid I (2011) Angle measurement reproducibility using EOS three dimensional reconstructions in adolescent idiopathic scoliosis treated by posterior instrumentation. *Spine (Phila Pa 1976)* 36:E1306 E1313
16. Vidal C, Ilharreborde B, Azoulay R, Sebag G, Mazda K (2013) Reliability of cervical lordosis and global sagittal spinal balance measurements in adolescent idiopathic scoliosis. *Eur Spine J* 22:1362 1367
17. De Kleuver M, Lewis SJ, Gersmisch NM, Kamper SJ, Alanay A, Berven SH, Cheung KM, Ito M, Lenke LG, Polly DW, Qiu Y, van Tulder M, Shaffrey C (2014) Optimal surgical care for adolescent idiopathic scoliosis: an international consensus. *Eur Spine J* 23:2603 2618
18. Quan GM, Gibson MJ (2010) Correction of main thoracic adolescent idiopathic scoliosis using pedicle screw instrumentation: does higher implant density improve correction? *Spine (Phila Pa 1976)* 35:562 567
19. Ilharreborde B, Vidal C, Skalli W, Mazda K (2013) Sagittal alignment of the cervical spine in adolescent idiopathic scoliosis treated by posteromedial translation. *Eur Spine J* 22:330 337
20. Ilharreborde B, Dubousset J, Le Huec JC (2014) Use of EOS imaging for the assessment of scoliosis deformities: application to postoperative 3D quantitative analysis of the trunk. *Eur Spine J* 23(Suppl 4):S397 S405
21. Charles YP, Sfeir G, Matter Parrat V, Sauleau EA, Steib JP (2015) Cervical sagittal alignment in idiopathic scoliosis treated by posterior instrumentation and in situ bending. *Spine (Phila Pa 1976)* 40:E419 E427
22. Watanabe K, Nakamura T, Iwanami A, Hosogane N, Tsuji T, Ishii K, Nakamura M, Toyama Y, Chiba K, Matsumoto M (2012) Vertebral derotation in adolescent idiopathic scoliosis causes hypokyphosis of the thoracic spine. *BMC Musculoskelet Disord* 12(13):99
23. Fletcher ND, Hopkins J, McClung A, Browne R, Sucato DJ (2012) Residual thoracic hypokyphosis after posterior spinal fusion and instrumentation in adolescent idiopathic scoliosis: risk factors and clinical ramifications. *Spine (Phila Pa 1976)* 37:200 206
24. Clement JL, Geoffroy A, Yagoubi F, Chau E, Solla F, Oborocianu I, Rampal V (2013) Relationship between thoracic hypokyphosis, lumbar lordosis and sagittal pelvic parameters in adolescent idiopathic scoliosis. *Eur Spine J* 22:2414 2420
25. ICRP, Khong PL, Ringertz H, Donoghue V, Frush D, Rehani M, Appelgate K, Sanchez R (2013) ICRP publication 121: radiological protection in paediatric diagnostic and interventional radiology. *Ann ICRP* 42(2):1 63