



HAL
open science

Salvage of congenital pseudarthrosis of the tibia by the induced membrane technique followed by a motorised lengthening nail

Tristan Pollon, Jérôme Sales de Gauzy, Thuy Trang Pham, Camille Thevenin Lemoine, Franck Accadbled

► To cite this version:

Tristan Pollon, Jérôme Sales de Gauzy, Thuy Trang Pham, Camille Thevenin Lemoine, Franck Accadbled. Salvage of congenital pseudarthrosis of the tibia by the induced membrane technique followed by a motorised lengthening nail. *Orthopaedics & Traumatology: Surgery & Research*, 2018, 104 (1), pp.147-153. 10.1016/j.otsr.2017.10.012 . hal-02135146

HAL Id: hal-02135146

<https://hal.science/hal-02135146>

Submitted on 21 May 2019

HAL is a multi-disciplinary open access archive for the deposit and dissemination of scientific research documents, whether they are published or not. The documents may come from teaching and research institutions in France or abroad, or from public or private research centers.

L'archive ouverte pluridisciplinaire **HAL**, est destinée au dépôt et à la diffusion de documents scientifiques de niveau recherche, publiés ou non, émanant des établissements d'enseignement et de recherche français ou étrangers, des laboratoires publics ou privés.





Open Archive Toulouse Archive Ouverte (OATAO)

OATAO is an open access repository that collects the work of some Toulouse researchers and makes it freely available over the web where possible.

This is an author's version published in: <https://oatao.univ-toulouse.fr/23116>

Official URL : <https://doi.org/10.1016/j.otsr.2017.10.012>

To cite this version :

Pollon, Tristan and Sales de Gauzy, Jérôme  and Pham, Thuy Trang and Thevenin Lemoine, Camille and Accadbled, Franck  *Salvage of congenital pseudarthrosis of the tibia by the induced membrane technique followed by a motorised lengthening nail.* (2018) *Orthopaedics & Traumatology: Surgery & Research*, 104 (1). 147-153. ISSN 1877-0568

Any correspondence concerning this service should be sent to the repository administrator:

tech-oatao@listes-diff.inp-toulouse.fr

Case report

Salvage of congenital pseudarthrosis of the tibia by the induced membrane technique followed by a motorised lengthening nail

T. Pollon*, J. Sales de Gauzy, T. Pham, C. Thévenin Lemoine, F. Accadbled

Département de chirurgie orthopédique, traumatologique et plastique, CHU de Toulouse, place du Dr-Baylac, 31059 Toulouse, France

A B S T R A C T

Keywords:

Limb length discrepancy
Congenital pseudarthrosis
Fitbone®
Masquelet technique
Induced membrane technique
Tibia
Neurofibromatosis

An 18-year-old male with neurofibromatosis type I was treated for congenital pseudarthrosis of the tibia using the Masquelet induced-membrane technique with internal fixation by retrograde implantation of a transplantar intramedullary nail. Bone healing was obtained at the expense of malunion with external rotation and 5.5 cm of lower limb shortening. A motorised intramedullary-lengthening nail (Fitbone®, Wittenstein, Igersheim, Germany) was implanted. This treatment was successful in correcting the rotational malalignment and limb length discrepancy. The motorised nail Fitbone® may be a valid option for treating complex cases of limb length discrepancy, including those combined with limb deformities.

1. Introduction

Congenital pseudarthrosis of the tibia (CPT) is a bone abnormality that is strongly associated with neurofibromatosis type 1 (NF1). The prevalence of CPT is 1/190,000 [1]. Two major therapeutic challenges must be met to achieve good outcomes: bone healing must be obtained, and the alignment abnormalities must be corrected. The technical difficulties in achieving these goals increase with patient age.

2. Case report

This 18-year-old male with NF1 presented with CPT manifesting as congenital bowing of the right leg. The deformity persisted despite two previous treatment attempts using the Ilizarov device followed by a third surgical procedure for shortening and internal fixation of the tibia. At referral to our centre, the right lower limb was 5 cm shorter than the left, and the deformity combined 40° of fixed flexion, 10° of valgus, and anterior bowing of the tibial shaft (Figs. 1 and 2). Range of motion was normal at the knee and restricted at the ankle.

Treatment was with the induced membrane technique using gentamicin-loaded Palacos® bone cement (Zimmer Biomet, Warsaw, IN, USA), realignment of the leg, and internal fixation via the transplantar retrograde implantation of a T2® tibial nail (Stryker, Kalamazoo, MI, USA), after resection down to bone devoid of macroscopic dystrophy (Fig. 3). The second stage was performed 6 weeks later and involved implanting autologous cancellous bone harvested from the two iliac crests (Fig. 4).

The outcome was favourable, with evidence of bone healing after 3 months. However, a leg length discrepancy of 5 cm persisted, and the leg was in 40° of external rotation (Fig. 5).

Bone lengthening was therefore performed by implantation of a motorised intramedullary nail (Fitbone®, Wittenstein, Igersheim, Germany) 2 years after the induced membrane procedure. In addition, the rotational malalignment was corrected. Thus, two tibial osteotomies were performed, one at the metaphysis to allow bone lengthening and the other at the midpoint of the diaphysis to immediately restore rotational alignment. The motorised nail bridged the ankle joint (Fig. 6). The intramedullary canal was patent, and no approach of the pseudarthrosis site was required. The limb was lengthened by 3 cm over 60 days. The presence after 4 months of 15° of valgus and 30° of flexion in the lengthening callus required revision surgery for implantation of a locked nail (Fig. 7). The valgus deformity was corrected by implantation of a conventional intramedullary-locking nail (Stryker). The proximal poly-axial locked nailing optimized the stability of the construct (Fig. 8).

* Corresponding author.

E-mail address: tristan.pollon@gmail.com (T. Pollon).

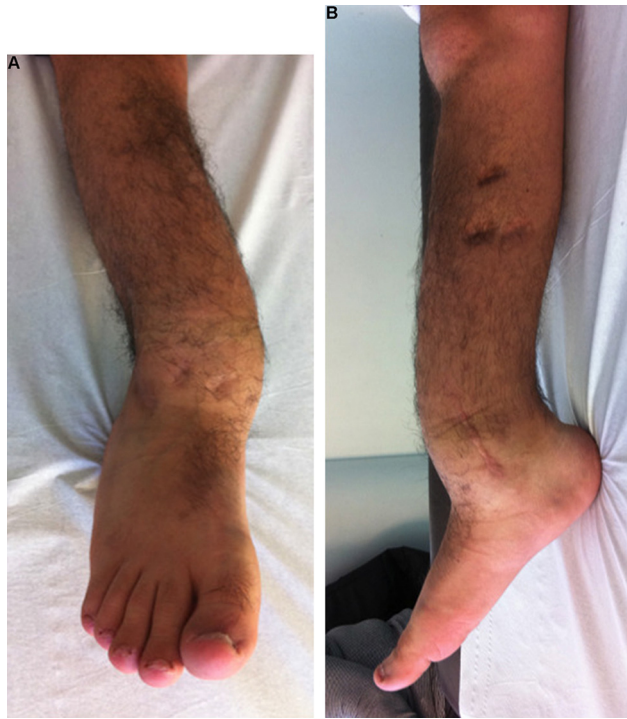

Fig. 1. Clinical appearance.

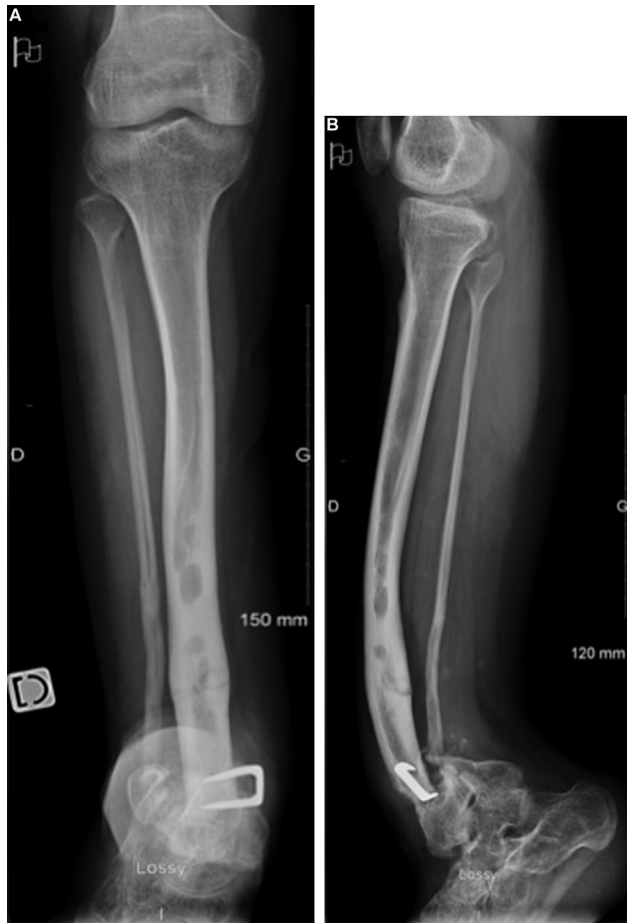

Fig. 2. Initial radiographs showing dystrophy of the tibia and fibula with anterolateral bowing; note the staple and evidence of pseudarthrosis of the tibia and fibula.

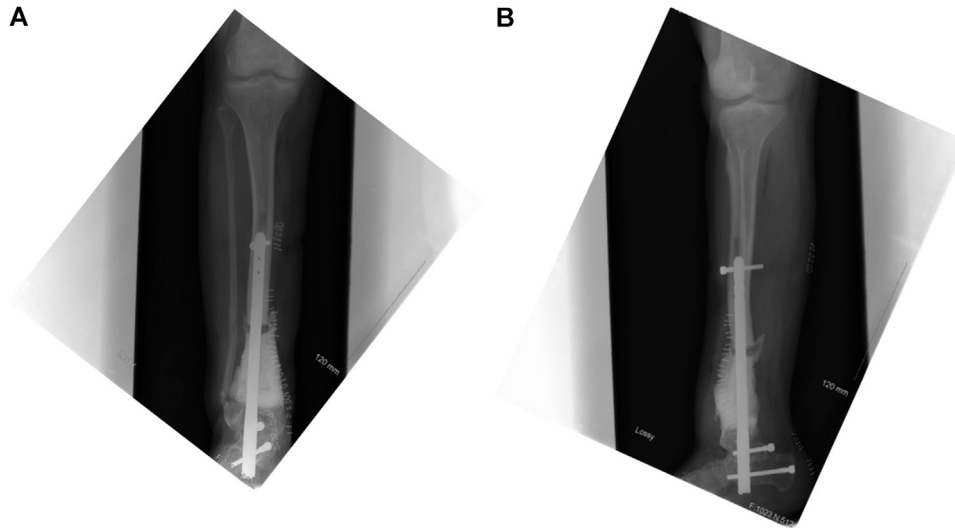


Fig. 3. First stage of reconstruction using the induced membrane technique, with implantation of cement, partial realignment in the coronal and sagittal planes, and transplantar implantation of a locking nail.

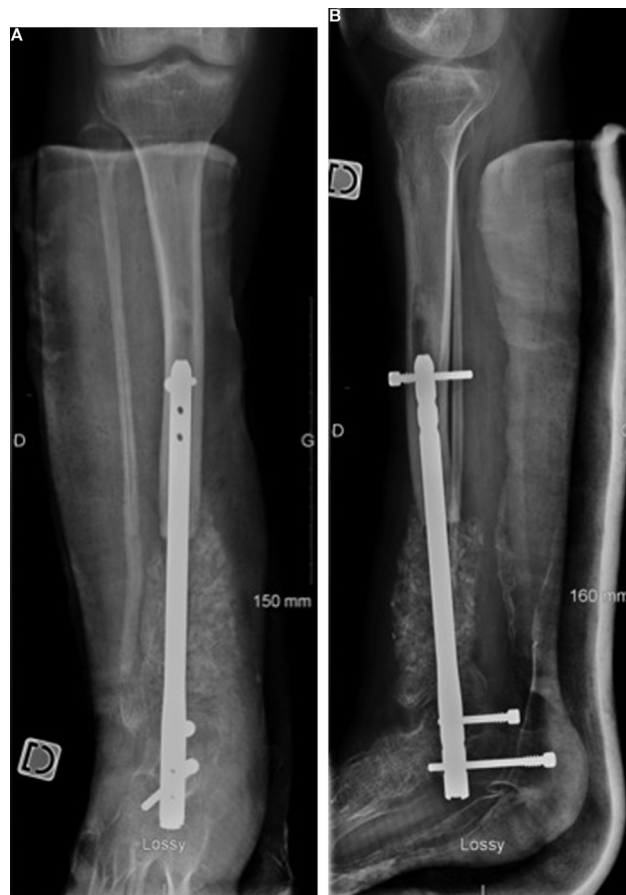

Fig. 4. Second stage of reconstruction using the induced membrane technique, with insertion of autologous cancellous bone grafts harvested from both posterior iliac crests.

The internal fixation material was removed 2 years after the last surgical procedure. Bone healing and limb realignment were obtained (Figs. 9 and 10). Tibial slope was 26° and the residual limb length discrepancy was 2 cm. Range of motion was normal at the knee. At the ankle, the arc of motion was 15° .

3. Discussion

In patients with CPT, nailing combined with the external fixation using the Ilizarov device has also been reported to provide good outcomes [2]. Zhu et al. obtained good bone healing rates

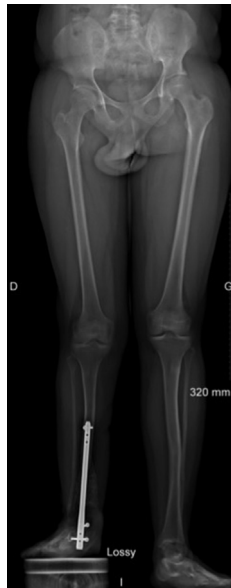

Fig. 5. Lower limb telemetry showed 5.5 cm shortening of the right leg and malunion with 40° of external rotation. Note the evidence of bone healing.

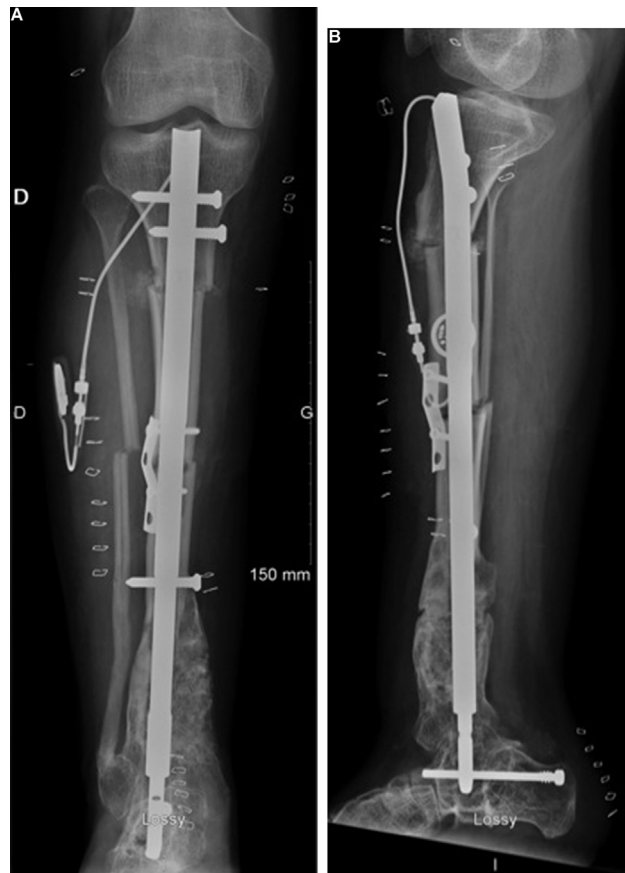


Fig. 6. Postoperative radiographs after distraction osteotomies and rotational realignment via a motorised nail.

with the two-stage Ilizarov technique [3]. Bone healing was achieved in 2 patients treated by Muhammad et al. using reaming, realignment, nailing, and lengthening in an Ilizarov device, without resection of the pseudarthrosis site [4]. Cho TJ et al. suggested proximal metaphyseal dysplasia as a risk factor for treatment failure [5]. Vascularised bone grafts have also pro-

duced good outcomes [6,7]. Accadbled et al. showed that the motorised nail Fitbone[®] method based on callus distraction (callosities) after osteotomy was effective in correcting limb length discrepancies [8].

In our patient, transplantar nailing and implantation of a cement spacer [9] ensured preservation of a patent intramedullary cav-

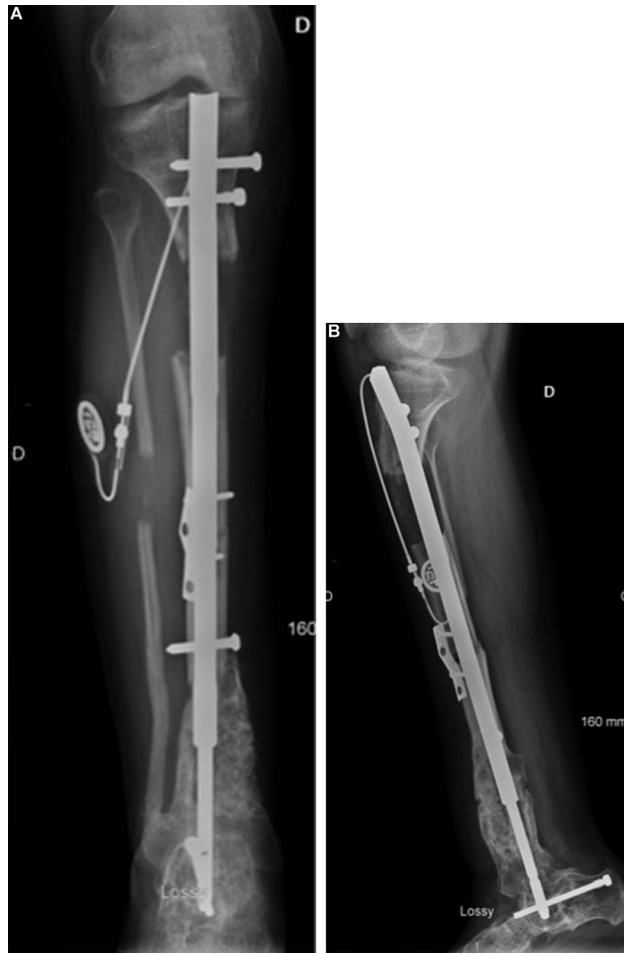

Fig. 7. Radiographs taken 4 months after implantation of the motorised nail, showing a small callus at the proximal metaphysis and a deformity with 30° of flexion and 15° of valgus; note the cut-out of a proximal locking nail.

ity [10]. The arthroereisis of the tibio-talar and sub-talar joints improved the stability of the construct [11] but contributed to restrict the mobility of these joints [12].

The second stage of deformity correction was not performed at the CPT site, as this strategy is associated with a high risk of non-union. Although performing two osteotomies can impair the blood

supply to the intermediate fragment [13], this option was chosen for its greater technical simplicity.

The risk of displacement causing flexion deformity during limb lengthening seems greater when the osteotomy is located more proximally. The nail is probably unable to effectively control this risk.

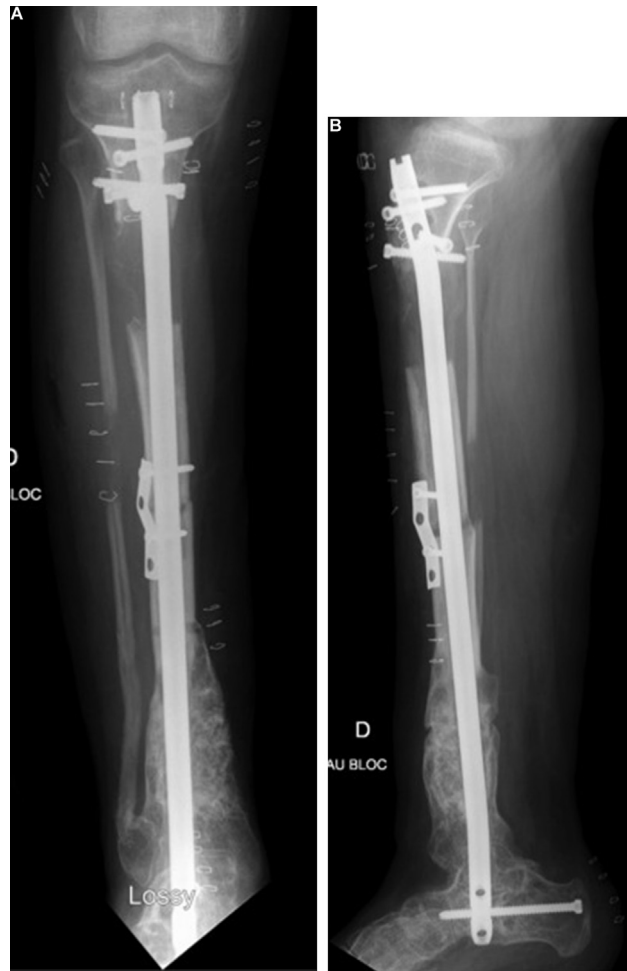

Fig. 8. Postoperative radiographs after revision surgery for realignment using an intramedullary-locking nail; the valgus is fully corrected but the flexion deformity shows little change.

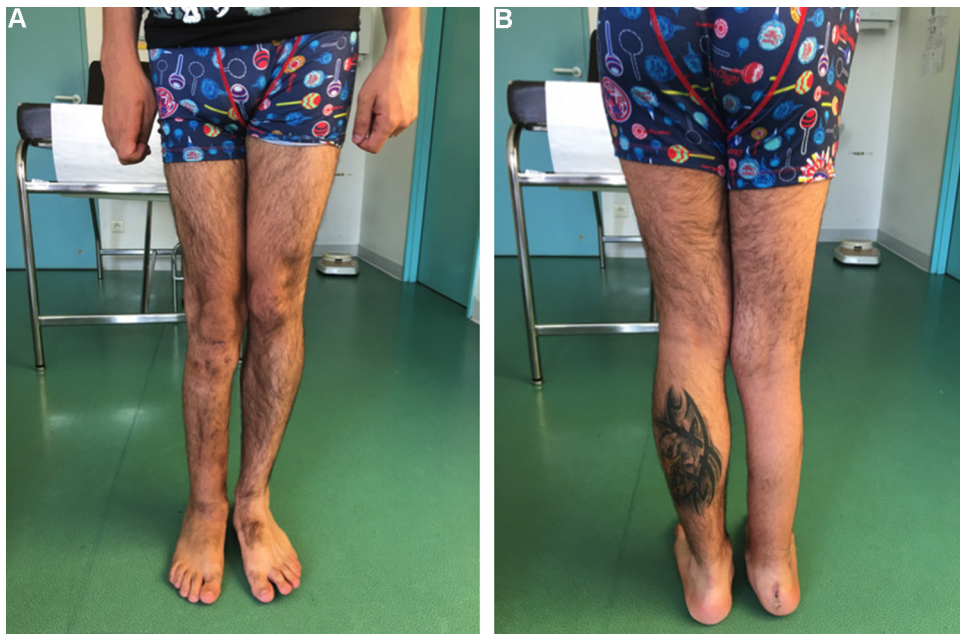

Fig. 9. Clinical appearance at last follow-up.

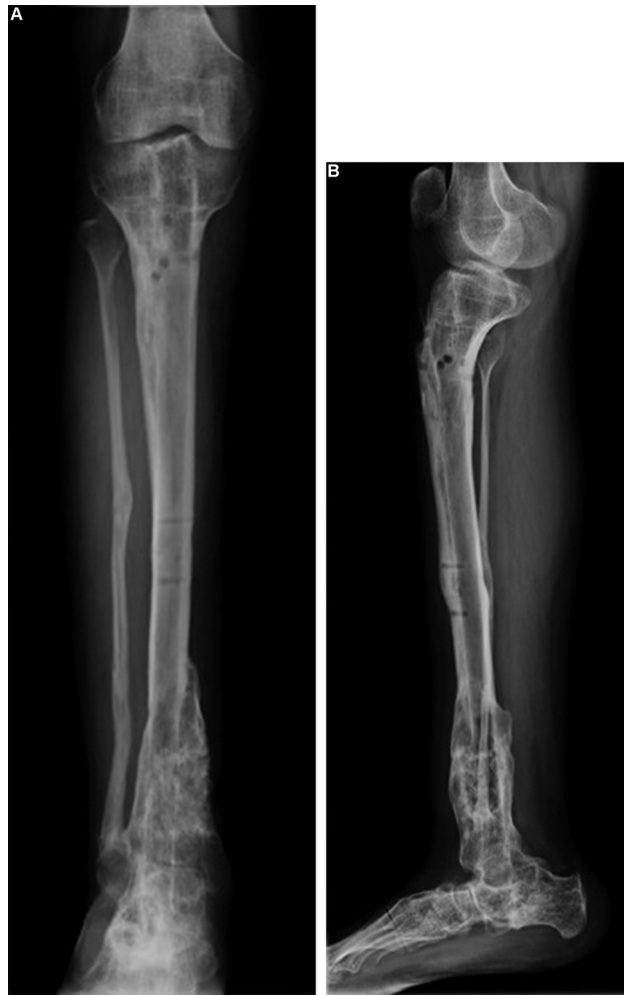

Fig. 10. Radiograph obtained 2 years after the last surgical procedure; bone healing is complete, and the tibial slope is 26°.

4. Conclusion

The Masquelet technique ensured bone healing but left residual deformities. Implantation of a motorised Fitbone® corrected the limb length discrepancy, and healing of the tibia was obtained despite the CPT and two osteotomies.

Disclosure of interest

The authors declare that they have no competing interest.

References

- [1] Hefti F, Bollini G, Dungal P, Fixsen J, Grill F, Ippolito E, et al. Congenital pseudarthrosis of the tibia: history, etiology, classification, and epidemiologic data. *J Pediatr Orthop* 2000;9:11–5.
- [2] Agashe MV, Song S-H, Refai MA, Park K-W, Song H-R. Congenital pseudarthrosis of the tibia treated with a combination of Ilizarov's technique and intramedullary rodding. *Acta Orthop* 2012;83:515–22.
- [3] Zhu G, Mei H, He R, Liu K, Tang J, Wu J. Effect of distraction osteogenesis in patient with tibial shortening after initial union of congenital pseudarthrosis of the tibia: A preliminary study. *BMC Musculoskelet Disord* 2015; 16:216.
- [4] Muhammad Abdul Jamil MK, Abdul Rashid AH, Ibrahim S. Congenital pseudoarthrosis of the tibia: healing by lengthening over a rod without compression of the nonunion. A preliminary report. *J Pediatr Orthop* 2013;22: 207–12.
- [5] Cho T-J, Choi IH, Lee KS, Lee SM, Chung CY, Yoo WJ, et al. Proximal tibial lengthening by distraction osteogenesis in congenital pseudarthrosis of the tibia. *J Pediatr Orthop* 2007;27:915–20.
- [6] Coleman SS, Coleman DA. Congenital pseudarthrosis of the tibia: treatment by transfer of the ipsilateral fibula with vascular pedicle. *J Pediatr Orthop* 1994;14:156–60.
- [7] Tan JS, Roach JW, Wang AA. Transfer of ipsilateral fibula on vascular pedicle for treatment of congenital pseudarthrosis of the tibia. *J Pediatr Orthop* 2011;31:72–8.
- [8] Accadbled F, Pailhé R, Cavaignac E, Sales de Gauzy J. Bone lengthening using the Fitbone® motorized intramedullary nail: the first experience in France. *Orthop Traumatol Surg Res* 2016;102:217–22.
- [9] Black SR, Kwon MS, Cherkashin AM, Samchukov ML, Birch JG, Jo C-H. Lengthening in congenital femoral deficiency: a comparison of circular external fixation and a motorized intramedullary nail. *J Bone Joint Surg Am* 2015;97:1432–40.
- [10] Shah H, Doddabasappa SN, Joseph B. Congenital pseudarthrosis of the tibia treated with intramedullary rodding and cortical bone grafting: a follow-up study at skeletal maturity. *J Pediatr Orthop* 2011;31:79–88.
- [11] Chalopin A, Pesenti S, Peltier E, Bin K, Launay F, Jouve J-L. Transplantar intramedullary locking nailing in childhood congenital pseudarthrosis of the tibia: a report of 3 cases. *Orthop Traumatol Surg Res* 2016;102:521–4.
- [12] Seo SG, Lee DY, Kim YS, Yoo WJ, Cho T-J, Choi IH. Foot and ankle function at maturity after Ilizarov treatment for atrophic-type congenital pseudarthrosis of the tibia: a comprehensive outcome comparison with normal controls. *J Bone Joint Surg Am* 2016;98:490–8.
- [13] Shirai H, Abe M, Nagaoka T, Onomura T. Appropriate osteotomy site and number in limb lengthening. *Clin Orthop Related Res* 1997;336:308–17.