



**HAL**  
open science

## **Neurotization of the superficial sensory branch of ulnar nerve by the distal posterior interosseous nerve: cadaveric feasibility study**

Pierre Laumonerie, Laurent Decaestecker, Stéphanie Delclaux, Costel Apredoaei, Meagan E. Tibbo, Monique Courtade-Saïdi, Pierre Mansat

### ► **To cite this version:**

Pierre Laumonerie, Laurent Decaestecker, Stéphanie Delclaux, Costel Apredoaei, Meagan E. Tibbo, et al.. Neurotization of the superficial sensory branch of ulnar nerve by the distal posterior interosseous nerve: cadaveric feasibility study. *Journal of Reconstructive Microsurgery*, 2017, 33 (09), pp.636-640. 10.1055/s-0037-1605365 . hal-02135139

**HAL Id: hal-02135139**

**<https://hal.science/hal-02135139>**

Submitted on 21 May 2019

**HAL** is a multi-disciplinary open access archive for the deposit and dissemination of scientific research documents, whether they are published or not. The documents may come from teaching and research institutions in France or abroad, or from public or private research centers.

L'archive ouverte pluridisciplinaire **HAL**, est destinée au dépôt et à la diffusion de documents scientifiques de niveau recherche, publiés ou non, émanant des établissements d'enseignement et de recherche français ou étrangers, des laboratoires publics ou privés.




## Open Archive Toulouse Archive Ouverte (OATAO)

OATAO is an open access repository that collects the work of some Toulouse researchers and makes it freely available over the web where possible.

This is an author's version published in: <https://oatao.univ-toulouse.fr/23107>

**Official URL :** <https://doi.org/10.1055/s-0037-1605365>

**To cite this version :**

Laumonerie, Pierre and Decaestecker, Laurent and Delclaux, Stéphanie and Apredoaei, Costel and Tibbo, Meagan E. and Courtade-Saïdi, Monique and Mansat, Pierre   
*Neurotization of the superficial sensory branch of ulnar nerve by the distal posterior interosseous nerve: cadaveric feasibility study.* (2017) *Journal of Reconstructive Microsurgery*, 33 (09). 636-640. ISSN 0743-684X

Any correspondence concerning this service should be sent to the repository administrator:

[tech-oatao@listes-diff.inp-toulouse.fr](mailto:tech-oatao@listes-diff.inp-toulouse.fr)

# Neurotization of the Superficial Sensory Branch of Ulnar Nerve by the Distal Posterior Interosseous Nerve: Cadaveric Feasibility Study

P. Laumonerie, MD<sup>1,2</sup> L. Decaestecker, MD<sup>1</sup> S. Delclaux, MD<sup>1</sup> C. Apredoaei, MD<sup>1</sup> M. E. Tibbo, MD<sup>3</sup>  
M. Courtade-Saïdi, MD, PhD<sup>4</sup> P. Mansat, MD, PhD<sup>1</sup>

<sup>1</sup> Department of Orthopaedic, Hôpital Pierre Paul Riquet, Toulouse, France

<sup>2</sup> Anatomy Laboratory, Faculty of Medicine, Toulouse, France

<sup>3</sup> Department of Orthopaedic, Mayo Clinic, Rochester, Minnesota

<sup>4</sup> Histology and Embryology Laboratory, Rangueil Medical School, Toulouse University, Toulouse, France

Address for correspondence Pierre Laumonerie, MD, Hôpital Pierre Paul Riquet, Anatomy Laboratory, Faculty of Medicine, Toulouse 31062, France (e mail: laumonerie.pierre@hotmail.fr).

## Abstract

**Background** In 2014, Delclaux et al described a case wherein the Battiston and Lanzetta's technique, modified by utilization of the posterior interosseus nerve (PIN), was used to perform double neurotization of the ulnar nerve (UN). This study evaluates the feasibility of transfer of proprioceptive fascicles of the PIN to the superficial sensory branch of the UN (SSBUN).

**Methods** The surgeries were performed on 16 fresh cadaveric wrist specimens. PIN transfer was performed through the interosseous membrane and sutured to the SSBUN. The diameter for each nerve, number of fascicles, and the percentage of fascicles without axons, under  $\times 10$ ,  $\times 40$ , and  $\times 100$  magnifications were performed by two observers.

**Results** Neurotization of the SSBUN by the PIN was successful in all cases. The median diameter of the SSBUN and PIN was 3.5 (3–4) and 2.3 mm (1.6–3), respectively. The SSBUN contained 5.5 fascicles (4–7), while the PIN contained 2 fascicles (0–4). The 16 PIN had limited (10 cases) or no axonal reserve (6 cases).

**Conclusion** This study supports the surgical and anatomical feasibility of neurotization of the SSBUN by the PIN. However, the PIN's limited axonal reserve may partially or totally compromise recovery.

## Keywords

- ▶ neurotization
- ▶ ulnar nerve
- ▶ nerve
- ▶ posterior interosseous nerve
- ▶ sensory
- ▶ deficit

Ulnar nerve (UN) injuries are common, and the potential for motor and sensory recovery thereafter is minimal.<sup>1–5</sup> Direct nerve repair is the reference gold standard.<sup>6–9</sup> At the very least, neurotization and distal tendon transfers are alternative choices for ulnar lesions with poor sensorimotor recovery prognoses.<sup>10–13</sup> Selective neurotization techniques for the motor branch of the UN have produced satisfactory results with respect to intrinsic muscle recovery at long-

term follow-up.<sup>12,14,15</sup> However, hypothenar anesthesia causes discomfort and cutaneous ulcerations of the ulnar aspect of the hand secondary to repetitive microtrauma. Successful restoration of ulnar motor and sensory function using neurotization techniques were described.<sup>16–18</sup> However, these newer techniques require harvesting of a sensory branch, thereby risking palmar anesthesia for the palmar cutaneous branch of the median nerve, and dysesthesia or anesthesia for the common palmar digital nerve of the third web space.<sup>16–18</sup>

 Author's ORCID ID [orcid.org/0000-0002-3019-9861](https://orcid.org/0000-0002-3019-9861).



In 2014, Delclaux et al reported rapid and successful sensorimotor recovery (M3/S2 at 18 months follow-up) using an innovative double neurotization technique of the UN by the anterior interosseous nerve (AIN) and the posterior interosseus nerve (PIN) without theoretical consequence for the donor site.<sup>19</sup> However, selective neurotization techniques for the motor branch of the UN by AIN was previously supported by anatomical work.<sup>20</sup> The objective of our study is to validate the feasibility of sensory neurotization via anatomic and histologic analyses.

## Methods

### Specimens

In this study, 16 fresh cadaveric upper extremities (8 left and 8 right) of 10 males and 6 females, with a median age of 77.5 years (67–88) were used. Exclusion criteria were antecedent trauma or surgical intervention at the level of the forearm (FA) or hand (fractures, wounds).

### Technique

The procedure consisted of four phases: UN dissection, PIN dissection, transfer of the PIN to the superficial sensory branch of the UN (SSBUN), and histologic analysis of the sutured ends under the microscope.

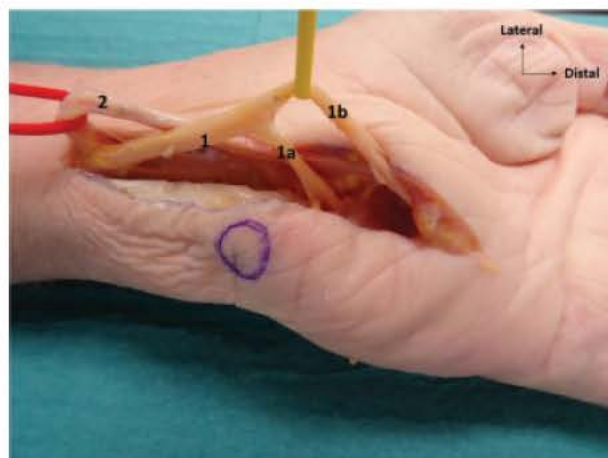
Dissection of the PIN on the dorsal surface of the wrist and of the UN on the palmar aspect of the hand, in addition to nerve suturing, were performed in the anatomy laboratory by hand surgeons (P.L. and L.D.). Surgical loops (at  $\times 4$  magnification) and fine microsurgery instruments were used. A single observer (P.L.) measured the length of the dissected portion of the PIN using calipers. During a separate dissection, transverse sections of the PIN and SSBUN were also prepared to assess their diameter (i.e., the section of nerve with the greatest distance from edge to edge was recorded for each nerve), number of fascicles, and the percentage of fascicles without axons, under  $\times 10$ ,  $\times 40$ , and  $\times 100$  magnifications. These analyses were performed by two observers (M.C.S. and P.L.).

### Ulnar Nerve Dissection

The FA was positioned in abduction and supination. A 6-cm incision was made on the volar aspect of the FA, lateral to the tendon of the flexor carpi ulnaris and pisiform. The tendon of the flexor carpi ulnaris was identified at the proximal end of the incision and retracted medially. The ulnar artery was dissected from the lateral border of the UN and retracted laterally. Guyon's canal was incised longitudinally. The superficial sensory and deep motor branches of the UN were dissected from distal to proximal. An interfascicular dissection of the UN was performed using surgical loupes, to separate the sensory and motor fascicles (**Fig. 1**).

### Dissection of the Posterior Interosseous Nerve

The FA was positioned in abduction and pronation. A 6-cm longitudinal incision, centered on Lister's tubercle, was made on the dorsal aspect of the FA. The extensor digitorum and extensor pollicis longus were retracted medially and radially,



**Fig. 1** Wrist joint (volar view). Deep motor branch (1a) and superficial sensory branch (1b) of the ulnar nerve. Ulnar artery (2) on the radial side of the common trunk of the ulnar nerve (1).

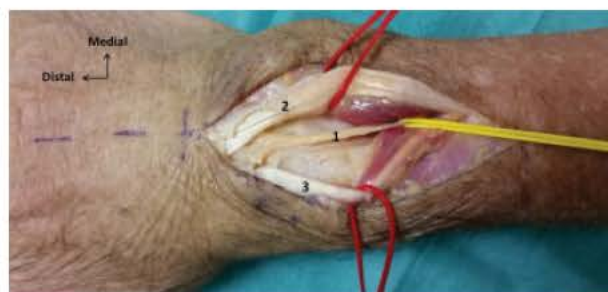respectively, to expose the PIN. Dissection of the PIN was performed, using surgical loupes, from distal to proximal beginning from the articular capsule (**Fig. 2**).

### Transfer of the Posterior Interosseous Nerve

Using surgical loupes, the PIN was sectioned at the most distal point possible at the level of the joint capsule. The PIN was transferred, without tension, through the interosseous membrane at the distalmost aspect of the pronator quadratus. The sensory fascicles of the fourth and fifth rays were connected to the fascicles of the PIN using 10–0 nonabsorbable monofilament epiperineurial suture in an interrupted fashion (**Figs. 3 and 4**).

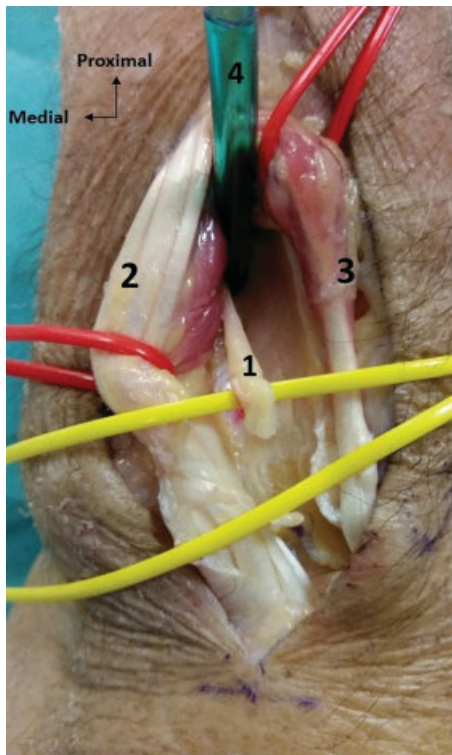
### Histologic Examination

Three centimeter margins on either side of the sutured connections between the PIN and SSBUN were sampled. The samples were fixed in formalin and embedded in paraffin. Transverse sections were then stained with Masson's trichrome to visualize the connective tissue envelope of the nerves. The samples were analyzed under  $\times 10$ ,  $\times 40$ , and  $\times 100$  magnifications. The respective diameter of the PIN and



**Fig. 2** Wrist joint (dorsal view). Posterior interosseus nerve (1) on the radial side of the extensor digitorum (2) and on the ulnar side of the extensor pollicis longus (3).



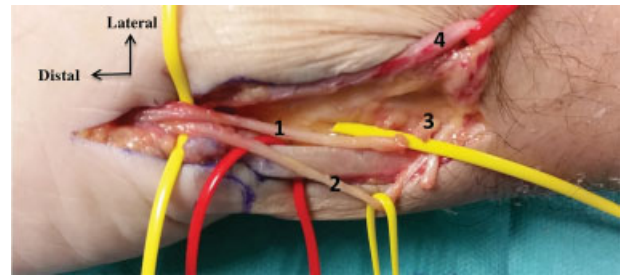


**Fig. 3** Wrist joint (dorsal view). Posterior interosseus nerve (sectioned and dissected) (1) between the extensor digitorum (2) and the extensor pollicis longus (3). The green tube (4) illustrates the transfer of the posterior interosseus nerve through the interosseous membrane.

SSBUN, as well as the number of fascicles with and without axons was thereby assessed (→ Fig. 5).

### Statistical Analysis

The results were described according to their median, and their minimum and maximum values.



**Fig. 4** Wrist joint (volar view). The SSBUN (1) and deep motor (2) branches of the ulnar nerve after interfascicular dissection. The posterior interosseus nerve (3) transferred anteriorly in contact with the SSBUN. The ulnar artery dissected and retracted laterally (4). SSBUN, superficial sensory branch of the ulnar nerve.

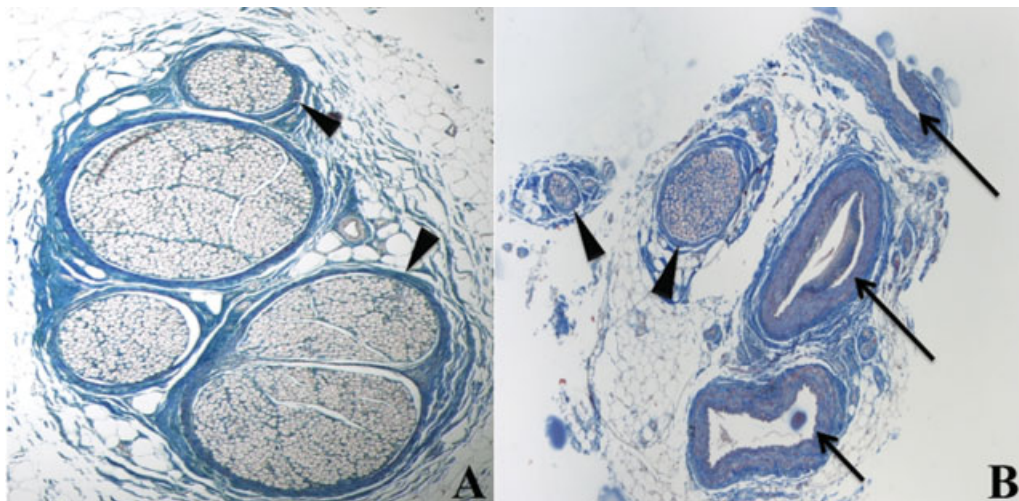
### Results

Transfer of the PIN to the SSBUN was successful in all 16 cases. Due to the intraneural dissection of the UN, the SSBUN was systematically mobilized which allowed for quality, tension-free sutures in all 16 cases. Mobilization of the elbow and wrist did not place tension on any of the 16 nerve sutures.

The median length of dissection of the PIN was 40 mm (37–43) from the distal cut edge. At  $\times 40$  magnification, the median diameter of the SSBUN and PIN was 3.5 (3–4) and 2.3 mm (1.6–3), respectively. The SSBUN contained 5.5 fascicles (4–7), while the PIN contained 2 fascicles (0–4). Complete absence of fascicles was observed in six PIN samples.

### Discussion

Sensation in the fourth and fifth digits is not essential for manipulation of objects and does not represent a functional



**Fig. 5** Histological illustration. Transverse sections of the ulnar nerve (A) and the posterior interosseus nerve (B), Masson's trichrome stain,  $\times 40$  magnification. Several fascicles with numerous axons in cross section surrounded by connective tissue (perineurium, arrow heads) can be seen within the ulnar nerve. Only two fascicles are present (arrow heads) in the posterior interosseus nerve, one of them is very small and contains only rare axons. Blood vessels (small arteries and vein) are also present in the section (arrows).

loss.<sup>1 5</sup> Double neurotization of the UN has two objectives: sensory recovery sufficient to prevent damage from micro-trauma (S2 or higher) and minimal morbidity for the donor site.

With respect to neurotization of the SSBUN, the choice of donor nerve has successively transitioned from the palmar branch of the median nerve to the common palmar digital nerve (CPDN) of the third web space, allowing for satisfactory grade S3 sensation recovery but with the theoretical risk of palmar anesthesia or dysesthesia at the donor site.<sup>16 18</sup> Due to the small sample size, absence of risk of deficit and/or neuroma to the third CPDN could not be demonstrated.<sup>18</sup>

In 2014, Delclaux et al described a case of double neurotization of UN via transfer of the PIN to the SSBUN, permitting grade S2 sensory recovery without donor-site morbidity at 18 months postoperatively.<sup>19</sup> The greatest strength of this operative technique is its negligible risk of neurological deficit for the donor site. The origin of the most distal motor branch of PIN nerve lies approximately 46.9 mm proximal to the ulnar head.<sup>21</sup> Since the distal portion of the nerve contains exclusively proprioceptive sensory fibers destined to provide sensory innervation to the joint capsule, it can be transferred without risk of subsequent sensory or motor deficit.

With respect to the 16 wrists in the present series, anatomic localization of the PIN was consistent on the radial wall of the fourth extensor compartments (between the extensor digitorum and the extensor pollicis longus) (→ **Figs. 2** and **3**). The mean length of dissection of the PIN was 41 mm from the distal cut edge, quite a distance from the most distal motor branch.<sup>21</sup>

Passage through the interosseous membrane and endoneurial dissection of the UN over a mean distance of 40 mm ensured a reduction in the distance necessary for transfer of the PIN and allowed for terminal-terminal sutures from the PIN to the SSBUN without tension in 100% of cases. Despite the difference in caliber between the two nerves, no difficulties arose during suture placement.

However, this surgical technique requires a two-incision approach, both posterior and anterior with opening of Guyon's canal to mobilize the SSBUN. The tension imparted on the PIN during its transfer, and on the suture, must be minimal to protect the nerve's minimal axonal reserve.<sup>22</sup> Histologic analysis elucidated the limits of this neurotization technique. Of the 16 PIN samples, 10 were found to have limited axonal reserve, while the remaining 6 had none (→ **Fig. 5B**). The absence of axons in six of the PIN samples (37.5% of cases) is a limitation of this technique. We speculate that the PIN could provide limited sensory recovery in 62.5% of cases, consistent with results reported by Delclaux et al.<sup>19</sup> The traction necessary to pass the PIN through the interosseous membrane could have induced axonal loss; this would explain the absence of axons in the six PIN samples. Finally, it should be noted that care should be taken when operating on the elderly since diminished proprioceptive fascicle reserve within the PIN in this group of patients could result in poor corticalization and regional perception outcome.<sup>23 25</sup> The

case report published by Delclaux et al does not seem representation of the expected results of this novel technique; therefore, a larger clinical study is required to establish its possible effectiveness and limitations.<sup>19,25</sup>

Fifty-seven percent of nerve injuries involving upper extremities occur in patients aged 16 to 35 years;<sup>1</sup> therefore, the advanced age of our cadavers together with the anticipated diminished fascicle count rendered our sample non-representative of the target population.<sup>23 25</sup> In addition, microscopic data extracted from slide review were performed by a single operator (P.L.).

## Conclusion

The present cadaveric study describes an alternative, novel strategy for the management of traumatic lesions of the proximal segment of the UN. The distal posterior interosseous nerve possesses the anatomic characteristics necessary to perform surgical transfer to the SSBUN. However, reinnervation potential may be limited by number of proprioceptive axons that the distal PIN possesses.

### Disclosures

All the authors report no conflict of interest concerning the materials or methods used in this study or the findings specified in this article.

### Funding

This research received no specific grant from any funding agency in the public, commercial, or not-for-profit sectors.

### Level of Evidence

The level of evidence is therapeutic IV.

### Contribution of Authors

All the authors (P.L., L.D., S.D., C.A., M.E.T., M.C.S., and P.M.) certify that each author has participated in the content and design of the study, the preparation of the article and its revisions, and final approval.

### Acknowledgment

The authors would like to thank Dina Da Mota (laboratory assistant, Rangueil Medical School, Toulouse University, France) for her technical support for histologic sections. We also would like to thank the persons who donated their bodies to the department of Laboratory of Applied Anatomy (Faculty of Medicine, Toulouse, France), without which this study would not have been possible.

## References

- 1 McAllister RM, Gilbert SE, Calder JS, Smith PJ. The epidemiology and management of upper limb peripheral nerve injuries in modern practice. *J Hand Surg [Br]* 1996;21(01):4-13
- 2 Jaquet JB, Luijsterburg AJ, Kalmijn S, Kuypers PD, Hofman A, Hovius SE. Median, ulnar, and combined median ulnar nerve injuries: functional outcome and return to productivity. *J Trauma* 2001;51(04):687-692

- 3 Bruyns CN, Jaquet JB, Schreuders TA, Kalmijn S, Kuypers PD, Hovius SE. Predictors for return to work in patients with median and ulnar nerve injuries. *J Hand Surg Am* 2003;28(01):28 34
- 4 Roganovic Z. Missile caused ulnar nerve injuries: outcomes of 128 repairs. *Neurosurgery* 2004;55(05):1120 1129
- 5 Murovic JA. Upper extremity peripheral nerve injuries: a Louisiana State University Health Sciences Center literature review with comparison of the operative outcomes of 1837 Louisiana State University Health Sciences Center median, radial, and ulnar nerve lesions. *Neurosurgery* 2009;65(4, Suppl):A11 A17
- 6 Kankaanpää U, Bakalim G. Peripheral nerve injuries of the upper extremity. Sensory return of 137 neurorrhaphies. *Acta Orthop Scand* 1976;47(01):41 45
- 7 Vastamäki M, Kallio PK, Solonen KA. The results of secondary microsurgical repair of ulnar nerve injury. *J Hand Surg [Br]* 1993;18(03):323 326
- 8 Taha A, Taha J. Results of suture of the radial, median, and ulnar nerves after missile injury below the axilla. *J Trauma* 1998;45(02):335 339
- 9 Vordemvenne T, Langer M, Ochman S, Raschke M, Schult M. Long term results after primary microsurgical repair of ulnar and median nerve injuries. A comparison of common score systems. *Clin Neurol Neurosurg* 2007;109(03):263 271
- 10 Lee SK, Wolfe SW. Nerve transfers for the upper extremity: new horizons in nerve reconstruction. *J Am Acad Orthop Surg* 2012;20(08):506 517
- 11 Seiler JG III, Desai MJ, Payne SH. Tendon transfers for radial, median, and ulnar nerve palsy. *J Am Acad Orthop Surg* 2013;21(11):675 684
- 12 Moore AM, Franco M, Tung TH. Motor and sensory nerve transfers in the forearm and hand. *Plast Reconstr Surg* 2014;134(04):721 730
- 13 Patterson JM. High ulnar nerve injuries: nerve transfers to restore function. *Hand Clin* 2016;32(02):219 226
- 14 Haase SC, Chung KC. Anterior interosseous nerve transfer to the motor branch of the ulnar nerve for high ulnar nerve injuries. *Ann Plast Surg* 2002;49(03):285 290
- 15 Novak CB, Mackinnon SE. Distal anterior interosseous nerve transfer to the deep motor branch of the ulnar nerve for reconstruction of high ulnar nerve injuries. *J Reconstr Microsurg* 2002;18(06):459 464
- 16 Battiston B, Lanzetta M. Reconstruction of high ulnar nerve lesions by distal double median to ulnar nerve transfer. *J Hand Surg Am* 1999;24(06):1185 1191
- 17 Brown JM, Yee A, Mackinnon SE. Distal median to ulnar nerve transfers to restore ulnar motor and sensory function within the hand: technical nuances. *Neurosurgery* 2009;65(05):966 977, discussion 977 978
- 18 Flores LP. Distal anterior interosseous nerve transfer to the deep ulnar nerve and end to side suture of the superficial ulnar nerve to the third common palmar digital nerve for treatment of high ulnar nerve injuries: experience in five cases. *Arq Neuropsiquiatr* 2011;69(03):519 524
- 19 Delclaux S, Aprédoaei C, Mansat P, Rongières M, Bonneville P. Case report: double nerve transfer of the anterior and posterior interosseous nerves to treat a high ulnar nerve defect at the elbow. *Chir Main* 2014;33(05):320 324
- 20 Robert M, Blanc C, Gasnier P, Le Nen D, Hu W. Neurotization of the deep branch of ulnar nerve with anterior interosseous nerve: anatomic study [in French]. *Chir Main* 2011;30(06):406 409
- 21 Jariwala A, Krishnan B, Soames R, Wigderowitz CA. Important anatomical relationships of the posterior interosseous nerve in the distal forearm for surgical planning: a cadaveric study. *J Wrist Surg* 2014;3(01):60 63
- 22 Lien SC, Cederna PS, Kuzon WM Jr. Optimizing skeletal muscle reinnervation with nerve transfer. *Hand Clin* 2008;24(04):445 454, vii
- 23 Jacobs JM, Love S. Qualitative and quantitative morphology of human sural nerve at different ages. *Brain* 1985;108(Pt 4): 897 924
- 24 Kanda T, Tsukagoshi H, Oda M, Miyamoto K, Tanabe H. Morphological changes in unmyelinated nerve fibres in the sural nerve with age. *Brain* 1991;114(Pt 1B):585 599
- 25 Verdú E, Ceballos D, Vilches JJ, Navarro X. Influence of aging on peripheral nerve function and regeneration. *J Peripher Nerv Syst* 2000;5(04):191 208