



HAL
open science

Peripheral nerve injury associated with a subdermal contraceptive implant: illustrative cases and systematic review of literature

Pierre Laumonerie, Laurent Blasco, Meagan E. Tibbo, Olivier Leclair,
Panagiotis Kerezoudis, Elodie Chantalat, Pierre Mansat

► To cite this version:

Pierre Laumonerie, Laurent Blasco, Meagan E. Tibbo, Olivier Leclair, Panagiotis Kerezoudis, et al. Peripheral nerve injury associated with a subdermal contraceptive implant: illustrative cases and systematic review of literature. *World Neurosurgery*, 2018, 111, pp.317-325. 10.1016/j.wneu.2017.12.160 . hal-02135137

HAL Id: hal-02135137

<https://hal.science/hal-02135137>

Submitted on 21 May 2019

HAL is a multi-disciplinary open access archive for the deposit and dissemination of scientific research documents, whether they are published or not. The documents may come from teaching and research institutions in France or abroad, or from public or private research centers.

L'archive ouverte pluridisciplinaire **HAL**, est destinée au dépôt et à la diffusion de documents scientifiques de niveau recherche, publiés ou non, émanant des établissements d'enseignement et de recherche français ou étrangers, des laboratoires publics ou privés.




Open Archive Toulouse Archive Ouverte (OATAO)

OATAO is an open access repository that collects the work of some Toulouse researchers and makes it freely available over the web where possible.

This is an author's version published in: <https://oatao.univ-toulouse.fr/23100>

Official URL : <https://doi.org/10.1016/j.wneu.2017.12.160>

To cite this version :

Laumonerie, Pierre and Blasco, Laurent and Tibbo, Meagan E. and Leclair, Olivier and Kerezoudis, Panagiotis and Chantalat, Elodie and Mansat, Pierre  *Peripheral nerve injury associated with a subdermal contraceptive implant: illustrative cases and systematic review of literature.* (2018) *World Neurosurgery*, 111. 317-325. ISSN 1878-8750

Any correspondence concerning this service should be sent to the repository administrator:

tech-oatao@listes-diff.inp-toulouse.fr

Peripheral Nerve Injury Associated with a Subdermal Contraceptive Implant: Illustrative Cases and Systematic Review of Literature

Pierre Laumonerie^{1,2}, Laurent Blasco³, Meagan E. Tibbo⁴, Olivier Leclair⁵, Panagiotis Kerezoudis⁴, Elodie Chantalat^{2,6}, Pierre Mansat¹

Key words

- Contraceptive implant
- Implant removal
- Nerve injury
- Peripheral nerve injury

Abbreviations and Acronyms

IO: Interosseal

MABC: Medial antebrachial cutaneous

MRI: Magnetic resonance imaging

SCI: Subdermal contraceptive implant

US: Ultrasound

From the ¹Department of Orthopaedic Surgery, Institut Locomoteur, Hôpital Pierre Paul Riquet, Toulouse, France;

²Anatomy Laboratory, Department of Orthopaedic Surgery, Faculty of Medicine, Toulouse, France; ³Department of Orthopaedic Surgery, Centre Hospitalier Universitaire de Reims, Reims, France; ⁴Department of Orthopaedic Surgery, Mayo Clinic, Rochester, Minnesota, USA; ⁵Department of Orthopaedic Surgery, Mèdipôle de Koutio, New Caledonia, France; and ⁶Department of Gynecological Surgery, Hôpital Paul de Viguier, Toulouse, France

To whom correspondence should be addressed: Pierre Laumonerie, M.D.

[E mail: laumonerie.p@chu.toulouse.fr]

INTRODUCTION

Use of subdermal contraceptive implants (SCIs) has been steadily increasing for approximately a decade.¹ The first SCI (Norplant; Wyeth-Ayerst International Inc., Wayne, Pennsylvania, USA) was approved in 1983 and consisted of 6 rods placed subcutaneously into the medial side of the nondominant arm. Norplant was followed by a succession of innovative SCIs, including 2-rod (Jadelle; Bayer Healthcare, Leverkusen, Germany, and Sino-implant; Shanghai Dahua Pharmaceuticals Co., Shanghai, China) and subsequently single-rod (Nexplanon and Implanon; Merck, Darmstadt, Germany) designs with a length of 40 mm and a diameter of 2 mm. These innovations significantly reduced insertion and

■ **BACKGROUND:** Despite demonstrable safety and efficacy of subdermal contraceptive implants (SCIs), both insertion and removal of SCIs in the arm have been associated with neurovascular complications. The aim of this study was to investigate type and prognosis of nerve injuries associated with SCIs.

■ **METHODS:** We performed a comprehensive search of 4 electronic databases for studies pertaining to patients with nerve injury and concurrent SCI. Studies published between January 1987 and June 2017 were included. Implant location, damaged nerves, clinical presentation, preoperative imaging (x-ray, ultrasound, magnetic resonance imaging), neurologic evaluation (nerve conduction studies, electromyography), and treatment methods were reviewed. To outline management strategies, 2 illustrative cases of major nerve injury caused by SCI removal were presented.

■ **RESULTS:** We analyzed 10 studies including 12 patients. Fourteen nerve injuries in 12 patients were reported during SCI insertion ($n = 1$) and removal ($n = 11$). Medial antebrachial cutaneous ($n = 5$) and median ($n = 5$) nerves were primarily affected. Neuropathic pain was the main symptom. Primary reasons for nerve injury were pulling or grasping of the nerve ($n = 9$) after mistaking it for the implant. Neurapraxia ($n = 7$) was the most common lesion and was treated with implant removal and clinical surveillance ($n = 6$). Five patients completely recovered; the remaining patients continued to have motor and/or sensory deficit at mean follow-up of 0.7 year (range, 0–2 years).

■ **CONCLUSIONS:** Nerve injuries related to SCIs are rare but potentially serious. For nonpalpable SCIs, a multidisciplinary approach, including practitioners with experience treating peripheral nerve injuries, is invaluable.

removal time as well as complexity. However, as procedural standardization occurred, surgeons and obstetrician-gynecologists became less and less involved in the insertion of SCIs in favor of general practitioners and midwives.^{2–6}

Adverse events related to insertion, localization, and removal of the SCI are rare, affecting 1% of insertions and 1.7% of removals, respectively.⁷ The manufacturer of Nexplanon implants estimates that intravascular placement has occurred in just over 1 patient per 1 million Nexplanon implants sold.⁸ However, given the recommended site of implantation, neurovascular injuries remain a potential complication for both SCI insertion and removal.⁹ In this

article, we present a systematic review of the literature on nerve injuries associated with SCIs. We also describe 2 patients at our institution who sustained significant nerve injuries during removal of SCIs; these serve as illustrative cases in an effort to demonstrate our approach to the treatment of these injuries. The primary aim of this study was to investigate the types of nerve injuries associated with SCIs.

MATERIALS AND METHODS

Illustrative Cases

Between 1983 and 2017, 2 patients with serious nerve injuries resulting from SCI

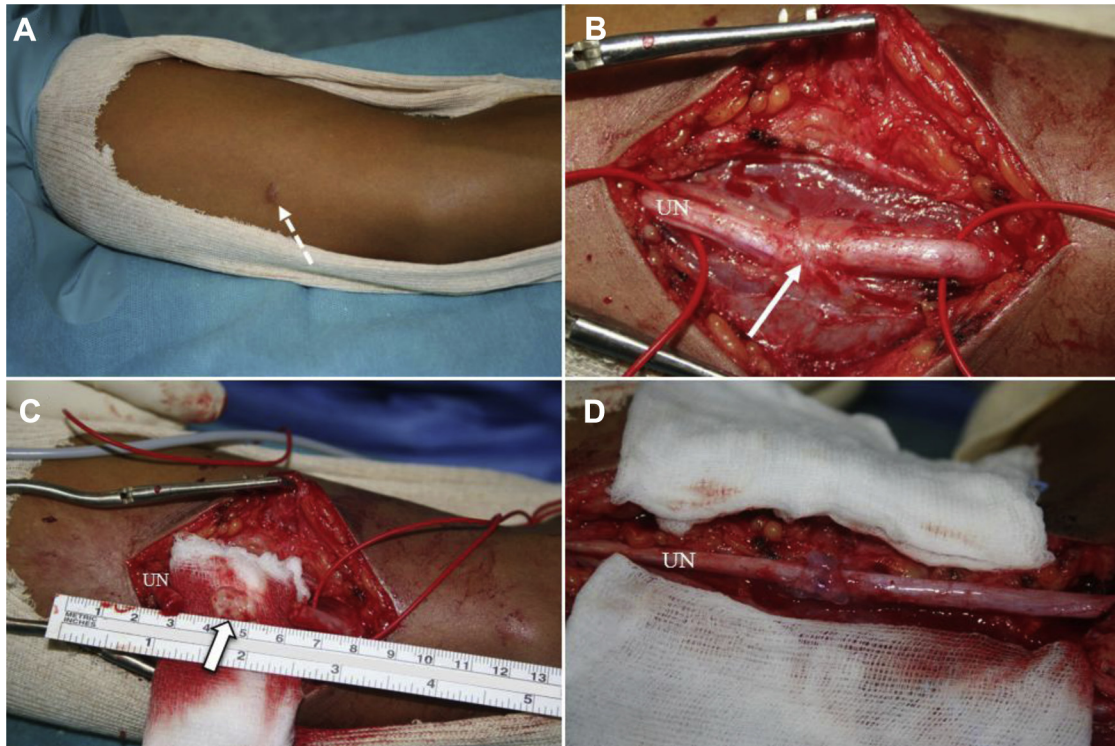


Figure 1. Case 1. (A) Preoperative photograph depicting prior incision (arrow) used to insert the subdermal contraceptive implant into the medial aspect of the arm. (B) Intraoperative

image of the ulnar nerve (arrow). (C and D) Close up of the ulnar nerve neuromas (arrow). UN, ulnar nerve.

insertion were treated at our institution (Médipôle de Koutio, Nouvelle-Calédonie, France); their cases were retrospectively reviewed. The SCIs were inserted at another institution, and the patients were referred to a peripheral nerve specialist (O.L.) in our department to remove the device and treat resulting nerve injuries. Records pertaining to consultations, hospitalizations, and surgical interventions in addition to laboratory examination data (nerve conduction studies and electromyography, ultrasound [US], magnetic resonance imaging [MRI]) were reviewed for each case by an orthopaedic surgeon (P.L.) with experience in peripheral nerve surgery.

Case 1. A 25-year-old woman was referred to our department after experiencing radiating pain in the ulnar nerve distribution during removal of an expired SCI (Figure 1). The Implanon device was palpable on the medial aspect of the arm and had been removed under local anesthesia by a midwife in clinic. Immediately postoperatively, the patient was unable to

fire the palmar and dorsal interossei (IO), flexor carpi ulnaris, or flexor digitorum profundus (fourth and fifth digits) muscles; she had a positive Froment sign and grade S3 sensory loss over the ulnar aspect of the palm (according to the British Medical Research Council). The aforementioned findings were initially diagnosed by the treating physician and subsequently confirmed by a neurologist. At 1 month, atrophy of IO and flexible ulnar claw posturing were also reported. Electrophysiologic testing confirmed a severe sensorimotor ulnar neuropathy. The first dorsal IO and abductor digiti minimi demonstrated 3+ fibrillations without activation. Sensory recordings were significant for persistence of low-amplitude signals (25 mV). US revealed fusiform enlargement of the ulnar nerve fascicle as it coursed over the distal third of the arm.

Owing to lack of improvement, surgical exploration under general anesthesia was performed 2 months later. The ulnar nerve was in continuity with a 1-cm neuroma.

No nerve action potential was recorded across the lesion. Resection of the neuroma was performed to expose healthy nerve tissue (1.5 cm); histologic examination later confirmed the diagnosis of neuroma. A 15-cm external neurolysis in addition to subcutaneous transposition were performed. The nerve was repaired using a 10-0 nonabsorbable monofilament epiperineurial suture in an interrupted fashion. At 12 months postoperatively, extrinsic and intrinsic muscles had grade M3 (British Medical Research Council) strength, and ulnar clawing was diminished. Partial sensory recovery was obtained (S3+ according to the British Medical Research Council), but the patient's ulnar paresthasias persisted. Sequential postoperative electromyograms documented reinnervation of ulnar nerve.

Case 2. A 31-year-old woman was referred to our department for a sensorimotor deficit occurring after failed removal of her SCI (Figure 2). The procedure had been performed in the operating room under

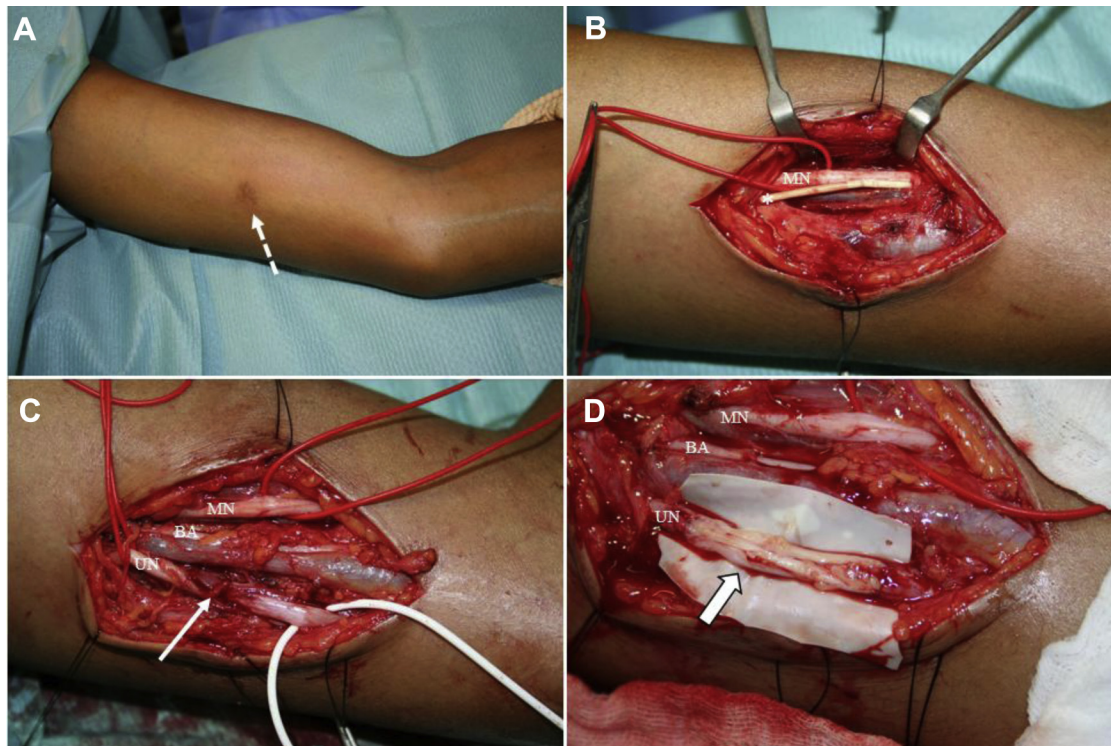


Figure 2. Case 2. (A) Preoperative photograph depicting previous incision (arrow) over the subdermal contraceptive implant on the medial aspect of the arm. (B) Intraoperative photograph showing the subdermal contraceptive implant

(asterisk) in contact with the median nerve. (C and D) The ulnar nerve after neuroma resection (arrow in C) at the time of implant removal was treated with a sural nerve graft (arrow in D). MN, median nerve; BA, brachial artery; UN, ulnar nerve.

regional anesthesia by a gynecologist; preoperative US did not allow for identification of the nonpalpable implant. The gynecologist noted resistance after pulling on a nerve rather than the implant; the patient described at that moment radiating pain in the ulnar nerve distribution. At 1 month postoperatively, weakness involving the IO, flexor carpi ulnaris, and flexor digitorum profundus (fourth and fifth digits) was graded 2 (IO), 0 (flexor carpi ulnaris), and 3 (flexor digitorum profundus). Flexible ulnar clawing and Froment sign were noted. The patient reported neuropathic pain and grade S4 and S0 sensory loss involving the fourth and fifth digits, respectively. At 6 months, atrophy of the hypothenar eminence and all IO was noted. Electrophysiologic testing confirmed a severe ulnar neuropathy without signs of reinnervation. MRI demonstrated fusiform enlargement of the ulnar nerve fascicle in addition to

migration of the implant toward the distal third of the medial arm.

Surgical exploration was performed 7 months later owing to lack of improvement and necessity of implant removal. Preoperative US-guided hook-wire marking of the implant was performed; this facilitated removal of the nonpalpable implant. The ulnar nerve had a 1.5-cm neuroma in continuity at the site of putative injury. No nerve action potential was recorded across the lesion. The neuroma was resected to expose healthy nerve tissue; subsequently, interposition sural nerve grafting was performed. Follow-up demonstrated continued clinical improvement. By 11 months postoperatively, there was resolution of ulnar clawing and there were improvements in both intrinsic and extrinsic muscle strength (IO, grade 4; flexor carpi ulnaris, grade 5; flexor digitorum profundus fourth and fifth digits, grades 3 and 0). The patient also experienced sensory recovery (S3+ in fourth digit

and S3 in fifth digit) and resolution of neuropathic pain. Sequential postoperative electromyograms demonstrated reinnervation changes in the ulnar nerve.

Literature Review

Literature Search Strategy. A literature search was performed using Medical Subject Headings and keywords in the following databases: Ovid Medline, Ovid Embase, Scopus, Web of Science, and Cochrane. The search was limited to English language literature; the terms “peripheral nerve injury,” “contraception” were combined with AND and OR. The references in each study were reviewed to identify additional articles corresponding to the research criteria.

Selection Criteria. Articles included in the present study were limited to articles that discussed nerve injuries caused by SCIs published between January 1988 and 2017. Studies in a language other than English or

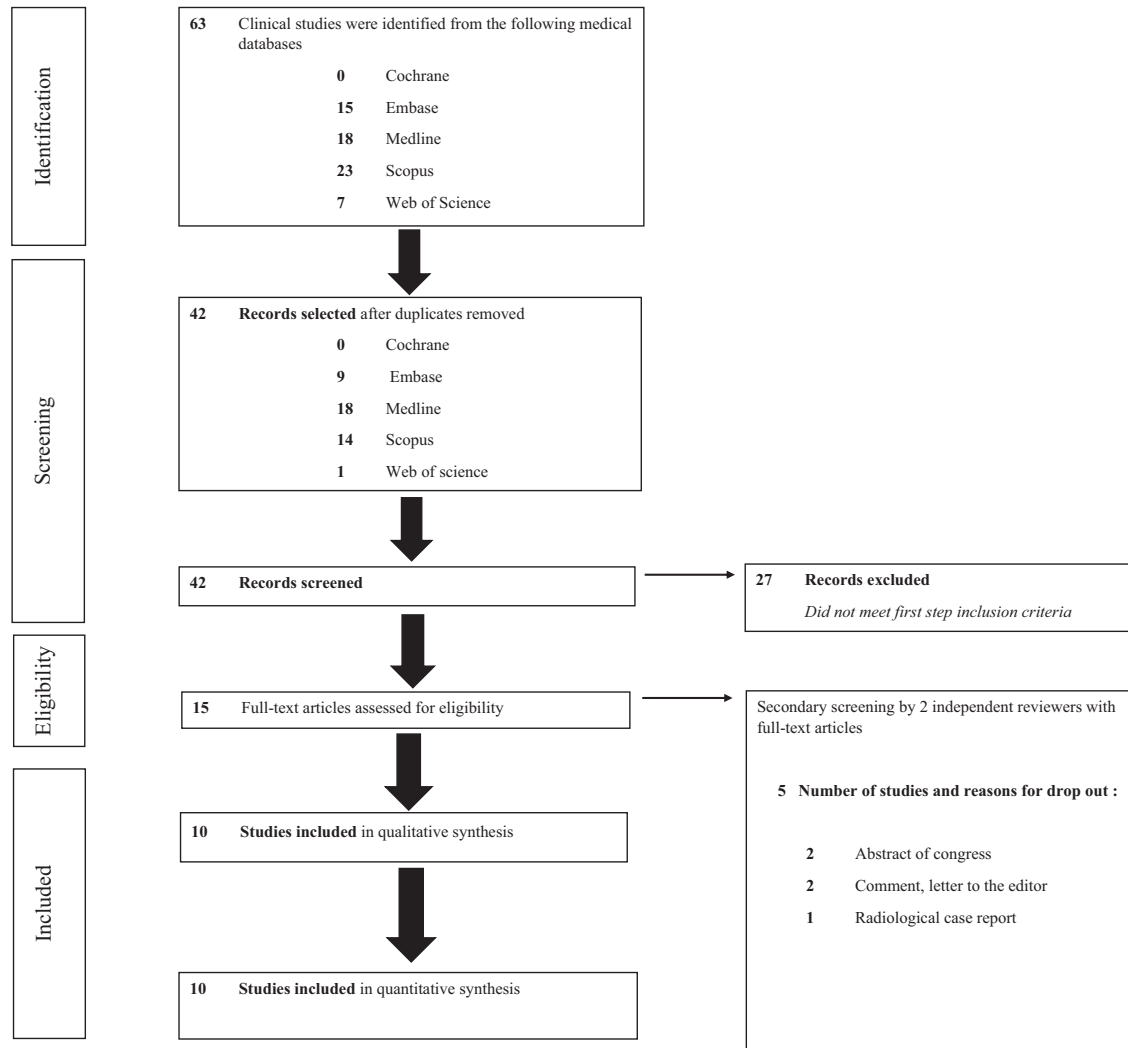


Figure 3. Preferred Reporting Items for Systematic Reviews and Meta Analyses flow chart summarizing search strategy for

relevant studies on peripheral nerve injuries caused by subdermal contraceptive implants.

with inadequate design (meta-analysis, review of the literature, abstract for meetings) and studies centered exclusively on the radiographic method of localization and/or on removal techniques of nonpalpable contraceptive implants were excluded.

Data Extraction and Critical Appraisal. Data were extracted from article text, tables and figures. Two investigators (P.L. and L.B.) independently reviewed the full text of all eligible articles. Disagreements between the 2 reviewers were resolved via discussion and consensus. When information was incomplete, the corresponding authors of the articles were contacted. Data extracted from the articles included a

description of the nerve injuries, contraceptive implants (model and location), preoperative clinical and radiographic presentation, surgical management, and midterm to long-term clinical outcomes following surgery. Level of evidence in the included studies was assessed using the criteria established by Oxford Centre for Evidence-based Medicine Levels of Evidence.¹⁰

RESULTS

Quality of Studies

Our electronic search yielded 63 studies. After applying inclusion and exclusion

criteria, 15 articles underwent full-text evaluation. After detailed evaluation, 8 case reports (level of evidence V) and 2 case series (level of evidence IV) were included in the analysis. A summary of the search strategy is presented in **Figure 3**.

Population Characteristics

The cohort consisted of 12 patients with a mean age of 29.8 years (range, 19–44 years) who were evaluated at a mean follow-up of 0.7 year (range, 0–2 years); 1 patient was lost to follow-up.⁸ Norplanon (n = 4), Implanon (n = 4), and Nexplanon (n = 4) SCIs were implanted in the nondominant arm (8 left and 2 right; not available for 2 cases) either

Table 1. Patient Characteristics in 10 Articles Describing Peripheral Nerve Injuries Secondary to Subdermal Contraceptive Implants Published Between January 1988 and June 2017

Study	Characteristics								
	Country	Patients			Subdermal Contraceptive Implant				
		Age (years)	Upper Limb	Prior Removal Attempts	Implant Model	Inserted by	Site	Depth	Palpable
Smith et al., 1998 ¹⁸	USA	23	Right	0	Norplant	Gynecologist	Medial aspect of arm	Subcutaneous	Yes
Sarma et al., 1998 ¹⁹	USA	36	Left	1	Norplant	Gynecologist	Medial aspect of arm	Subfascial	No
Marin and McMillian, 1998 ²⁰	USA	17	Left	1	Norplant	Gynecologist	Medial aspect of arm	Subfascial	No
Nash and Staunton, 2001 ²¹	United Kingdom	33	Left	1	Norplant	NA	Medial aspect of arm	Subcutaneous	NA
Wechselberger et al., 2006 ¹⁶	Austria	24	Left	1	Implanon	Gynecologist	Medial aspect of arm	Subfascial	No
Gillies et al., 2011 ¹³	Australia	44	NA	1	Implanon	General practitioner	Medial aspect of arm	Subcutaneous	No
		26	NA	1	Implanon	General practitioner	Medial aspect of arm	Subcutaneous	No
Brown and Britton, 2012 ¹²	United Kingdom	26	Right	1	Implanon	NA	Medial aspect of arm	Subcutaneous	No
Restrepo and Spinner, 2016 ¹⁷	USA	19	Left	0	Nexplanon	Gynecologist	Medial aspect of arm	Subcutaneous	No
Belyea et al., 2017 ¹¹	USA	39	Left	2	Nexplanon	Gynecologist	Medial aspect of arm	Subfascial	No
Odom et al., 2017 ¹⁴	USA	36	Left	4	Nexplanon	Gynecologist	Medial aspect of arm	Subfascial	No
		25	Left	1	Nexplanon	Gynecologist	Medial aspect of arm	Subfascial	Yes

NA, not available.

subcutaneously (n = 6) or beneath the fascia (n = 6). The implants were not palpable in 7 patients; this information was not available for 1 case. All patients had an abnormal clinical examination or additional study findings. Neuropathic pain (n = 12) was identified in all patients. Clinical examination revealed paresthesias in 11 patients, weakness in 6 patients, and sensory loss in 8 patients. Electrodiagnostic studies were performed in symptomatic patients (n = 4) either before or after device removal. Ultrasound images (n = 8) and/or radiographs (n = 2) were sufficient to localize the implant in 7 patients^{8,11-16} and, later, to better describe the nerve injury in 1 patient.¹⁷ No patient underwent preoperative MRI. Population characteristics are reported in **Tables 1** and **2**.

Peripheral Nerve Injuries

There were 14 peripheral nerve injuries associated with SCIs reported during or after insertion (n = 2) and removal (n = 12) procedures; no associated lesions

were reported. The 2 most commonly injured nerves were the medial antebrachial cutaneous (MABC) nerve (n = 5) and median nerve (n = 5). Nerve injury was primarily due to pulling or grasping of the nerve (n = 9) after mistaking it for the implant. Neurapraxia (n = 7) was the most common lesion and was treated primarily with implant removal and clinical surveillance (n = 6). Nerve coaptation (n = 2) was performed for partial nerve transection. Neurolysis (external neurolysis [n = 1] or epineurolysis [n = 1]) was performed to treat neuroma or nerve compression by scar tissues and/or SCIs. Of patients, 5 completely recovered, and 6 continued to have a motor and/or sensory deficit at short-term to long-term follow-up; 1 patient was lost to follow-up.¹⁹ No additional interventions were performed for the treatment of sequelae. Management by a pain specialist was requested in 1 case owing to persistent dysesthesia and paresthesia in the hand 4 months after coaptation of the median nerve.²² The results are summarized in **Table 2**.

DISCUSSION

Difficulties encountered during the removal of SCIs have stimulated intensive research into the development of easy-to-use systems.^{9,23} The development of these new devices will likely reduce the incidence of insertion site complications.^{9,24,25} Although rare, SCIs have the potential to cause serious peripheral nerve injuries during insertion and removal.^{11,14,17} The broader, more common spectrum of adverse implant site reactions include pain, hematoma, swelling, redness, and scarring.^{4,26} These complications were described in 5.9% of women within the first few years after SCI insertion and/or removal.²⁷ The insertion procedure is straightforward and can typically be performed in the office. Implants must be inserted into the subcutaneous space on the medial aspect of the nondominant arm 8–10 cm proximal to the medial epicondyle under local anesthesia via a disposable sterile applicator. The SCI must be palpable throughout the duration of its use.^{15,23}

After a maximum of 3 years, the palpable implant is removed under local anesthesia through a small incision at the distal end of the rod. Manual pressure is applied to the proximal end of the device to push it through the 2-mm incision and grasp it with forceps as it appears; no dissection is required.^{4,5,15,28,29}

In the medial aspect of the midarm, neurovascular structures are separated from one another by the brachialis fascia that divides the arm into superficial and deep compartments. The MABC nerve lies within the subcutaneous space along with the basilic vein.¹⁶ The MABC nerve courses within the anterior proximal arm, medial to the brachial artery; it becomes a subcutaneous structure when it pierces the brachial fascia (basilica hiatus) 14 cm proximal to the medial epicondyle. SCIs are typically inserted in this vicinity; therefore, it follows that incorrect subcutaneous positioning of the implant may induce damage to the branches of the MABC nerve (anterior, or ulnar).^{16,30} The subaponeurotic course of the MABC nerve also places it at risk for injury owing to accidental traction at the time of implant removal. The spectrum of injuries to the MABC nerve described in the literature is broad, ranging from neurapraxia to complete nerve transection (Table 2). Clinical symptoms are also variable and may include impaired sensation. An area of localized, severe pain in the distribution of the MABC nerve may occur in the case of a transected nerve trapped in scar tissue.¹⁶ Neurovascular structures beneath the fascia are also at risk; these structures include the brachial artery and terminal branches of brachial plexus (Figures 1 and 2, Table 2). Accidental traction on the nerve rather than the implant at the time of removal and nerve compression are the 2 primary reasons for incomplete injuries. Nerve transection ($n = 6$) is the second most common injury pattern and affecting the median and/or ulnar nerves overall; emergent surgical treatment should be the rule in this setting because of the risk of neuroma formation (Figures 1 and 2, Table 2).

Although previous reports quote migration rates reaching 39%,³¹ a recently published study of 4294 practitioners demonstrated migration in only 0.26% of

cases,² with most implants migrating <2 cm from the initial insertion site. Too-deep initial positioning and/or migration of the implant may lead to difficulty with localization via palpation at the time of implant removal. In our study, 83% of nerve injuries involved patients with nonpalpable implants. A standardized clinical and radiographic evaluation should be undertaken to locate the nonpalpable SCI, the neurovascular structures, and possible associated lesions to facilitate safe implant removal.^{14,24} Neurovascular sequelae resulting from insertion or removal of a SCI must be identified at the time of initial evaluation for patients requesting a new device. Scarring induced by a malpositioned implant can also place pressure on the nerve at a distance from the SCI insertion site.^{20,21} Clinical assessment should include a detailed history to accurately understand the patient's symptoms as well as attempted implant palpation; this provides an initial impression regarding the location of possible nerve injuries. Neuropathic pain at the level of the upper arm or a history of SCI use should prompt the physician to suspect nerve injury. Any loss of distal sensory and motor function associated with insertion or removal of an SCI should be treated as a suspected serious nerve injury and addressed within days (Table 2); any delay in treatment exposes patients to the risk of neuroma formation (Figure 1C).¹⁷ Recent literature describes the use of various methods to localize nonpalpable SCIs, including x-rays, US, computed tomography, and MRI.^{1,14,20,24,26,32-36} US examination should be considered the first-line imaging because of its low cost, lack of ionizing radiation, and wide availability.^{24,37} MRI is the best method for unequivocal localization of implants not detectable on US.^{24,35,37} High-resolution 3T MRI with T₁-weighted, T₂-weighted, or gradient echo sequences (spoiled gradient recalled echo) with robust fat suppression, with and without gadolinium enhancement is the recommended second-line imaging for implant localization and peripheral nerve imaging.^{24,37} Despite the fact that US was used in 75% of patients in this study, no diagnostic MRI studies have been reported in the literature. In cases where intraoperative implant localization is challenging, extensive dissection must be avoided. We

recommend intraoperative US-guided hook-wire marking of the implant by an experienced musculoskeletal radiologist to facilitate safe dissection.³⁸ For symptomatic patients, nerve conduction studies and electromyography can assist further by determining the severity of the injury and confirming its location; these studies also allow for improved clinical follow-up of patients in whom lesions are treated with or without surgery.

All nerve injuries that occurred during the removal of nonpalpable SCIs were caused by providers without formal microsurgical training (Table 2). Given the risks of neurovascular injury with nonpalpable SCIs, we recommend asking a peripheral nerve specialist for assistance with removal.^{14,24} In the event that an inadvertent nerve injury is suspected, immediate action should be undertaken. We avoid local anesthetics and paralytics, as they preclude intraoperative nerve stimulation. In the present study, 75% of nerve injuries were associated with accidental traction (pulling or grasping) on the nerve when it was mistaken for the SCI. For this reason, we advocate for wide operative exposure, avoiding grasping the nonpalpable implant with surgical instruments until it has been identified in its entirety and separated from adjoining tissues (Figure 1, Tables 1 and 2).¹⁷ For patients with clinical or electromyographic evidence of nerve injury, the nerves in close proximity to the implant must be exposed and inspected. A nerve stimulator (Vari-Stim III Nerve Locator; Medtronic Xomed, Inc., Jacksonville, Florida, USA) is needed to identify abnormally functioning nerves in cases where no striking visual abnormality is present intraoperatively. When complete nerve transection is encountered, timely surgical repair should be performed using 9-0 or 10-0 epineural nonabsorbable monofilament suture placed in an interrupted fashion under direct visualization with surgical loupes or a microscope.³² When direct repair is not feasible, a graft must be used (Figure 1). Neurotization and/or tendon transfer should be considered for proximal nerve transections with motor deficits lasting >6 months.^{22,32,39} In the case of superficial lesions, if primary nerve coaptation of the MABC nerve is not possible, its proximal end should be

Table 2. Summary of Various Treatment Approaches in 10 Articles Describing Neurovascular Complications After Subdermal Contraceptive Implant Insertion and/or Removal Published Between January 1988 and June 2017

Study	Nerve		Injury			Treatment			
	Nerves Involved	Lesion	Timing	Mechanism of Injury	Treating Provider	Treatment	Times to Treatment (months)	Treating Provider	Functional Outcomes
Smith et al., 1998 ¹⁸	Ulnar	Contusion by needle ("U" technique) ³	Removal	Nerve contusion	Gynecologist	Clinical and physiologic surveillance		Neurologist	Residual deficit
Sarma et al., 1998 ¹⁹	Median	Neurapraxia	Second removal attempt	Pulling/grasping on nerve	Gynecologist	Implant removal and clinical surveillance	1	Interventional radiologist	Lost to follow up
Marin and McMillian, 1998 ²⁰	Ulnar	Neurapraxia	After removal	Compression by scar tissues	Gynecologist	Epineurolysis	1	NA	Residual deficit
Nash and Staunton, 2001 ²¹	MABC	Neurapraxia	After insertion	Compression by implant and/or scar tissues	NA	Implant removal and clinical and physiologic surveillance		NA	Residual deficit
Wechselberger et al., 2006 ¹⁶	MABC	Partial section	Attempted removal	Pulling/grasping on nerve	Gynecologist	Implant removal and nerve coaptation	NA	Plastic surgeon	Full recovery
Gillies et al., 2011 ¹³	Median	Partial section	Attempted removal	Pulling/grasping on nerve	Gynecologist	Implant removal and nerve coaptation	0.4 (12 days)	Hand surgeon	Residual deficit
	Median	Partial section	Attempted removal	Pulling/grasping on nerve	Gynecologist	Implant removal and nerve coaptation	0.03 (1 day)	Hand surgeon	Residual deficit
Brown and Britton, 2012 ¹²	MABC	Neurapraxia	Insertion	Compression by implant	NA	Implant removal and clinical surveillance	24	Orthopaedic surgeon	Full recovery (immediate postprocedure)
Restrepo and Spinner, 2016 ¹⁷	MABC, median, and ulnar	Sections (<i>n</i> = 3) complicated by neuromas (<i>n</i> = 3)	Removal	Pulling/grasping on nerve	Gynecologist	External neurolysis (median, ulnar, and MABC)	5	Neurosurgeon	Full recovery (ulnar nerve); residual deficit (MABC, median nerves)
Belyea et al., 2017 ¹¹	Median nerve	Neurapraxia	Second removal attempt	Pulling/grasping on nerve	Gynecologist	Implant removal and clinical surveillance	NA	Orthopaedic surgeon	Full recovery
Odom et al., 2017 ¹⁴	NA	Neurapraxia	Fourth removal attempt	Pulling/grasping on nerve	Gynecologist	Implant removal and clinical surveillance	NA	Plastic surgeon	Full recovery
	MABC	Neurapraxia	Removal attempt	Pulling/grasping on nerve and/or compression by implant	Gynecologist	Implant removal and clinical surveillance	0.1 (3 days)	Plastic surgeon	Full recovery

NA, not available; MABC, medial antebrachial cutaneous.

transposed proximally and buried deep into the muscle of the arm to avoid formation of a painful neuroma.^{16,40}

Limitations

The limitations of this study relate to its retrospective, single-center nature and sample size. The retrospective design inherently leads to more loss of data and bias. Owing to the small number of cases and the nature of this study, specific recommendations for surgical treatment cannot be established. Follow-up was of short duration for most patients (mean 0.7 year; range, 0–2 years), and neurologic data were sparse; this did not allow for a reliable analysis of postoperative outcomes after treatment of these injuries.

Lessons Learned

All patients with nonpalpable SCIs are at risk for serious nerve injury and require a thorough preoperative imaging evaluation and referral to a peripheral nerve specialist. Neuropathic arm pain in a patient with an SCI should prompt the clinician to suspect a nerve injury until proven otherwise. In the setting of deep, nonpalpable implants, a large incision that sufficiently exposes the entirety of the SCI is advised to avoid accidental injury to neighboring neurovascular structures. A handheld electrical stimulator may also be useful in cases where nerve injury is suspected.

Future Directions

To further improve on the safety of contraceptive implants, we should consider revising the recommended area of implantation provided by manufacturer (a minimum of 8 cm above the medial epicondyle) to avoid vulnerable nerves and vessels of the medial arm.¹⁴ Placement over the body of the biceps brachii or into the medial thigh are possible alternatives, but both may be cosmetically unappealing.^{19,41} Wechselberger et al.¹⁶ speculated that Implanon insertion into the medial supraumbilical region through the umbilicus might be an ideal way to prevent scarring and eliminate the risk of neurovascular injury. Both etonogestrel contraceptive implants are off-white and visually similar to nerves and blood vessels. We advocate changing the color of the device to the green or turquoise used during the manufacturer training programs required by the U.S. Food and Drug

Administration to avoid confusion at the time of implant removal.¹⁴

CONCLUSIONS

Nerve injuries related to SCIs are rare but serious. In cases of nonpalpable implants, a multidisciplinary approach including practitioners with expertise in the treatment of peripheral nerve lesions is invaluable.

ACKNOWLEDGMENTS

We thank Ms. Ann Farrell (Mayo Clinic Library, Rochester, Minnesota, USA) for her help with the electronic search and abstract compilation.

REFERENCES

1. Kavanaugh ML, Jerman J, Finer LB. Changes in use of long-acting reversible contraceptive methods among U.S. women, 2009-2012. *Obstet Gynecol.* 2015;126:917-927.
2. Darney PD. Implantable contraception. *Eur J Contracept Reprod Health Care.* 2000;5(suppl 2):2-11.
3. Fischer MA. Implanon: a new contraceptive implant. *J Obstet Gynecol Neonatal Nurs.* 2008;37:361-368.
4. Levine JP, Sinofsky FE, Christ MF, Implanon US Study Group. Assessment of Implanon insertion and removal. *Contraception.* 2008;78:409-417.
5. Mascarenhas L. Insertion and removal of Implanon: practical considerations. *Eur J Contracept Reprod Health Care.* 2000;5(suppl 2):29-34.
6. Power J, French R, Cowan F. Subdermal implantable contraceptives versus other forms of reversible contraceptives or other implants as effective methods of preventing pregnancy. *Cochrane Database Syst Rev.* 2007;3:CD001326.
7. Darney P, Patel A, Rosen K, Shapiro LS, Kaunitz AM. Safety and efficacy of a single-rod etonogestrel implant (Implanon): results from 11 international clinical trials. *Fertil Steril.* 2009;91:1646-1653.
8. Rowlands S, Mansour D, Walling M. Intravascular migration of contraceptive implants: two more cases. *Contraception.* 2017;95:211-214.
9. Wehrle KE. The Norplant System: easy to insert, easy to remove. *Nurse Pract.* 1994;19:47-54.
10. Howick J, Chalmers I, Glasziou P, Greenhalgh T, Heneghan C, Liberati A, et al. The 2011 Oxford CEBM Levels of Evidence (Introductory Document) 2011. Available at: <http://www.cebm.net/index.aspx?o=5653>. Accessed April 29, 2014.
11. Belyea C, Ernat J, Gumboc R. Removal of a contraceptive implant from the brachial neurovascular sheath. *J Hand Surg.* 2017;42:e115-e117.
12. Brown M, Britton J. Neuropathy associated with etonogestrel implant insertion. *Contraception.* 2012;86:591-593.

13. Gillies R, Scougall P, Nicklin S. Etonogestrel implants case studies of median nerve injury following removal. *Aust Fam Physician.* 2011;40:799-800.
14. Odom EB, Eisenberg DL, Fox IK. Difficult removal of subdermal contraceptive implants: a multidisciplinary approach involving a peripheral nerve expert. *Contraception.* 2017;96:89-95.
15. Rowlands S. Legal aspects of contraceptive implants. *J Fam Plann Reprod Health Care.* 2010;36:243-248.
16. Wechselberger G, Wolfram D, Püzl P, Soelder E, Schoeller T. Nerve injury caused by removal of an implantable hormonal contraceptive. *Am J Obstet Gynecol.* 2006;195:323-326.
17. Restrepo CE, Spinner RJ. Major nerve injury after contraceptive implant removal: case illustration. *J Neurosurg.* 2016;124:188-189.
18. Smith JM, Conwit RA, Blumenthal PD. Ulnar nerve injury associated with removal of Norplant implants. *Contraception.* 1998;57:99-101.
19. Sarma SP, Silverstein M, Lewis C. Removal of a Norplant implant located near a major nerve using interventional radiology-digital subtraction fluoroscopy. *Contraception.* 1998;58:387-389.
20. Marin R, McMillian D. Ulnar neuropathy associated with subdermal contraceptive implant. *South Med J.* 1998;91:875-878.
21. Nash C, Staunton T. Focal brachial cutaneous neuropathy associated with Norplant use: suggests careful consideration of the recommended site for inserting contraceptive implants. *J Fam Plann Reprod Health Care.* 2001;27:155-156.
22. Giuffre JL, Bishop AT, Spinner RJ, Shin AY. The best of tendon and nerve transfers in the upper extremity. *Plast Reconstr Surg.* 2015;135:617e-630e.
23. Walling M. Inserting the etonogestrel contraceptive implant. *J Fam Plann Reprod Health Care.* 2016;42:75.
24. Shulman LP, Gabriel H. Management and localization strategies for the nonpalpable Implanon rod. *Contraception.* 2006;73:325-330.
25. Voedisch A, Hugin M. Difficult implant removals. *Curr Opin Obstet Gynecol.* 2017;29:449-457.
26. Chen MJ, Creinin MD. Removal of a nonpalpable etonogestrel implant with preprocedure ultrasonography and modified vasectomy clamp. *Obstet Gynecol.* 2015;126:935-938.
27. Klavon SL, Grubb GS. Insertion site complications during the first year of NORPLANT use. *Contraception.* 1990;41:27-37.
28. Pearson S, Stewart M, Bateson D. Implanon NXT: expert tips for best-practice insertion and removal. *Aust Fam Physician.* 2017;46:104-108.
29. Pymar HC, Creinin MD, Schwartz JL. "Pop-out" method of levonorgestrel implant removal. *Contraception.* 1999;59:383-387.
30. Benedikt S, Parvizi D, Feigl G, Koch H. Anatomy of the medial antebrachial cutaneous nerve and its

- significance in ulnar nerve surgery: an anatomical study. *J Plast Reconstr Aesthet Surg.* 2017;70:1582-1588.
31. Ismail H, Mansour D, Singh M. Migration of Implanon. *J Fam Plann Reprod Health Care.* 2006;32:157-159.
 32. Fox IK, Mackinnon SE. Adult peripheral nerve disorders: nerve entrapment, repair, transfer, and brachial plexus disorders. *Plast Reconstr Surg.* 2011;127:105e-118e.
 33. Kang W, Hian Tan K. A simple technique for localization of deeply inserted, nonpalpable Norplant implant. *Contraception.* 2005;71:392-394.
 34. Mansour D, Fraser IS, Walling M, Glenn D, Graesslin O, Egarter C, et al. Methods of accurate localisation of non-palpable subdermal contraceptive implants. *J Fam Plann Reprod Health Care.* 2008;3:9-12.
 35. Persaud T, Walling M, Geoghegan T, Buckley O, Stunell H, Torreggiani WC. Ultrasound-guided removal of Implanon devices. *Eur Radiol.* 2008;18:2582-2585.
 36. Singh M, Mansour D, Richardson D. Location and removal of non-palpable Implanon implants with the aid of ultrasound guidance. *J Fam Plann Reprod Health Care.* 2006;32:153-156.
 37. Merki-Feld GS, Brekenfeld C, Migge B, Keller DJ. Nonpalpable ultrasonographically not detectable Implanon rods can be localized by magnetic resonance imaging. *Contraception.* 2001;63:325-328.
 38. Nouri K, Pinker-Domenig K, Ott J, Fraser I, Egarter C. Removal of non-palpable Implanon® with the aid of a hook-wire marker. *Contraception.* 2013;88:577-580.
 39. Korus L, Ross DC, Doherty CD, Miller TA. Nerve transfers and neurotization in peripheral nerve injury, from surgery to rehabilitation. *J Neurol Neurosurg Psychiatry.* 2016;87:188-197.
 40. Stahl S, Rosenberg N. Surgical treatment of painful neuroma in medial antebrachial cutaneous nerve. *Ann Plast Surg.* 2002;48:154-158.
 41. Adkinson JM, Talsania JS. Ulnar nerve ligation after removal of Norplant: a case report. *Hand (NY).* 2013;8:92-96.

Conflict of interest statement: The authors declare that the article content was composed in the absence of any commercial or financial relationships that could be construed as a potential conflict of interest.