



HAL
open science

How the greater tuberosity affects clinical outcomes after reverse shoulder arthroplasty for proximal humeral fractures

Xavier Ohl, Nicolas Bonneville, David Gallinet, Nassima Ramdane, Philippe Valenti, Lauryl Decroocq, Pascal Boileau

► To cite this version:

Xavier Ohl, Nicolas Bonneville, David Gallinet, Nassima Ramdane, Philippe Valenti, et al.. How the greater tuberosity affects clinical outcomes after reverse shoulder arthroplasty for proximal humeral fractures. *Journal of Shoulder and Elbow Surgery*, 2018, 27 (12), pp.2139-2144. 10.1016/j.jse.2018.05.030 . hal-02135121

HAL Id: hal-02135121

<https://hal.science/hal-02135121>

Submitted on 21 May 2019

HAL is a multi-disciplinary open access archive for the deposit and dissemination of scientific research documents, whether they are published or not. The documents may come from teaching and research institutions in France or abroad, or from public or private research centers.

L'archive ouverte pluridisciplinaire **HAL**, est destinée au dépôt et à la diffusion de documents scientifiques de niveau recherche, publiés ou non, émanant des établissements d'enseignement et de recherche français ou étrangers, des laboratoires publics ou privés.




Open Archive Toulouse Archive Ouverte (OATAO)

OATAO is an open access repository that collects the work of some Toulouse researchers and makes it freely available over the web where possible.

This is an author's version published in: <https://oatao.univ-toulouse.fr/23092>

Official URL : <https://doi.org/10.1016/j.jse.2018.05.030>

To cite this version :

Ohl, Xavier and Bonneville, Nicolas  and Gallinet, David and Ramdane, Nassima and Valenti, Philippe and Decroocq, Lauryl and Boileau, Pascal *How the greater tuberosity affects clinical outcomes after reverse shoulder arthroplasty for proximal humeral fractures.* (2018) *Journal of Shoulder and Elbow Surgery*, 27 (12). 2139-2144. ISSN 1058-2746

Any correspondence concerning this service should be sent to the repository administrator:

tech-oatao@listes-diff.inp-toulouse.fr

How the greater tuberosity affects clinical outcomes after reverse shoulder arthroplasty for proximal humeral fractures

Xavier Ohl, MD, PhD^a, Nicolas Bonnevalle, MD, PhD^{b,*}, David Gallinet, MD^c,
Nassima Ramdane, PhD^d, Philippe Valenti, MD^e, Lauryl Decroocq, MD^f,
Pascal Boileau, MD, PhD^f, SOFCOT^g

^aOrthopaedic Department, University Hospital, Reims, France

^bDepartment of Orthopaedic Surgery, Riquet Hospital, University of Toulouse, Toulouse, France

^cSaint Vincent Private Hospital, Besançon, France

^dUnité de Méthodologie–Biostatistique et Data Management, Lille, France

^eParis Shoulder Institut, Paris, France

^fDepartment of Orthopaedic Surgery, iULS (Institut Universitaire Locomoteur & Sport), University of Nice Sophia Antipolis, Nice, France

^gFrench Society of Orthopedic Surgery and Traumatology, Paris, France

Background: Our purpose was to evaluate the clinical and radiologic outcomes of reverse shoulder arthroplasty for proximal humeral fractures in a large cohort of elderly patients and compare the results in the case of tuberosity excision, failed fixation, or anatomic healing.

Methods: In this retrospective multicenter study, 420 patients underwent review and radiography with a minimum follow-up period of 12 months. The patients were divided into 3 groups according to the status of the greater tuberosity (GT) on the last anteroposterior radiographs: anatomic GT healing (group A, n = 169); GT resorption, malunion, or nonunion (group B, n = 131); and GT excision (group C, n = 120). Complications were recorded; shoulder function, active mobility, and subjective results were assessed.

Results: At a mean follow-up of 28 months, the mean Simple Shoulder Value in group A (75%) outperformed the results found in groups B (69%, $P < .001$) and C (56%, $P < .001$). Overall, the mean adjusted Constant-Murley score was significantly higher in group A ($93\% \pm 22\%$) than in group B ($82\% \pm 22\%$) and group C ($80\% \pm 24\%$) ($P < .001$), but there was no difference between groups B and C ($P = .88$). Anterior active elevation and external rotation were significantly better in group A than in groups B and C ($P < .001$). The instability rate was significantly higher in group C (n = 15 [12.5%], $P < .001$) than in group A (n = 2) or group B (n = 3).

Conclusion: In elderly patients who have undergone a reverse shoulder arthroplasty for acute proximal humeral fractures, anatomic tuberosity healing improves objective and subjective outcomes. GT excision is associated with the worst functional results and increases the risk of postoperative shoulder instability.

Institutional Review Board approval was received (CCTIRS-16-003), and the ethical committee approved this study.

*Reprint requests: Nicolas Bonnevalle, MD, PhD, Département d'orthopédie, Hôpital Riquet, Place Baylac, 31059 Toulouse Cedex 09, France.

E-mail address: nicolasbonnevalle@yahoo.fr (N. Bonnevalle).

Level of evidence: Level III; Retrospective Cohort Design; Treatment Study

Keywords: Proximal humeral fractures; reverse shoulder arthroplasty; greater tuberosity excision; greater tuberosity healing; shoulder instability; complication

Proximal humeral fractures (PHFs) are the third most common fracture in elderly persons and represent a significant challenge for orthopedic surgeons.⁹ Fracture fixation in the elderly population increases the risk of failure owing to poor bone quality and avascular necrosis. On the other hand, nonoperative treatment does not always lead to acceptable shoulder function because of the possibility of severe malunion in an older population of patients wanting to recover their quality of life after the injury. Hemiarthroplasty has been proposed as an alternative to fixation; however, clinical outcomes depend on anatomic healing of the tuberosities around the implant.¹ Because reverse shoulder arthroplasty (RSA) has led to promising results in patients with cuff deficiency, indications for this procedure have been expanded to complex PHFs.⁶

Optimal management of the tuberosities in RSA remains unclear and controversial. Some authors reported satisfactory clinical outcomes of RSA after removal of both tuberosities.³ Others reported better active external rotation after fixation and healing of the tuberosities around the stem.^{4,6} However, despite strong fixation, malunions, osteolysis, and nonunions have been reported.^{4,7,11}

The aim of this study was to assess the clinical and radiologic outcomes of RSA implanted for acute PHFs in a large cohort of elderly patients and compare the results in patients with anatomic greater tuberosity (GT) healing, failed fixation (malunion, nonunion, or osteolysis), and GT excision. We hypothesized that better clinical outcomes would be observed in patients with healed tuberosities than in patients with failed tuberosity fixation or in those in whom the tuberosities have been excised.

Materials and methods

Study design

In this retrospective multicenter study, we included patients with an acute PHF who were treated with a primary RSA between January 2010 and December 2015, regardless of whether the GT was fixed or removed, and who had a minimum follow-up period of 12 months. We excluded patients with pathologic fractures (primary tumor or metastasis), patients with previous surgery on the involved shoulder, patients in whom surgery was performed more than 6 weeks after the injury occurred, and patients without plain anteroposterior radiographs of the shoulder at 12 months after surgery. Patients gave their consent for the analysis of their clinical and radiologic data.

Patient population

Five hundred sixty-seven patients were eligible, and 420 patients (74%) with an RSA implanted for an acute PHF were reviewed and underwent radiography with minimum 1-year follow-up (Fig. 1). The mean age at surgery was 78 years, 83% of patients were women, the mean body mass index was 26.3 ± 5.5 kg/m², and the injured shoulder was on the dominant side in 58% of cases. The American Society of Anesthesiologists score was III or IV in 38% of the cohort.

Surgical technique

A deltopectoral approach (n = 100) or deltoid-splitting approach (n = 320) was performed with patients in the beach-chair position. Six different RSA models were used; 48% (n = 200) were specifically designed to treat PHFs with a low-profile stem and bone grafting around the metaphysis. A cemented stem was used in 88% of cases (n = 370). The glenosphere diameter was 36 mm in 66% of cases. In 300 RSA cases, both tuberosities were fixed with 2 or 4 horizontal cerclages around the metaphysis. For the remaining 120 RSAs, the surgeons decided to excise the greater and lesser tuberosities. Postoperatively, the shoulder was placed in a sling in 75% of cases. Physiotherapy was started immediately with free range of motion in 55%.




Figure 1 Flowchart.

Radiologic evaluation

Anteroposterior views in the neutral position were analyzed (minimum, 12 months) to determine the status of the GT and classify the patients into 3 groups:

- Group A showed anatomic tuberosity healing, in which the GT was visible on the lateral part of the stem, at the level with or below (no more than 5 mm) the prosthetic head, and in continuity with the diaphysis (Fig. 2).
- Group B had failed anatomic healing with malunion, non-union, or resorption (Fig. 3).

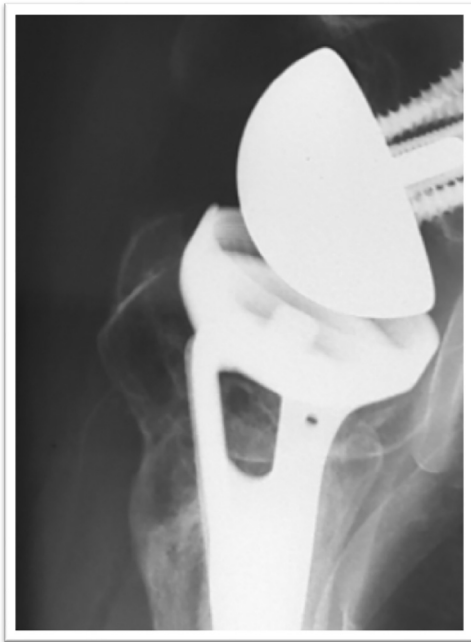


Figure 2 Anatomic healing of greater tuberosity.

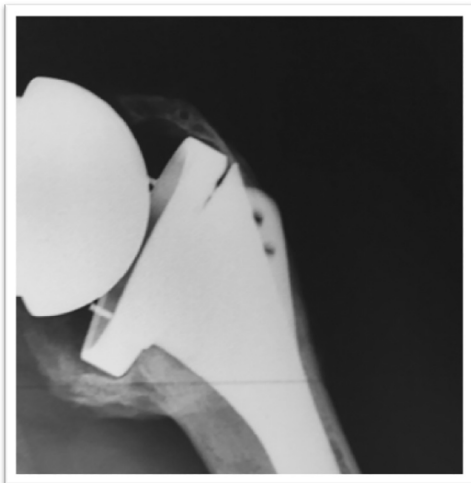


Figure 3 Malunion of greater tuberosity.

- Group C underwent excision of the tuberosities at the time of surgery (Fig. 4).

Clinical assessment

The Constant-Murley score (CMS) and Simple Shoulder Value (SSV) were used to determine the functional outcome.^{2,8,13} For active range of motion, elevation (active anterior elevation) was measured with a goniometer (patient in a seated position) in the sagittal plane and external rotation was measured in the coronal plane with the arm by the patient's side and in 90° of abduction. Internal rotation—measured as the highest vertebral level the patient could reach behind his or her back—was translated into a numerical value as in the CMS.

Statistical analysis

Statistical tests were performed by an independent epidemiologic department using the SAS software package (release 9.4; SAS Institute, Cary, NC, USA). Data are presented as number (percentage) for categorical variables and mean \pm standard deviation (range) for quantitative variables. The normality of distribution was checked graphically and by using the Shapiro-Wilk test. Demographic data and outcome scores between the 3 groups according to GT status were compared using the χ^2 or Fisher exact test for categorical variables and Kruskal-Wallis test for quantitative variables. We also performed Dwass-Steel-Critchlow-Fligner multiple-comparison analysis, which is based on pair-wise 2-sample Wilcoxon comparisons. The significance threshold was set at .05.

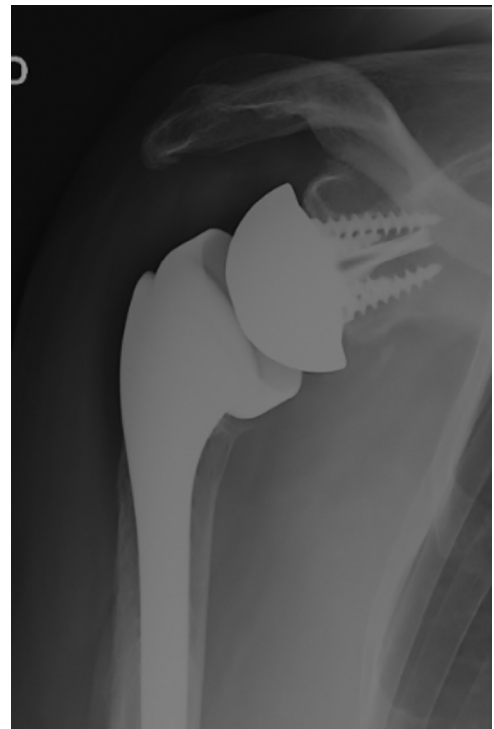


Figure 4 Excision of greater tuberosity.

Results

Complications and revision

There were 10 postoperative infections (2.4%), 6 cases of glenoid loosening (1.4%), and 8 cases of humeral loosening (1.9%). Of the shoulders, 20 (4.7%) were unstable, with early dislocations (<1 month) in 16 and late dislocations in 4. Six were stable after closed reduction, whereas 4 others remained unstable but were left in their dislocated state because of an unacceptable perioperative risk of revision surgery. Reoperation was performed on 13 shoulders: 12 were successfully revised and 1 implant was removed.

Clinical results

At a mean follow-up of 28 months (range, 12-60 months), the mean CMS was 57 ± 15 points, the mean adjusted CMS was $86\% \pm 23\%$, and the mean SSV was $70\% \pm 18\%$. Overall, mean active anterior elevation reached $115^\circ \pm 30^\circ$, mean active external rotation with the arm at the side was $17^\circ \pm 17^\circ$, mean external rotation in 90° of abduction was $32^\circ \pm 25^\circ$, and mean internal rotation was 4 ± 2 points (sacrum).

Radiologic results

The patients were divided into 3 groups according to GT status as defined earlier: group A (anatomic GT healing, $n = 169$ [40%]), group B (GT resorption, malunion, or nonunion; $n = 131$ [31%]), and group C (GT excision, $n = 120$ [29%]). There was no significant difference in demographic characteristics between groups A, B, and C (Table I).

Influence of tuberosity conservation and healing

Patients in group A (tuberosity healing) had the best shoulder function, the best range of active motion, and the highest subjective shoulder values (Table II). Overall, the mean adjusted CMS was significantly higher in group A ($93\% \pm 22\%$) than in group B ($82\% \pm 22\%$) and group C ($80\% \pm 24\%$) ($P < .001$), but there was no difference between group B and group C ($P = .88$).

At last follow-up, the mean SSV in group A (75%) outperformed the results found in groups B (69%, $P < .001$) and C (56%, $P < .001$). Anterior active elevation was significantly better in group A ($127^\circ \pm 27^\circ$) than in groups B ($114^\circ \pm 29^\circ$) and C ($101^\circ \pm 25^\circ$, $P < .001$). Active external rotation was also significantly better in group A ($22^\circ \pm 16^\circ$) than in groups B ($17^\circ \pm 20^\circ$) and C ($7^\circ \pm 7^\circ$, $P < .001$). Finally, the rate of postoperative shoulder instability was significantly higher in group C (12%, $P < .0001$) than in group A ($n = 2$) or group B ($n = 3$). The other complications were not correlated with the type of group.

Discussion

In this large cohort of 420 patients who underwent review and radiography with a mean follow-up period of 28 months (range, 12-60 months), we found that tuberosity reattachment and healing around the RSA were associated with the best functional outcomes, the best range of active motion, and the best subjective outcomes. Patients with GT malunion, nonunion, or osteolysis had significantly lower active range of motion, functional results, and SSVs, whereas patients in whom the tuberosities had been excised had the worst clinical and subjective outcomes and the highest risk of shoulder instability (12.5%).

Instability after RSA implantation is a severe postoperative complication. The fact that tuberosity excision is increasing the risk of postoperative instability is not surprising: After excision of the tuberosities, the stabilizing effect of soft tissues (rotator cuff) around the ball-and-socket joint is lost. Moreover, the anatomic landmark provided by the GT reduction is lost, making it difficult (if not impossible) to determine the height of the prosthesis. Without the GT landmark, the humerus can be potentially shortened (ie, the prosthesis can be implanted too low), which can contribute to postoperative instability. Unfortunately, because we did not make postoperative measurements of both humeri at last review, we were not able to validate this hypothesis.

RSA for the treatment of displaced PHFs in elderly patients is gaining popularity among surgeons because clinical results are more reliable than those obtained with hemiarthroplasty.^{1,4-7,11,13,15} Since RSA has been designed to overcome cuff-deficient shoulders, some surgeons have

Table I Demographic characteristics of patients according to GT status

	Total (n = 420)	Group			P value
		A (n = 169)	B (n = 131)	C (n = 120)	
Age, yr	77.7 ± 7.7 (48-97)	78 ± 8 (45-97)	77 ± 8 (58-93)	77 ± 8 (58-93)	.19
Female	86.4%	84.0%	84.0%	93.3%	.056
ASA score III or IV	32.4%	30.8%	33.0%	33.3%	.86

GT, greater tuberosity; ASA, American Society of Anesthesiologists.

Values are expressed as percentage or mean \pm standard deviation (range). No difference was observed between groups. Group A showed anatomic healing; group B showed failed fixation (nonunion, osteolysis, or malunion); and group C underwent tuberosity excision.

Table II Functional outcomes in study groups

Parameter	Group			P value
	Total (n = 420)	A (n = 169)	B (n = 131)	
Constant-Murley score (out of 100 points)	56.8 ± 14.9 (12 to 93)	61.0 ± 13.5*† (18 to 89)	54.5 ± 15.2*‡ (14 to 87)	53.2 ± 15.2†‡ (12 to 93)
Adjusted Constant-Murley score, %	85.7 ± 23.0 (19 to 142)	92.7 ± 21.5§ (26 to 142)	81.7 ± 22.4§¶¶ (22 to 126)	80.1 ± 23.6 ¶¶ (19 to 135)
SSV, °	69.9 ± 17.9 (10 to 100)	75.5 ± 14.8#** (10 to 100)	69.1 ± 18.2†† (10 to 100)	56.5 ± 18.3**†† (30 to 90)
AAE, °	115.4 ± 29.8 (20 to 180)	126.7 ± 27.6††§§ (50 to 180)	113.8 ± 29.9†† (30 to 180)	100.6 ± 24.9§§ (20 to 160)
ER1, °	16.7 ± 17.1 (-30 to 90)	22.0 ± 16.2¶¶## (-20 to 90)	16.7 ± 20.2¶¶*** (-30 to 90)	6.6 ± 6.6##*** (-30 to 10)
ER2, °	32.4 ± 25.1 (0 to 100)	43.2 ± 26.9†††## (0 to 100)	33.0 ± 26.8†††§§§ (0 to 100)	17.5 ± 5.9†††§§§ (0 to 20)
IR	4.3 ± 2.5 (0 to 10)	4.8 ± 2.7 .¶¶¶¶ (0 to 10)	4.0 ± 2.4 .### (0 to 10)	4.0 ± 2.3¶¶¶¶### (0 to 10)

SSV, Simple Shoulder Value; AAE, active anterior elevation; ER1, external rotation with arm at side; ER2, external rotation in 90° of abduction; IR, internal rotation. Values are expressed as mean ± standard deviation (range). Group A showed anatomic healing; group B showed failed fixation (nonunion, osteolysis, or malunion); and group C underwent tuberosity excision.

* P = .0002; † P < .0001; ‡ P < .8383; § P < .001; || P < .0001; ¶ P = .8861; # P = .0270; ** P = .0001; †† P = .0013; ‡‡ P = .0007; §§ P = .0015; ¶¶ P = .0048; ## P < .0001; *** P < .0001; ††† P = .0101; ### P < .0001; §§§ P < .0001; |||| P = .0335; ¶¶¶ P = .0393; #### P = .9955.

proposed excising the tuberosities,^{5,6} whereas others have suggested that tuberosity reattachment is less important than in hemiarthroplasty.^{10,11} The question that we attempted to answer in this study was as follows: Are clinical and subjective outcomes of RSA for PHFs comparable in the case of tuberosity excision, failed fixation, or anatomic healing? To try to answer this question, we performed a multicenter study and analyzed the clinical and subjective results based on the surgical tuberosity management (excision vs conservation) and the final aspect of the tuberosities on the last postoperative radiographs (GT healing in an anatomic position vs nonunion, malunion, or resorption).

Our study data suggest that healing of the GT in an anatomic position is required to achieve the best functional outcomes in patients with RSA for PHFs. As a result, surgeons should make all efforts to perform conservation, bone grafting, and fixation of the tuberosities to obtain bone healing around the prosthesis, and they should discontinue tuberosity excision in RSA for acute PHFs.

The results found in this study are similar to those reported in the literature and confirm that tuberosity excision should not be performed in patients who receive an RSA for acute fracture. Cazeneuve and Cristofari⁵ reported on their first RSA cases in 47 fractures with a mean follow-up period of more than 6 years (range, 1-16 years). They did not address the tuberosities and used an implant with a bulky metaphysis that was not specifically designed for fracture cases. They reported a mean Constant score at the last follow-up of 53 points and found a 10% rate of postoperative instability. Gallinet et al¹¹ compared 2 cohorts of RSAs with or without tuberosity fixation retrospectively. They concluded that preservation and fixation of the tuberosities led to better clinical outcomes in terms of active range of motion, especially in external rotation in abduction with a gain of +35°. Because external rotation can be provided by only the teres minor and infraspinatus muscles, GT fixation is necessary if we expect to restore spatial control of the hand during arm elevation and activities of daily living. However, successful healing in an anatomic position after GT fixation is difficult to achieve. Gallinet et al reported that only 64% of cases had anatomic healing after use of the suture technique described by Boileau et al.¹ More recently, Sebastiá-Forcada et al¹⁵ reported the same rate. The addition of a lateral autograft (from the humeral head) between the metaphysis of the implant and tuberosities results in an anatomic healing rate of 80% to 100%.^{10,12,14}

This study has the limitations related to a multicenter, retrospective study. One limitation is the high number of patients who died before 1 year or were too frail to be clinically reviewed with radiographs and therefore could not be included. Another limitation is related to the number of different implants used. A more lateralized design versus a medialized one may have potentially influenced the functional outcomes. Finally, we analyzed mainly the impact of GT healing and positioning, but we did not investigate the impact of the lesser tuberosity (healed or not) on clinical outcomes because the radiologic evaluation was not considered accurate enough.

To our knowledge, this is the largest cohort of RSAs implanted for acute fractures reported in the literature today. Moreover, we stratified the patients and analyzed the results according to the tuberosity management and healing, and the 3 groups of patients studied (tuberosity healing vs tuberosity malunion or nonunion vs tuberosity excision) were comparable in terms of age, sex, and health status (American Society of Anesthesiologists score).

Conclusion

In elderly patients who have undergone an RSA for acute PHFs, tuberosity healing improves the clinical outcomes and decreases the risk of postoperative instability. Tuberosity fixation failure is associated with lower functional results, whereas tuberosity excision provides the worst functional results and the highest risk of postoperative instability. Our results suggest that tuberosity preservation, fixation, and healing are mandatory when RSA is used to treat displaced PHFs in an elderly population.

Disclaimer

The authors, their immediate families, and any research foundations with which they are affiliated have not received any financial payments or other benefits from any commercial entity related to the subject of this article.

References

1. Boileau P, Krishnan SG, Tinsi L, Walch G, Coste JS, Molé D. Tuberosity malposition and migration: reasons for poor outcomes after hemiarthroplasty for displaced fractures of the proximal humerus. *J Shoulder Elbow Surg* 2002;11:401-12. <https://doi.org/10.1067/mse.2002.124527>
2. Boileau P, Rumian AP, Zumstein MA. Reversed shoulder arthroplasty with modified L'Episcopo for combined loss of active elevation and external rotation. *J Shoulder Elbow Surg* 2010;19(Suppl):20-30. <http://dx.doi.org/10.1016/j.jse.2009.12.011>
3. Bonneville N, Tournier C, Clavert P, Ohl X, Sirveaux F, Saragaglia D, et al. Hemiarthroplasty versus reverse shoulder arthroplasty in 4-part displaced fractures of the proximal humerus: multicenter retrospective study. *Orthop Traumatol Surg Res* 2016;102:569-73. <http://dx.doi.org/10.1016/j.otsr.2016.02.014>
4. Bufquin T, Hersan A, Hubert L, Massin P. Reverse shoulder arthroplasty for the treatment of three- and four-part fractures of the proximal humerus in the elderly: a prospective review of 43 cases with a short-term follow-up. *J Bone Joint Surg Br* 2007;89:516-20. <http://dx.doi.org/10.1302/0301-620X.89B4.18435>
5. Cazeneuve JF, Cristofari DJ. The reverse shoulder prosthesis in the treatment of fractures of the proximal humerus in the elderly. *J Bone Joint Surg Br* 2010;92:535-9. <http://dx.doi.org/10.1302/0301-620X.92B4.22450>
6. Cazeneuve JF, Cristofari DJ. Delta III reverse shoulder arthroplasty: radiological outcome for acute complex fractures of the proximal humerus in elderly patients. *Orthop Traumatol Surg Res* 2009;95:325-9. <http://dx.doi.org/10.1016/j.otsr.2009.03.018>
7. Chun YM, Kim DS, Lee DH, Shin SJ. Reverse shoulder arthroplasty for four-part proximal humerus fracture in elderly patients: can a healed tuberosity improve the functional outcomes? *J Shoulder Elbow Surg* 2017;26:1216-21. <http://dx.doi.org/10.1016/j.jse.2016.11.034>
8. Constant CR, Gerber C, Emery RJ, Søjbjerg JO, Gohlke F, Boileau P. A review of the Constant score: modifications and guidelines for its use. *J Shoulder Elbow Surg* 2008;17:355-61. <http://dx.doi.org/10.1016/j.jse.2007.06.022>
9. Court-Brown CM, Clement ND, Duckworth AD, Aitken S, Biant LC, McQueen MM. The spectrum of fractures in the elderly. *Bone Joint J* 2014;96-B:366-72. <http://dx.doi.org/10.1302/0301-620X.96B3.33316>
10. Formaini NT, Everding NG, Levy JC, Rosas S. Tuberosity healing after reverse shoulder arthroplasty for acute proximal humerus fractures: the "black and tan" technique. *J Shoulder Elbow Surg* 2015;24:e299-306. <http://dx.doi.org/10.1016/j.jse.2015.04.014>
11. Gallinet D, Adam A, Gasse N, Rochet S, Obert L. Improvement in shoulder rotation in complex shoulder fractures treated by reverse shoulder arthroplasty. *J Shoulder Elbow Surg* 2013;22:38-44. <http://dx.doi.org/10.1016/j.jse.2012.03.011>
12. Garofalo R, Flanagan B, Castagna A, Lo EY, Krishnan SG. Reverse shoulder arthroplasty for proximal humerus fracture using a dedicated stem: radiological outcomes at a minimum 2 years of follow-up-case series. *J Orthop Surg Res* 2015;10:129. <http://dx.doi.org/10.1186/s13018-015-0261-1>
13. Gilbert MK, Gerber C. Comparison of the subjective shoulder value and the Constant score. *J Shoulder Elbow Surg* 2007;16:717-21. <http://dx.doi.org/10.1016/j.jse.2007.02.123>
14. Levy JC, Badman B. Reverse shoulder prosthesis for acute four-part fracture: tuberosity fixation using a horseshoe graft. *J Orthop Trauma* 2011;25:318-24. <http://dx.doi.org/10.1097/BOT.0b013e3181f22088>
15. Sebastián-Forcada E, Cebrián-Gómez R, Lizaur-Utrilla A, Gil-Guillén V. Reverse shoulder arthroplasty versus hemiarthroplasty for acute proximal humeral fractures. A blinded, randomized, controlled, prospective study. *J Shoulder Elbow Surg* 2014;23:1419-26. <http://dx.doi.org/10.1016/j.jse.2014.06.035>