



Clinical outcomes of posterior bone block procedures for posterior shoulder instability: multicenter retrospective study of 66 cases

Philippe Clavert, Edouard Furioli, K. Andieu, François Sirveaux,
Marie-Béatrice Hardy, Geoffroy Nourissat, Yves Bouju, Jérôme Garret,
Arnaud Godenèche, Pierre Mansat

► To cite this version:

Philippe Clavert, Edouard Furioli, K. Andieu, François Sirveaux, Marie-Béatrice Hardy, et al.. Clinical outcomes of posterior bone block procedures for posterior shoulder instability: multicenter retrospective study of 66 cases. *Orthopaedics & Traumatology: Surgery & Research*, 2017, 103 (8), pp.S193-S197. 10.1016/j.otsr.2017.08.006 . hal-02135116

HAL Id: hal-02135116

<https://hal.science/hal-02135116>

Submitted on 21 May 2019

HAL is a multi-disciplinary open access archive for the deposit and dissemination of scientific research documents, whether they are published or not. The documents may come from teaching and research institutions in France or abroad, or from public or private research centers.

L'archive ouverte pluridisciplinaire **HAL**, est destinée au dépôt et à la diffusion de documents scientifiques de niveau recherche, publiés ou non, émanant des établissements d'enseignement et de recherche français ou étrangers, des laboratoires publics ou privés.




Open Archive Toulouse Archive Ouverte (OATAO)

OATAO is an open access repository that collects the work of some Toulouse researchers and makes it freely available over the web where possible.

This is an author's version published in: <https://oatao.univ-toulouse.fr/23103>

Official URL : <https://doi.org/10.1016/j.otsr.2017.08.006>

To cite this version :

Clavert, Philippe and Furioli, Edouard and Andieu, K. and Sirveaux, François and Hardy, Marie-Béatrice and Nourissat, Geoffroy and Bouju, Yves and Garret, Jérôme and Godenèche, Arnaud and Mansat, Pierre  *Clinical outcomes of posterior bone block procedures for posterior shoulder instability: multicenter retrospective study of 66 cases.* (2017) Orthopaedics & Traumatology: Surgery & Research, 103 (8). S193-S197. ISSN 1877-0568

Any correspondence concerning this service should be sent to the repository administrator:
tech-oatao@listes-diff.inp-toulouse.fr

Clinical outcomes of posterior bone block procedures for posterior shoulder instability: Multicenter retrospective study of 66 cases

P. Clavert^{a,*}, E. Furioli^a, K. Andieu^b, F. Sirveaux^c, M.B. Hardy^d, G. Nourissat^e, Y. Bouju^f, J. Garret^g, A. Godenèche^h, P. Mansatⁱ, the French Arthroscopy Society

^a Upper Limb Surgery Unit, CCOM, 10, avenue Baumann, 67400 Illkirch, France

^b Orthopaedic department, CHU de Nantes, 5, rue Gaston-Veil, 44000 Nantes, France

^c CHRU-Centre Chirurgie Emile-Gallé, 49, rue Hermite, 54052 Nancy cedex, France

^d Clinique Mutualiste Chirurgicale, 3, rue le verrier, 42100 Saint-Étienne, France

^e Clinique des Maussins Ramsay Générale de Santé, 67, rue de Romainville, 75019 Paris, France

^f Institut Main Atlantique, 21, rue des Martyrs, 44100 Nantes, France

^g Clinique du Parc, 155, boulevard Stalingrad, 69006 Lyon, France

^h Centre Orthopédique Santy, 24, avenue Paul-Santy, 69008 Lyon, France

ⁱ Service de Chirurgie Orthopédique-Traumatologie, Hôpital Purpan, place du Dr-Baylac, 31059 Toulouse, France

A B S T R A C T

Keywords:

Shoulder
Posterior instability
Bone block procedure
Clinical results
Complications

Background: The posterior bone block procedure is a well-known treatment option for posterior shoulder instability. The goal of this retrospective multicenter study was to evaluate the clinical and radiological outcomes of this procedure.

Material and methods: The study cohort consisted of 66 patients (55 men, 11 women) with an average age of 27.8 years who were evaluated clinically and radiologically using a standardized questionnaire after posterior bone block surgery.

Results: The Constant score significantly improved postoperatively ($P < 0.0001$). The postoperative Walch-Duplay score was 81.5. The Rowe score was 86.5 points. The pain level (VAS) was significantly reduced after this procedure ($P < 0.0001$). Eighty-five percent of patients were satisfied or very satisfied with the outcome.

Conclusion: This multicenter study of 66 patients shows that the posterior bone block procedure is an effective technique with good subjective and objective outcomes; however, the possibility of complications cannot be ignored.

Clinical study: Level of evidence IV.

1. Introduction

Chronic posterior shoulder instability is rare with an estimated incidence between 2% and 4% in the general population; it makes up 1% to 4% of all shoulder instability cases [1–5]. In contrast to anterior instability, patients mostly report subluxation episodes and rarely true dislocations [6–8]. In certain cases, this condition only manifests itself in the form of an unstable painful shoulder (UPS) [6,9–11]. There is currently no agreement on the best surgical treatment for this condition, especially given the wide spectrum of clinical presentations. The voluntary or involuntary nature of the instability, along with hypermobility, makes the diagnosis and

treatment challenging. For these reasons, high failure rates have been reported [12].

Except in cases of recurrent pure posterior dislocations due to trauma that can be treated surgically right away, other forms of posterior instability should be treated functionally initially [4,6,12–16] using neuromuscular reprogramming with proprioceptive rehabilitation [17]. When this fails, surgical treatment is justified [18]. But, there is little consensus as to which surgical procedure should be performed. The indication is made based on the preoperative clinical examination and the imaging assessment. The procedure can target the soft tissues (open or arthroscopic posterior capsular plication) or the bones (posterior bone block or opening-wedge posterior glenoid osteotomy). Published surgical treatment studies are rare and often include only a small number of patients [5,19–25].

The bone block procedure was first described by Rocher in 1931 using a rib graft [26]. Use of a free, subperiosteal iliac crest graft

* Corresponding author.

E-mail address: Philippe.clavert@chru-strasbourg.fr (P. Clavert).

was proposed by Ilfeld in 1943 [27], but only for patients who had failed posterior capsule stabilization procedures. Screw fixation of this graft was proposed by Gosset in 1976 [20] and then combined with a procedure on the posterior capsule by Fronek [6]. By analogy with anterior coracoid bone grafting, Kouvalchouk proposed performing a bone block procedure using the posterior portion of the acromion with a deltoid flap, thereby providing triple posterior restraints [21].

The working hypothesis of our study was that the posterior bone block is a surgical technique that leads to good clinical outcomes (stability and resumption of sports activities) with acceptable complication and failure rates. The primary objective was to evaluate the subjective and objective outcomes of posterior bone block procedures based on two well-defined clinical pictures: (1) pure traumatic posterior instability (i.e. clearly defined initial injury event, with or without dislocation, which is recurrent and painful), (2) voluntary dislocations and subluxations that may or may not have become involuntary. Because of the small number of cases, we excluded patients with UPS and uncategorized posterior instability. The secondary objectives were to study the radiological changes in the bone blocks over time.

2. Patients and methods

This was a retrospective multicenter study of patients with posterior shoulder instability treated by an open or arthroscopic procedure in the context of a SFA symposium on unidirectional posterior shoulder instability. Three broad clinical pictures were included: (1) recurrent traumatic posterior instability (dislocation or subluxation), (2) recurrent voluntary posterior instability (dislocation or subluxation) that became involuntary and (3) unstable painful shoulder (UPS) [6,9–11].

2.1. Patients

All patients reviewed by March 31, 2016 with a minimum 2 years' follow-up were included. Included were adult patients being treated for pure posterior instability who had a complete preoperative clinical examination and preoperative imaging work-up. Patients were excluded if they did not agree to their clinical or radiological data being used for this study, had incomplete or non-usable medical records, had undergone revision surgery or had a neglected posterior dislocation. In all, 66 patients underwent a posterior bone block procedure using an iliac graft (according to the standard or arthroscopic method) or an acromial graft (according to Kouvalchouk's technique [21,22]). To better compare the clinical outcomes based on the clinical presentation, three patients with UPS and three with uncategorized instability were excluded. The study flow chart is given in Fig. 1.

2.2. Preoperative assessment

The preoperative data consisted of the patients' history (sex, age, injured side, dominant side, sports activities, history of trauma, voluntary or involuntary nature of the instability, presence of pain), a clinical examination (modified Beighton criteria [28]), the apprehension test and Gerber's lift-off test [29], and the Constant-Murley test [30]. The radiological work-up consisted of at least plain AP and lateral X-rays and typically a CT arthrography to detect cartilage damage, damage to the posteroinferior edge of the glenoid, glenoid degeneration, posterior labral tears.

2.3. Surgical procedure

The following data were collected from the surgical records: type of bone block used (iliac [31] or acromial [21]), bone block

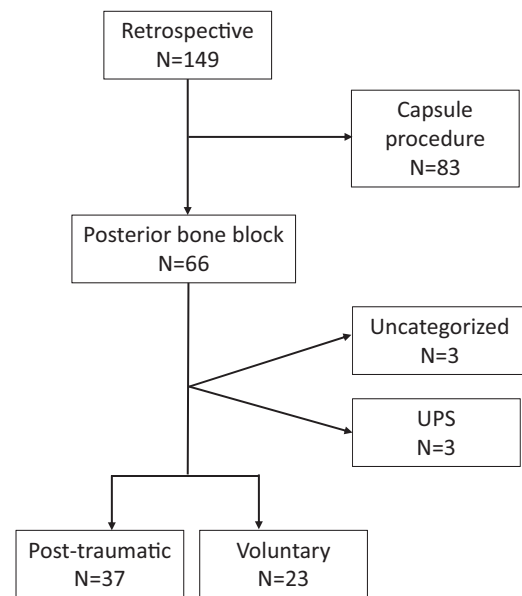


Fig. 1. Study flow chart for inclusions (UPS: unstable painful shoulder).

position (overhanging or not), number of screws used and whether capsulolabral reconstruction was also performed.

2.4. Postoperative follow-up

The type and duration of immobilization was noted, as was the time elapsed before the patients returned to work and resumed sports activities. Patients were reviewed in person to determine the Constant-Murley score [30], Walch-Duplay score [32,33], Rowe score [34,35], subjective shoulder value (SSV) [36] and pain levels using a visual analog scale (VAS).

X-rays using AP and Bernageau lateral views [37] were also done to assess the position of the bone block and whether it had resorbed over time.

2.5. Statistical analysis

The statistical analysis was done using XLstat 2007 software (Addinsoft, Paris, France). Data were summarized by determining the mean, minimum, maximum and standard deviation (SD) values. Quantitative variables were compared using the Kruskal-Wallis test and the Mann-Whitney *U* test.

3. Results

3.1. Study population

The mean age of the 66 patients was 27.8 years (15–58 years, SD 10.3 years). The right shoulder was affected in 55 patients (83%). The dominant arm was involved in 51 patients (77%). Most patients were recreational athletes (Table 1). Hypermobility was found in 35% of patients (23 cases) and a positive apprehension test in 30% of patients (20 cases). Fifteen patients (23%) had pain and 52 patients (79%) had a positive Gerber sign. The instability was triggered by an injury event in 80% of patients ($n = 53$). Pure involuntary instability was present in 38 patients (58%).

3.2. Imaging

On the glenoid side, damage to the posterior portion of the glenoid was present in 34 patients (52%), including 10 fractures

Table 1
Characteristics of the study population.

Gender ratio M/F	83%
Age	27.8
Injured side	
Right	83%
Left	17%
Dominant side	
Non-dominant	23%
Dominant	77%
Sports participation	
Recreational	64%
Competitive	13%
Hobbies only	17%
Sedentary	6%

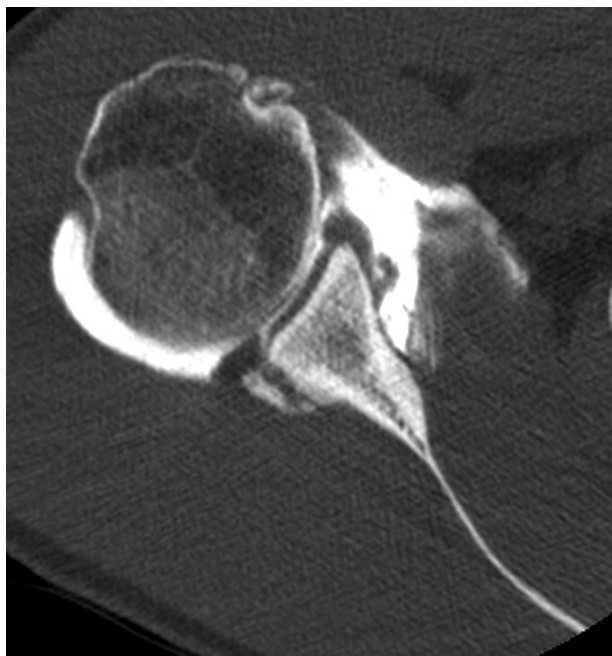


Fig. 2. Posterior glenoid fracture (recurrent post-traumatic posterior instability).

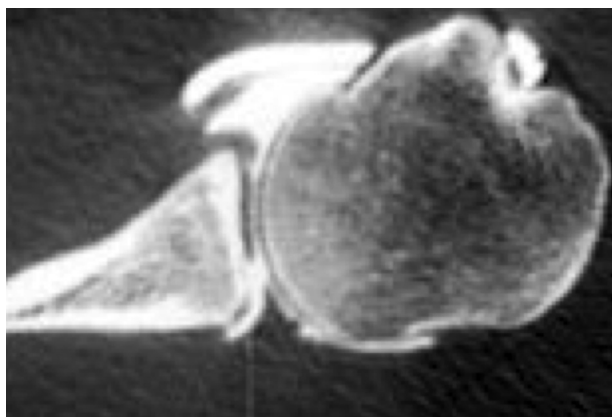


Fig. 3. Posteroinferior glenoid cartilage damage.

(15%) (Fig. 2). A reverse Bankart lesion was present in 39 patients (59%). In addition, 11% of patients had cartilage damage (Fig. 3) like a Kim lesion [38] that was well-defined (7 patients). On the humeral side, 20 patients had a reverse Hill-Sachs lesion (30%).

Table 2
Comparison of preoperative and postoperative Constant score items.

	Intraoperative	Postoperative	<i>P</i>
Pain	8.54	12.38	<0.0001
Function	13.81	17.7	<0.0001
Mobility	37.57	37.74	0.238
Strength	16.41	18.22	0.009
Total	76.11	86.04	<0.0001

3.3. Surgical procedure

An iliac bone block was used in 86% of patients (57 patients) and an acromial bone block in the other 14%. The bone block was flush in 9 patients (14%), extra-articular in 10 patients (15%), flush and extra-articular in 13 patients (20%), overhanging and intra-articular in 9 patients (14%), overhanging and extra-articular in 18 patients (28%). Two screws were used to fix the bone block in 60% of cases.

The postoperative immobilization was in neutral position in 73% of cases, external rotation in 14% of cases and internal rotation in 14% of cases for an average of 4.8 weeks (1–6, SD 1.24). Return to work was possible in 94% of patients in the same job after a mean of 5 months (1–15). Resumption of sports activities was possible in 67% of patients after a mean of 6.5 months (1–12).

3.4. Final review

The mean follow-up in this study was 3.7 years (range 1–13 years, SD 3.4). The overall Constant score improved significantly between the preoperative period (76.11 points) and the postoperative period (86.04 points) ($P < 0.0001$). The pain subscore (8.54 points to 12.38 points, $P < 0.0001$) and function subscore (13.81 points to 17.7 points, $P < 0.0001$) improved significantly. The individual items of the Constant score are listed in Table 2.

The Walch-Duplay score averaged 81.5 (25–100). The Rowe score was 86.5 points (20–100). The VAS for pain significantly decreased from 4.7 to 1.6 ($P < 0.0001$). Subjectively, 58% of patients were very satisfied with the outcome, 27% were satisfied, 6% were somewhat satisfied and 9% were disappointed.

Relative to the type of bone graft used surgically, there was no effect of bone block overhang on the Constant score ($P = 0.1$), pain levels ($P > 0.05$), mobility ($P = 1$), the Walch-Duplay score ($P = 0.422$) and the Rowe score ($P = 0.678$). There was no significant effect of the patient having preoperative bone or cartilage damage on the clinical outcomes at the last follow-up, independent of the clinical presentation.

3.5. Radiological outcomes

Fifteen patients did not have reliable X-ray data. For the other 51 patients, the bone block was considered intact in 35% (18 cases), partial lysis was found in 31% of bone blocks (16 cases) (Fig. 4), and considerable lysis in 33% of cases (17 patients). There was no significant clinical effect of radiological bone block resorption on the overall Constant score ($P > 0.05$), the pain subscore ($P > 0.05$) or the mobility subscore ($P > 0.05$). There was also no effect on the recurrence of subluxations ($P > 0.05$).

3.6. Complications

There were no general intraoperative complications, nor morbidity related to the surgical technique (in the operated shoulder and/or at the graft harvest site). There were no complications related to the fixation hardware.

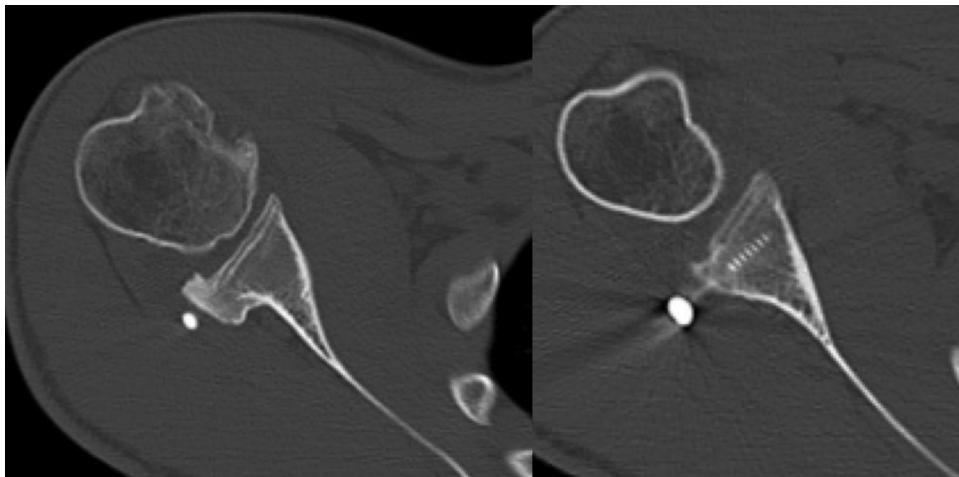


Fig. 4. Resorption of posterior bone block.

Table 3
Impact of clinical presentation on the outcomes.

Score	Invol	Volont to Invol	<i>P</i>
CS	86	86.7	0.535
Pain	13.2	11.7	0.85
Mobility	37.5	38.5	0.53
Activity	17.7	18.5	0.679
Pain (VAS)	1	2.1	0.13
SSV	84	83.7	0.14

3.7. Failures

There was one case of true dislocation (1%) and seven cases of subluxation. Eight patients had constant pain (12%), one patient had intermittent pain (1.5%) and three patients (4.5%) experienced new instability episodes (true dislocation or subluxation).

3.8. Impact of clinical presentation

We found no difference in the outcomes based on the clinical picture: involuntary (post-traumatic) or voluntary to involuntary. These findings are presented in more detail in [Table 3](#).

4. Discussion

Posterior shoulder instability is rarer than anterior instability. Its clinical diagnosis is difficult, often delayed or missed. Proper classification is essential for the appropriate treatment to be implemented. Initially, published studies recommended treating patients eligible for surgery with a posterior bone block instead of a capsule procedure because of the particularly high failure rate (up to 23% according to McIntyre [39]) [12,15,40,41]. The contribution of arthroscopy to understanding the pathology and technical improvements have led to more satisfactory results [38,42,43]. We conducted a multicenter retrospective study to ensure we had a sufficient sample size to compare our findings with published studies that often have small cohorts [5,19–25,44–46]. In addition to the small sample sizes, the surgical techniques and length of follow-up in these studies differ. Thus, it is difficult to compare our findings with those of other studies.

Our study confirms this procedure is typically indicated for patients with the following characteristics: male, about 30 years of age, right-handed, recreational athlete with post-traumatic involuntary instability in his dominant arm following an injury. The surgery is mainly performed with an iliac bone graft fixed with

two screws. This surgery leads to good outcomes with significant improvement in the Constant and Walch-Duplay scores and a high satisfaction rate. These findings are consistent with those of three recent studies. Boileau et al. [38] reported a Walch-Duplay score of 89 in a 15-patient study. Schwartz et al. [40] reported a Walch-Duplay score of 82.9 in a 19-patient study. Servien et al. [39] reported a postoperative Constant score of 93.3 in a 21-patient study of iliac bone block.

However, the complication rate in our study cannot be ignored with a 12% recurrence rate (dislocation and subluxation) and 18% patients having persistent pain. This recurrence rate differs from that of other studies, since no recurrence of the dislocation or subluxation was reported by Gosset [20], Essadki et al. [25], and Boileau et al. [44]. Fronek [6] reported one case of recurrence; however most patients in their study had voluntary instability. This is likely related to the small sample size in the above studies.

The persistent postoperative pain is also an important finding in our study. This was also found in the study by Servien et al. [45], who reported pain in 45% of their patients. This pain could be related to insufficient control of posterior translation in bone block procedures done without an associated posterior capsular reconstruction. But it is more likely related to the presence of posteroinferior chondral lesions in 11% of cases ([Fig. 3](#)), which have not been described extensively [47,48]. This pain may also be related to the presence of a reverse Hill-Sachs lesion, which alters joint kinetics and proprioception. This lesion is present in 100% of cases in certain studies [12,22,45] and in 30% of cases in our study.

Bone block resorption was another important finding in our study ([Fig. 4](#)). This alteration is generally not reported in published studies; it occurred in nearly one-third of the patients in our study (major lysis). According to Sirveaux et al. [22], the bone block's overhang is responsible for its partial resorption (100% in their study). They did not find any cases of major lysis in their study.

Conversely, we did not find any other of the previously reported complications, such as an intra-articular screw [22,23]. This technical error can be avoided by having adequate joint exposure. This is technically difficult when using a posterior approach to the shoulder and is sometimes not done when implanting an extra-articular bone block. For this reason, some authors have recommended performing infraspinatus tenotomy [6,12,20,21]. We do not believe this procedure is necessary and none of the patients included in our study required this additional approach. We recommend performing posterior arthrotomy by passing between the infraspinatus and teres minor [5]. Arthroscopy can have an important role in this surgical strategy [44,46,48].

The limitations of this study are mainly related to its retrospective design. For this reason, some data were missing. While this study has a relatively large patient cohort when compared to other published studies, the statistical analysis had low power (non-parametric tests). Our protocol did not include a CT scan at the last follow-up. For this reason, we could only identify lysis of the bone block and qualify it (total or partial), without quantifying the volume of bone lost. Since this was a multicenter study, the surgical technique for implantation of the iliac bone block varied (with or without overhang, extra- or intra-articular). While this variability contributes to bias in cases with less than 2 years' follow-up, it will have a larger impact over time. Lastly, our sample size was not large enough to determine which type of graft was most appropriate (iliac or acromial) and which type of approach was best (open or arthroscopic).

Disclosure of interest

Dr. Clavert reports personal fees from Wright-Tornier, outside the submitted work.

The other authors have not supplied their declaration of competing interest.

References

- [1] Hovelius L. Incidence of shoulder dislocation in Sweden. *Clin Orthop* 1982;166:127–31.
- [2] Scott D. Treatment of recurrent posterior dislocations of the shoulder by glenoplasty. Report of three cases. *J Bone Joint Surg* 1967;49:471–6.
- [3] Petersen S. Posterior shoulder instability. *Orthop Clin North Am* 2000;31:263–74.
- [4] Hawkins R. Glenoid osteotomy for recurrent posterior subluxation of the shoulder: assessment by computed axial tomography. *J Shoulder Elbow Surg* 1996;5:393–400.
- [5] Mowery C, Garfin S, Booth, Rothman R. Recurrent posterior dislocation of the shoulder: treatment using a bone block. *J Bone Joint Surg* 1985;67:777–81.
- [6] Fronek J, Warren R, Bowen M. Posterior subluxation of the glenohumeral joint. *J Bone Joint Surg* 1989;71:205–16.
- [7] Tibone J, Ting A. Capsulorrhaphy with a staple for recurrent posterior subluxation of the shoulder. *J Bone Joint Surg* 1990;72A:999–1002.
- [8] Hawkins R. Arthroscopic stapling repair for shoulder instability: a retrospective study of 50 cases. *Arthroscopy* 1989;5:122–8.
- [9] Boileau P. [Painful shoulder: the only sign of unrecognized instability accidents]. *Rev Chir Orthop Reparatrice Appar Mot* 2000;86:122–5.
- [10] Boileau P, Zumstein M, Balg F, Penington S, Bicknell R. The unstable painful shoulder (UPS) as a cause of pain from unrecognized antero-inferior instability in the young athlete. *J Shoulder Elbow Surg* 2011;20:98–106.
- [11] DeLong J, Jiang K, Bradley J. Posterior instability of the shoulder: a systematic review and meta-analysis of clinical outcomes. *Am J Sports Med* 2015;43:1805–17.
- [12] Fuchs B, Jost B, Gerber C. Posterior-inferior capsular shift for treatment of recurrent, voluntary posterior subluxation of the shoulder. *J Bone Joint Surg* 2000;82:16–25.
- [13] Hawkins R, Janda D. Posterior instability of the glenohumeral joint. A technique of repair. *Am J Sports Med* 1996;24:275–8.
- [14] Burkhead WJ, Rockwood CJ. Treatment of instability of the shoulder with an exercise program. *J Bone Joint Surg* 1992;74:890–6.
- [15] Hurley J, Anderson T, Dear W, Andrich J, Bergfeld J, Weiker G. Posterior shoulder instability: surgical versus conservative results with evaluation of glenoid version. *Am J Sports Med* 1992;20:396–400.
- [16] Hawkins R, Belle R. Posterior instability of the shoulder. *Instr Course Lect* 1989;38:211–5.
- [17] Beall M, Diefenbach G, Allen A. Electromyographic biofeedback in the treatment of voluntary posterior instability of the shoulder. *Am J Sports Med* 1987;15:175–8.
- [18] Pollock R, Bigliani L. Recurrent posterior shoulder instability: diagnosis and treatment. *Clin Orthop* 1993;291:85–96.
- [19] Fried A. Habitual posterior dislocation of the shoulder. *Acta Orthop Scand* 1949;18:329–45.
- [20] Gosset J. Luxations récidivantes postérieures de l'épaule. Technique de butée osseuse scapulaire postérieure. À propos de quatre cas personnels. *Ann Chir* 1976;30:569–72.
- [21] Kouvalchouk J, Coudert X, Watin Augouard L, Da Siva Rosa R, Paszkowski A. Le traitement des instabilités postérieures de l'épaule par butée acromiale pédiculée à un lambeau deltoïdien. *Rev Chir Orthop* 1993;79:661–5.
- [22] Sirveaux F, Roche O, De Gasperi M, Mole D. Traitement de l'instabilité postérieure de l'épaule par butée iliaque ou acromiale : à propos d'une série de 18 cas. *Rev Chir Orthop* 2004;90:411–9.
- [23] Hinojosa J, Fery A, Schmitt D, Sommet J. Recurrent posterior instability of the shoulder. *Int Surg* 1989;74:257–60.
- [24] Ahlgren S, Hedlund T, Nistor L. Idiopathic posterior instability of the shoulder joint. Results of operation with posterior bone graft. *Acta Orthop Scand* 1978;49:600–3.
- [25] Essadki B, Dumontier C, Sautet A, Apoil A. Instabilité postérieure de l'épaule chez le sportif traitée par butée iliaque, à propos de 6 observations. *Rev Chir Orthop* 2000;86:765–72.
- [26] Rocher H. Butée glénoïdienne postérieure par greffon costal dans une subluxation habituelle de l'épaule due à une paralysie obstétricale. *Paris Chir* 1931;2:33–43.
- [27] Ilfeld F, Holder H. Recurrent dislocation of the shoulder joint. *J Bone Joint Surg* 1943;25:156.
- [28] Sauers E, Borsia P, Herling D, Stanley R. Instrumented measurement of glenohumeral joint laxity and its relationship to passive range of motion and generalized joint laxity. *Am J Sports Med* 2001;29:142–50.
- [29] Gerber C, Ganz R. Clinical assessment of instability of the shoulder. With special reference to anterior and posterior drawer test. *J Bone Joint Surg* 1984;66:551–6.
- [30] Constant C, Murley A. A clinical method of functional assessment of the shoulder. *Clin Orthop* 1987;214:160–4.
- [31] Levigne C, Garret J, Walch G. Posterior bone block for posterior instability. *Tech Shoulder Elbow Surg* 2005;6:26–35.
- [32] Fayad F, Mace Y, Lefevre-Colau M, Poiraudou S, Rannou F, Revel M. Measurement of shoulder disability in the athlete: a systematic review. *Ann Readapt Med Phys* 2004;47:389–95.
- [33] Walch G. La luxation récidivante antérieure de l'épaule. *Rev Chir Orthop* 1991;77:177–91.
- [34] Rowe C. Prognosis in dislocation of the shoulder. *J Bone Joint Surg* 1956;38A:957–77.
- [35] Rowe C. The shoulder. Dislocation of the shoulder. Churchill Livingstone; 1988. p. 165–291.
- [36] Gilbert M, Gerber C. Comparison of the subjective shoulder value and the Constant score. *J Shoulder Elbow Surg* 2007;16:717–21.
- [37] Bernageau J. Le bourrelet glénoïdien. *Ann Radiol* 1995;38:266–74.
- [38] Kim S, Ha K, Park J, Kim Y, Lee Y, Lee J, et al. Arthroscopic posterior labral repair and capsular shift for traumatic unidirectional recurrent posterior subluxation of the shoulder. *J Bone Joint Surg* 2003;85:1479–87.
- [39] McIntyre L, Caspari R, Savoie F. The arthroscopic treatment of posterior shoulder instability: two-years results of a multiple suture technique. *Arthroscopy* 1997;13:426–32.
- [40] Abrams J, Savoie F, Tauro J, Bradley J. Recent advances in the evaluation and treatment of shoulder instability: anterior, posterior, and multidirectional. *Arthroscopy* 2002;18:1–13.
- [41] Heller K, Forst J, Cohen B, Forst R. Atraumatic recurrent posterior shoulder subluxation: review of the literature and recommendations for treatment. *Acta Orthop Belg* 1995;61:263–70.
- [42] Williams R, Strickland S, Cohen M, Altchek D, Warren R. Arthroscopic repair for traumatic posterior shoulder instability. *Am J Sports Med* 2003;31:203–9.
- [43] Wolf E, Eakin C. Arthroscopic capsular plication for posterior shoulder instability. *Arthroscopy* 1998;14:153–63.
- [44] Boileau P, Hardy M, McClelland W, Thélu C, Schwartz D. Arthroscopic posterior bone block procedure: a new technique using suture anchor fixation. *Arthroscopy Techniques* 2013;2:e473–7.
- [45] Servien E, Walch G, Cortes Z, Edwards T, O'Connor D. Posterior bone block procedure for posterior shoulder instability. *Knee Surg Sports Traumatol Arthrosc* 2007;15:1130–6.
- [46] Schwartz D, Goebel S, Piper K, Kordasiewicz B, Boyle S, Lafosse L. Arthroscopic posterior bone block augmentation in posterior shoulder instability. *J Shoulder Elbow Surg* 2013;22:1092–101.
- [47] Robinson C, Aderinto J. Recurrent posterior shoulder instability. *J Bone Joint Surg* 2005;87:883–92.
- [48] Buess E, Waibl B, Sieverding M, Halbgewachs J. Posteroinferior shoulder instability: clinical outcome of arthroscopic stabilization in 32 shoulders and categorization based on labral mapping. *Arch Orthop Trauma Surg* 2015;135:673–81.