



## **Painful posterior shoulder instability: anticipating and preventing failure. A study in 25 patients.**

Jérôme Garret, Geoffroy Nourissat, Marie-Béatrice Hardy, Diego Antonucci, Philippe Clavert, Pierre Mansat, Arnaud Godenèche

### **► To cite this version:**

Jérôme Garret, Geoffroy Nourissat, Marie-Béatrice Hardy, Diego Antonucci, Philippe Clavert, et al.. Painful posterior shoulder instability: anticipating and preventing failure. A study in 25 patients.. Orthopaedics & Traumatology: Surgery & Research, 2017, 103 (8), pp.S199-S202. 10.1016/j.otsr.2017.08.005 . hal-02135088

**HAL Id: hal-02135088**

**<https://hal.science/hal-02135088>**

Submitted on 21 May 2019

**HAL** is a multi-disciplinary open access archive for the deposit and dissemination of scientific research documents, whether they are published or not. The documents may come from teaching and research institutions in France or abroad, or from public or private research centers.

L'archive ouverte pluridisciplinaire **HAL**, est destinée au dépôt et à la diffusion de documents scientifiques de niveau recherche, publiés ou non, émanant des établissements d'enseignement et de recherche français ou étrangers, des laboratoires publics ou privés.




## Open Archive Toulouse Archive Ouverte (OATAO)

OATAO is an open access repository that collects the work of some Toulouse researchers and makes it freely available over the web where possible.

This is an author's version published in: <https://oatao.univ-toulouse.fr/23106>

**Official URL :** <https://doi.org/10.1016/j.otsr.2017.08.005>

### To cite this version :

Garret, Jérôme and Nourissat, Geoffroy and Hardy, Marie-Béatrice and Antonucci, Diego and Clavert, Philippe and Mansat, Pierre  and Godenèche, Arnaud *Painful posterior shoulder instability: anticipating and preventing failure. A study in 25 patients.* (2017) Orthopaedics & Traumatology: Surgery & Research, 103 (8). S199-S202. ISSN 1877-0568

Any correspondence concerning this service should be sent to the repository administrator:

[tech-oatao@listes-diff.inp-toulouse.fr](mailto:tech-oatao@listes-diff.inp-toulouse.fr)

# Painful posterior shoulder instability: Anticipating and preventing failure. A study in 25 patients

J. Garret <sup>a,\*</sup>, G. Nourissat <sup>b</sup>, M.B. Hardy <sup>c</sup>, D. Antonucci <sup>d</sup>, P. Clavert <sup>e</sup>, P. Mansat <sup>f</sup>, A. Godenèche <sup>g</sup>, the French Arthroscopy Society

<sup>a</sup> Clinique du Parc, 155, boulevard Stalingrad, 69006 Lyon, France

<sup>b</sup> Clinique des Maussins-Ramsay-Générale-de-Santé, 67, rue de Romainville, 75019 Paris, France

<sup>c</sup> Clinique Mutualiste Chirurgicale, 3, rue le Verrier, 42100 Saint-Étienne, France

<sup>d</sup> Clinica Ortopedica e Traumatologica, Università degli Studi di Pavia, Fondazione IRCCS Policlinico San Matteo, Pavia, Italy

<sup>e</sup> Service de chirurgie du membre supérieur, CCOM, Laboratoire iCube, CNRS UMR 7357, Équipe 12 Matériaux Multi-échelles et Biomécanique, Institut de Mécanique des Fluides et des Solides, CHRU de Strasbourg, 2–4, rue Boussingault, 67000 Strasbourg, France

<sup>f</sup> Département d'Orthopédie-Traumatologie, Hôpital Riquet, CHU-Purpan, place du Dr.-Baylac, 31059 Toulouse, France

<sup>g</sup> Ransay Générale de Santé, Centre Orthopédique Santy, Hôpital Privé Jean-Mermoz, 69008 Lyon, France

## A B S T R A C T

### Keywords:

Posterior shoulder instability  
Painful shoulder instability  
Capsulo-labral reconstruction  
Posterior bone block procedure  
Shoulder pain in athletes

**Background:** Painful posterior shoulder instability (PPSI) is the least common of the three clinical patterns of posterior shoulder instability. PPSI is defined as pain combined with anatomical evidence of posterior instability but no instability events.

**Material and method:** We studied a multicentre cohort of 25 patients with PPSI; 23 were identified retrospectively and had a follow-up of at least 2 years and 2 patients were included prospectively. Most patients engaged in sports.

**Results:** All 25 patients underwent surgery, which usually consisted in arthroscopic capsulo-labral reconstruction. The outcome was excellent in 43% of patients; another 43% had improvements but reported persistent pain. The pain remained unchanged or worsened in the remaining 14% of patients. Causes of failure consisted of a missed diagnosis of shoulder osteoarthritis with posterior subluxation, technical errors, and postoperative complications. The main cause of incomplete improvement with persistent pain was presence of cartilage damage.

**Conclusion:** Outcomes were excellent in patients who were free of cartilage damage, bony abnormalities associated with posterior instability (reverse Hill–Sachs lesion, erosion or fracture of the posterior glenoid), technical errors, and postoperative complications.

## 1. Introduction

Posterior shoulder instability (PSI) is a rare condition that accounts for only 2% to 10% of all cases of shoulder instability [1–5]. PSI differs from anterior shoulder instability regarding the clinical manifestations, diagnosis, and treatment.

Clinically, PSI presents as three different entities [6]: recurrent involuntary posterior dislocation and/or subluxation; voluntary PSI, which may progress to involuntary PSI; and painful PSI (PPSI), in which pain is the only symptom. Three main treatment approaches can be distinguished: non-operative treatment, surgical stabilisation by capsulo-labral reconstruction, and surgical stabilisation via a bone block procedure.

This multicentre study reports outcomes in patients with painful PPSI, i.e., with no history of dislocation or subluxation. The patients were included retrospectively or prospectively. The study objectives were to assess the features of PPSI and the effectiveness of the treatments used and to devise means of anticipating and preventing treatment failures. The working hypothesis was that treatment outcomes were more variable in PPSI than in other patterns of PSI.

\* Corresponding author.

E-mail addresses: j.garret@cliniqueduparclyon.com (J. Garret), gnourissat@wanadoo.fr (G. Nourissat), mariebeatricehardy@gmail.com (M.B. Hardy), antonucci.diego01@gmail.com (D. Antonucci), philippe.clavert@chru-strasbourg.fr (P. Clavert), mansat.p@chu-toulouse.fr (P. Mansat), arnaud.godenèche@wanadoo.fr (A. Godenèche).

2. Material and methods

2.1. Patients

Two multicentre studies, one retrospective and the other prospective, were approved by the appropriate ethics committee. Of 203 patients treated for PPSI, 151 were included retrospectively; all these patients were treated surgically and re-evaluated at least 2 years after surgery. The remaining 52 patients were treated non-operatively or surgically. The patients were recruited by 17 surgeons in 11 centres in France.

The patients were divided into three clinical subgroups: involuntary dislocation and/or subluxation (the largest subgroup); voluntary PSI with or without progression to involuntary PSI; and PPSI (the smallest subgroup). PPSI was defined as pain with anatomical findings indicating posterior instability but no instability events.

2.2. Data collection

We recorded the following data: sex; side involved; dominant side; age at symptom onset; age at treatment; sports activities; whether PPSI was due to trauma; overall shoulder mobility; shoulder laxity; Beighton’s criteria [7]; and results of posterior, anterior, and inferior apprehension tests. Standard radiographs (antero-posterior views in neutral, external, and internal rotation and scapular Y view) and axial slice images with intra-articular contrast injection (computed tomography [CT] and/or magnetic resonance imaging) were evaluated. Treatment outcomes were evaluated based on the Constant’s pain subscore (with a value of 0 indicating the worst pain possible and a value of 15 no pain), Constant’s score [8–10], and the Subjective Shoulder Value (SSV) [11].

2.3. Statistical analysis

Descriptive statistics were computed. The Shapiro–Wilk test was used to assess distribution normality. Differences between mean values were compared by applying Student’s test when distribution was normal and the Mann–Whitney test otherwise. The Chi<sup>2</sup> test was chosen to evaluate associations linking categorical variables. Statistical analyses were performed using R software version 3.3.3. (R Foundation, Vienna, Austria). Values of *P* < 0.05 were considered statistically significant.

3. Results

3.1. Patients

Of the 25 study patients with PPSI, 23 were included retrospectively and 2 prospectively. There were 16 males and 9 females with a mean age of 30 years (range, 16–45 years). The right shoulder was involved in 15 patients and the left shoulder in 10 patients; the dominant side was involved in 68% of cases. A history of trauma was noted in 80% of patients. Furthermore, 84% of patients reported engaging in sports overall, 46% in recreational sports, and 38% in competitions. Among patients with sports activities, 83% participated in sports that place strain on the shoulders (boxing,

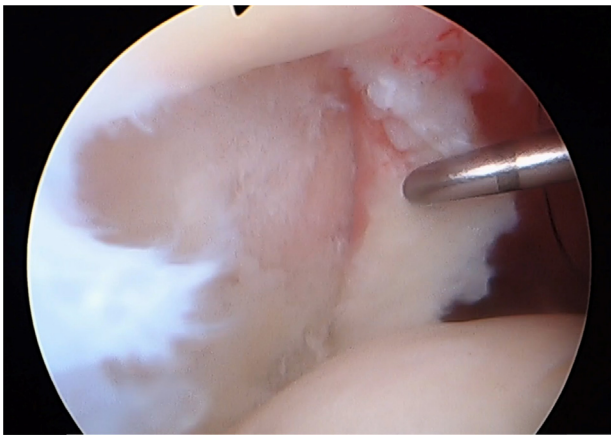


Fig. 1. Posterior cartilage damage.

handball, volleyball, tennis, judo, rugby, weight-lifting) (Table 1). Mean time from symptom onset to surgery was 23 months (median, 15 months; range, 3–93 months).

3.2. Physical findings

The posterior apprehension test in adduction and internal rotation was positive in 40% of patients, the anterior apprehension test in abduction and external rotation in 40% of patients, and the inferior Gagey apprehension test in 20% of patients [12]. The anterior test was the only positive apprehension test in 20% of patients.

3.3. Imaging study findings

On the imaging studies, 52% of shoulders had no bony abnormalities related to instability (glenoid erosion or fracture, reverse Hills–Sachs notch). In contrast, 22% of shoulders had damage to the glenoid cartilage. In keeping with this finding, the surgical exploration found cartilage damage to the glenoid in 28% of cases (Fig. 1) and to the humeral head in 8% of cases.

3.4. Management

All 25 patients underwent surgical treatment. Surgery consisted in arthroscopic capsulo-labral reconstruction in 22 patients (Fig. 2). An overhanging iliac bone block was implanted in 2 patients and a flush acromial bone block in 1 patient. After surgery, the shoulder was immobilised in neutral rotation in 74% of patients.

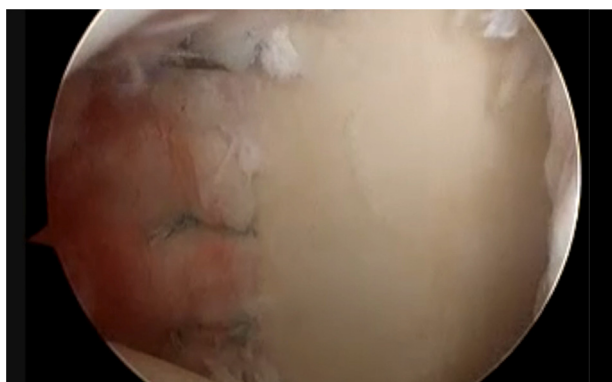
3.5. Outcomes

3.5.1. Overall outcomes

The SSV improved from 45% before surgery to 82% after surgery. After surgery, the Walch–Duplay score was 76 and the Rowe score was 81. The crude Constant score improved from 67 preoperatively to 81 postoperatively (Table 2). After surgery, 74% of patients reported being satisfied by the procedure and had resumed their main sports activity.

Table 1  
Study patients.

	Sex	Side	Age (years)	Trauma	Sports
25 patients	16 (64%) males 9 (36%) females	Right, <i>n</i> = 15 (60%) Left, <i>n</i> = 10 (40%) Dominant side involved in 17/25 (68%)	Minimum 16 Maximum 45 Mean, 30	Yes, 20/25 (80%) No, 5/25 (20%)	Competition, 9/25 (38%) Recreational, 12/25 (46%) None, 4/25 (16%)



**Fig. 2.** Re-attachment of the posterior labrum.

**Table 2**  
Functional and subjective outcomes.

	Before surgery	After surgery
Constant, pain subscore	6	11.3
Constant, total score	67	83
SSV	45	82
Walch–Duplay score		76
Rowe score		81

SSV: Subjective Shoulder Value.

**Table 3**  
Constant pain subscore.

	Pain subscore	Percentage
Marked pain relief	13/15 to 15/15	44
Moderate pain relief	10/15 to 12/15	44
No pain relief	Lower than 5/15	12

### 3.5.2. Clinical outcomes

The assessment of postoperative pain differentiated three groups of patients (Table 3). Major pain relief defined as a Constant pain subscore of 13–15 was noted in 43% of patients and moderate pain relief with a Constant pain subscore of 10–12 in 43% of patients. The treatment failed in the remaining 3 (14%) patients, who had unchanged or worsened pain with a Constant pain subscore lower than 5.

### 3.5.3. Anatomical outcomes

Of the 3 patients with treatment failure, 1 had bipolar osteoarthritis with static posterior subluxation, 1 had early anchor migration, and 1 had acromial block nonunion.

Partial improvement was noted in 11 patients with persistent but moderate pain. Among them, 50% had glenoid cartilage damage visible during arthroscopy and 40% on imaging studies. In this group, 2 patients had postoperative shoulder stiffness, 1 had osteolysis of an iliac bone block, and 2 had deep reverse Hill–Sachs notches.

Surgery was successful in 11 patients, who reported little or no postoperative pain. None of these patients had cartilage damage, postoperative shoulder stiffness, surgical complications (anchor migration or bone block lysis), or reverse Hill–Sachs notches.

## 4. Discussion

The shoulder is the least stable joint in the body, with less than one-third of the humeral head surface in contact with the glenoid cavity. Static stability is provided by the joint cartilage, labrum, and ligaments [13]. The structures responsible for posterior stability are the posterior capsule, inferior glenohumeral ligament, and

posterior labrum. Damage to any of these structures can therefore result in PSI [4,14]. Our study confirms the existence of PPSI as a clinical entity in which pain is the only symptom. Furthermore, the results support our hypothesis that treatment outcomes vary, depending on the presence of preexisting bone and cartilage lesions.

The patient profile was similar to that seen in involuntary PSI. Thus, many patients engaged in sports that put strain on the shoulders and reported a trauma as the inciting event. No patients had ligament laxity or joint hypermobility. Time from symptom onset to surgery was less than 2 years in the patients with PPSI, compared to 6 years in the group with involuntary PSI and 8 years in the group with voluntary-to-involuntary PSI. These differences suggest that pain may be less well tolerated than posterior instability events.

The physical findings were limited. Thus, the posterior apprehension test was negative in over 60% of patients and the only positive apprehension test was anterior in 20% of patients. The diagnostic was usually provided by a finding of posterior labral damage on imaging studies.

The main preoperative predictor of treatment outcomes was the presence of cartilage damage. The differential diagnoses of PPSI are incipient posterior osteoarthritis with subluxation and postero-superior impingement syndrome. Diagnostic errors may lead to inappropriate stabilising surgery, which may worsen the condition [13].

Compared to the other PSI groups, the PPSI group had a higher proportion of patients managed by capsulo-labral reconstruction. The rationale for this procedure is the absence of bony alterations associated with instability and of ligament laxity. A meta-analysis indicated that arthroscopic capsulo-labral reconstruction provided better outcomes compared to bone block procedures [16]. Surgery should be considered in patients who have failed optimal non-operative treatment given for at least 6 months. Non-operative treatment consists of proprioception exercises, strengthening exercises for the external rotators and scapular stabilisers, and sports activity modification [4].

## 5. Conclusion

PPSI with pain as the only symptom is the least common presentation of PSI. The diagnosis is often provided by imaging studies performed to assess shoulder pain in a young athlete. Surgical capsulo-labral reconstruction, seems to be a reliable treatment option [16] that produces good outcomes in patients without preexisting cartilage damage, postoperative complications, or postoperative shoulder stiffness. Damage to the posterior glenoid cartilage predicts incomplete improvement after surgery and should be sought routinely. The most common causes of treatment failure are diagnostic errors, technical errors, and post-operative complications [15].

## Disclosure of interest

The authors declare that they have no competing interest.

## References

- [1] Antosh J, Tokish J, Owens B. Posterior shoulder instability: current surgical management. *Sports Health* 2016;8:520–6.
- [2] Wooten CJ, Krych AJ, Schleck CD, Hudgens JL, May JH, Dahm DL. Arthroscopic capsulolabral reconstruction for posterior shoulder instability in patients 18 years old or younger. *Pediatr Orthop* 2015;35:462–6.
- [3] Owens BD, Campbell SE, Cameron KL. Risk factors for posterior shoulder instability in young athletes. *Am J Sports Med* 2013;41:2645–9.
- [4] Tannenbaum E, Sekiya JK. Evaluation and management of posterior shoulder instability. *Sports Health* 2011;3:253–63.

- [5] Bottoni CR, Franks BR, Moore JH, DeBerardino TM, Taylor DC, Arciero RA. Operative stabilization of posterior shoulder instability. *Am J Sports Med* 2005;33:996–1002.
- [6] Boileau P, Zumstein M, Balg F, Penington S, Bicknell RT. The unstable painful shoulder (UPS) as cause of pain from unrecognized anteroinferior instability in the young athlete. *J Shoulder Elbow Surg* 2011;20:98–106.
- [7] Beighton PH, Horan F. Orthopedic aspects of the Ehlers–Danlos syndrome. *J Bone Joint Surg Br* 1969;51:444–53 [Beighton score].
- [8] Roy JS, MacDermid JC, Woodhouse LJ. A systematic review of the psychometric properties of the Constant–Murley score. *J Shoulder Elbow Surg* 2010;19:157–64.
- [9] Constant CR, Murley AH. A clinical method of functional assessment of the shoulder. *Clin Orthop Relat Res* 1987;160–4.
- [10] Wright RW, Baumgarten KM. Shoulder outcomes measures. *J Am Acad Orthop Surg* 2010;18:436–44.
- [11] Gilbert MK, Gerber C. Comparison of the subjective shoulder value and the Constant score. *J Shoulder Elbow Surg* 2007;16:717–21.
- [12] Gagey OJ, Gagey N. The hyperabduction test. *J Bone Joint Surg Br* 2001;83:69–74.
- [13] Wang VM, Flatow EL. Pathomechanics of acquired shoulder instability: a basic science perspective. *J Shoulder Elbow Surg* 2005;14 [2S–11S].
- [14] Pagnani MJ, Warren RF. Stabilizers of the glenohumeral joint. *J Shoulder Elbow Surg* 1994;3:173–90.
- [15] Bradley JP, Baker 3rd CL, Kline AJ, Armfield DR, Chhabra A. Arthroscopic capsulolabral reconstruction for posterior instability of the shoulder: prospective study of 100 shoulders. *Am J Sports Med* 2006;34:1061–71.
- [16] DeLong JM, Jiang K, Bradley JP. Posterior instability of the shoulder: a systematic review and meta-analysis of clinical outcomes. *Am J Sports Med* 2015;43:1805–17.