



HAL
open science

Arthroscopic osteochondral autograft transfer for juvenile osteochondritis dissecans of the humeral head

Thuy Trang Pham, Jean Kany, Walid Lakhal, Jérôme Sales de Gauzy, Franck
Accadbled

► **To cite this version:**

Thuy Trang Pham, Jean Kany, Walid Lakhal, Jérôme Sales de Gauzy, Franck Accadbled. Arthroscopic osteochondral autograft transfer for juvenile osteochondritis dissecans of the humeral head. *Journal of bone & joint surgery case connector*, 2017, 7 (3), pp.e63-e67. 10.2106/JBJS.CC.17.00003 . hal-02135079

HAL Id: hal-02135079

<https://hal.science/hal-02135079>

Submitted on 21 May 2019

HAL is a multi-disciplinary open access archive for the deposit and dissemination of scientific research documents, whether they are published or not. The documents may come from teaching and research institutions in France or abroad, or from public or private research centers.

L'archive ouverte pluridisciplinaire **HAL**, est destinée au dépôt et à la diffusion de documents scientifiques de niveau recherche, publiés ou non, émanant des établissements d'enseignement et de recherche français ou étrangers, des laboratoires publics ou privés.



Open Archive Toulouse Archive Ouverte (OATAO)

OATAO is an open access repository that collects the work of some Toulouse researchers and makes it freely available over the web where possible.

This is an author's version published in: <https://oatao.univ-toulouse.fr/23115>

Official URL : <https://doi.org/10.2106/JBJS.CC.17.00003>

To cite this version :

Pham, Thuy Trang and Kany, Jean and Lakhali, Walid and Sales de Gauzy, Jérôme and Accadbled, Franck *Arthroscopic Osteochondral Autograft Transfer for Juvenile Osteochondritis Dissecans of the Humeral Head*. (2017) *JBJS Case Connector*, 7 (3). e63-e67. ISSN 2160-3251

Any correspondence concerning this service should be sent to the repository administrator:

tech-oatao@listes-diff.inp-toulouse.fr

Arthroscopic Osteochondral Autograft Transfer for Juvenile Osteochondritis Dissecans of the Humeral Head

A Case Report

Thuy Trang Pham, MD, Jean Kany, MD, Walid Lakhal, MD, Jérôme Sales de Gauzy, PhD, and Franck Accadbled, PhD

Investigation performed at Service de Chirurgie Orthopédique Pédiatrique, Hôpital des Enfants, CHU de Toulouse, Toulouse, France

Abstract

Case: Osteochondritis dissecans (OCD) rarely affects the humeral head. We describe a 14-year-old adolescent who, despite conservative treatment, had persistent pain in the left shoulder as well as limited function. Radiographs and a computed tomography (CT) arthrogram revealed an osteochondral defect of the humeral head. He was managed with an arthroscopic osteochondral autograft transfer from the knee, which provided a satisfactory outcome.

Conclusion: Arthroscopic osteochondral autograft transfer is an effective option for the treatment of OCD of the humeral head.

Osteochondritis dissecans (OCD) is a well-described pathology of the knee, the capitellum, and the talar dome. To our knowledge, very few cases of OCD of the humeral head have been reported. Several treatment options, including activity limitation and osteochondral allograft transfer, have been described¹⁻³. We present our experience with an adolescent patient with OCD of the humeral head who was treated with an arthroscopic osteochondral autograft transfer.

The patient and his parents were informed that data concerning the case would be submitted for publication, and they provided consent.

Case Report

A right-hand-dominant 14-year-old boy presented to our department with a 2-year history of left shoulder pain. There was no history of initial trauma. The symptoms had been progressively worsening, causing him to cease sports activity, including soccer and karate. He previously had visited an orthopaedic surgeon who had initially advised rest and prescribed pain medication (nonsteroidal anti-inflammatory drugs), and eventually had prescribed shoulder immobilization and physiotherapy, with little and transient improvement. On physical examination, the passive range of motion was 30° of elevation, 10° of abduction, 30° of external rotation, and internal rotation to the greater

trochanter. Pain was rated 10 of 10 on the visual analog scale (VAS). The Constant score was 8 of 100 points. There was no vasomotor dysfunction. Radiographs and a computed tomography (CT) arthrogram showed a 1.2-cm² osteochondral defect on the superomedial aspect of the humeral head, without any osseous fragments or loose bodies (Fig. 1). We decided to perform an arthroscopic osteochondral autograft transfer.

Surgical Procedure

The patient was placed in the beach-chair position, and a tourniquet was placed on the ipsilateral thigh. Shoulder testing under general anesthesia demonstrated full range of motion. Shoulder arthroscopy was performed using the posterior and anteromedial portals. Exploration of the glenohumeral joint showed a 1.5-cm² osteochondral defect with marked surrounding synovitis (Fig. 2) but no loose bodies. The coracoacromial ligament was released to allow correct positioning of the graft harvester perpendicular to the lesion. A synovectomy was performed, and the defect was debrided with a curet. A template with a diameter of 10 mm was positioned in the defect, and the same diameter was selected for the graft. A cylindrical cutter (COR Precision Targeting System; DePuy Synthes, Mitek) with a 10-mm diameter was used to harvest a 15-mm-deep bone plug from the center of the lesion through the anteromedial portal.

Disclosure: The authors indicated that no external funding was received for any aspect of this work.

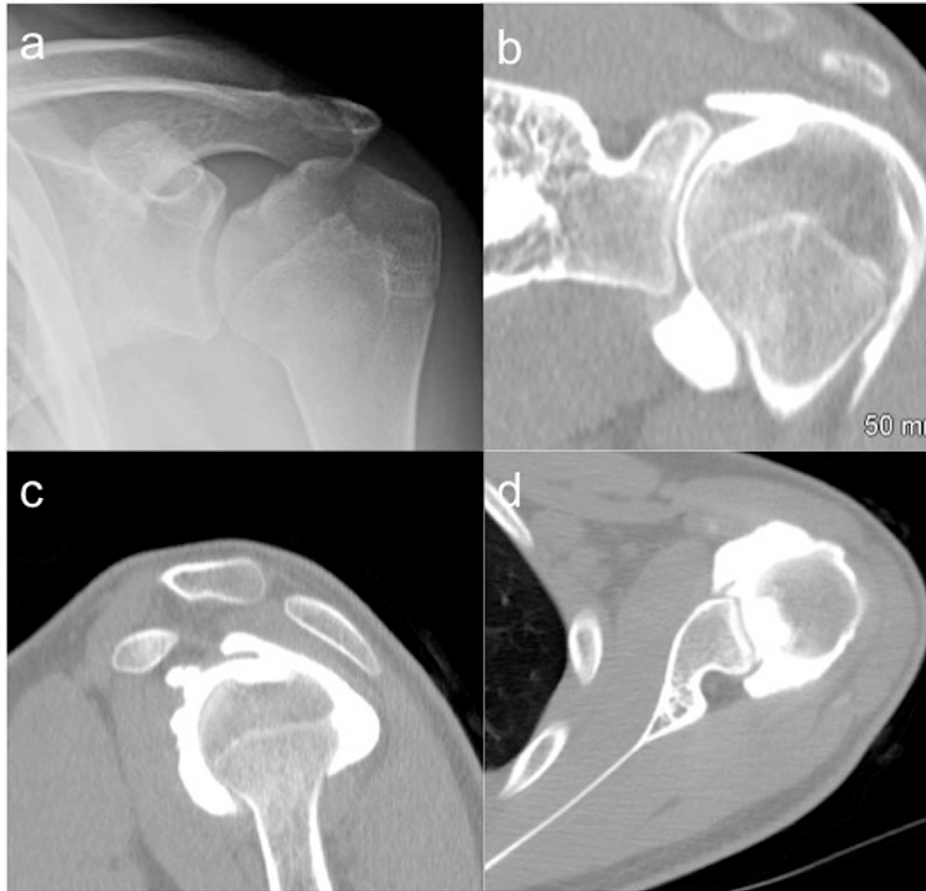

Fig. 1
Preoperative anteroposterior radiograph (**Fig. 1 A**) and CT arthrograms (**Figs. 1 B, 1 C, and 1 D**) of the left shoulder showing the osteochondral defect.

Next, a knee arthroscopy was performed using 2 standard anterior and 1 accessory medial parapatellar portals. The graft was harvested from the superomedial ridge of the femoral trochlea. A cylindrical core (10 mm in diameter and 15 mm deep) was obtained. Then, the recipient site in the humeral head was filled with the donor osteochondral graft from the knee. A level joint surface was obtained. The donor site in the knee was filled with the graft from the humeral head to prevent knee hemarthrosis (Video 1).

The arm was kept in a sling for 3 weeks postsurgery. Passive and active-assisted mobilization were started immediately after the surgery, and active exercise was started after 3 weeks. Full weight-bearing was allowed immediately after the surgery.

At the 26-month follow-up, the patient had no pain, and the VAS score was 0 of 10. He had recovered full range of motion and had normal function. The Constant score was 92 of 100 points, and the subjective shoulder value (SSV) was 70%. He resumed all sports activities. No complications related to the donor site were observed. Magnetic resonance imaging (MRI) showed healing of the osteochondral defect with normal thickness of the grafted cartilage in comparison to the surrounding articular cartilage (Fig. 3).

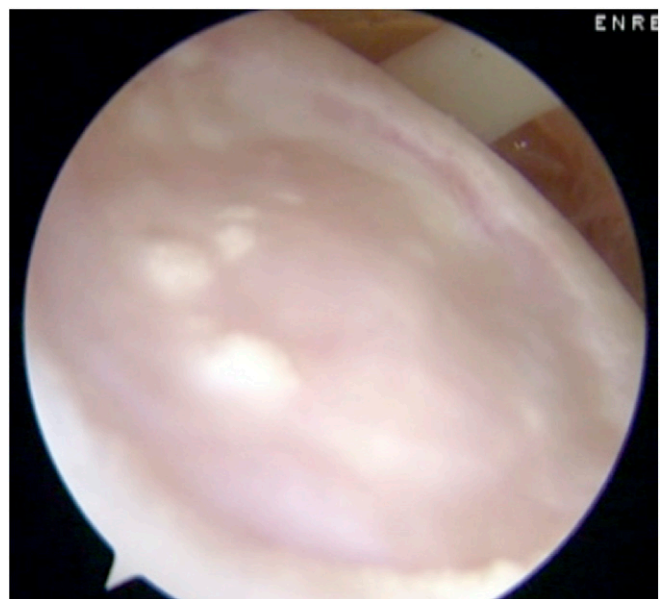


Fig. 2
Arthroscopic view showing an osteochondral defect at the superomedial aspect of the humeral head.

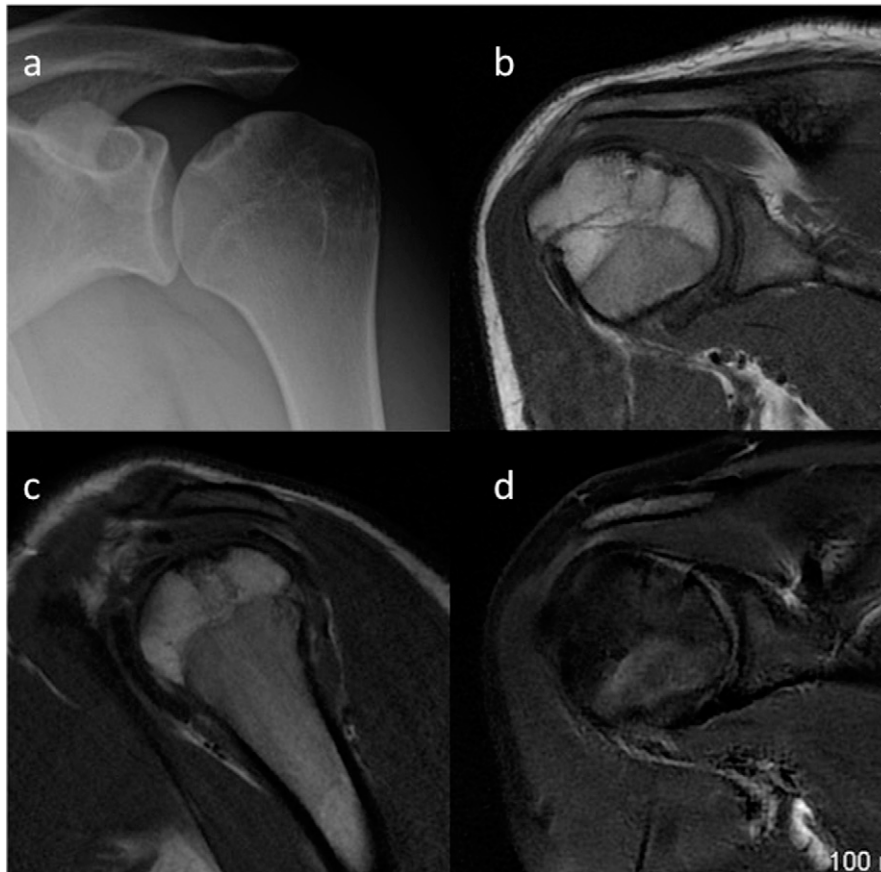


Fig. 3 Anteroposterior radiograph (Fig. 3 A) and MRI scans (Figs. 3 B [T1 weighted], 3 C [T1 weighted], and 3 D [fat saturated T2 weighted]) at the 26 month follow up showing the integrated graft and a level joint surface.

Discussion

OCD of the humeral head is rare; to our knowledge, only 14 cases previously have been reported¹⁻¹³ (Table I). In most of these cases, the patients were men and it occurred on the dominant side. The origin of this condition remains unknown. The most commonly suggested hypothesis is the combined effect of acute trauma or repetitive micro-traumatic injury and the disturbance of local microvasculature. OCD of the humeral head is rather frequent in dogs; because it occurs in the weight-bearing limbs of these quadrupeds, the role of mechanical strain is strongly suggested¹⁴. In our patient, no history of traumatic or micro-traumatic injury was noted, and the nondominant shoulder was affected.

Several treatment options have been described in the literature. Management includes conservative treatment with rest and activity restriction or surgical treatment, including debridement, removal of loose fragments, curettage, and drilling of the lesion. Other surgical treatments that have been reported include osteochondral allograft transfer in 1 case⁹, osteochondral autograft transfer in 1 case¹, and osteochondral fragment fixation with poly-L-lactic acid pins in 1 case¹². Johnson and Warner reported a case of OCD

involving the posterosuperior aspect of the humeral head in a right-hand-dominant 19-year-old man⁹. The patient underwent primary arthroscopic debridement and removal of the loose bodies, but the symptoms returned after 1 year. A second arthroscopic debridement was performed, but the pain resumed after 6 months. Next, reconstruction of the humeral head was performed with an osteochondral allograft through an open deltopectoral approach. At the 3-year follow-up, the patient had no pain and had full range of motion⁹. Many of the reported patients, treated with debridement, curettage, drilling, or removal of the loose fragments, were followed for <1 year, which did not allow assessment of the long-term clinical outcome. At the 26-month follow-up, our patient had no pain and had full range of motion. This result is consistent with the findings of Park et al.¹ In their patient, a biopsy taken during the second-look arthroscopy 5 months following the initial surgery showed a normal pattern of hyaline cartilage.

Surgical alternatives include microfracture and autologous chondrocyte implantation¹⁵. Microfracture can provide satisfactory early results, but there can be deterioration over the long term¹⁶. Therefore, we did not use this

TABLE I Characteristics of Reported OCD Cases of the Humeral Head*

Authors	No.	Age (yr)	Sex	Side	Dominant Side	Localization	Treatment	Last Follow up	Results
Park et al. ¹	1	13	M	Left	Right	Posterosuperior	Osteochondral autograft transfer	2 years, 7 months	No symptoms, good functional results
Mahirogullari et al. ⁴	1	15	M	Right	Right	Posterosuperior	Debridement and removal of loose fragment	10 months	No symptoms, complete range of motion
Mima et al. ¹²	1	29	M	Right	Right	Medial	Fixation of the osteochondral fragment with poly L lactic acid pins	4 years	Good clinical results; ASES, 89.2
Anderson and Guilford ⁶	1	28	M	Right	Right	Superior	Drilling	6 weeks	Complete range of motion
Ganter and Reichelt ¹³	2	26	M	Left	Right	Superior	Drilling		
		36	F	Bilateral		Superior	None		
Hamada et al. ²	1	12	M	Right	Right	Posterosuperior	Removal, curettage, drilling	1 year, 7 months	No pain
Ishikawa et al. ¹¹	1	44	M	Right	Right	Anterosuperior	Rest (after arthroscopic examination)	8 months	No pain, complete range of motion
Johnson and Warner ⁹	1	19	M	Right	Right	Posterosuperior	Osteochondral allograft (after 2 arthroscopic debridements)	3 years	No pain, return to sport activities
Miller and Hilkevitch ¹⁰	1	40	M	Right		Anterosuperior	Removal, curettage, drilling		
Petrini et al. ⁵	1	17	M	Left		Anterosuperior	Rest		
Pydisetty et al. ⁸	1	15	M	Left	Right	Anterosuperior	Rest	6 months	No pain
Debeer and Brys ⁷	1	17	M	Right	Right	Central	None	6 months	No pain, normal range of motion
Lunden and Legrand ³	1	16	M	Right	Right	Superior	Drilling	4 months	No pain, return to basketball
Current case	1	14	M	Left	Right	Superomedial	Arthroscopic osteochondral autograft transfer	2 years, 2 months	No pain; Constant score, 92 points

*OCD = osteochondritis dissecans, and ASES = American Shoulder and Elbow Surgeons score.

technique in our young patient. Conversely, osteochondral transfer has shown very satisfactory results for OCD lesions in the knee that are within this size range¹⁷. It is a rather

simple technique that can be performed arthroscopically in a single step, as opposed to autologous chondrocyte implantation¹⁸.

In summary, arthroscopic osteochondral autograft transfer is an effective option for the treatment of OCD of the humeral head. However, we believe that a longer follow-up period is necessary to demonstrate its effectiveness. ■

Thuy Trang Pham, MD¹
Jean Kany, MD²
Walid Lakkhal, MD³

Jérôme Sales de Gauzy, PhD¹
Franck Accadbled, PhD¹

¹Service de Chirurgie Orthopédique Pédiatrique, Hôpital des Enfants, CHU de Toulouse, Toulouse, France

²Service de Chirurgie Orthopédique, Clinique de l'Union, Saint Jean, France

³Service de Chirurgie Orthopédique Pédiatrique, Le Centre Hospitalier Régional Universitaire de Tours, Tours, France

E mail address for T.T. Pham: francethuytrang@yahoo.fr

References

1. Park TS, Kim TS, Cho JH. Arthroscopic osteochondral autograft transfer in the treatment of an osteochondral defect of the humeral head: report of one case. *J Shoulder Elbow Surg.* 2006 Nov Dec;15(6):e31 6. Epub 2006 Aug 4.
2. Hamada S, Hamada M, Nishiue S, Doi T. Osteochondritis dissecans of the humeral head. *Arthroscopy.* 1992;8(1):132 7.
3. Lunden JB, Legrand AB. Osteochondritis dissecans of the humeral head. *J Orthop Sports Phys Ther.* 2012 Oct;42(10):886. Epub 2012 Sep 28.
4. Mahirogullari M, Chloros GD, Wiesler ER, Ferguson C, Poehling GG. Osteochondritis dissecans of the humeral head. *Joint Bone Spine.* 2008 Mar;75(2):226 8. Epub 2007 Aug 31.
5. Petrini A, Grassi G, Pranzo Zaccaria C. Osteochondritis dissecans of the humeral head. *Chir Organi Mov.* 1984 Jan Mar;69(1):83 5.
6. Anderson WJ, Guilford WB. Osteochondritis dissecans of the humeral head. An unusual cause of shoulder pain. *Clin Orthop Relat Res.* 1983 Mar;173:166 8.
7. Debeer P, Brys P. Osteochondritis dissecans of the humeral head: clinical and radiological findings. *Acta Orthop Belg.* 2005 Aug;71(4):484 8.
8. Pydisetty RV, Prasad SS, Kaye JC. Osteochondritis dissecans of the humeral head in an amateur boxer. *J Shoulder Elbow Surg.* 2002 Nov Dec;11(6):630 2.
9. Johnson DL, Warner JJ. Osteochondritis dissecans of the humeral head: treatment with a matched osteochondral allograft. *J Shoulder Elbow Surg.* 1997 Mar Apr;6(2):160 3.
10. Miller LF, Hilkevitch A. Osteochondritis dissecans of the shoulder. *Am J Roentgenol Radium Ther.* 1950 Feb;63(2):223 7, illust.
11. Ishikawa H, Ueba Y, Yonezawa T, Kurosaka M, Ohno O, Hirohata K. Osteochondritis dissecans of the shoulder in a tennis player. *Am J Sports Med.* 1988 Sep Oct;16(5):547 50.
12. Mima Y, Matsumura N, Ogawa K, Iwamoto T, Ochi K, Sato K, Toyama Y. Osteochondritis dissecans on the medial aspect of the humeral head. *Int J Shoulder Surg.* 2016 Apr Jun;10(2):89 91.
13. Ganter M, Reichelt A. Osteochondrosis dissecans of the humeral head. *Z Orthop Ihre Grenzgeb.* 1996 Jan Feb;134(1):73 5.
14. Olivieri M, Ciliberto E, Hulse DA, Vezzoni A, Ingravalle F, Peirone B. Arthroscopic treatment of osteochondritis dissecans of the shoulder in 126 dogs. *Vet Comp Orthop Traumatol.* 2007;20(1):65 9.
15. Elser F, Braun S, Dewing CB, Millett PJ. Glenohumeral joint preservation: current options for managing articular cartilage lesions in young, active patients. *Arthroscopy.* 2010 May;26(5):685 96. Epub 2010 Apr 8.
16. Millett PJ, Huffard BH, Horan MP, Hawkins RJ, Steadman JR. Outcomes of full thickness articular cartilage injuries of the shoulder treated with microfracture. *Arthroscopy.* 2009 Aug;25(8):856 63.
17. Chambers HG, Shea KG, Anderson AF, Brunelle TJJ, Carey JL, Ganley TJ, Paterno MV, Weiss JM, Sanders JO, Watters WC 3rd, Goldberg MJ, Keith MW, Turkelson CM, Wies JL, Raymond L, Boyer KM, Hitchcock K, Anderson S, Sluka P, Boone C, Patel N; American Academy of Orthopedic Surgeons. Diagnosis and treatment of osteochondritis dissecans. *J Am Acad Orthop Surg.* 2011 May;19(5):297 306.
18. Romeo AA, Cole BJ, Mazzocca AD, Fox JA, Freeman KB, Joy E. Autologous chondrocyte repair of an articular defect in the humeral head. *Arthroscopy.* 2002 Oct;18(8):925 9.