



**HAL**  
open science

## Management of massive rotator cuff tears: prospective study in 218 patients

Maxime Cavalier, Stéphane Jullion, Jean Kany, Jean Grimberg, Yves Lefebvre, Didier Oudet, Sophie Grosclaude, Christophe Charousset, Pascal Boileau, Thierry Joudet, et al.

### ► To cite this version:

Maxime Cavalier, Stéphane Jullion, Jean Kany, Jean Grimberg, Yves Lefebvre, et al.. Management of massive rotator cuff tears: prospective study in 218 patients. *Orthopaedics & Traumatology: Surgery & Research*, 2018, 104 (8), pp.S193-S197. 10.1016/j.otsr.2018.09.007 . hal-02135078

**HAL Id: hal-02135078**

**<https://hal.science/hal-02135078>**

Submitted on 21 May 2019

**HAL** is a multi-disciplinary open access archive for the deposit and dissemination of scientific research documents, whether they are published or not. The documents may come from teaching and research institutions in France or abroad, or from public or private research centers.

L'archive ouverte pluridisciplinaire **HAL**, est destinée au dépôt et à la diffusion de documents scientifiques de niveau recherche, publiés ou non, émanant des établissements d'enseignement et de recherche français ou étrangers, des laboratoires publics ou privés.




## Open Archive Toulouse Archive Ouverte (OATAO)

OATAO is an open access repository that collects the work of some Toulouse researchers and makes it freely available over the web where possible.

This is an author's version published in: <https://oatao.univ-toulouse.fr/23090>

**Official URL :** <https://doi.org/10.1016/j.otsr.2018.09.007>

**To cite this version :**

Cavalier, Maxime and Jullion, Stéphane and Kany, Jean and Grimberg, Jean and Lefebvre, Yves and Oudet, Didier and Grosclaude, Sophie and Charousset, Christophe and Boileau, Pascal and Joudet, Thierry and Bonnevielle, Nicolas  *Management of massive rotator cuff tears: prospective study in 218 patients.* (2018) *Orthopaedics & Traumatology: Surgery & Research*, 104 (8). S193-S197. ISSN 1877-0568

Any correspondence concerning this service should be sent to the repository administrator:

[tech-oatao@listes-diff.inp-toulouse.fr](mailto:tech-oatao@listes-diff.inp-toulouse.fr)

# Management of Massive Rotator Cuff Tears: Prospective study in 218 patients

Maxime Cavalier<sup>a,\*</sup>, Stéphane Jullion<sup>b</sup>, Jean Kany<sup>c</sup>, Jean Grimberg<sup>d</sup>, Yves Lefebvre<sup>e</sup>,  
Didier Oudet<sup>f</sup>, Sophie Grosclaude<sup>g</sup>, Christophe Charousset<sup>h</sup>, Pascal Boileau<sup>i</sup>,  
Thierry Joudet<sup>j</sup>, Nicolas Bonneville<sup>j</sup>, French Arthroscopic Society<sup>k</sup>

<sup>a</sup> IULS, hôpital Pasteur 2, CHU de Nice, 30, voie romaine, 06001 Nice, France

<sup>b</sup> Centre chirurgical Emile Gallé, CHRU, 49, rue Hermite, 54000 Nancy, France

<sup>c</sup> Clinique de l'Union, 31240 Saint-Jean, France

<sup>d</sup> LIRCOS, 75016 Paris, France

<sup>e</sup> Clinique Rhéna, 16, allée de la Robertsau, 67000 Strasbourg, France

<sup>f</sup> Clinique de l'Alliance, 1, boulevard Alfred Nobel, 37540 Saint-Cyr-sur-Loire, France

<sup>g</sup> Clinique du Prac, 155, ter boulevard Stalingrad, 69006 Lyon, France

<sup>h</sup> Clinique Turin, 3-11, rue de Turin, 75008 Paris, France

<sup>i</sup> Clinique chirurgicale du Libournais, 33500 Libourne, France

<sup>j</sup> Service d'orthopédie, institut universitaire du sport, hôpital Riquet, CHU de Toulouse, 31059 Toulouse cedex 09, France

<sup>k</sup> 15, rue Ampère, 92500 Rueil-Malmaison, France

## A B S T R A C T

### Keywords:

Massive cuff tear

Partial repair

Reverse shoulder arthroplasty

Latissimus dorsi transfer

Biceps tenodesis

**Background:** No consensus exists about the management of massive and symptomatic rotator cuff tears (RCTs). The objective of this study was to compare the 12-month clinical outcomes of various treatment options for massive RCTs.

**Hypothesis:** Arthroscopic surgery has a role to play in the treatment of massive and apparently irreparable RCTs.

**Material and methods:** A prospective multicentre non-randomised study was performed in patients with massive RCTs managed non-operatively (NONOP) or by arthroscopic tenotomy/tenodesis of the long head of biceps (aTLB), arthroscopic partial tendon repair (aPTR), arthroscopic latissimus dorsi transfer (aLDT), or reverse shoulder arthroplasty (RSA). Clinical outcomes were evaluated based on the Constant score, Subjective Shoulder Value (SSV), and American Shoulder and Elbow Surgeons (ASES) score after 3, 6, and 12 months.

**Results:** The 218 included patients (mean age, 69 years) were distributed as follows: NONOP,  $n = 71$ ; aTLB,  $n = 26$ ; aPTR,  $n = 61$ ; aLDT,  $n = 25$ ; and RSA,  $n = 35$ . After 12 months, the mean Constant score, SSV, and ASES score values were 70, 68%, and 73, respectively, and had improved significantly versus the preoperative values in all treatment groups. RSA was the only treatment followed by improvements in all Constant score items. Active forwards elevation improved significantly in the NONOP (+25°), aPTR (+26°), and RSA (+66°) groups. An improvement in active external rotation was seen only in the RSA group, where it was small (+10°,  $p = 0.046$ ). Significant increases in internal rotation were seen in the NONOP (+1.6 points) and aPTR (+1.7 points) groups.

**Conclusion:** Arthroscopic techniques (aTLB, aPTR, and aLDT) for managing massive irreparable RCTs produce significant functional gains. Partial tendon repair (aPTR) and RSA may provide better outcomes than isolated aTLB or aLDT.

**Level of evidence:** III, non-randomised prospective study.

## 1. Introduction

No accurate definition exists of what constitutes a massive rotator cuff tear (RCT). Gerber et al. [1] stated that an RCT was massive if a full-thickness tear involved at least two tendons including the

\* Corresponding author. IULS, hôpital Pasteur 2, CHU de Nice, 30, voie romaine, 06001 Nice, France.

E-mail address: maximecav@hotmail.com (M. Cavalier).

supra-spinatus and infra-spinatus tendons. Boileau et al. [2] defined massive RCTs as grade III tendon retraction according to Patte [3] or major muscle wasting with a Goutallier fatty degeneration grade  $\geq 2$  [4] or a subacromial interval  $< 7$  mm.

The treatment of massive RCTs is not universally agreed on within the surgical community. New arthroscopic techniques such as double-row repair have been suggested to increase the tendon healing rates and improve the clinical and anatomical outcomes [5,6]. However, depending on the clinical presentation, other treatments may deserve consideration, including non-operative treatment (NONOP) by rehabilitation and local corticosteroid injections, isolated arthroscopic tenotomy or tenodesis of the long head of biceps (aTLB), arthroscopic partial tendon repair (aPTR), palliative arthroscopic latissimus dorsi transfer (aLDT), and reverse shoulder arthroplasty (RSA) [2,7–9].

The objective of this study was to compare the 12-month clinical outcomes of various treatment options for massive RCTs. The working hypothesis was that arthroscopic surgery has a role to play in the treatment of massive and apparently irreparable RCTs.

## 2. Material and method

### 2.1. Population

A prospective multicentre non-randomised study was conducted at 11 centres specialised in shoulder surgery. The appropriate ethics committee approved the study (04–415) and informed consent was obtained from the patients before study inclusion.

Consecutive patients with massive RCTs were included between 1 May 2015 and 1 May 2016. Massive RCT was defined as a full-thickness tear involving at least two tendons, including one whose muscle belly had a Goutallier fatty degeneration grade greater than II [4]. The management was at the discretion of the surgeons. The patients were divided into five groups depending on the management technique: first-line NONOP, aTLB, aPTR, aLDT, and RSA.

Exclusion criteria were shoulder stiffness, gleno-humeral osteoarthritis, follow-up shorter than 12 months, and previous surgery on the affected shoulder.

The following data were collected: age, gender, dominant side, occupation, smoking history, and American Society of Anesthesiologists (ASA) score.

### 2.2. Operative techniques

The choice of the aPTR technique was at the discretion of the surgeons. Three techniques were used: cuff reinsertion by tension-band suturing to anchors inserted into the lateral aspect of the humerus, with partial coverage of the tendon footprint; margin convergence, consisting in isolated side-to-side cuff suturing [10]; and shoelace repair combining side-to-side suturing with anchor fixation [11,12].

The technique described by Kany et al. [13] was used for aLDT. An incision about 5 cm in length was made to harvest the tendon. The transfer was performed arthroscopically to the apex of the greater tuberosity, with fixation by an endobutton. Three metal markers spaced 2, 4 and 6 cm apart were attached to the transferred tendon to allow a radiographic evaluation.

### 2.3. Clinical assessments

The history of the RCT was clarified, including the data and mode of symptom onset and whether the injury was work-related or classified as an occupational condition. Each patient underwent standardised physical evaluations at baseline then 3, 6, and 12

months later. Each evaluation included a determination of the passive and active ranges of forwards elevation, external rotation with the elbow at the side, and internal rotation. The standard rotator cuff tests were performed including the belly-press, bear-hug, lift-off, palm-up, drop-arm, and horn blower's tests [14–18]. Functional outcomes were assessed based on the Subjective Shoulder Value (SSV), Constant score [19] and American Shoulder and Elbow Surgeons (ASES) score.

### 2.4. Radiological evaluations

At baseline, standard antero-posterior and lateral radiographs were obtained. The acromio-humeral interval was measured to allow classification according to Hamada et al. [20] and Lévine et al. [21] Slice imaging (magnetic resonance imaging [MRI] or computed tomography-arthrography [CT-arthrography]) was performed to evaluate rotator cuff tendon retraction according to Patte [3] and to assess muscle trophicity and fatty degeneration according to Goutallier et al. [4] We used the classification described by Collin [22] to define the type of tear based on the involved tendons (Fig. 1).

After 12 months, tendon healing in the aPTR group was assessed by MRI using the five-type classification described by Sugaya [6]. Types I and II are characterised by healed tendons, type III by continuous but incompletely healed tendons, and types IV and V by unhealed or discontinuous tendons. In the aLDT group, the distances between the metal markers inserted during surgery were measured on an antero-posterior radiograph. Increases in the distances were interpreted as indicating rupture of the transferred tendon.

### 2.5. Statistical analysis

The data were entered electronically and hosted online with assistance from the Calimed Santé group (Marseille, France). The statistical analysis was conducted in collaboration with ThinkR (Caen, France).

Quantitative variables were described as mean  $\pm$  SD and compared using the non-parametric Kruskal–Wallis and Mann–Whitney tests. Qualitative variables were evaluated using contingency tables and Fisher's exact test. Values of  $p < 0.05$  were considered significant. The statistical tests were performed

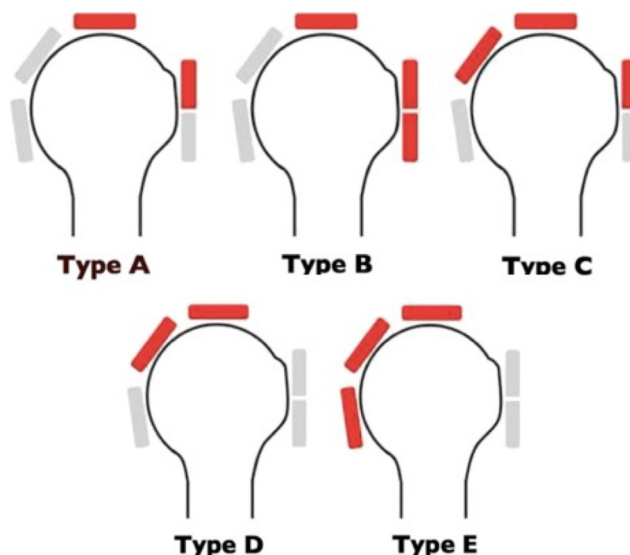


Fig. 1. Collin classification based on the rotator cuff tendons involved.

**Table 1**  
Patient characteristics in each treatment group.

	NONOP	aTLB	aPTR	aLDT	RSA	Total	<i>p</i> value
N of patients	71	26	41	25	35	218	
Mean age, years	70	71	64	65	73	69	<b>&lt;0.001</b>
Males/Females (%)	56/44	35/65	56/44	48/52	44/56	51/49	0.68
ASA score 1 or 2 (%)	95	86	98	100	83	94	<b>0.005</b>
Dominant side (%)	80	78	77	78	67	77	0.97
Work-related injury (%)	11	15	5	20	0	10	0.016

NONOP: non-operative treatment; aTLB: arthroscopic tenotomy or tenodesis of the long head of biceps tendon; aPTR: arthroscopic partial tendon repair; aLDT: arthroscopic latissimus dorsi transfer; RSA: reverse shoulder arthroplasty.

using StatView 5.0 software (Abacus Concepts, Berkeley, CA, USA; 1992).

### 3. Results

Of 221 included patients, 3 were excluded due to missing data, leaving 218 patients for the study, 110 males and 108 females with a mean age of  $68.8 \pm 10.0$  years. The patients were distributed as follows: NONOP,  $n = 71$ ; aTLB,  $n = 26$ ; aPTR,  $n = 61$ ; aLDT,  $n = 25$ ; and RSA,  $n = 35$ . Table 1 reports the main features in each group. The dominant arm was affected in 77% of patients. The injury was work-related in 10% of patients. Most of the patients (94%) had an ASA score of 1 or 2. Differences across groups were found for mean age at baseline, ASA score, and proportion of patients with work-related injuries.

#### 3.1. Preoperative data

The radiographic acromio-humeral interval was  $> 7$  mm (Hamada 1) in 38% of patients, Hamada 2 in 47%, and Hamada 3 in 13%. In the Collin classification [22], lesion type was C in 34% of patients, D in 42%, and E in 12%. Table 2 describes the appearance of the rotator cuff tendons by MRI or CT-arthrography.

#### 3.2. Functional outcomes

Functional outcomes are reported in Table 3. At last follow-up, the SSV and ASES score were significantly improved in all five-treatment groups. The Constant score was significantly improved in four groups, the exception being the aTLB group ( $52$  to  $62$ ,  $p = 0.048$ ). The analysis of Constant sub-scores showed a non-significant improvement in strength in the NONOP group ( $p = 0.0489$ ). In the

aTLB group, only the activity sub-score was significantly improved. In the aLDT group, gains were obtained on the pain and activity items, whereas neither mobility nor force improved significantly. Finally, in the aPTR and RSA groups, all Constant sub-scores improved significantly. Fig. 2 illustrates the Constant score changes at 3, 6, and 12 months in each treatment group.

#### 3.3. Motion range assessments

Active forwards elevation improved significantly in the NONOP ( $112^\circ$  to  $137^\circ$ ,  $p < 0.01$ ), aPTR ( $130^\circ$  to  $156^\circ$ ,  $p < 0.01$ ), and RSA ( $77^\circ$  to  $143^\circ$ ,  $p < 0.01$ ) groups. The differences were not significant in the aTLB and aLDT groups. An improvement in active external rotation was achieved only with RSA and remained limited ( $20.1^\circ$  to  $30^\circ$ ,  $p = 0.046$ ).

Internal rotation increased significantly in the NONOP ( $5.7$  to  $7.3/10$ ,  $p = 0.02$ ) and aPTR ( $5.7$  to  $7.4/10$ ,  $p = 0.017$ ) groups.

#### 3.4. Anatomical outcomes

Of the 61 patients in the aPTR group, 41 (67%) underwent MRI after 12 months. In patients with a Goutallier fatty degeneration grade  $\leq 3$ , the healing rate was only 13% for the supra-spinatus and 48% for the infra-spinatus. In patients with higher fatty degeneration grades, tendon healing never occurred.

In the aLDT group, an increase in the distance between two metal markers indicating rupture of the transfer or its fixation was noted in 43% of patients.

#### 3.5. Complications

In the NONOP group, 3 (4%) patients required surgery due to insufficient clinical effectiveness. No complications were recorded in the aTLB group. After aPTR, the complication rate was 3% (1 case each of anchor migration and postoperative infection). In the aLDT group, 1 (4%) patient experienced a haematoma that required surgical drainage. Finally, in the RSA group, 1 (3%) patient developed an infection that required lavage 2 months after surgery.

**Table 2**  
Preoperative status of the rotator cuff.

	Tendon retraction type	Goutallier fatty degeneration grade
Supra-spinatus	0: 7%	0: 2%
	1: 10%	1: 5%
	2: 36%	2: 28%
	3: 47%	3: 44%
Infra-spinatus		4: 21%
	0: 16%	0: 5%
	1: 20%	1: 10%
	2: 34%	2: 31%
Sub-scapularis	3: 30%	3: 42%
		4: 12%
	0: 54%	0: 40%
	1: 32%	1: 35%
Teres minor	2: 10%	2: 11%
	3: 4%	3: 9%
		4: 5%
	0: 77%	0: 71%
	1: 16%	1: 20%
	2: 4%	2: 6%
	3: 3%	3: 2%
		4: 1%

## 4. Discussion

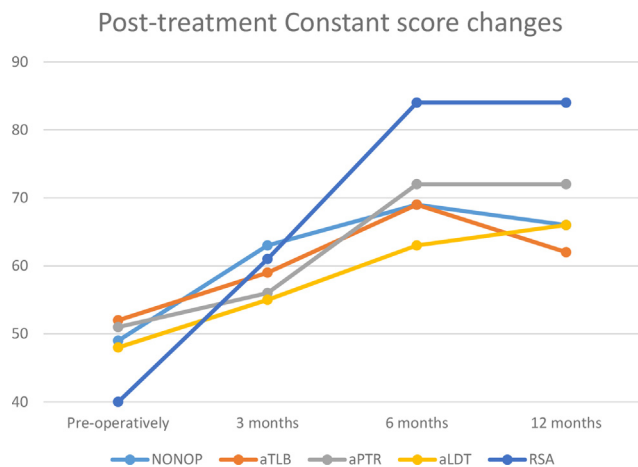
The objective of this study was to evaluate and compare the outcomes of massive RCTs treated non-operatively or using various surgical options including aTLB, aPTR, aLDT, and RSA. Other techniques such as grafting [23,24] and sub-acromial spacer implantation were not evaluated [25], as their very recent introduction limits the available clinical follow-up data.

A consensus regarding the management of massive RCTs may be difficult to achieve given the broad range of available non-operative and surgical treatment options of varying technical complexity. Furthermore, the clinical presentation can vary independently from the anatomical lesions. The shoulder may be painful but functional, with preserved forwards elevation above  $90^\circ$ , or non-functional, with pseudo-paralysis.

**Table 3**  
Pre and Post-treatment functional results.

	NONOPn=71			aTLBn=26			aPTRn=61			aLDTn=25			RSAn=35			Totaln=218		
	Pre-op	Post-op	p	Pre-op	Post-op	p	Pre-op	Post-op	p	Pre-op	Post-op	p	Pre-op	Post-op	p	Pre-op	Post-op	p
S (/25)	3.6	5.2	0.049	5	7	0.47	4	6.1	0.017	3	4.1	0.17	2.1	8.8	<0.01	3.5	6.1	<0.01
P (/15)	5.6	7.8	<0.01	6	6.7	0.48	6.2	8	<0.01	1.7	8.3	<0.01	6.1	9.3	<0.01	5.4	8	<0.01
A (/20)	9.1	13.7	<0.01	8.2	12.3	<0.01	8.8	15.5	<0.01	7.3	13.7	<0.01	7.6	17.8	<0.01	8.5	14.6	<0.01
M (/40)	22.4	28.2	<0.01	23.2	25.3	0.13	25.5	32.3	<0.01	31.3	32	0.6	15.9	30.1	<0.01	23.2	29.6	<0.01
Cs score	49	66	<0.01	52	62	0.048	51	72	<0.01	48	66	<0.01	40	84	<0.01	48	70	<0.01
SSV (%)	39	65	<0.01	43	65	<0.01	42	73	<0.01	28	59	<0.01	32	81	<0.01	38	68	<0.01
ASES	45.2	68.8	<0.01	30.5	59.9	<0.01	34	77.9	<0.01	61.1	74.4	<0.01	34	88.1	<0.01	41.2	73.5	<0.01
AFE (°)	112	137	<0.01	130	138	0.41	130	156	<0.01	166	143	NS	77	143	<0.01	119	145	<0.01
ER1 (°)	28.3	30.2	0.42	30.6	32.7	0.86	30.3	38.1	0.052	27.6	31.4	0.41	20.1	30	0.046	26.8	32.9	<0.01
IR (/10)	5.7	7.3	0.02	5.1	5.6	0.55	5.7	7.4	0.017	6	7.5	0.94	4.4	4.4	NS	5.4	6.6	<0.01

NONOP: non-operative treatment; aTLB: arthroscopic tenotomy or tenodesis of the long head of biceps tendon; aPTR: arthroscopic partial tendon repair; aLDT: arthroscopic latissimus dorsi transfer; RSA: reverse shoulder arthroplasty; Pre-op: preoperative; post-op: postoperative; S: strength; P: pain; A: activity; M: mobility; Cs score: Constant score; SSV: Subjective Shoulder Value; ASES: American Shoulder and Elbow Surgeons score; AFE: active forwards elevation; ER1: external rotation with the elbow at the side; IR: internal rotation.



**Fig. 2.** Constant score changes over the first 12 months after treatment.

In patients with massive RCTs, surgery is usually performed only after a period of non-operative treatment, which deserves to be tried. Thus, a combination of local corticosteroid injections and rehabilitation improved the functional scores in our study, alleviating the pain and producing an about 25° gain in active forwards elevation.

With isolated tenodesis of the long head of biceps, Boileau et al. [2] obtained satisfactory clinical outcomes with a 23° increase in active forwards elevation and a significant decrease in pain intensity. In our study, this treatment was not followed by significant improvements in pain or mobility but improved the overall functional scores.

Partial tendon repair is a controversial option. Although Shon et al. [26] and Chen et al. [27] reported functional improvements, half the patients were dissatisfied at last follow-up. Cuff et al. [28] noted improvements in the functional scores but not in range of motion. Similarly, in our study, active forwards elevation increased by 26°, but neither external nor internal rotation improved.

In our aLDT group, the functional scores improved but strength and motion range did not, in contrast to results obtained by Namdari et al. [29]. This discrepancy may be ascribable to our fairly high rate of transfer rupture (43%) due to failure of the fixation method.

Finally, RSA produced the best outcomes, with improvements in all the functional scores. In addition, RSA considerably improved active forwards elevation, from 77° to 143° after 12 months, although this group of patients was the oldest and less active forwards elevation at baseline than any of the other four groups. As shown in the literature review by Sevivas et al. [9], complications can occur in up to 20% of patients after RSA.

The strengths of our study are the availability of complete data for all patients, due to the prospective design, and the large number of included patients. The main limitation is the short follow-up of only 12 months. Improvements may continue to occur after this time point, particularly after aLDT and RSA.

## 5. Conclusion

The broad diversity of available treatment options hinders the development of a consensus about the management of massive RCTs. Non-operative treatment is a minimally invasive option that deserves to be used initially. Outcomes may be better after aPTR (despite the low tendon healing rate) and RSA than after aTLB and aLDT. A longer follow-up would provide information on the maintenance of improvements with each treatment option.

## Finding sources

Financial assistance was provided by the French Society of Arthroscopy.

## 6. Authors' contribution

Maxime Cavalier: patients inclusion, clinical follow-up, data collection and analysis, article redaction.

Stéphane Jullion, Jean Kany, Jean Grimberg, Yves Lefebvre, Didier Oudet, Sophie Grosclaude, Christophe Charousset, Pascal Boileau, Thierry Joudet, Nicolas Bonneville: patients inclusion, clinical follow-up, data collection and analysis.

## Disclosure of interest

The authors declare that they have no competing interest.

## References

- Gerber C, Fuchs B, Hodler J. The results of repair of massive tears of the rotator cuff. *J Bone Jt Surg Am* 2000;82:505–15.
- Boileau P, Baqué F, Valerio L, Ahrens P, Chuinard C, Trojani C. Isolated arthroscopic biceps tenotomy or tenodesis improves symptoms in patients with massive irreparable rotator cuff tears. *J Bone Jt Surg Ser A* 2007;89:747–57. <http://dx.doi.org/10.2106/JBJS.E.01097>.
- Patte D. Classification of rotator cuff lesions. *Clin Orthop* 1990;254:81–6.
- Goutallier D, Postel J-M, Bernageau J, Lavau L, Voisin M-C. Fatty muscle degeneration in cuff ruptures. *Clin Orthop Relat Res* 1994;304:78–83. <http://dx.doi.org/10.1097/00003086-199407000-00014>.
- Hein J, Reilly JM, Chae J, Maerz T, Anderson K. Retear rates after arthroscopic single-row, double-row, and suture bridge rotator cuff repair at a minimum of 1 year of imaging follow-up: a systematic review. *Arthroscopy* 2015;31:2274–81. <http://dx.doi.org/10.1016/j.arthro.2015.06.004>.

- [6] Sugaya H, Maeda K, Matsuki K, Moriishi J. Repair integrity and functional outcome after arthroscopic double-row rotator cuff repair. A prospective outcome study. *J Bone Joint Surg Am* 2007;89:953–60, <http://dx.doi.org/10.2106/JBJS.F.00512>.
- [7] Godenèche A, Freychet B, Lanzetti RM, Clechet J, Carrillon Y, Saffarini M. Should massive rotator cuff tears be reconstructed even when only partially repairable? *Knee Surgery. Sport Traumatol Arthrosc* 2017;25:2164–73, <http://dx.doi.org/10.1007/s00167-016-4105-2>.
- [8] Kany J, Grimberg J, Amaravathi RS, Sekaran P, Scorpie D, Werthel JD. Arthroscopically-assisted latissimus dorsi transfer for irreparable rotator cuff insufficiency: Modes of failure and clinical correlation. *Arthroscopy* 2018;34:1139–50, <http://dx.doi.org/10.1016/j.arthro.2017.10.052>.
- [9] Sevivas N, Ferreira N, Andrade R, et al. Reverse shoulder arthroplasty for irreparable massive rotator cuff tears: a systematic review with meta-analysis and meta-regression. *J Shoulder Elb Surg* 2017;26:e265–77, <http://dx.doi.org/10.1016/j.jse.2017.03.039>.
- [10] Mazzocca AD, Bollier M, Fehsenfeld D, et al. Biomechanical evaluation of margin convergence. *Arthroscopy* 2011;27:330–8, <http://dx.doi.org/10.1016/j.arthro.2010.09.003>.
- [11] Suzuki H, Chang A, Kumagai H, Shimizu Y, Sakai A, Uchida S. Arthroscopic shoelace side-to-side repair technique using ultratape for the treatment of longitudinal midsubstance rotator cuff tears. *Arthrosc Tech* 2017;6:e1845–50, <http://dx.doi.org/10.1016/j.eats.2017.06.058> [eCollection 2017 Oct].
- [12] van der Zwaal P, Pool LD, Hacquebord ST, van Arkel ER, van der List MP. Arthroscopic side-to-side repair of massive and contracted rotator cuff tears using a single uninterrupted suture: the shoestring bridge technique. *Arthroscopy* 2012;28:754–60, <http://dx.doi.org/10.1016/j.arthro.2011.11.006>.
- [13] Kany J, Kumar HA, Chang VK, et al. Mini invasive axillary approach and arthroscopic humeral head interference screw fixation for latissimus dorsi transfer in massive and irreparable posterosuperior rotator cuff tears. *Tech Shoulder Elbow Surg* 2010;11:8–14.
- [14] Tokish JM, Decker MJ, Ellis HB, et al. The belly-press test for the physical examination of the subscapularis muscle: electromyographic validation and comparison to the lift-off test. *J Shoulder Elb Surg* 2003;12:427–30.
- [15] Jobe FW, Jobe CM. Painful athletic injuries of the shoulder. *Clin Orthop Relat Res* 1983;173:117–24.
- [16] Barth JR, Burkhart SS, De Beer JF. The bear-hug test: a new and sensitive test for diagnosing a subscapularis tear. *Arthroscopy* 2006;22:1076–84, <http://dx.doi.org/10.1016/j.arthro.2006.05.005>.
- [17] Greis PE, Kuhn JE, Schultheis J, et al. Validation of the lift-off test and analysis of subscapularis activity during maximal internal rotation. *Am J Sports Med* 1996;24:589–93, <http://dx.doi.org/10.1177/036354659602400505>.
- [18] Walch G, Boulahia A, Calderone S, Robinson AH. The “dropping” and “horn-blower’s” signs in evaluation of rotator-cuff tears. *J Bone Jt Surg* 1998;80:624–8, <http://dx.doi.org/10.1302/0301-620X.80B4.8651>.
- [19] Constant CRMA. A clinical method of functional assessment of the shoulder. *Clin Orthop Relat Res* 1987;214:160–4.
- [20] Hamada K, Yamanaka K, Uchiyama Y, Mikasa T, Mikasa M. A radiographic classification of massive rotator cuff tear arthritis. *Clin Orthop Relat Res* 2011;469:2452–60, <http://dx.doi.org/10.1007/s11999-011-1896-9>.
- [21] Lévine C, Boileau P, Favard L, et al. Scapular notching in reverse shoulder arthroplasty. *J Shoulder Elb Surg* 2008;17:925–35, <http://dx.doi.org/10.1016/j.jse.2008.02.010>.
- [22] Collin P, Matsumura N, Lädermann A, Denard PJ, Walch G. Relationship between massive chronic rotator cuff tear pattern and loss of active shoulder range of motion. *J Shoulder Elb Surg* 2014;23:1195–202, <http://dx.doi.org/10.1016/j.jse.2013.11.019>.
- [23] Ferguson DP, Lewington MR, Smith TD, Wong IH. Graft utilization in the augmentation of large-to-massive rotator cuff repairs. *Am J Sports Med* 2016;44:2984–92, <http://dx.doi.org/10.1177/0363546515624463>.
- [24] Lewington MR, Ferguson DP, Smith TD, Burks R, Coady C, Wong IH. Graft utilization in the bridging reconstruction of irreparable rotator cuff tears: A systematic review. *Am J Sports Med* 2017;45:3149–57, <http://dx.doi.org/10.1177/0363546517694355>.
- [25] Deranlot J, Herisson O, Nourissat G, et al. Arthroscopic subacromial spacer implantation in patients with massive irreparable rotator cuff tears: clinical and radiographic results of 39 retrospective cases. *Arthroscopy* 2017;33:1639–44, <http://dx.doi.org/10.1016/j.arthro.2017.03.029>.
- [26] Shon MS, Koh KH, Lim TK, Kim WJ, Kim KC, Yoo JC. Arthroscopic partial repair of irreparable rotator cuff tears: Preoperative factors associated with outcome deterioration over 2 years. *Am J Sports Med* 2015;43:1965–75, <http://dx.doi.org/10.1177/0363546515558122>.
- [27] Chen KH, Chiang ER, Wang HY, Ma HL. Arthroscopic partial repair of irreparable rotator cuff tears: Factors related to greater degree of clinical improvement at 2 years of follow-up. *Arthroscopy* 2017;33:1949–55, <http://dx.doi.org/10.1016/j.arthro.2017.06.047>.
- [28] Cuff DJ, Pupello DR, Santoni BG. Partial rotator cuff repair and biceps tenotomy for the treatment of patients with massive cuff tears and retained overhead elevation: midterm outcomes with a minimum 5 years of follow-up. *J Shoulder Elb Surg* 2016;25:1803–9, <http://dx.doi.org/10.1016/j.jse.2016.04.001>.
- [29] Namdari S, Voleti P, Baldwin K, Glaser D, Huffman GR. Latissimus dorsi tendon transfer for irreparable rotator cuff tears: a systematic review. *J Bone Joint Surg Am* 2012;94:891–8, <http://dx.doi.org/10.2106/JBJS.K.00841>.