



## **Clinical and MRI outcomes 10 years after repair of massive posterosuperior rotator cuff tears**

Philippe Collin, Michel Colmar, Hervé Thomazeau, Pierre Mansat, Pascal Boileau, Philippe Valenti, Mo Saffarini, Luca Nover, Jean-François Kempf

### **► To cite this version:**

Philippe Collin, Michel Colmar, Hervé Thomazeau, Pierre Mansat, Pascal Boileau, et al.. Clinical and MRI outcomes 10 years after repair of massive posterosuperior rotator cuff tears. *Journal of Bone and Joint Surgery, American Volume*, 2018, 100 (21), pp.1854-1863. 10.2106/JBJS.17.01190 . hal-02135075

**HAL Id: hal-02135075**

**<https://hal.science/hal-02135075>**

Submitted on 21 May 2019

**HAL** is a multi-disciplinary open access archive for the deposit and dissemination of scientific research documents, whether they are published or not. The documents may come from teaching and research institutions in France or abroad, or from public or private research centers.

L'archive ouverte pluridisciplinaire **HAL**, est destinée au dépôt et à la diffusion de documents scientifiques de niveau recherche, publiés ou non, émanant des établissements d'enseignement et de recherche français ou étrangers, des laboratoires publics ou privés.




## Open Archive Toulouse Archive Ouverte (OATAO)

OATAO is an open access repository that collects the work of some Toulouse researchers and makes it freely available over the web where possible.

This is an author's version published in: <https://oatao.univ-toulouse.fr/23109>

**Official URL :** <https://doi.org/10.2106/JBJS.17.01190>

### To cite this version :

Collin, Philippe and Colmar, Michel and Thomazeau, Hervé and Mansat, Pierre  and Boileau, Pascal and Valenti, Philippe and Saffarini, Mo and Nover, Luca and Kempf, Jean-François *Clinical and MRI outcomes 10 years after repair of massive posterosuperior rotator cuff tears*. (2018) The Journal of Bone and Joint Surgery, 100 (21). 1854-1863. ISSN 0021-9355

Any correspondence concerning this service should be sent to the repository administrator:  
[tech-oatao@listes-diff.inp-toulouse.fr](mailto:tech-oatao@listes-diff.inp-toulouse.fr)

# Clinical and MRI Outcomes 10 Years After Repair of Massive Posterosuperior Rotator Cuff Tears

Philippe Collin, MD, Michel Colmar, MD, Hervé Thomazeau, MD, Pierre Mansat, MD, PhD, Pascal Boileau, MD, Philippe Valenti, MD, Mo Saffarini, MEng, Luca Nover, MSc, and Jean-François Kempf, MD, PhD

*Investigation performed at Institut Locomoteur de l'Ouest CHP Saint Grégoire (Vivalto Santé), Saint Grégoire, France*

**Background:** Massive rotator cuff tears are challenging to treat, with few or no studies on long-term outcomes of repair. The purpose of this study was to report 10-year outcomes following repair of massive posterosuperior rotator cuff tears, with and without extension into the subscapularis, and to determine prognostic factors that could influence clinical scores and retear rates.

**Methods:** The records of 234 patients who underwent repair of a massive posterosuperior rotator cuff tear at a total of 15 centers were retrieved. Patients were asked to return for evaluation at 10 years; 78 patients could not be contacted, 7 had died, and 19 had undergone a reoperation. A total of 130 patients (68% men) with a mean age (and standard deviation) of  $56.1 \pm 7.7$  years (range, 26 to 79 years) were evaluated clinically, and 102 of them were also evaluated using magnetic resonance imaging (MRI). The tear was confined to the supraspinatus and infraspinatus tendons in 94 shoulders and also involved the superior portion of the subscapularis in 36 shoulders. Univariable and multivariable regressions were performed to determine whether 10-year total Constant-Murley scores and repair integrity were associated with patient characteristics, tear patterns, or repair techniques.

**Results:** In the study cohort, complications were noted in 14 shoulders (11%) (stiffness in 10 and infection in 4). For the 130 shoulders evaluated clinically, the mean total Constant-Murley score improved from  $53.1 \pm 15.9$  (range, 14 to 83) preoperatively to  $78.5 \pm 11.3$  (range, 36 to 98) at 10 years. Of the 102 shoulders evaluated using MRI, 32 had a retear (Sugaya type IV or V). Of the 19 shoulders that underwent a reoperation (excluded from the study cohort), 9 had a retear. The overall prevalence of retears was 34%. Multivariable regression analysis revealed a significant association between the 10-year Constant-Murley score and preoperative retraction of the infraspinatus tendon, but no association between retears and any of the variables. Involvement of the subscapularis had no significant effect on preoperative or postoperative Constant-Murley scores or retear rates.

**Conclusions:** Patients who had repair of a massive posterosuperior rotator cuff tear maintained considerable improvements in clinical and radiographic outcomes at 10 years. Partial concomitant tears of the subscapularis did not affect the total postoperative Constant-Murley scores or retear rates.

**Level of Evidence:** Therapeutic Level IV. See Instructions for Authors for a complete description of levels of evidence.

Massive rotator cuff tears constitute 10% to 40% of all full-thickness rotator cuff tears, and the surgical treatment is often challenging because of substantial fatty infiltration, tendon retraction, and tissue degeneration<sup>1-4</sup>. Retear rates have ranged widely, between 17% and 94%, in recent short and mid-term studies<sup>1,5-13</sup>, although most authors agree that surgical repair generally improves outcomes<sup>5,6,8,9,12,14-17</sup>. The discrepancies in reported retear rates led some surgeons to

prefer reverse shoulder arthroplasty for patients with a massive rotator cuff tear. The inconsistencies in reported outcomes are likely due to the heterogeneity of tear patterns, limited cohort sizes and follow-up periods, and the scarcity of postoperative images necessary to assess tendon healing.

There is no clear consensus on the definition of massive rotator cuff tears. Cofield<sup>18</sup> and others<sup>19,20</sup> described them as tears of >5 cm, whereas Gerber et al.<sup>5</sup> and others<sup>21,22</sup> described

**Disclosure:** None of the authors received funds directly or indirectly for this study.

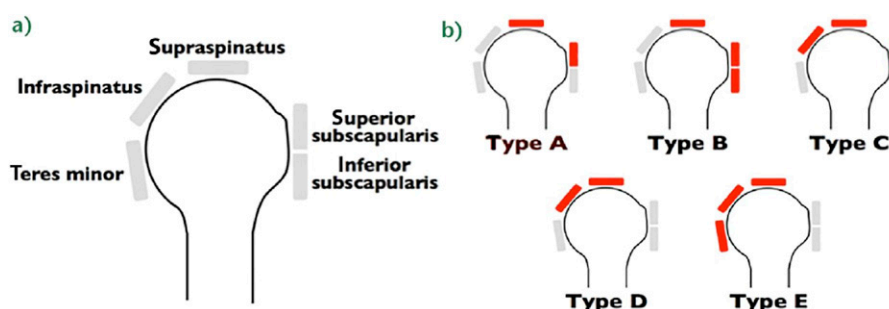


Fig. 1

The Collin classification of massive rotator cuff tears. Type A = tears of the supraspinatus and superior part of the subscapularis, type B = tears of the supraspinatus and entire subscapularis, type C = complete tears of the supraspinatus and infrapinatus with a partial tear of the superior part of the subscapularis, type D = complete tears of the supraspinatus and infrapinatus, and type E = complete tears of the supraspinatus, infrapinatus, and teres minor.

them as tears involving  $\geq 2$  tendons and others confined them to tears of  $>2$  tendons<sup>6,11,14</sup>. The tear patterns are also seldom considered, although most surgeons realize that surgical strategies and clinical outcomes depend on the geometry of the tear<sup>13,23</sup>. To distinguish among different tear patterns and prescribe treatment options, one of us (P.C.) and colleagues<sup>24</sup> classified massive rotator cuff tears into 5 distinct combinations of torn tendons (Collin classification; Fig. 1), but the pertinence of this classification is yet to be confirmed in a sizeable cohort and with a long follow-up.

The purpose of this study was to retrospectively evaluate Constant-Murley scores<sup>25</sup> and retear rates 10 years following repair of massive posterosuperior rotator cuff tears with and without extension into the subscapularis, and to determine associations with prognostic factors (patient demographics, concomitant tears of the subscapularis, preoperative fatty infiltration, and tendon retraction). The hypotheses were that (1) surgical repair of massive posterosuperior rotator cuff tears achieves satisfactory clinical scores and repair integrity at 10 years and (2) tears with partial extension into the subscapularis tendon are associated with poorer clinical scores and retear rates than tears limited to the supraspinatus, infrapinatus, and teres minor tendons.

## Materials and Methods

### Study Design

We retrospectively studied the records of all adults who had undergone surgical repair of a massive posterosuperior rotator cuff tear in 2003 performed by any of 15 surgeons at 15 centers. The patients were identified in 2014 by the surgeons who performed the operations, within the framework of a nationwide symposium on 10-year outcomes of rotator cuff repairs. For each patient, the surgeons specified demographic data and which rotator cuff tendons were torn on the basis of magnetic resonance imaging (MRI) and intraoperative findings. The inclusion criterion for the present study was, in accordance with the Collin classification<sup>24</sup> (Fig. 1), a massive posterosuperior rotator cuff tear classified as type C (complete tears of the supraspinatus and infrapinatus with a partial tear of the superior part of the subscapularis), type D (complete tears of the supraspinatus and infrapinatus), or type E (com-

plete tears of the supraspinatus, infrapinatus, and teres minor) treated with complete surgical repair through either an open or an arthroscopic approach. The exclusion criteria were massive anterosuperior rotator cuff tears classified as type A (tears of the supraspinatus and superior part of the subscapularis) or type B (tears of the supraspinatus and entire subscapularis), partial tendon repairs, or previous surgery on the ipsilateral shoulder.

Before surgery, patients were evaluated clinically using the total Constant-Murley score<sup>25</sup> and radiographically using MRI to assess fatty infiltration according to the classification described by Goutallier et al.<sup>26</sup> and modified by Fuchs et al.<sup>27</sup>, tendon retraction according to the Patte classification system<sup>28</sup>, and the subacromial space according to the classification system of Hamada et al.<sup>29</sup>. All patients provided informed consent for their enrollment in this study, which was approved by the institutional review board of the national regulatory body for all 15 institutions (number 2013-A01788-37).

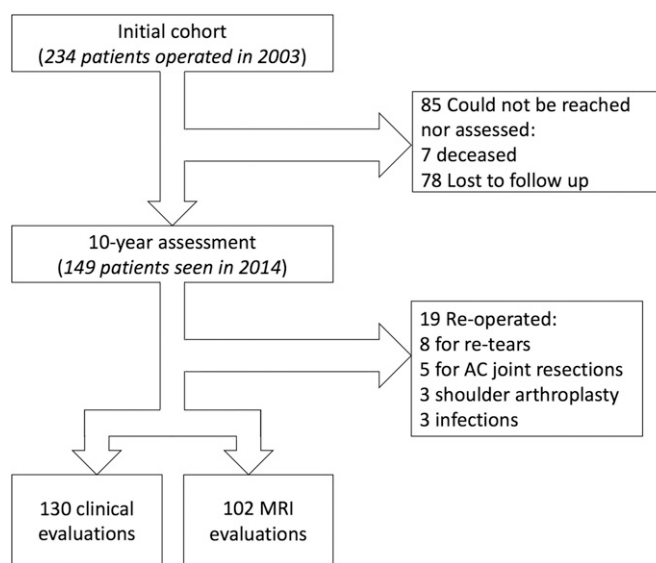


Fig. 2

Flowchart detailing patient inclusion in and exclusion from the original cohort. AC = acromioclavicular.



Of the original cohort of 234 patients, 7 had died from causes unrelated to the shoulder surgery, 78 could not be contacted, and 19 were excluded because they had undergone a reoperation (9 of which were for a retear) before 10 years. The reoperations included 8 repairs of painful retears, 3 conversions to reverse shoulder arthroplasty (only 1 of which was in a shoulder with a retear), 5 acromioclavicular joint resections, and 3 operations to treat infection (Fig. 2). This left a study cohort of 130 patients (88 men [68%] and 42 women), with a mean age (and standard deviation) of  $56.1 \pm 7.7$  years (range, 26 to 79 years) at the time of the surgery, who were examined clinically (Table I). The cohort comprised 36 type-C tears (with a partial tear of the subscapularis), 91 type-D tears, and 3 type-E tears. Twenty-eight of the 130 patients were unable or unwilling to be evaluated radiographically, so only 102 patients (64% men) were evaluated using MRI.

### Surgical Techniques

The repair was open (2 deltopectoral, 45 anterolateral, and 36 superolateral procedures) in 83 shoulders (64%) and arthroscopic in 47 shoulders (36%). Adjuvant acromioplasty was performed in 120 shoulders (92%). Biceps tenodesis or tenotomy was performed in 73 (56%) and 23 (18%) of the shoulders, respectively (Table II), and with 35

**TABLE I Patient Demographics**

Variable	No. (%) <sup>*</sup>
No.	130
Age† (yr)	$56.1 \pm 7.7$ (26 79)
Men:women	88:42
Dominant side	
Yes	100 (77%)
Unknown	2 (2%)
Smoker	
Yes	16 (12%)
Unknown	37 (28%)
Previous trauma	
Yes	58 (45%)
Unknown	9 (7%)
Time between onset and op.† (yr)	$1.8 \pm 3.4$ (0.1 27)
Unknown	6 (5%)
Work related accident	34 (26%)
Profession	
Sedentary	35 (27%)
Light manual labor	29 (22%)
Heavy manual labor	45 (35%)
Repetitive	15 (12%)
Unknown	6 (5%)

<sup>\*</sup>Unless otherwise indicated. †The values are given as the mean and standard deviation with the range in parentheses.

**TABLE II Data from Preoperative Clinical and Radiographic Assessments and Case Notes**

Variable	No. (%) <sup>*</sup>
No.	130
Preoperative clinical assessment	
Passive forward elevation† (°)	$157.5 \pm 25.9$ (70 180)
Active forward elevation† (°)	$143.4 \pm 32.3$ (30 180)
Contralateral shoulder	
Normal	88 (68%)
Painful	20 (15%)
Rotator cuff tear	22 (17%)
Preoperative radiographic assessment	
Presence of acromial spur	
Yes	60 (46%)
None	54 (42%)
Unknown	16 (12%)
Tendon retraction (supraspinatus: infraspinatus)	
Minor	32 (25%): 60 (46%)
Moderate	58 (45%): 26 (20%)
Severe	39 (30%): 27 (21%)
Unknown	1 (1%): 17 (13%)
Fatty infiltration (supraspinatus: infraspinatus)	
0	31 (24%): 38 (29%)
1	35 (27%): 37 (28%)
2	25 (19%): 15 (12%)
3	3 (2%): 3 (2%)
Unknown	36 (28%): 37 (28%)
Intraoperative assessment	
Surgical technique	
Arthroscopy	47 (36%)
Open	76 (58%)
Mini open	7 (5%)
Acromioplasty	120 (92%)
Long head of biceps	
Normal	21 (16%)
Abnormal	86 (66%)
Unknown	23 (18%)
Adjuvant biceps procedure	
None	25 (19%)
Tenodesis	73 (56%)
Tenotomy	23 (18%)
Unknown	9 (7%)

<sup>\*</sup>Unless otherwise indicated. †The values are given as the mean and standard deviation with the range in parentheses.

(74%) of the arthroscopic repairs and 61 (73%) of the open repairs. The tendons were repaired using a single row of suture anchors in 72 shoulders (52 treated with anchor

**TABLE III Clinical Outcomes at 10 Year Follow up**

Variable	Mean ± Standard Deviation (Range)			P Value
	Clinical Cohort (N = 130)	Type C* (N = 36; 28%)	Types D+E* (N = 94; 72%)	
Constant Murley score				
Preop.				
Total	53.1 ± 15.9 (14 83)	51.2 ± 18.3 (14 82)	54.0 ± 14.9 (16 83)	0.426
Strength	7.2 ± 5.4 (0 22)	7.6 ± 6.4 (0 22)	7.1 ± 4.9 (0 20)	
Pain	5.7 ± 3.0 (0 15)	5.6 ± 3.2 (0 15)	5.7 ± 2.9 (0 15)	
Postop.				
Total	78.5 ± 11.3 (36 98)	78.5 ± 8.6 (61 95)	78.4 ± 12.2 (36 98)	0.566
Strength	11.2 ± 5.9 (0 25)	11.3 ± 5.2 (4 22)	11.2 ± 6.1 (0 25)	
Pain	13.1 ± 2.7 (5 15)	13.1 ± 2.7 (7 15)	13.1 ± 2.7 (5 15)	
Net improvement	25.4 ± 17.7 (−26 71)	27.4 ± 18.8 (−5 71)	24.5 ± 17.3 (−26 65)	0.490
Postop. SSV	83.4 ± 15.7 (30 100)	82.5 ± 15.3 (45 100)	83.8 ± 15.8 (30 100)	0.533
Postop. SST	10.1 ± 2.1 (3 12)	10.3 ± 1.8 (5 12)	10.0 ± 2.2 (3 12)	0.855
*According to the classification system of Collin et al. <sup>24</sup> .				

\*According to the classification system of Collin et al.<sup>24</sup>.

screws and 20, with interference-fit anchors) and by transosseous techniques in 46 shoulders; the material was not specified for 12 shoulders. All repairs were complete at the end of the intervention.

#### Postoperative Rehabilitation

All centers followed the same rehabilitation protocol, with passive-motion exercises initiated on the first postoperative day and, when possible, hydrotherapy after skin healing. The arm was supported in a sling at the body (n = 34), at 20° of abduction (n = 92), or in an unspecified configuration (n = 4) for a mean of 5.8  $\pm$  1.0 weeks (median, 6 weeks; range, 2 to 8 weeks). Active shoulder motion was allowed after a mean of 7.7  $\pm$  4.3 weeks (median, 6 weeks; range, 1 to 32 weeks). Patients were not allowed to perform any strengthening or strenuous work for 6 months after the surgery as part of a

standardized protocol. Light sports and demanding activities were allowed after 6 months.

#### Clinical Evaluation

This study cohort of 130 patients was evaluated clinically using the total Constant-Murley score<sup>25</sup>, Subjective Shoulder Value (SSV)<sup>5,30</sup>, and Simple Shoulder Test (SST)<sup>31</sup>. The Constant-Murley score was assessed before surgery and at the time of final follow-up.

#### MRI Evaluation

One hundred and two patients were evaluated with MRI at the last follow-up. The MRI scans were used to assess fatty infiltration of the supraspinatus tendon according to the classification described by Goutallier et al.<sup>26</sup> and modified by Fuchs et al.<sup>27</sup> and healing of the supraspinatus tendon according to the classification described by Sugaya et al.<sup>32</sup>. The MRI

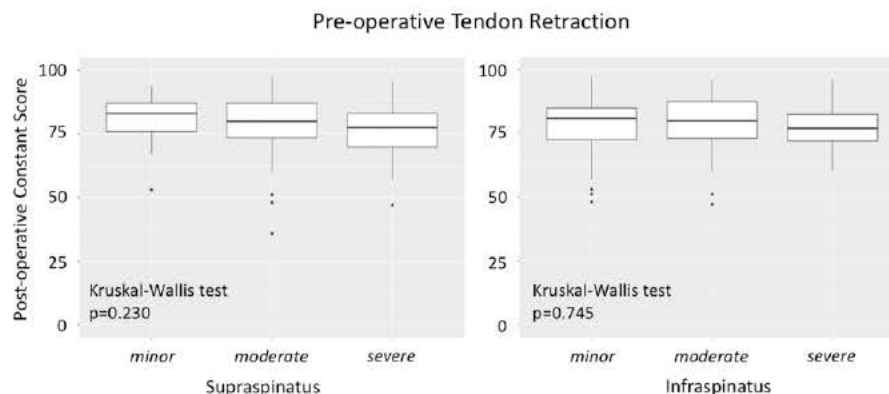


Fig. 3

Boxplots illustrating 10 year Constant Murley scores for shoulders with different extents of preoperative tendon retraction. Numbers on x axis = stages according to the Patte classification<sup>28</sup>, horizontal line = median, top and bottom of box = third and first quartiles, top and bottom of whiskers = 95% confidence interval, and dots = outliers.



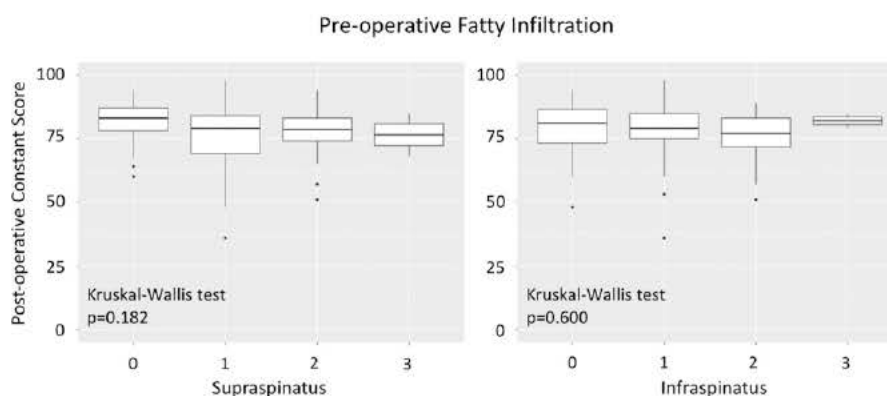


Fig. 4  
Boxplots illustrating 10 year Constant Murley scores for shoulders with different stages of preoperative fatty infiltration. Numbers on x axis = grades according to the classification described by Goutallier et al.<sup>26</sup> and modified by Fuchs et al.<sup>27</sup>, horizontal line = median, top and bottom of box = third and first quartiles, top and bottom of whiskers = 95% confidence interval, and dots = outliers.

protocol included (1) T2-weighted fat-suppression sequences (non-proton-density-weighted) in the oblique coronal, oblique sagittal, and transverse planes, including the entire scapula, to analyze tendon healing and (2) T1-weighted sequences in the transverse and sagittal planes to analyze fatty infiltration and muscle conditions.

The MRI scans were interpreted by 3 observers—a senior radiologist, a senior surgeon, and a junior surgeon. To determine intraobserver and interobserver agreement, each observer repeated their assessments of 50 MRIs after an interval of 3 weeks. The Cohen  $\kappa$  statistic test revealed good intraobserver agreement ( $\kappa = 0.71$ ) and moderate

**TABLE IV Results of Univariable and Multivariable Regression Analysis of Total 10 Year Constant Murley Score**

Variable	Univariable			Multivariable (N = 88)		
	Regression Coefficient*	95% Confidence Interval	P Value	Regression Coefficient*	95% Confidence Interval	P Value
Age	-0.1	-0.4 to 0.1	0.267			
Sex: male vs. female	-3.9	-8.2 to 0.5	0.079	-4.1	-9.1 to 0.9	0.114
Collin type: type C vs. types D+E	0.1	-4.7 to 4.5	0.961			
Tear chronicity: chronic vs. traumatic	-1.6	-5.7 to 2.6	0.464	-4.0	-8.7 to 0.6	0.092
Surgical technique: arthroscopy vs. open	1.1	-3.1 to 5.3	0.599	3.9	-0.8 to 8.6	0.101
Long head of biceps procedure						
None vs. tenodesis	-1.2	-6.5 to 4.1	0.659			
None vs. tenotomy	-2.4	-8.9 to 4.0	0.458			
Preop. supraspinatus tendon retraction						
None vs. moderate	-2.9	-8.0 to 2.1	0.254			
None vs. severe	-4.1	-9.6 to 1.4	0.142			
Preop. infraspinatus tendon retraction						
None vs. moderate	-0.4	-5.6 to 4.9	0.865	0.0	-6.0 to 6.6	0.928
None vs. severe	-0.7	-6.1 to 4.7	0.800	-7.1	-13.0 to -1.2	0.020†
Preop. fatty infiltration of supraspinatus						
Stage 0 vs. 1	-5.8	-11.0 to -0.5	0.032			
Stage 0 vs. 2	-4.3	-10.1 to 1.5	0.145			
Preop. fatty infiltration of infraspinatus						
Stage 0 vs. 1	-0.8	-5.9 to 4.2	0.743			
Stage 0 vs. 2	-3.3	-10.2 to 3.5	0.338			

\*Expected difference. †Significant.

TABLE V MRI Outcomes at 10 Year Follow up				
	No. (%)			P Value
	Entire MRI Cohort (N = 102)	Type C* (N = 26)	Types D+E* (N = 76)	
Sugaya classification of supraspinatus				0.459
1	10 (10%)	5 (19%)	5 (7%)	
2	31 (30%)	6 (23%)	25 (33%)	
3	29 (28%)	7 (27%)	22 (29%)	
4	12 (12%)	3 (12%)	9 (12%)	
5	20 (20%)	5 (19%)	15 (20%)	
*According to the classification system of Collin et al. <sup>24</sup> .				

interobserver agreement ( $\kappa = 0.56$ ) for the Goutallier classification<sup>26</sup>, modified by Fuchs et al.<sup>27</sup>, of fatty infiltration. The  $\kappa$  statistic test revealed good intraobserver agreement ( $\kappa = 0.74$ ) and moderate interobserver agreement ( $\kappa = 0.68$ ) for classification of tendon healing according to the Sugaya system<sup>32</sup>. In case of disagreement, which was most frequent between the junior and senior surgeons<sup>33</sup>, a consensus was reached through discussion by the observers.

#### Statistical Analysis

Descriptive statistics were used to summarize the data. Because of small numbers, type-E tears were regrouped with type-D tears to form a single category, thereafter termed *types D+E*. Sample size estimation showed that 32 shoulders per group would be required to detect a clinically relevant difference of 10 points in the total Constant-Murley score between tear types (C versus D+E), with a standard deviation of 14, an alpha of 0.05, and a power of 0.80. After assessing the normality of distributions for variables and outcomes, the Wilcoxon rank-sum test (2 groups) or Kruskal-Wallis test ( $\geq 3$  groups) was used to compare continuous variables (Constant-Murley score, SSV, and SST) and the Fisher exact test was used to compare categorical variables (tendon repair integrity). Univariable regressions were performed to identify associations of 2 outcomes (total Constant-Murley score and retears defined by Sugaya type IV or V) with 10 variables: patient age, sex, tear type, chronicity, surgical approach, adjuvant biceps procedure, preoperative tendon retraction of the supraspinatus and the infraspinatus, and preoperative fatty infiltration of the supraspinatus and the infraspinatus. Multivariable regressions were then performed after identification of relevant variables by backward selection using the Akaike information criterion (AIC)<sup>34</sup>. With a sample size of 130, our regression models were deemed sufficiently powered on the basis of the recommendation of Austin and Steyerberg<sup>35</sup> of 10 subjects per variable. Statistical analyses

were performed using R version 3.3.3 and the “rms” package. P values of  $<0.05$  were considered significant.

#### Results

In our study cohort of 130 patients, early complications were noted in 14 shoulders (11%). These included 10 cases (8%) of stiffness (a deficit of  $>30^\circ$  in external rotation and passive forward elevation, compared with the intact contralateral shoulder, that had persisted for  $>6$  months after surgery), which were treated successfully by physiotherapy and/or corticosteroid injections, and 4 infections (3%), treated using local and/or oral antibiotics. It should be noted, however, that this complication rate did not account for the 19 shoulders that had subsequent surgery and were not included in the study (Fig. 2).

TABLE VI Univariable Analysis* in Relation to 10 Year Tendon Status (Rear)†			
Variable	Odds Ratio	95% Confidence Interval	P Value
Age	1.03	0.97 to 1.09	0.340
Sex: male vs. female	0.64	0.24 to 1.59	0.350
Collin type: type C vs. types D+E	1.04	0.40 to 2.83	0.939
Tear chronicity: chronic vs. traumatic	0.91	0.38 to 2.15	0.827
Surgical technique: arthroscopy vs. open	0.60	0.22 to 1.49	0.286
Long head of biceps procedure			
None vs. tenodesis	0.95	0.31 to 3.1	0.925
None vs. tenotomy	0.71	0.17 to 3.0	0.641
Preop. supraspinatus tendon retraction			
None vs. moderate	2.04	0.63 to 7.93	0.257
None vs. severe	6.13	1.75 to 25.68	0.007†
Preop. infraspinatus tendon retraction			
None vs. moderate	2.56	0.87 to 7.61	0.087
None vs. severe	4.56	1.34 to 16.47	0.016†
Preop. fatty infiltration of supraspinatus			
Stage 0 vs. 1	2.10	0.61 to 7.92	0.249
Stage 0 vs. 2	4.67	1.29 to 18.95	0.023†
Preop. fatty infiltration of infraspinatus			
Stage 0 vs. 1	1.05	0.33 to 3.35	0.937
Stage 0 vs. 2	3.85	0.97 to 16.68	0.060
*Multivariable analysis was not performed as backward selection identified no relevant variables. †Significant.			



**TABLE VII Comparison Between Patients with and without MRI Follow up**

Variable	Mean $\pm$ Standard Deviation (Range)		P Value
	Not Evaluated Using MRI (N = 28)	Evaluated Using MRI (N = 102)	
Age at surgery (yr)	57.7 $\pm$ 7.3 (38.5 71.3)	55.9 $\pm$ 7.7 (25.5 78.7)	0.202
Constant Murley score			
Preop.	48.2 $\pm$ 17.5 (16.0 82.0)	54.4 $\pm$ 15.3 (14.0 83.0)	0.093
Postop.	74.0 $\pm$ 11.0 (36.0 87.0)	79.5 $\pm$ 11.2 (47.0 98.0)	0.018*
Net improvement	25.9 $\pm$ 23.3 (−26.0 75.0)	25.2 $\pm$ 17.2 (−13.0 71.0)	1.000
SSV	82.0 $\pm$ 16.4 (45.0 100.0)	92.8 $\pm$ 15.5 (30.0 100.0)	0.612
SST	10.1 $\pm$ 2.2 (5.0 12.0)	10.0 $\pm$ 2.1 (3.0 12.0)	0.733

\*Significant.

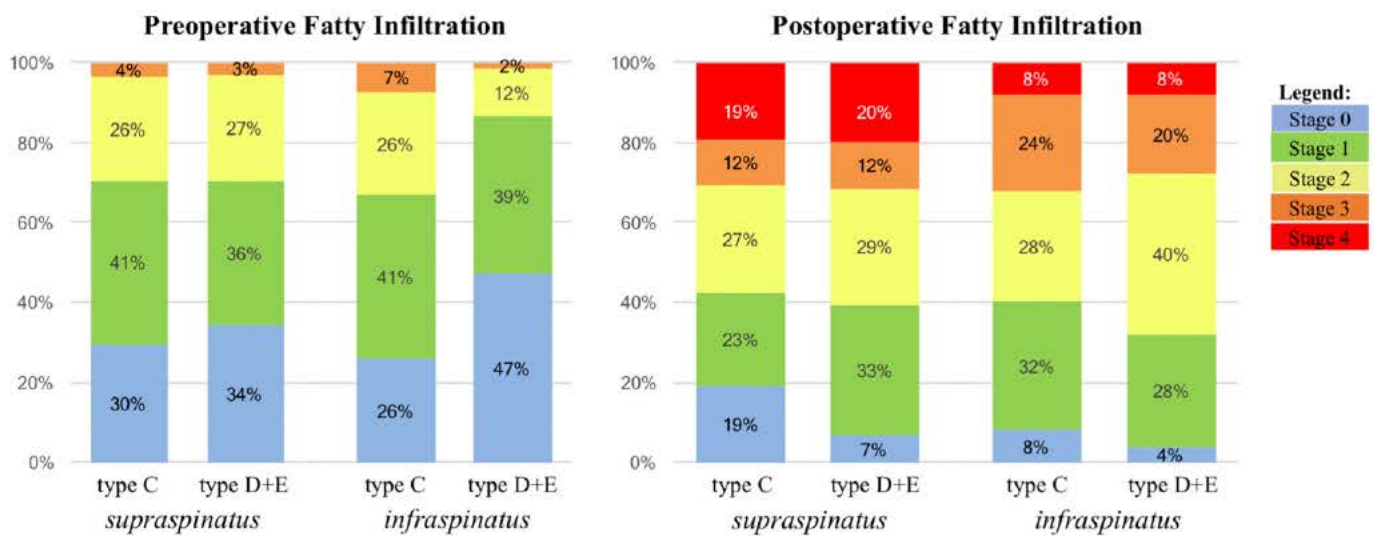
### Clinical Evaluation

Clinical evaluation demonstrated an improvement in the mean total Constant-Murley score from  $53.1 \pm 15.9$  (range, 14 to 83) preoperatively to  $78.5 \pm 11.3$  (range, 36 to 98) at 10 years. The mean postoperative SSV was  $83.4 \pm 15.7$  (range, 30 to 100), and the mean postoperative SST score was  $10.1 \pm 2.1$  (range, 3 to 12). There were no significant differences between the 36 type-C tears and the 94 types-D+E tears in terms of preoperative or postoperative Constant-Murley scores or the postoperative SSV or SST score (Table III). The Kruskal-Wallis test revealed that the postoperative Constant-Murley score was not significantly associated with preoperative tendon retraction (Fig. 3), preoperative fatty infiltration (Fig. 4), or the preoperative subacromial space ( $p = 0.302$ ). Univariable regression revealed that the postoperative

Constant-Murley score was significantly associated only with preoperative fatty infiltration of the supraspinatus ( $p = 0.032$ ). Backward selection identified 4 relevant variables (sex, tear chronicity, surgical technique, and preoperative retraction of the infraspinatus tendon), but multivariable regression revealed that the postoperative Constant-Murley score was significantly associated only with preoperative tendon retraction of the infraspinatus ( $p = 0.020$ ) (Table IV).

### Imaging

Advanced imaging of the 102 shoulders with MRI revealed the repair integrity of the supraspinatus at 10 years to be Sugaya type I in 10 (10%), type II in 31 (30%), type III in 29 (28%), type IV in 12 (12%), and type V in 20 (20%). There were no significant differences in supraspinatus retear rates (Sugaya type IV or V)



All differences between Type C and Type D+E for pre- and post-operative fatty infiltration for the supraspinatus and infraspinatus were not significant.

Fig. 5

Preoperative fatty infiltration associated with type C tears and types D+E tears in the supraspinatus and infraspinatus. No significant differences were found between the 2 types.



## Post-operative Tendon Repair Integrity (Sugaya)

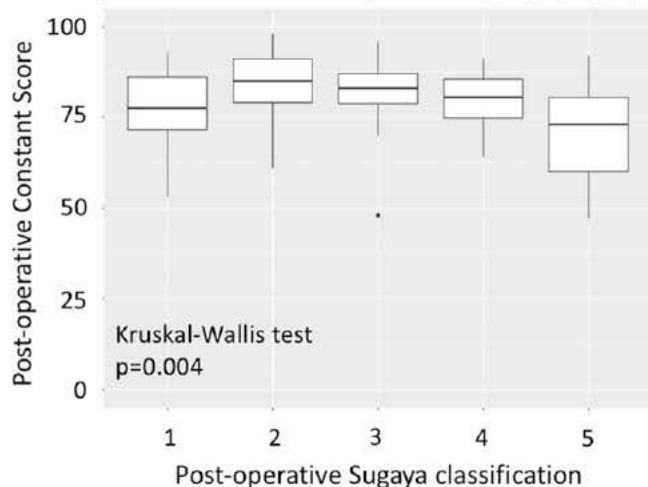


Fig. 6  
Boxplots illustrating 10 year Constant Murley scores for shoulders with different Sugaya classifications of repair integrity<sup>32</sup>. Horizontal line = median, top and bottom of box = third and first quartiles, top and bottom of whiskers = 95% confidence interval, and dot = outlier.

between the type-C tears (8 of 26, 31%) and the types-D+E tears (24 of 76, 32%) (Table V). Univariable regression revealed that the retear rate was significantly associated with severe preoperative tendon retraction of the supraspinatus ( $p = 0.007$ ) and of the infraspinatus ( $p = 0.016$ ) as well as stage-2 fatty infiltration of the supraspinatus ( $p = 0.023$ ), whereas backward selection identified no relevant variables and multivariable regression was therefore not performed (Table VI).

The 28 patients who were not evaluated with MRI had significantly lower 10-year Constant-Murley scores than the 102 evaluated using MRI, although the 2 groups had equivalent SSV and SST scores and net improvements in Constant-Murley scores (Table VII).

The patterns of preoperative fatty infiltration were similar between type-C tears and types-D+E tears, except in the infraspinatus muscle, where it was more advanced (although not significantly so) in type-C tears (Fig. 5). The 10-year Constant-Murley scores were significantly associated with postoperative repair integrity ( $p = 0.004$ ) (Fig. 6).

## Discussion

The principal findings of this study are that, 10 years following repair of massive posterosuperior rotator cuff tears, the postoperative total Constant-Murley scores were still on average 25 points better than the preoperative scores, which exceeds the minimal clinically important difference<sup>36</sup>, despite an overall retear rate of 34%. Furthermore, partial concomitant tears of the subscapularis tendon were not associated with lower scores or higher retear rates. The only independent factor that compromised 10-year functional outcomes was preoperative retraction of the infraspinatus tendon. These findings therefore confirm our first hypothesis, that surgical repair of

massive posterosuperior rotator cuff tears achieves satisfactory clinical scores and repair integrity at 10 years, but refute our second hypothesis, that tears with partial anterior extension (type C) are associated with poorer clinical scores and retear rates compared with tears limited to posterolateral tendons (types D+E). We had expected tears with partial anterior extension to have poorer outcomes due to compromised anterior humeral and biceps stability, but the present findings suggest that surgical repair granted sufficient long-term integrity of the subscapularis.

The average 10-year total Constant-Murley score in the present series was  $78.5 \pm 11.3$ , which compares favorably with scores reported after repairs of massive rotator cuff tears in general<sup>7,9,12,37-39</sup>. We are aware of only 2 studies in which Constant-Murley scores were reported for subgroups of posterosuperior tears in the mid-term: Bennett<sup>40</sup> reported a mean score of 74.0 for a subgroup of 8 patients at 3.2 years, and Godenèche et al.<sup>13</sup> reported a mean score of 81.6 for a subgroup of 33 patients at 3.4 years. Our analyses also revealed that the total Constant-Murley score was associated only with severe preoperative tendon retraction of the infraspinatus, and not of the supraspinatus, and was not associated with preoperative fatty infiltration of either the supraspinatus or the infraspinatus. Our findings contradict a number of recent studies that showed preoperative fatty infiltration beyond stage 1<sup>9,13,41</sup> or 2<sup>42</sup> to significantly compromise postoperative clinical scores. It is important to note, however, that unlike other studies on massive rotator cuff tears—in which considerable proportions of shoulders had fatty infiltration of stages 3 and 4—only 2% of the shoulders in our cohort had stage-3 fatty infiltration and none had stage 4. These recent studies differ considerably, however, with respect to their specific observations. Shon et al.<sup>41</sup> reported that 2-year outcomes of partial repair of irreparable large and massive rotator cuff tears were associated with fatty infiltration of the teres minor, but not fatty infiltration of the other rotator cuff muscles. Dwyer et al.<sup>42</sup> found that “major” fatty infiltration (stages 3 and 4) compromised the reparability of large and massive rotator cuff muscles. Godenèche et al.<sup>13</sup> reported that 3-year clinical scores following repairs of massive rotator cuff tears depend primarily on the extent of preoperative fatty infiltration. Our findings could be different because of the more chronic nature of the tears (mean time from onset to surgery of  $1.8 \pm 3.4$  years) as well as the longer follow-up, both of which could have attenuated differences in outcomes.

The rate of retears at 10 years in the present series is 34%, which is within the range reported in the literature on massive rotator cuff tears<sup>1,5-13</sup>. Direct comparison of results is difficult, however, because of the heterogeneity of cohorts, techniques, follow-up, and scoring systems. The total postoperative Constant-Murley scores were significantly correlated with repair integrity at 10 years (Fig. 6). It is worth noting, however, that although retears were significantly associated with preoperative tendon retraction and fatty infiltration in univariable analysis (Table VI), backward selection did not identify any significant associations with retears. This unexpected finding may be due to the limited size of the radiographic cohort



(n = 102) and, particularly, to the relatively small number of retears observed (n = 32), although the present series represents one of the largest cohorts of massive rotator cuff tears with long-term MRI assessment. The outcomes of surgical repairs of massive rotator cuff tears have improved over the years, thanks to advances in operative techniques and materials<sup>11,22,43</sup>.

The recognition that some massive tears may not be repairable, particularly in elderly patients with advanced fatty infiltration, has led some surgeons to prefer reverse shoulder arthroplasty. To our knowledge, we are the first to report long-term outcomes of surgical repair in a large sample of massive rotator cuff tears, and the satisfactory clinical and anatomic findings suggest that tendon repair should be considered, rather than other more invasive treatments, especially for young patients.

As is typical of retrospective investigations, this study has limitations related to selection and performance bias, including the large proportion of patients lost to follow-up (33%) and the exclusion of patients who had a reoperation or did not have follow-up MRI. It is worth noting, however, that the patients who did not have follow-up MRI (n = 28) had lower 10-year Constant-Murley scores than the patients who had follow-up MRI (n = 102), although their net score improvements were equivalent. Furthermore, the small number of retears observed (n = 32) may have been insufficient to perform multivariable regression analysis to identify independent predictors. Finally, the effects of the heterogeneity of the repair techniques, such as with regard to the suture techniques and anchor materials used, are difficult to evaluate because of the multicentric nature of the study.

The main strength of the present study is that it investigated structural and functional outcomes at the time of long-term follow-up after repair of massive posterosuperior rotator cuff tears. Our data therefore enabled a 10-year evaluation of repair integrity.

In conclusion, 10 years following repair of massive posterosuperior rotator cuff tears, the postoperative total Constant-Murley scores were on average 25 points better than the preoperative scores, despite an overall retear rate of 34%. Partial concomitant tears of the subscapularis tendon (type-C tears) were not associated with lower clinical scores or higher retear rates than tears limited to the supraspinatus and infraspinatus (types-D+E tears). At 10 years, the total Constant-Murley score was significantly associated with repair integrity. ■

NOTE: The authors thank the following members of the symposium sponsored by SOFCOT (Société Française de Chirurgie Orthopédique et Traumatologique) for their contributions to patient enrollment, data collection, statistical analysis, and interpretation of findings: G. Andre, B. Augereau, M. Betz, D. Deplanque, J.-C. Dosch, L. Favard, M. Ferrand, P.-H. Flurin, A. Fregeac, C. Gerber, A. Godenèche, P. Hardy, A. Herve, M. Khalife, L. Lafosse, N. Meyer, D. Mole, C. Nich, L. Niglis, G. Opsemer, V. Sabatier, P. Valenti, and G. Walch. The authors are also grateful to A. Hibon for her assistance with data management and manuscript preparation.

Philippe Collin, MD<sup>1</sup>  
Michel Colmar, MD<sup>2</sup>  
Hervé Thomazeau, MD<sup>3,4</sup>  
Pierre Mansat, MD, PhD<sup>5</sup>  
Pascal Boileau, MD<sup>6</sup>  
Philippe Valenti, MD<sup>7</sup>  
Mo Saffarini, MEng<sup>8</sup>  
Luca Nover, MSc<sup>8</sup>  
Jean François Kempf, MD, PhD<sup>9</sup>

<sup>1</sup>Institut Locomoteur de l'Ouest CHP Saint Grégoire (Vivalto Santé), Saint Grégoire, France

<sup>2</sup>Hôpital Privé des Côtes d'Armor, Plérin, France

<sup>3</sup>Université de Rennes 1, Rennes, France

<sup>4</sup>Service de Chirurgie Orthopédique, Centre Hospitalier Universitaire de Rennes, Hôpital Pontchaillou, Rennes, France

<sup>5</sup>Toulouse University Hospital, Toulouse, France

<sup>6</sup>Service de Chirurgie Orthopédique et Chirurgie du Sport, Institut Universitaire Locomoteur et du Sport, CHU de Nice Hôpital Pasteur, Nice, France

<sup>7</sup>Institut Parisien de l'Epaule, Clinique Bizet, Paris, France

<sup>8</sup>ReSurg SA, Nyon, Switzerland

<sup>9</sup>Centre Hospitalier Universitaire de Strasbourg, Strasbourg, France

E mail address for M. Saffarini: journals@resurg.eu

ORCID iD for P. Collin: [0000 0002 2821 2182](https://orcid.org/0000-0002-2821-2182)  
ORCID iD for M. Colmar: [0000 0001 9639 1787](https://orcid.org/0000-0001-9639-1787)  
ORCID iD for H. Thomazeau: [0000 0003 1730 7597](https://orcid.org/0000-0003-1730-7597)  
ORCID iD for P. Mansat: [0000 0002 2333 0366](https://orcid.org/0000-0002-2333-0366)  
ORCID iD for P. Boileau: [0000 0003 0140 9505](https://orcid.org/0000-0003-0140-9505)  
ORCID iD for P. Valenti: [0000 0002 0352 8527](https://orcid.org/0000-0002-0352-8527)  
ORCID iD for M. Saffarini: [0000 0002 9656 987X](https://orcid.org/0000-0002-9656-987X)  
ORCID iD for L. Nover: [0000 0002 0311 7891](https://orcid.org/0000-0002-0311-7891)  
ORCID iD for J. F. Kempf: [0000 0003 3399 637X](https://orcid.org/0000-0003-3399-637X)

## References

- Galatz LM, Ball CM, Teefey SA, Middleton WD, Yamaguchi K. The outcome and repair integrity of completely arthroscopically repaired large and massive rotator cuff tears. *J Bone Joint Surg Am*. 2004 Feb;86 A(2):219-24.
- Kim KC, Shin HD, Cha SM, Kim JH. Repair integrity and functional outcomes for arthroscopic margin convergence of rotator cuff tears. *J Bone Joint Surg Am*. 2013 Mar 20;95(6):536-41.
- Thès A, Hardy P, Bak K. Decision making in massive rotator cuff tear. *Knee Surg Sports Traumatol Arthrosc*. 2015 Feb;23(2):449-59. Epub 2014 Dec 11.
- Le BT, Wu XL, Lam PH, Murrell GA. Factors predicting rotator cuff retears: an analysis of 1000 consecutive rotator cuff repairs. *Am J Sports Med*. 2014 May;42(5):1134-42. Epub 2014 Apr 18.
- Gerber C, Fuchs B, Hodler J. The results of repair of massive tears of the rotator cuff. *J Bone Joint Surg Am*. 2000 Apr;82(4):505-15.
- Zumstein MA, Jost B, Hempel J, Hodler J, Gerber C. The clinical and structural long term results of open repair of massive tears of the rotator cuff. *J Bone Joint Surg Am*. 2008 Nov;90(11):2423-31.
- Chung SW, Huang CB, Kim SH, Oh JH. Shoulder stiffness after rotator cuff repair: risk factors and influence on outcome. *Arthroscopy*. 2013 Feb;29(2):290-300. Epub 2013 Jan 3.
- Park JY, Lee SH, Oh KS, Moon SG, Hwang JT. Clinical and ultrasonographic outcomes of arthroscopic suture bridge repair for massive rotator cuff tear. *Arthroscopy*. 2013 Feb;29(2):280-9.
- Barth J, Fotiadis E, Barthelemy R, Genna S, Saffarini M. Ultrasonic evaluation of the repair integrity can predict functional outcomes after arthroscopic double row rotator cuff repair. *Knee Surg Sports Traumatol Arthrosc*. 2015 Feb;23(2):376-85. Epub 2015 Jan 20.



10. Berdusco R, Trantalís JN, Nelson AA, Sohmer S, More KD, Wong B, Boorman RS, Lo IK. Arthroscopic repair of massive, contracted, immobile tears using interval slides: clinical and MRI structural follow up. *Knee Surg Sports Traumatol Arthrosc.* 2015 Feb;23(2):502 7. Epub 2013 Sep 22.
11. Heuberger PR, Kölblinger R, Buchleitner S, Pauzenberger L, Laky B, Auffarth A, Moroder P, Salem S, Krieglleder B, Anderl W. Arthroscopic management of massive rotator cuff tears: an evaluation of debridement, complete, and partial repair with and without force couple restoration. *Knee Surg Sports Traumatol Arthrosc.* 2016 Dec;24(12):3828 37. Epub 2015 Aug 8.
12. Wang E, Wang L, Gao P, Li Z, Zhou X, Wang S. Single versus double row arthroscopic rotator cuff repair in massive tears. *Med Sci Monit.* 2015 May 28;21:1556 61.
13. Godenèche A, Freychet B, Lanzetti RM, Clechet J, Carrillon Y, Saffarini M. Should massive rotator cuff tears be reconstructed even when only partially repairable? *Knee Surg Sports Traumatol Arthrosc.* 2017 Jul;25(7):2164 73. Epub 2016 Apr 7.
14. Chung SW, Kim JY, Kim MH, Kim SH, Oh JH. Arthroscopic repair of massive rotator cuff tears: outcome and analysis of factors associated with healing failure or poor postoperative function. *Am J Sports Med.* 2013 Jul;41(7):1674 83. Epub 2013 Apr 30.
15. Favard L, Berhouet J, Colmar M, Boukobza E, Richou J, Sonnard A, Huguet D, Courage O; Société d'orthopédie de l'Ouest. Massive rotator cuff tears in patients younger than 65 years. What treatment options are available? *Orthop Traumatol Surg Res.* 2009 Jun;95(4)(Suppl 1):S19 26. Epub 2009 May 7.
16. Boileau P, Baqué F, Valerio L, Ahrens P, Chuinard C, Trojani C. Isolated arthroscopic biceps tenotomy or tenodesis improves symptoms in patients with massive irreparable rotator cuff tears. *J Bone Joint Surg Am.* 2007 Apr;89(4):747 57.
17. Bennett WF. Arthroscopic repair of isolated subscapularis tears: A prospective cohort with 2 to 4 year follow up. *Arthroscopy.* 2003 Feb;19(2):131 43.
18. Cofield RH. Rotator cuff disease of the shoulder. *J Bone Joint Surg Am.* 1985 Jul;67(6):974 9.
19. DeOrio JK, Cofield RH. Results of a second attempt at surgical repair of a failed initial rotator cuff repair. *J Bone Joint Surg Am.* 1984 Apr;66(4):563 7.
20. Mori D, Funakoshi N, Yamashita F. Arthroscopic surgery of irreparable large or massive rotator cuff tears with low grade fatty degeneration of the infraspinatus: patch autograft procedure versus partial repair procedure. *Arthroscopy.* 2013 Dec;29(12):1911 21. Epub 2013 Oct 26.
21. Fossati C, Arrigoni P, Ragone V, Spennacchio P, Banfi G, Randelli F, Randelli P. How do massive immobile rotator cuff tears behave after arthroscopic interval slides? Comparison with mobile tears. *Joints.* 2014 Jul 8;2(2):66 70.
22. Iagulli ND, Field LD, Hobgood ER, Ramsey JR, Savoie FH 3rd. Comparison of partial versus complete arthroscopic repair of massive rotator cuff tears. *Am J Sports Med.* 2012 May;40(5):1022 6. Epub 2012 Mar 13.
23. Ok HS, Kim BG, Choi WC, Hong CG, Kim JW, Kim JH. Clinical relevance of classifying massive rotator cuff tears: results based on functional and radiological findings after arthroscopic repair. *Am J Sports Med.* 2017 Jan;45(1):157 66. Epub 2016 Oct 21.
24. Collin P, Matsumura N, Lädermann A, Denard PJ, Walch G. Relationship between massive chronic rotator cuff tear pattern and loss of active shoulder range of motion. *J Shoulder Elbow Surg.* 2014 Aug;23(8):1195 202. Epub 2014 Jan 14.
25. Constant CR, Murley AH. A clinical method of functional assessment of the shoulder. *Clin Orthop Relat Res.* 1987 Jan;(214):160 4.
26. Goutallier D, Postel JM, Bernageau J, Lavau L, Voisin MC. Fatty muscle degeneration in cuff ruptures. Pre and postoperative evaluation by CT scan. *Clin Orthop Relat Res.* 1994 Jul;(304):78 83.
27. Fuchs B, Weishaupt D, Zanetti M, Hodler J, Gerber C. Fatty degeneration of the muscles of the rotator cuff: assessment by computed tomography versus magnetic resonance imaging. *J Shoulder Elbow Surg.* 1999 Nov Dec;8(6):599 605.
28. Patte D. Classification of rotator cuff lesions. *Clin Orthop Relat Res.* 1990 May;(254):81 6.
29. Hamada K, Fukuda H, Mikasa M, Kobayashi Y. Roentgenographic findings in massive rotator cuff tears. A long term observation. *Clin Orthop Relat Res.* 1990 May;(254):92 6.
30. Gilbert MK, Gerber C. Comparison of the subjective shoulder value and the Constant score. *J Shoulder Elbow Surg.* 2007 Nov Dec;16(6):717 21.
31. Lippitt SB, Harryman DT II, Matsen FA III. A practical tool for evaluating function: the Simple Shoulder Test. In: Matsen FA III, Fu FH, Hawkins RJ, editors. *The shoulder: a balance of mobility and stability.* Rosemont: American Academy of Orthopaedic Surgeons; 1993.
32. Sugaya H, Maeda K, Matsuki K, Moriishi J. Repair integrity and functional outcome after arthroscopic double row rotator cuff repair. A prospective outcome study. *J Bone Joint Surg Am.* 2007 May;89(5):953 60.
33. Niglis L, Collin P, Dosch JC, Meyer N, Kempf JF; SoFCOT. Intra and inter observer agreement in MRI assessment of rotator cuff healing using the Sugaya classification 10years after surgery. *Orthop Traumatol Surg Res.* 2017 Oct;103(6):835 9. Epub 2017 Jun 24.
34. Akaike H. A new look at the statistical model identification. *IEEE Trans Automat Contr.* 1974;19(6):716 23.
35. Austin PC, Steyerberg EW. The number of subjects per variable required in linear regression analyses. *J Clin Epidemiol.* 2015 Jun;68(6):627 36. Epub 2015 Jan 22.
36. Kukkonen J, Joukainen A, Itälä A, Äärimaa V. Operatively treated traumatic versus non traumatic rotator cuff ruptures: a registry study. *Ups J Med Sci.* 2013 Mar;118(1):29 34. Epub 2012 Nov 20.
37. Burkhart SS, Barth JR, Richards DP, Zlatkin MB, Larsen M. Arthroscopic repair of massive rotator cuff tears with stage 3 and 4 fatty degeneration. *Arthroscopy.* 2007 Apr;23(4):347 54.
38. Denard PJ, Burkhart SS. Medialization of the subscapularis footprint does not affect functional outcome of arthroscopic repair. *Arthroscopy.* 2012 Nov;28(11):1608 14. Epub 2012 May 24.
39. Moser M, Jablonski MV, Horodyski M, Wright TW. Functional outcome of surgically treated massive rotator cuff tears: a comparison of complete repair, partial repair, and debridement. *Orthopedics.* 2007 Jun;30(6):479 82.
40. Bennett WF. Arthroscopic repair of massive rotator cuff tears: a prospective cohort with 2 to 4 year follow up. *Arthroscopy.* 2003 Apr;19(4):380 90.
41. Shon MS, Koh KH, Lim TK, Kim WJ, Kim KC, Yoo JC. Arthroscopic partial repair of irreparable rotator cuff tears: preoperative factors associated with outcome deterioration over 2 years. *Am J Sports Med.* 2015 Aug;43(8):1965 75. Epub 2015 May 26.
42. Dwyer T, Razmjou H, Henry P, Gosselin Fournier S, Holtby R. Association between pre operative magnetic resonance imaging and reparability of large and massive rotator cuff tears. *Knee Surg Sports Traumatol Arthrosc.* 2015 Feb;23(2):415 22. Epub 2013 Oct 30.
43. Franceschi F, Papalia R, Vasta S, Leonardi F, Maffulli N, Denaro V. Surgical management of irreparable rotator cuff tears. *Knee Surg Sports Traumatol Arthrosc.* 2015 Feb;23(2):494 501. Epub 2012 Dec 2.