



HAL
open science

Anatomical total shoulder arthroplasty in young patients with osteoarthritis

Marc Olivier Gauci, Nicolas Bonneville, Grégory Moineau, Mohammed Baba, Gilles Walch, Pascal Boileau

► **To cite this version:**

Marc Olivier Gauci, Nicolas Bonneville, Grégory Moineau, Mohammed Baba, Gilles Walch, et al.. Anatomical total shoulder arthroplasty in young patients with osteoarthritis. *The Bone & Joint Journal (BJJ)*, 2018, 100-B (4), pp.485-492. 10.1302/0301-620X.100B4.BJJ-2017-0495.R2 . hal-02135074

HAL Id: hal-02135074

<https://hal.science/hal-02135074>

Submitted on 21 May 2019

HAL is a multi-disciplinary open access archive for the deposit and dissemination of scientific research documents, whether they are published or not. The documents may come from teaching and research institutions in France or abroad, or from public or private research centers.

L'archive ouverte pluridisciplinaire **HAL**, est destinée au dépôt et à la diffusion de documents scientifiques de niveau recherche, publiés ou non, émanant des établissements d'enseignement et de recherche français ou étrangers, des laboratoires publics ou privés.




Open Archive Toulouse Archive Ouverte (OATAO)

OATAO is an open access repository that collects the work of some Toulouse researchers and makes it freely available over the web where possible.

This is an author's version published in: <https://oatao.univ-toulouse.fr/23095>

Official URL : <https://doi.org/10.1302/0301-620X.100B4.BJJ-2017-0495.R2>

To cite this version :

Gauci, Marc Olivier and Bonneville, Nicolas  and Moineau, Grégory and Baba, Mohammed and Walch, Gilles and Boileau, Pascal *Anatomical total shoulder arthroplasty in young patients with osteoarthritis*. (2018) *The Bone & Joint Journal*, 100-B (4). 485-492. ISSN 2049-4394

Any correspondence concerning this service should be sent to the repository administrator:

tech-oatao@listes-diff.inp-toulouse.fr

Anatomical total shoulder arthroplasty in young patients with osteoarthritis

ALL-POLYETHYLENE VERSUS METAL-BACKED GLENOID

M. O. Gauci,
N. Bonnevielle,
G. Moineau,
M. Baba,
G. Walch,
P. Boileau

*From Institut
Universitaire
Locomoteur et du
Sport, Hôpital
Pasteur 2, Nice,
France*

■ M. O. Gauci, MD, Orthopaedic Surgeon
Institut Universitaire
Locomoteur et du Sport,
Hôpital Pasteur 2 and
Université Nice-Sophia
Antipolis, Nice Cedex 1, France.

■ N. Bonnevielle, MD, PhD,
Orthopaedic Surgeon
Centre Hospitalier Universitaire
de Toulouse-Purpan, Toulouse,
France.

■ G. Moineau, MD, Orthopaedic Surgeon
Clinique Pasteur-Lanroze, Brest,
France.

■ M. Baba, MD, FRACS,
Orthopaedic Surgeon
Sydney Adventist Hospital,
Wahroonga, New South Wales,
Australia.

■ G. Walch, MD, Orthopaedic Surgeon
Centre Médical Santy, Lyon,
France

■ P. Boileau, MD, Orthopaedic Surgeon
Institut Universitaire
Locomoteur et du Sport,
Hôpital Pasteur 2 and
Université Nice-Sophia
Antipolis, Nice Cedex 1, France.

Correspondence should be sent to P. Boileau; email: boileau.p@chu-nice.fr

Aims

Controversy about the use of an anatomical total shoulder arthroplasty (aTSA) in young arthritic patients relates to which is the ideal form of fixation for the glenoid component: cemented or cementless. This study aimed to evaluate implant survival of aTSA when used in patients aged < 60 years with primary glenohumeral osteoarthritis (OA), and to compare the survival of cemented all-polyethylene and cementless metal-backed glenoid components.

Materials and Methods

A total of 69 consecutive aTSAs were performed in 67 patients aged < 60 years with primary glenohumeral OA. Their mean age at the time of surgery was 54 years (35 to 60). Of these aTSAs, 46 were undertaken using a cemented polyethylene component and 23 were undertaken using a cementless metal-backed component. The age, gender, preoperative function, mobility, pre-morbid glenoid erosion, and length of follow-up were comparable in the two groups. The patients were reviewed clinically and radiographically at a mean of 10.3 years (5 to 12, SD 26) postoperatively. Kaplan–Meier survivorship analysis was performed with revision as the endpoint.

Results

A total of 26 shoulders (38%) underwent revision surgery: ten (22%) in the polyethylene group and 16 (70%) in the metal-backed group ($p < 0.0001$). At 12 years' follow-up, the rate of implant survival was 74% (SD 0.09) for polyethylene components and 24% (SD 0.10) for metal-backed components ($p < 0.0002$). Glenoid loosening or failure was the indication for revision in the polyethylene group, whereas polyethylene wear with metal-on-metal contact, instability, and insufficiency of the rotator cuff were the indications for revision in the metal-backed group.

Preoperative posterior subluxation of the humeral head with a biconcave/retroverted glenoid (Walch B2) had an adverse effect on the survival of a metal-backed component.

Conclusion

The survival of a cemented polyethylene glenoid component is three times higher than that of a cementless metal-backed glenoid component ten years after aTSA in patients aged < 60 years with primary glenohumeral OA. Patients with a biconcave (B2) glenoid have the highest risk of failure.

The treatment of symptomatic primary glenohumeral osteoarthritis (OA) in patients aged < 60 years is controversial. Given that the number of arthroplasties of the shoulder that are being undertaken in young patients is increasing at a rate of 8.2% per year,¹ it is important to consider the requirement for revision at some time in the future.^{2,3} Arthroplasty of the shoulder in the young patient remains a challenge, as their physical

demands are higher and they have a longer life expectancy.⁴ Most of the controversy about this procedure in young patients relates to the management of the glenoid (resurfacing or not) and, when the glenoid is resurfaced, whether the fixation should be cemented or cementless.^{5–7} Hemiarthroplasty provides less predictable pain relief than anatomical total shoulder arthroplasty (aTSA), and may lead to erosion of the glenoid with significant

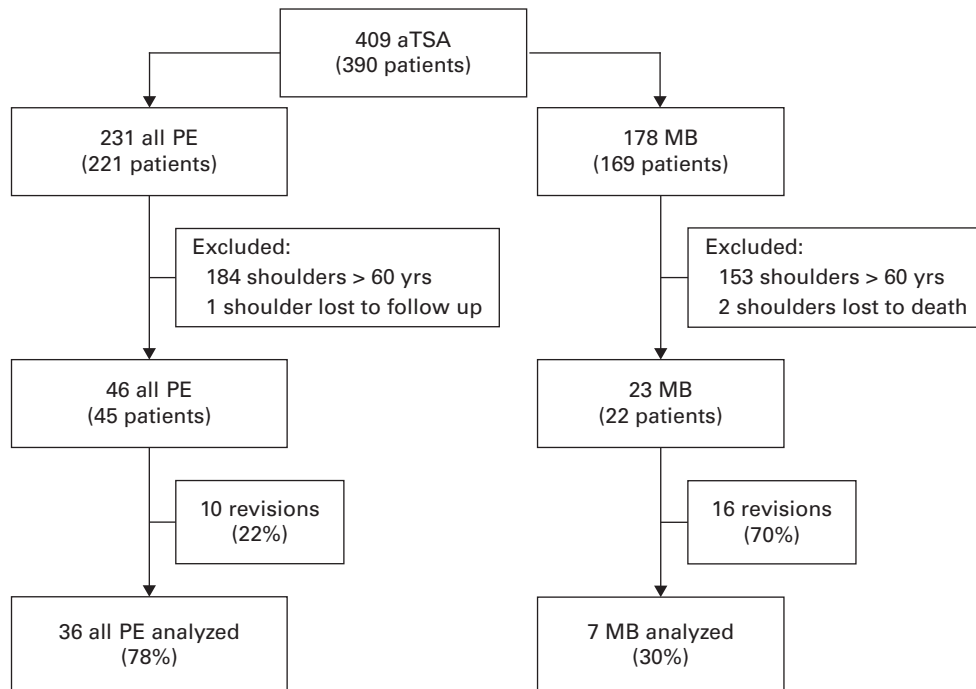


Fig. 1

Flowchart showing the functional analysis and revision. aTSA, anatomical total shoulder arthroplasty; PE, polyethylene; MB, metal-backed.

symptoms.^{8,9} Moreover, revisions of hemiarthroplasty to aTSA give worse results than primary aTSA.¹⁰ These observations have led to a decreasing use of hemiarthroplasty compared with aTSAs in young patients.^{1,11}

In the general population, a number of complications may occur on the glenoid side with loosening or failure.¹²⁻¹⁴ Some surgeons prefer to use a cementless metal-backed glenoid component in a young patient,¹⁵ whereas others prefer to use a cemented all-polyethylene component.^{6,16} The arguments for using a metal-backed component in young patients are an improved fixation to bone and theoretically easier revision surgery. However, there is little available evidence to compare these implants, and little is known about their survival in young patients. The purpose of this study was to evaluate the longevity of aTSA when used in young patients with primary glenohumeral OA and to compare the survival of glenoid resurfacing using either cemented polyethylene or cementless metal-backed components. We hypothesized that, at mid- and long-term follow-up, both cemented and cementless components in aTSA would be at risk of failure in patients < 60 years.

Patients and Methods

This retrospective study was undertaken in five centres on patients undergoing surgery between 1994 and 1999. Those with a metal-backed component had been included in a previous study by Boileau et al.¹⁷ At a minimum of three years' follow-up, the authors demonstrated that: 1)

the survival rate of cementless metal-backed components was inferior to cemented all-polyethylene components; and 2) the incidence of radiolucency at the glenoid-cement interface with all-polyethylene components was high. Inclusion criteria were: age < 60 years at the time of surgery, a single diagnosis of primary glenohumeral OA, an intact rotator cuff preoperatively, those with the same cemented humeral component, glenoid resurfacing with either a cemented polyethylene or a cementless metal-backed glenoid component, and minimum clinical and radiological follow-up of five years. Exclusion criteria included other diagnoses, those undergoing revision arthroplasty, and those whose operation involved glenoid bone graft.

A total of 69 consecutive shoulders in 67 patients were included (Fig. 1). Six patients (six shoulders) had previous surgery: four arthroscopic debridements and two acromioplasties.

The demographics of the patients were recorded and analyzed for differences between cemented-polyethylene (n = 46) and cementless-metal-backed glenoid components (n = 23). Initially, the two groups were comparable. A preoperative CT arthrogram was performed to assess the rotator cuff and the type of erosion of the glenoid according to Walch et al¹⁸ (Table I).

Operative technique and components. A deltopectoral approach was used. The subscapularis tendon was tenotomized in 57 cases (82%) and a subscapularis peel was performed in 12 cases (18%). Tenodesis of the long

Table I. Initial demographic data and glenoid morphology, rotator cuff status, and fatty degeneration evaluated on preoperative CT arthrogram (n = 69)

	Cemented, all-PE glenoid (n = 46)	Cementless, MB glenoid (n = 23)	p-value*
Mean age, yrs (range)	55 (40 to 60)	53 (35 to 60)	0.24
Gender (male:female)	28:18	13:10	0.10
Mean preoperative Constant score (SD)	28 (12)	30 (10)	0.32
Mean preoperative Adjusted Constant score, % (SD)	33 (14)	36 (12)	0.36
Pain	4 (2)	4 (3)	
Activity	7 (3)	7 (3)	
Mobility	14 (5)	15 (5)	
Strength	4 (5)	4 (5)	
Mean preoperative anterior forward elevation, ° (SD)	88 (27)	88 (26)	0.38
Preoperative active external rotation, ° (SD)	9 (18)	-3 (13)	0.02
Preoperative active internal rotation, pts (SD)	4 (2)	2 (2)	0.37
Glenoid erosion (CT scan), n (%)			
Walch Type A	13 A1, 8 A2 (47)	7 A1, 2 A2 (40)	0.24
Walch Type B	6 B1, 19 B2 (53)	10 B1, 3 B2 (56)	0.21
Walch Type C	0 (0)	1 (4)	0.28
Partial cuff tear, %			
Supraspinatus	14	13	0.21
Infraspinatus	5	4	0.34
Subscapularis fatty infiltration, %			
0	73	40	0.09
1	24	57	0.14
2	3	3	0.23

*Mann-Whitney U test

PE, polyethylene; MB, metal-backed

head of the biceps was undertaken in 40 cases (58%) with a suture to the transverse humeral ligament. The rotator cuff was intact except in five shoulders (7%) with a partial tear of supraspinatus that was left untreated. The same cemented third generation humeral component was used in all patients (Aequalis; Tornier, Montbonnot, France, anatomical prosthesis).^{6,19} An eccentric dial system in the prosthetic head allowed the offset of the articular surface of the humeral head to be reproduced in relation to the shaft and a variable inclination of the neck allowed reproduction of the individual neck-shaft angle.²⁰

The choice of glenoid component (cemented polyethylene or cementless metal-backed) was left to the discretion of the surgeon without specific criteria. The polyethylene component (Aequalis PE; Tornier, Montbonnot, France) had a trapezoidal keel that was the same size irrespective of size of the glenoid. The component was flat or curved-back depending the radius of curvature of the glenoid with a total thickness of 5 mm. Polyethylene components contained shallow rings within the keel for interlocking with cement. The metal-backed component (Aequalis MB Glenoid; Tornier, Montbonnot, France) had a flat tray 3 mm thick, a 4 mm polyethylene insert, and two expandable pegs with a screw. It was thus 2 mm thicker (7 mm) than the polyethylene component and had a hydroxyapatite-coated back with a matrix surface to allow the ingrowth of bone. The polyethylene in both components underwent the same manufacturing process and was sterilized in air. The operative technique has been described previously.⁶ Asymmetrical anterior reaming was performed to make the surface of the glenoid perpendicular to the scapular axis in those with posterior erosion or

severe retroversion.¹⁸ The same postoperative rehabilitation protocol was used for all patients.

Outcomes assessment. Clinical and radiographic assessment was undertaken at three, six, 12, and 24 months postoperatively and yearly thereafter.²¹ Visual analogue scale (VAS) scores for pain and active range of movement, as well as the original and adjusted Constant scores,²² were recorded and the patients rated the outcome using the Subjective Shoulder Value (SSV).²³

The Mole²⁴ classification was used to assess radiolucent lines (RLLs). The glenoid component was considered to be loose if there was migration or tilt, a petal or tray-fracture, or a RLL score of > 10 points. Polyethylene wear was considered present if the thickness between the humeral head and the surface of the bone for the polyethylene component or tray of the metal for the metal-backed component decreased between the postoperative and latest radiographs and/or if there was metal-on-metal contact.

All patients gave written, informed consent.

Statistical analysis. Wilcoxon's paired *t*-test was used for the analysis of pre- and postoperative data. Comparison between the groups at the final follow-up was performed with the Mann-Whitney test and the Kruskal-Wallis test was used for non-paired data. Survival of the implants were estimated using the Kaplan-Meier method.²⁵ Patients who died were used as censored data. A *p*-value < 0.05 was considered significant.

Results

At 12 years, the rate of implant survival with revision as the endpoint was 74% (SD 0.09) for the cemented polyethylene component and 24% (SD 0.10) for the cementless metal-

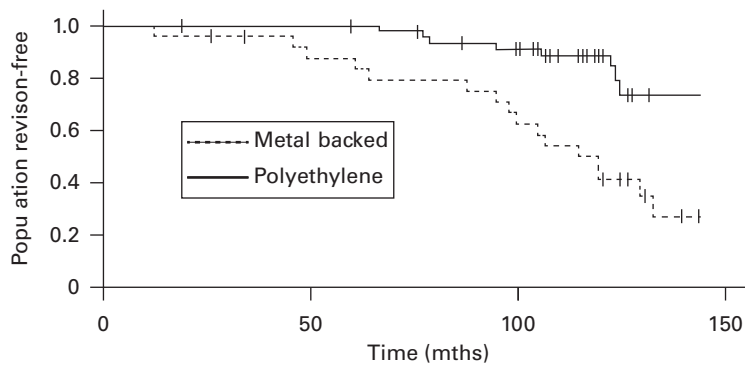


Fig. 2

Kaplan–Meier survivorship after anatomical total shoulder arthroplasty (aTSA) for primary glenohumeral osteoarthritis in patients aged < 60 years. Patients who died are considered as censored data. At 12-year follow-up, the revision-free rate of survival was 74% (SD 0.09) for the cemented all-polyethylene component and 24% (SD 0.10) for the cementless metal-backed component ($p = 0.00002$). The mean age was 54 years (35 to 60) and the mean follow-up was nine years (5 to 13).

Table II. Complications according to the type of glenoid component that was used (more than one complication may occur in a patient)

	All-PE glenoid	MB glenoid	Global series
Glenoid loosening, n	10	5	15
Excessive PE wear, n	0	9	9
Rotator cuff tear, n	3	0	3
Instability, n	0	5	5
Infection, n	0	1	1
Stiffness, n	0	1	1
Total, n (%)	13/46 (28)	21/23 (91)	34/69 (49)

PE, polyethylene; MB, metal-backed

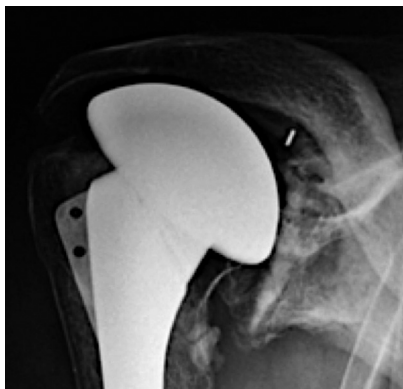

Fig. 3

Anteroposterior radiograph of a cemented, all-polyethylene component, 15 years after surgery. Despite obvious glenoid loosening with superior tilting of the component, the patient has little pain and a functional shoulder.

backed component (Fig. 2); this difference was significant ($p = 0.00002$).

The risk of the glenoid component requiring removal was significantly higher for the metal-backed component (odds ratio, 6.58; 95% confidence interval, 2.25 to 19.27; $p < 0.001$). A total of 34 complications (51%) occurred in

69 shoulders. They are summarized in Table II. Complications occurred in 13 shoulders in the polyethylene group at a mean of 10.1 years, the main complication being glenoid loosening, although many patients were asymptomatic (Fig. 3).

Complications occurred in 21 shoulders in the metal-backed group at a mean of 8.6 years, the main complications being polyethylene wear with metal-on-metal contact and instability (Table II, Fig. 4).

A total of 26 shoulders (38%) underwent revision surgery. The rate of revision was more than three times higher with metal-backed components (70%) than with polyethylene components (22%; $p < 0.0001$). Ten (22%) in the polyethylene group needed revision at a mean of 9.3 years and 16 (70%) in the metal-backed group required revision at a mean of 7.5 years. ($p < 0.0001$). Although there can be many indications for revision of aTSA, the primary indications are shown in Table III. The main indication was loosening in the polyethylene group and dysfunction of the rotator cuff and/or instability in the metal-backed group.

In the metal-backed group, excessive polyethylene wear with metal-on-metal contact occurred in nine shoulders (39%) at a mean of seven years (2.5 to 11 years) (Fig. 5).

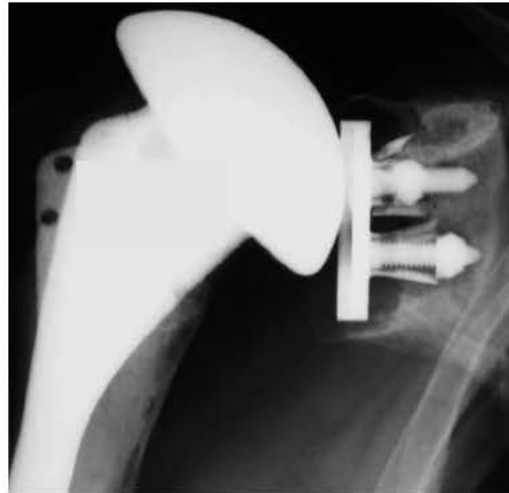

Fig. 4

Radiograph of a cementless, metal-backed component five years after surgery, showing loosening due to anterior instability secondary to insufficiency of subscapularis. Severe glenoid bone loss was found at revision surgery with asymmetrical anterior polyethylene wear.

Table III. Primary indications for revision surgery according to the type of glenoid component

	All-PE glenoid	MB glenoid	Global series
Glenoid loosening, n	10	3	13
Excessive PE wear, n	0	9	9
Instability, n	0	2	2
Infection, n	0	1	1
Stiffness, n	0	1	1
Total, n (%)	10/46 (22)	16/23 (70)	26/69 (38)

PE, polyethylene; MB, metal-backed

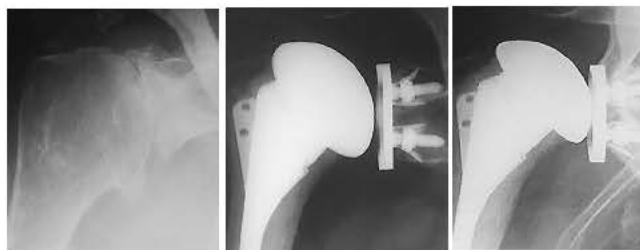


Fig. 5a

Fig. 5b

Fig. 5c

Radiographs taken a) preoperatively, b) three years and c) nine years postoperatively showing complete polyethylene wear with metal-on-metal contact without loosening of a metal-backed glenoid component.

Two patients required revision due to recurrent posterior dislocation. Both had complete wear of the posterior part of the polyethylene, although this was not the primary indication for revision. Three aTSA had glenoid loosening without polyethylene wear. A reverse shoulder arthroplasty (RSA) was used in one; in the other two, the glenoid component was removed and reconstruction with an iliac

crest bone graft was undertaken without replacing the glenoid component.

During revision, conservation of the metal-backed tray with the introduction of a new polyethylene insert was not possible because of associated soft-tissue deficiency, prosthetic instability, glenoid bone loss, and erosion or damage of the tray. It was not possible to adapt a sphere on the metal-backed tray to convert the aTSA into a RSA, although this was theoretically possible with this design of glenoid component.

Influence of initial type of glenoid erosion. Among the 22 shoulders with a polyethylene component who had a native type A glenoid (A1 and A2), 17 (77%) developed radiological evidence of glenoid loosening with or without symptoms; this was found in 18 of 24 (75%) in the type-B glenoid group. No significant difference was found with respect to the native glenoid morphology, according to Walch et al.¹⁸

Among the nine shoulders with a metal-backed component who had a native type A glenoid (A1 and A2), one developed glenoid loosening; this was found in four of

Table IV. Clinical outcomes in the 43 shoulders that did not require revision at a mean follow-up of 10.3 years

	Preoperative	Postoperative	p-value*
Mean Constant score (SD)	28 (12)	64 (18)	< 0.001
Mean adjusted Constant score, % (SD)	33 (14)	82 (24)	< 0.001
Active elevation, ° (SD)	84 (25)	128 (37)	< 0.001
External rotation, ° (SD)	8 (9)	34 (23)	< 0.001
Mean Visual Analogue Scale (SD)	7 (2)	3 (3)	< 0.001
Mean Subjective Shoulder Value, % (SD)	33 (23)	70 (26)	< 0.001

* Wilcoxon paired t-test

Table V. Clinical outcomes in patients who did not require revision according to the type of component. The metal-backed group was too small for a statistical comparison to be performed

	All-PE glenoid (n = 36)	MB glenoid (n = 7)
Mean follow-up, years (SD)	10 (2)	11 (1)
Mean Constant score (SD)	64 (17)	64 (24)
Mean adjusted Constant score, % (SD)	82 (22)	84 (32)
Active elevation, ° (SD)	128 (36)	129 (48)
External rotation, ° (SD)	35 (23)	29 (21)
Mean Visual Analogue Scale (SD)	3 (3)	4 (3)
Mean Subjective Shoulder Value, % (SD)	69 (23)	71 (34)

13 in the type B glenoid group. A type-B glenoid preoperatively was significantly associated with an increased rate of glenoid loosening ($p < 0.01$).

Clinical and radiological outcomes in patients free of revision. At the time of final review at a mean of 10.3 years (SD 26), function was analyzed in 43 shoulders that had not required revision: 36 in the polyethylene group and seven in the metal-backed group. The scores were significantly improved compared with the preoperative scores (Tables IV and V). A statistical comparison between the groups was not possible as the metal-backed group was too small.

Periprosthetic radiolucency of < 1 mm was present on the immediate postoperative radiographs in 19 components (41%) in the polyethylene group. At the time of the final review, 32 polyethylene components (89%) and one metal-backed component (14%) had a radiolucency. This appeared on the inferior aspect of the polyethylene components.

Discussion

We report the survival, complications and long-term outcome of aTSA when used in patients aged < 60 years with primary glenohumeral OA. We were able to confirm our hypotheses that both cemented and cementless glenoid components in aTSA are at risk of failure in these patients at this time. The survival of metal-backed glenoid components declines rapidly with time and is significantly inferior to that of polyethylene components. The rate of revision is more than three times higher in metal-backed components, 12 years postoperatively. The overall revision-free rate of survival of an aTSA, ten years postoperatively, was 65%.

These results corroborate those previously reported in smaller series.^{26,27} Sperling et al⁸ reported a rate of survival of 84% for aTSA at 13 years in 29 patients, aged < 50

years. Denard and Walch,²⁸ using revision surgery for glenoid loosening as the endpoint, reported a rate of survival of 62.5% at ten years in 52 patients aged < 55 years. It has been suggested that higher levels of activity may explain, in part, the shorter survival in young adults.²⁹

The choice of glenoid component is critical to the longevity of aTSA in young patients. We found that the rates of survival for polyethylene and metal-backed components were 70% and 22%, respectively, 12 years postoperatively. Similar findings have been previously reported.³⁰ Fox et al³¹ found a rate of survival of 67% for metal-backed components compared with 92% for polyethylene components at 15 years. In a historical cohort from between 1976 and 2008, Singh et al, from the Mayo Clinic³ found a significant difference between the two different modes of fixation in univariate analysis. However, the difference was no longer significant in multivariate analysis.³ Many factors have been suggested to explain the difference: the thickness of metal-backed components, which was 7 mm compared with 5 mm in our series, increases the risk of soft tissue failure due to over lateralization;^{6,29} the difference in elasticity between polyethylene and metal increases the risk of polyethylene wear,^{32,33} and the difference in modulus of elasticity between metal and bone potentially increases the risk of stress-shielding of the underlying bone.³⁴⁻³⁶

One of the arguments for using a metal-backed component in young patients is that it facilitates exchange of a worn polyethylene insert, or the introduction of a metal sphere to convert an aTSA into a RSA.^{37,38} However, we found that conservation of the metal tray with the introduction of a new insert was not possible because of soft-tissue deficiency, prosthetic instability, glenoid bone loss and erosion, or damage to the tray. Another argument is that this type of component would be easier to revise than

a polyethylene component.³⁸⁻⁴⁰ However, we found that severe osteolysis of the glenoid generated by polyethylene and metallic debris from the metal-backed component resulted in difficult revision surgery, and the frequent need to reconstruct a badly destroyed glenoid with bone graft (Fig. 5).

This study demonstrated that premorbid glenohumeral anatomy is also a critical factor for the longevity of aTSA. Preoperative posterior subluxation of the humeral head with B2-glenoids was associated with shorter survival of a metal-backed component. Some explanations have already been proposed. Recurrent posterior subluxation of the humeral head leads to an eccentric load on the polyethylene and the generation of debris, which has a biological role, promoting osteolysis of the glenoid and loosening.^{6,28,41} Although we did not find the same correlation for polyethylene components, we now prefer to use a RSA in patients with a biconcave or dysplastic glenoid and a subluxed humeral head on preoperative CT scans.^{28,42-44}

As shown by Papadonikolakis and Matsen,⁷ the indications for revision of a polythene component are different from those for a metal-backed component. We confirmed that glenoid loosening is the main indication for revision of polyethylene components, whereas polyethylene wear and soft-tissue problems are the main indications for revision of a metal-backed component. We found that loosening of a polyethylene component was often asymptomatic and well tolerated clinically, probably because of its progressive medialization and tilt.⁴¹ In contrast, loosening of a metal-backed component was poorly tolerated. Our interpretation of this is that the initial fixation of a metal-backed component is probably better, but that polyethylene wear with associated metal-on-metal contact leads to granuloma formation and severe osteolysis of the glenoid, as well as loosening and migration.⁴²

Limitations of the study include the fact that five surgeons performed the operations without strict criteria to determine when to use a polyethylene or metal-backed component. However, this series reflects the current activity and issues encountered in the daily practice of a shoulder surgeon. A potential bias is that we were unable to evaluate the level of activity postoperatively. It is possible, for instance, that patients having heavier physical demands were more likely to be treated with a metal-backed component. Longer follow-up would probably identify additional patients with a polyethylene component requiring revision. Finally, our conclusions are specific to the polyethylene and metal-backed components that we used.⁴⁵ The polyethylene, however, underwent the same manufacturing process and was sterilized by the same procedure. Despite these limitations, our series is homogeneous with a single diagnosis of primary glenohumeral OA and, to our knowledge, it is the largest cohort of aTSA when used in

young adults and followed for a relatively long time. We were also able to compare two sub-groups of patients with different types of glenoid component, which were initially comparable.

The long-term survival of aTSA in young active patients remains a concern. At mid- to long-term follow up, aTSA has a high risk of failure in patients aged < 60 years. We also confirmed that the choice of glenoid component is critical when considering an aTSA in young patients with OA. The rate of revision was more than three times higher when cementless metal-backed components were used than when cemented polyethylene components were used. Furthermore, preoperative posterior subluxation of the humeral head with a B2-glenoid is associated with shorter survival of metal-backed components.

In conclusion, our data do not support the use of a metal-backed glenoid component when undertaking aTSA in young patients. Until better options are available, aTSA with a polyethylene component is preferable in these patients.

Take home message:

- The choice of the glenoid implant is a critical factor for the longevity of anatomical total shoulder arthroplasty in young patients.
- In young patients, survival of cementless metal-backed glenoid is significantly lower than cemented all-polyethylene implant.
- Preoperative posterior humeral head subluxation with reverted/biconcave glenoid (B- or C-type glenoid) has a negative effect on metal-backed implant survival.

References

1. Padeigimas EM, Maltenfort M, Lazarus MD, et al. Future patient demand for shoulder arthroplasty by younger patients: national projections. *Clin Orthop Relat Res* 2015;473:1860-1867.
2. Raiss P, Aldinger PR, Kasten P, Rickert M, Loew M. Total shoulder replacement in young and middle-aged patients with glenohumeral osteoarthritis. *J Bone Joint Surg [Br]* 2008;90-B:764-769.
3. Singh JA, Sperling JW, Cofield RH. Revision surgery following total shoulder arthroplasty: analysis of 2588 shoulders over three decades (1976 to 2008). *J Bone Joint Surg [Br]* 2011;93-B:1513-1517.
4. Rodosky MW, Bigliani LU. Indications for glenoid resurfacing in shoulder arthroplasty. *J Shoulder Elbow Surg* 1996;5:231-248.
5. Bartelt R, Sperling JW, Schleck CD, Cofield RH. Shoulder arthroplasty in patients aged fifty-five years or younger with osteoarthritis. *J Shoulder Elbow Surg* 2011;20:123-130.
6. Boileau P, Avidor C, Krishnan SG, et al. Cemented polyethylene versus uncemented metal-backed glenoid components in total shoulder arthroplasty: a prospective, double-blind, randomized study. *J Shoulder Elbow Surg* 2002;11:351-359.
7. Papadonikolakis A, Matsen FA III. Metal-backed glenoid components have a higher rate of failure and fail by different modes in comparison with all-polyethylene components: a systematic review. *J Bone Joint Surg [Am]* 2014;96-A:1041-1047.
8. Sperling JW, Cofield RH, Rowland CM. Minimum fifteen-year follow-up of Neer hemiarthroplasty and total shoulder arthroplasty in patients aged fifty years or younger. *J Shoulder Elbow Surg* 2004;13:604-613.
9. Swarup I, Henn CM, Nguyen JT, et al. Effect of pre-operative expectations on the outcomes following total shoulder arthroplasty. *Bone Joint J* 2017;99-B:1190-1196.
10. Carroll RM, Izquierdo R, Vazquez M, et al. Conversion of painful hemiarthroplasty to total shoulder arthroplasty: long-term results. *J Shoulder Elbow Surg* 2004;13:599-603.
11. Sowa B, Bochenek M, Bülhoff M, et al. The medium- and long-term outcome of total shoulder arthroplasty for primary glenohumeral osteoarthritis in middle-aged patients. *Bone Joint J* 2017;99-B:939-943.

12. **Edwards TB, Kadakia NR, Boulahia A, et al.** A comparison of hemiarthroplasty and total shoulder arthroplasty in the treatment of primary glenohumeral osteoarthritis: results of a multicenter study. *J Shoulder Elbow Surg* 2003;12:207–213.
13. **Bryant D, Litchfield R, Sandow M, et al.** A comparison of pain, strength, range of motion, and functional outcomes after hemiarthroplasty and total shoulder arthroplasty in patients with osteoarthritis of the shoulder. A systematic review and meta-analysis. *J Bone Joint Surg [Am]* 2005;87-A:1947–1956.
14. **Gartsman GM, Roddey TS, Hammerman SM.** Shoulder arthroplasty with or without resurfacing of the glenoid in patients who have osteoarthritis. *J Bone Joint Surg [Am]* 2000;82-A:26–34.
15. **Martin SD, Zurakowski D, Thornhill TS.** Uncemented glenoid component in total shoulder arthroplasty. Survivorship and outcomes. *J Bone Joint Surg [Am]* 2005;87-A:1284–1292.
16. **Young A, Walch G, Boileau P, et al.** A multicentre study of the long-term results of using a flat-back polyethylene glenoid component in shoulder replacement for primary osteoarthritis. *J Bone Joint Surg [Br]* 2011;93-B:210–216.
17. **Boileau P, Moineau G, Morin-Salvo N, et al.** Metal-backed glenoid implant with polyethylene insert is not a viable long-term therapeutic option. *J Shoulder Elbow Surg* 2015;24:1534–1543.
18. **Walch G, Badet R, Boulahia A, Khoury A.** Morphologic study of the glenoid in primary glenohumeral osteoarthritis. *J Arthroplasty* 1999;14:756–760.
19. **Werthel J- D, Lonjon G, Jo S, et al.** Long-term outcomes of cemented versus cementless humeral components in arthroplasty of the shoulder: a propensity score-matched analysis. *Bone Joint J* 2017;99-B 666–673.
20. **Boileau P, Walch G.** The three-dimensional geometry of the proximal humerus. *J Bone Joint Surg [Br]* 1997;79-B:857–865.
21. **Green A, Norris TR.** Imaging techniques for glenohumeral arthritis and glenohumeral arthroplasty. *Clin Orthop Relat Res* 1994;307:7–17.
22. **Constant CR, Murley AH.** A clinical method of functional assessment of the shoulder. *Clin Orthop Relat Res* 1987;214:160–164.
23. **Gilbart MK, Gerber C.** Comparison of the subjective shoulder value and the Constant score. *J Shoulder Elbow Surg* 2007;16:717–721.
24. **Molé D, Roche O, Riand N, Levigne C, Walch G.** Cemented glenoid component: results in osteoarthritis and rheumatoid arthritis. In: Walch G, Boileau P, eds. *Shoulder Arthroplasty*. Berlin: Springer-Verlag, 1999;163–171.
25. **Kaplan EL, Meier P.** Nonparametric Estimation from Incomplete Observations. *J Am Stat Assoc* 1958;53:457–481.
26. **Clement ND, Mathur K, Colling R, Stirrat AN.** The metal-backed glenoid component in rheumatoid disease: eight- to fourteen-year follow-up. *J Shoulder Elbow Surg* 2010;19:749–756.
27. **Clement ND, Duckworth AD, Colling RC, Stirrat AN.** An uncemented metal-backed glenoid component in total shoulder arthroplasty for osteoarthritis: factors affecting survival and outcome. *J Orthop Sci* 2013;18:22–28.
28. **Denard PJ, Walch G.** Current concepts in the surgical management of primary glenohumeral arthritis with a biconcave glenoid. *J Shoulder Elbow Surg* 2013;22:1589–1598.
29. **Young AA, Walch G, Pape G, Gohlke F, Favard L.** Secondary rotator cuff dysfunction following total shoulder arthroplasty for primary glenohumeral osteoarthritis: results of a multicenter study with more than five years of follow-up. *J Bone Joint Surg [Am]* 2012;94-A:685–693.
30. **Clitherow HDS, Frampton CMA, Astley TM.** Effect of glenoid cementation on total shoulder arthroplasty for degenerative arthritis of the shoulder: a review of the New Zealand National Joint Registry. *J Shoulder Elbow Surg* 2014;23:775–781.
31. **Fox TJ, Cil A, Sperling JW, et al.** Survival of the glenoid component in shoulder arthroplasty. *J Shoulder Elbow Surg* 2009;18 859–863.
32. **Cofield RH.** Uncemented total shoulder arthroplasty. A review. *Clin Orthop Relat Res* 1994;307:86–93.
33. **Taunton MJ, McIntosh AL, Sperling JW, Cofield RH.** Total shoulder arthroplasty with a metal-backed, bone-ingrowth glenoid component. Medium to long-term results. *J Bone Joint Surg [Am]* 2008;90-A:2180–2188.
34. **Gupta S, van der Helm FCT, van Keulen F.** The possibilities of uncemented glenoid component—a finite element study. *Clin Biomech (Bristol, Avon)* 2004;19:292–302.
35. **Gupta S, van der Helm FCT, van Keulen F.** Stress analysis of cemented glenoid prostheses in total shoulder arthroplasty. *J Biomech* 2004;37:1777–1786.
36. **Pelletier MH, Langdown A, Gillies RM, Sonnabend DH, Walsh WR.** Photoelastic comparison of strains in the underlying glenoid with metal-backed and all-polyethylene implants. *J Shoulder Elbow Surg* 2008;17:779–783.
37. **Castagna A, Delcogliano M, de Caro F, et al.** Conversion of shoulder arthroplasty to reverse implants: clinical and radiological results using a modular system. *Int Orthop* 2013;37:1297–1305.
38. **Katz D, Kany J, Valenti P, et al.** New design of a cementless glenoid component in unconstrained shoulder arthroplasty: a prospective medium-term analysis of 143 cases. *Eur J Orthop Surg Traumatol* 2013;23:27–34.
39. **Rosenberg N, Neumann L, Modi A, Mersich IJ, Wallace AW.** Improvements in survival of the uncemented Nottingham Total Shoulder prosthesis: a prospective comparative study. *BMC Musculoskelet Disord* 2007;8:76.
40. **Kany J, Amouyel T, Flamand O, Katz D, Valenti P.** A convertible shoulder system: is it useful in total shoulder arthroplasty revisions? *Int Orthop* 2015;39:299–304.
41. **Walch G, Young AA, Boileau P, et al.** Patterns of loosening of polyethylene keeled glenoid components after shoulder arthroplasty for primary osteoarthritis: results of a multicenter study with more than five years of follow-up. *J Bone Joint Surg [Am]* 2012;94-A:145–150.
42. **Vuillermin CB, Trump ME, Barwood SA, Hoy GA.** Catastrophic failure of a low profile metal-backed glenoid component after total shoulder arthroplasty. *Int J Shoulder Surg* 2015;9:121–127.
43. **Gauci MO, Boileau P, Baba M, Chaoui J, Walch G.** Patient-specific glenoid guides provide accuracy and reproducibility in total shoulder arthroplasty. *Bone Joint J* 2016;98-B:1080–1085.
44. **Theivendran K, Varghese M, Large R, et al.** Reverse total shoulder arthroplasty using a trabecular metal glenoid base plate: functional and radiological outcomes at two to five years. *Bone Joint J* 2016;98-B:969–975.
45. **Merolla G, Chin P, Sasyniuk TM, Paladini P, Porcellini G.** Total shoulder arthroplasty with a second-generation tantalum trabecular metal-backed glenoid component: Clinical and radiographic outcomes at a mean follow-up of 38 months. *Bone Joint J* 2016;98-B:75–80.

Author contributions:

M. O. Gauci: Data collection, Participating in conceptualizing the study, Revising the manuscript.
 N. Bonneville: Data collection, Participating in conceptualizing the study, Revising the manuscript.
 G. Moineau: Participating in conceptualizing the study, Revising the manuscript.
 M. Baba: Participating in conceptualizing the study, Revising the manuscript.
 G. Walch: Senior surgeon, Data analysis, Participating in conceptualizing the study, Revising the manuscript.
 P. Boileau: Senior surgeon, Data analysis, Participating in conceptualizing the study, Revising the manuscript.

Funding statement:

The author or one or more of the authors have received or will receive benefits for personal or professional use from a commercial party related directly or indirectly to the subject of this article.

Acknowledgements:

The authors acknowledge Luc Favard, MD, Daniel Mole, MD, and Christophe Levigne, MD for their contribution to the data collection.

This is an open-access article distributed under the terms of the Creative Commons Attribution license (CC-BY-NC), which permits unrestricted use, distribution, and reproduction in any medium, but not for commercial gain, provided the original author and source are credited.