



HAL
open science

Rich table but short life: Diffuse idiopathic skeletal hyperostosis in Danish astronomer Tycho Brahe (1546-1601) and its possible consequences

Sacha Kacki, Petr Velemínský, Niels Lynnerup, Sylva Kaupova, Alizé Lacoste Jeanson, Ctibor Povýšil, Martin Horák, Jan Kučera, Kaare Lund Rasmussen, Jaroslav Podliska, et al.

► To cite this version:

Sacha Kacki, Petr Velemínský, Niels Lynnerup, Sylva Kaupova, Alizé Lacoste Jeanson, et al.. Rich table but short life: Diffuse idiopathic skeletal hyperostosis in Danish astronomer Tycho Brahe (1546-1601) and its possible consequences. PLoS ONE, 2018, 13 (4), pp.e0195920. 10.1371/journal.pone.0195920 . hal-02118068

HAL Id: hal-02118068

<https://hal.science/hal-02118068>

Submitted on 21 May 2019

HAL is a multi-disciplinary open access archive for the deposit and dissemination of scientific research documents, whether they are published or not. The documents may come from teaching and research institutions in France or abroad, or from public or private research centers.

L'archive ouverte pluridisciplinaire **HAL**, est destinée au dépôt et à la diffusion de documents scientifiques de niveau recherche, publiés ou non, émanant des établissements d'enseignement et de recherche français ou étrangers, des laboratoires publics ou privés.



Distributed under a Creative Commons Attribution 4.0 International License


RESEARCH ARTICLE

Rich table but short life: Diffuse idiopathic skeletal hyperostosis in Danish astronomer Tycho Brahe (1546-1601) and its possible consequences

Sacha Kacki^{1,2}, Petr Velemínský^{3*}, Niels Lynnerup⁴, Sylva Kaupová³, Alizé Lacoste Jeanson⁵, Ctibor Povýšil⁶, Martin Horák⁷, Jan Kučera⁸, Kaare Lund Rasmussen⁹, Jaroslav Podliska¹⁰, Zdeněk Dragoun¹⁰, Jiří Smolík¹¹, Jens Velle¹², Jaroslav Brůžek^{2,5}

1 Department of Archaeology, Durham University, Durham, United Kingdom, **2** PACEA–UMR 5199, University of Bordeaux, Pessac, France, **3** Department of Anthropology, National Museum, Prague, Czech Republic, **4** Laboratory of Biological Anthropology, Institute of Forensic Medicine, University of Copenhagen, Copenhagen, Denmark, **5** Department of Anthropology and Human Genetics, Faculty of Science, Charles University, Prague, Czech Republic, **6** Institute of Pathology, First Faculty of Medicine, Charles University and General University Hospital in Prague, Prague, Czech Republic, **7** Department of Radiology, Na Homolce Hospital, Prague, Czech Republic, **8** Nuclear Physics Institute of Czech Academy of Sciences, Husinec-Řež, Czech Republic, **9** Institute of Physics, Chemistry and Pharmacy, University of Southern Denmark, Odense, Denmark, **10** Department of Archaeology, National Heritage Institute, Prague, Czech Republic, **11** Institute of Chemical Process Fundamentals of Czech Academy of Sciences, Prague, Czech Republic, **12** Department of Culture and Society—Section for Medieval and Renaissance Archaeology, Aarhus University, Højbjerg, Denmark

* petr_veleminsky@nm.cz



OPEN ACCESS

Citation: Kacki S, Velemínský P, Lynnerup N, Kaupová S, Jeanson AL, Povýšil C, et al. (2018) Rich table but short life: Diffuse idiopathic skeletal hyperostosis in Danish astronomer Tycho Brahe (1546-1601) and its possible consequences. *PLoS ONE* 13(4): e0195920. <https://doi.org/10.1371/journal.pone.0195920>

Editor: Siân E Halcrow, University of Otago, NEW ZEALAND

Received: November 29, 2017

Accepted: April 2, 2018

Published: April 19, 2018

Copyright: © 2018 Kacki et al. This is an open access article distributed under the terms of the [Creative Commons Attribution License](https://creativecommons.org/licenses/by/4.0/), which permits unrestricted use, distribution, and reproduction in any medium, provided the original author and source are credited.

Data Availability Statement: All relevant data are within the paper and its Supporting Information files.

Funding: This work was financially supported by the Ministry of Culture of the Czech Republic, Grant No. DKRV0 2017/18, 2018/17, 2018/18, National Museum, 00023272 to Petr Velemínský and Grantová Agentura, Univerzita Karlova grant 230516 to M.Sc. Alizé Lacoste Jeanson. The funders had no role in study design, data collection

Abstract

The exhumation of Danish astronomer Tycho Brahe (1546–1601) was performed in 2010 to verify speculative views on the cause of his death. Previous analyses of skeletal and hair remains recovered from his grave refuted the presumption that he died from poisoning. These studies also outlined the possibility that he actually died from an acute illness, echoing the rather vague and inaccurate testimony of some historical records. We performed a detailed paleopathological analysis of Tycho Brahe’s skeletal remains, along with a reconstruction of his diet based on carbon and nitrogen stable isotopes analysis and an estimate of his physical status (relative body fat) based on medullar and cortical dimensions of the femoral shaft. The astronomer’s remains exhibit bone changes indicative of diffuse idiopathic skeletal hyperostosis (DISH). The study further allows us to classify him as obese (100% reliability according to our decision tree designed from Danish males), and points out his rich diet (high input of animal protein and/or marine resources) and high social status. Comorbidities of DISH and obesity are reviewed, and their influence on health status is discussed. We further consider some conditions associated with metabolic syndrome as possible causes of Tycho Brahe’s final symptoms (urinary retention, renal failure and coma), including diabetes, alcoholic ketoacidosis and benign prostatic hypertrophy. Although a definite and specific diagnosis cannot be established, our study points to today’s civilization diseases often associated with DISH and metabolic syndrome as the possible cause of death of Tycho Brahe.

and analysis, decision to publish, or preparation of the manuscript.

Competing interests: The authors have declared that no competing interests exist.

Introduction

Danish astronomer Tycho Brahe (1546–1601) is world renowned for his contribution to the foundation of modern observational astronomy, and also the controversy surrounding the circumstances of his death. He was only 54 years old when he died in Prague, on October 24th, 1601, after 11 days of sudden illness. His first symptoms appeared shortly after attending a banquet at the Count of Rosenberg. During this banquet, he had allegedly held his urine longer than was his habit due to etiquette. According to contemporary accounts of his illness, he was thereafter no longer able to urinate. There are three testimonies about the last days of Tycho Brahe—those of Johannes Jessenius, Johannes Kepler, and the young German doctor Johannes Wittich. The first two described symptoms evocative of uremia. Jessenius had reported that “Urine retention and strong pain followed. Bladder inflammation, which—as is usually the case—was immediately accompanied by continuous fever, and from this quite slight delirium arose.” [1] Jessenius’s testimony also mentions that by the 11th day, his delirium had subsided and Brahe regained consciousness, but only for a few hours before he died [2]. Similarly, Kepler wrote that Brahe “endured five days and nights of agony, unable to sleep. Uninterrupted insomnia followed; intestinal fever; and little by little, delirium.” [1,3] Wittich, who was in Prague when Brahe passed away but did not treat the astronomer himself, concluded that a kidney stone was the cause of his anuria [1,3,4]. This third account, which has become the most popular one, claims that Brahe died because of a ruptured bladder [5].

Some alleged that Brahe’s death was not accidental and that the organ failure described in physicians’ accounts were actually the result of poison ingestion. The first of these conspiracy theories was revealed shortly after his death by William Shakespeare in the play *Hamlet* (1603). More recently, scholars argued that the ruptured bladder could be considered indirect evidence for Hg poisoning, which can result in uremia and kidney failure [6,7]. This assertion has been challenged by other researchers, who argue that bladder rupture is a rare and unlikely occurrence [1,3,4].

The uncertainty around the circumstances of Brahe’s death was one of the reasons why the renaissance astronomer was recently exhumed from his final resting place in the Church of Our Lady before Týn in Prague. The opening of his grave and subsequent study of his remains were performed by a Danish–Czech team under the direction of the National Heritage Institute in Prague on November 15th–19th, 2010 [8]. This was actually the second opening of his grave; it was previously opened in 1901 by physician and anthropologist Jindrich Matiegka, with the purpose of proving that his remains were still in the grave [9]. At that time, hair samples from the scalp and beard were obtained. A sizeable part of a large red textile present in the tomb was cut into small pieces and given away as mementos of the day. The original coffin, where the astronomer was buried, was broken and the remains placed into a smaller tin coffin, which was then replaced in the grave. The 2010 reopening led to the rediscovery of this container, which still contained most of the bones of the astronomer. The authenticity of his skeletal remains can be considered as very certain, as the tin coffin was still sealed when extracted in 2010; upon opening, the bones completely matched the 1901 description [9], including facial bones with mummified skin and beard remnants still attached. In addition, its authenticity is supported by the anthropological analysis, which demonstrated that the skeleton was with absolute certainty that of a male individual whose age at death was approximately 50 years [10].

The purpose of the Danish–Czech research team was mainly to collect samples of hair, bones, and teeth to determine concentration of Hg and other chemical elements in the remains and to discuss whether or not Brahe had been poisoned. These investigations revealed that Brahe could have been exposed to small doses of Hg in the last weeks of his life, possibly due to administration of his own *Elixir Tychonis*, which contained Hg [5]. He was however not

administered potentially lethal doses of Hg, neither shortly before his death nor earlier in his life [11]. Analysis of Brahe's bones revealed signs of long-term exposure to abnormal levels of Au, whereas hair analysis suggested recent exposure to Fe, As, Ag, Au, and Hg. Possible sources of exposure may have been related to Brahe's alchemy activities. Concerning Au, exposure to gold cutlery, involvement in gold plating, and use of gold leaf added to wine can also be considered. It is noteworthy that the concentration of Au, Ag, and a few other elements began to decrease 2 months before his death, suggesting a discontinued exposure to these elements [5]. In addition, histomorphometric examination of a sample from the anterior iliac crest was performed and revealed that bone mineralization was within normal limits. This finding excludes the presence of disorders causing abnormal mineralization, such as renal osteodystrophy, nutritional osteomalacia, vitamin D and calcium deficiencies from gastrointestinal malabsorption syndromes, intoxication with certain metals, and phosphate deficiency [5].

The results of the previous studies thus ruled out the hypothesis that Brahe was poisoned with Hg; but they do not reveal the precise circumstances of his death. More generally, nothing is known about Brahe's health during the last years of his life, nor shortly before his death, with the exception of the aforementioned final 11 days [1]. It is noteworthy, however, that previous studies investigated these questions through chemical analysis and histomorphometric examination only, while pathological bone changes that were present on his skeleton were overlooked as a source of potential information. Preliminary paleopathological evaluation showed that Brahe's remains exhibited extensive remodeling in all spinal segments, as well as changes at the ligament and muscle insertions [12]. The etiology of these skeletal changes was, however, not assessed further. The aim of the newly undertaken investigations was therefore to assess Brahe's physical condition and health, based on a multi-proxy, disease-focused approach of his skeletal remains.

In this paper, we present the result of the first comprehensive paleopathological analysis of Tycho Brahe's skeletal remains, providing evidence that the aforementioned bones changes were caused by diffuse idiopathic skeletal hyperostosis (DISH). We further discuss risk factors for the condition related to Brahe's lifestyle (i.e. dietary excesses and obesity), as revealed by reconstruction of his diet based on carbon and nitrogen stable isotopes analysis and an estimate of his physical status (relative body fat) based on medullar and cortical dimensions of his femoral shaft. We also offer a plausible clarification of the circumstances of his death based on new data on his physical condition and health. Although DISH is nowadays a relatively common condition in older males and has been previously reported in archaeological material, the current study is one of the rare to provide multidisciplinary evidence of the possible causes and consequences of this condition, which still deserves more attention in both the medical sciences and paleopathology with respect to its etiology and life-threatening comorbidities. The study of Brahe's remains furthermore contributes to the osteobiography of this famous person, who in many ways was an example of a true "Renaissance" man of nobility.

Material and methods

The bones recovered from the coffin are those of a single and almost complete adult skeleton (Fig 1). A few bone elements are missing, probably due to loss or removal at the time of the 1901 reopening of the grave. The skull is only represented by the facial bones and the lower part of the frontal bone. The mandible is missing, as well as most of the cervical vertebrae (C1, C3–C5). With regards to the post-cranial skeleton, the right radius and bones of the left hand are missing, as well as most intermediate and distal phalanges of the right hand and both feet. The other skeletal elements are present and generally well preserved, with the exception of the bones of the right upper limb that have suffered taphonomic breakage and cortical erosion.

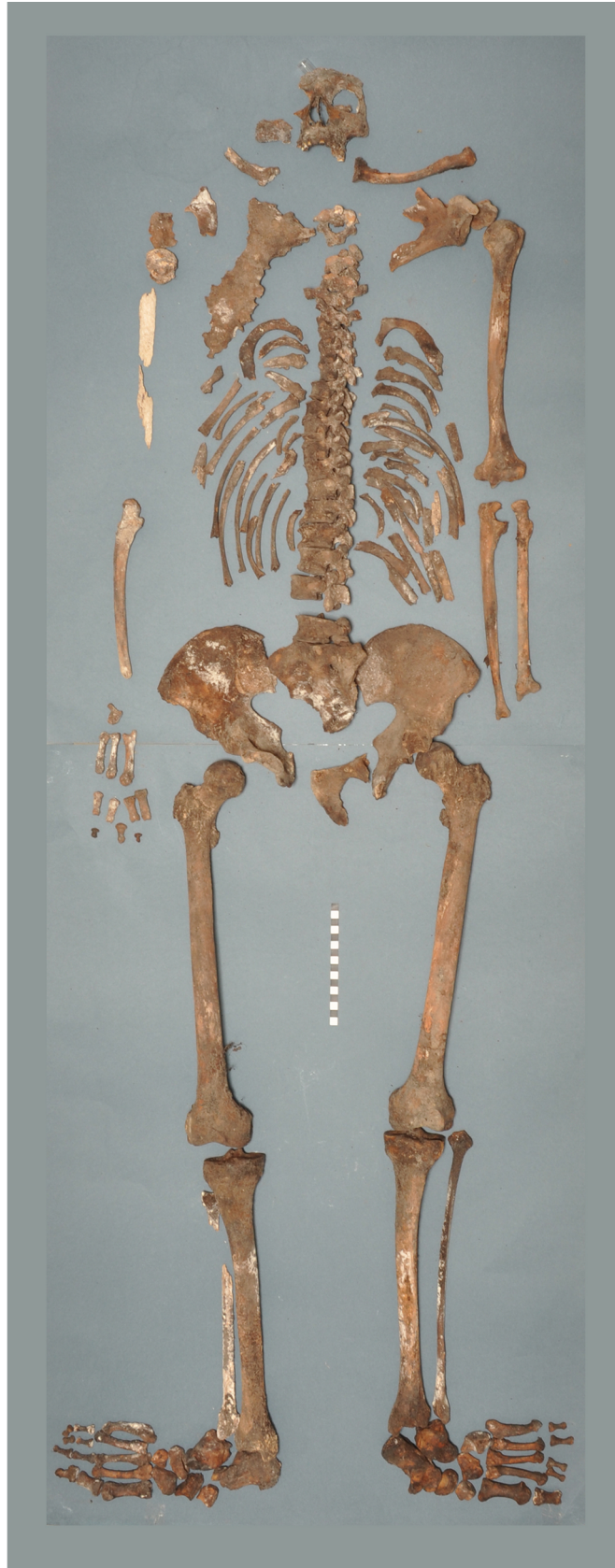

Fig 1. The skeletal remains of Tycho Brahe (Photo Marek Jantač).

<https://doi.org/10.1371/journal.pone.0195920.g001>

Degenerative changes of the spine (spondylosis), osteoarthritic changes at extraspinal sites, and enthesal changes were recorded and described according standard scoring systems developed for paleopathology [13–16]. Macroscopic examination was supplemented by X-ray of each preserved bone, performed at the Department of Anthropology, National Museum in Prague. In addition, all bones were scanned by computed tomography (CT) using a Somatom Sensation 16 (Siemens, Erlangen, Germany) with a slice thickness of 0.4 mm, 0.75 mm increment. CT examination was performed at the Department of Radiology, Hospital Na Homolce in Prague. Surface models were segmented using TIVMI software (<http://projets.pacea.u-bordeaux.fr/TIVMI/>).

Paleopathological assessment of DISH

DISH is a common but often unrecognized systemic disorder characterized by ossification adjacent to the anterior longitudinal ligament in the spinal column and ossification of extraspinal entheses and ligaments [17–19]. Various diagnostic criteria for DISH have been published in the clinical and paleopathological literature (Table 1). Most of them focus on spinal changes and the number of vertebrae that have to be affected, however variable according to the methods. Some authors proposed that the diagnosis of DISH is restricted to the case where calcification and ossification at the site of the anterior longitudinal ligament leads to the complete fusion of the vertebral bodies [20–22]. However, close inspection of cadavers of individuals radiographically diagnosed with DISH reveal areas in which true ankylosis is not present, but rather, irregular osseous outgrowths interdigitate, their undulating surface being separated by thin layers of fibrous tissue [23,24]. Consequently, some authors proposed to consider any flowing ossification confined to the right side of the thoracic vertebrae, with or without fusion, as a diagnostic feature of DISH [17,25,26]. Cases where bony bridges are incomplete have been termed early-stage DISH by some authors [22,27], although to our knowledge no study has demonstrated the relation between degree of bone fusion and disease duration. One of the key features of the spinal manifestations of DISH is that they usually involve only the right side of the thoracic vertebrae, whereas in the lumbar spine both the right and left sides of the vertebral body may be equally involved [23,28]. The unilaterality of changes in the thoracic spine is thought to be due to the left sided descending aorta, whose pulsation may inhibit bone production [29,30].

Besides vertebral changes, diagnostic criteria for DISH may also include calcification or ossification in the extraspinal ligaments and entheses [21,25,26,35]. Enthesal changes and ligament ossification in DISH patients are reported to be particularly common in the pelvis (iliac crest, ischial tuberosity, sacrotuberous, and iliolumbar ligaments), trochanters, calcaneus (Achilles tendon and plantar aponeurosis) and olecranon (triceps brachii) [23,26,36,37]. Moreover, DISH may result in the formation of para-articular osteophytes in the sacroiliac joint that can extend from its margin and even bridge the articulation [23]. A previous paleopathological study showed a significant association between sacroiliac fusion by bridging osteophytes and the presence of DISH [38], so it can be considered as an additional diagnostic feature of the condition.

In the current study, DISH was diagnosed relying primarily on the widely used diagnostic criteria of Resnick and Niwayama [17]. This method is favored since it is one of the most restrictive, both in terms of the number of affected vertebrae and with regards to exclusion criteria. The latter prevents a wrongful diagnosis. Symmetrical enthesal changes at extraspinal

Table 1. Diagnostic criteria for diffuse idiopathic hyperostosis in the clinical and paleopathological literature (modified and completed after [31]).

Criteria	Spinal changes	Extra-spinal changes	Exclusion criteria
Bywaters et al. 1966 [32]	Complete bridge between two vertebral bodies (any level)	Not required	Signs of degenerative disc disease
Julkunen 1971 [20]	Two complete bridges between contiguous or non-contiguous vertebral bodies (thoracic region)	Not required	None
Harris 1974 [33]	Hypertrophic spurs with at least two bony bridges (thoracic region)	Not required	Sacroiliitis; changes evocative of other spinal diseases
Resnick and Niwayama 1976 [17]	Flowing calcification and ossification along the anterolateral aspect of four contiguous vertebral bodies (any level); with or without ankyloses	Not required	Intervertebral disc space narrowing; signs of extensive degenerative disc disease; apophyseal joint ankylosis; sacroiliac joint erosion, sclerosis, or intraarticular osseous fusion
Arlet and Mazières 1985 [34]	Flowing ossification along the anterolateral aspect of three contiguous vertebral bodies (lower thoracic region); with or without ankyloses	Not required	Intervertebral disc space narrowing; signs of extensive degenerative disc disease; apophyseal joint ankylosis; sacroiliac joint erosion, sclerosis, or intraarticular osseous fusion
Utsinger 1985 [21]			
• Definite DISH	Bridging of four contiguous vertebral bodies (thoracolumbar region)	Not required	Signs of degenerative disc disease; apophyseal joint ankylosis
• Probable DISH	Bridging of two vertebral bodies	Bilateral patellar tufting, heel spurring and olecranon tufting	
• Possible DISH	Bridging of two vertebral bodies	Not required	
	Not required	Symmetrical enthesophytes	
Crubézy and Crubézy-Ibáñez 1993 [35]			
• Definite DISH	Bridging of three vertebral bodies (lower thoracic region) / four vertebral bodies (any level)	Not required	Sacroiliac joint erosion, sclerosis, or intraarticular osseous fusion
• Probable DISH	Bridging of two vertebral bodies	Symmetrical enthesopathies (posterior calcanei, olecranons, and upper patellae)	
• Possible DISH	Bridging of two vertebral bodies	Not required	
	Not required	Symmetrical enthesopathies	
Rogers and Waldron 2001 [26]	Hyperostosis affecting three vertebral bodies (thoracic region); with or without ankylosis	Calcification or ossification in ligaments and entheses	None
Kacki and Villotte 2006 [25]			
• Definite DISH	Flowing ossification along the anterolateral aspect of four contiguous vertebral bodies (thoracic region); with or without ankyloses	Not required	Intervertebral disc space narrowing; apophyseal joint ankylosis
• Probable DISH	Flowing ossification along the anterolateral aspect of two contiguous vertebral bodies (thoracic region); with or without ankyloses	Symmetrical enthesal changes (patellar tufting, heel spurring, olecranon tufting)	
Waldron 2008 [22]	Fusion of four contiguous vertebrae (thoracic region)	Ossification into entheses and ligaments	None

<https://doi.org/10.1371/journal.pone.0195920.t001>

sites and bridging para-articular osteophytes in the sacroiliac joint, although not taken as primary criteria in the diagnosis, were considered as additional evidence of the condition.

Stable isotope analysis

For stable isotope analysis, 300 mg of compact bone was sampled from the femoral shaft of Tycho Brahe. For comparative purposes, we also analyzed a similar sample collected from the skeleton of Brahe's wife, Kirsten Jørgensdatter, whose skeletal remains were obtained during

the same exhumation and whose identity was already confirmed by Matiegka [9]. Femurs were preferred for sampling instead of more routinely used bones (i.e. ribs) because skeletal remains of Kirsten Jørgensdatter were found in such a state, that we could not be sure that present rib fragments belonged to her. Due to the distinct turnover rate of different parts of the skeleton [39], the same bone element was needed for sampling to capture the dietary signal of similar life period of both individuals [40].

Collagen extraction proceeded according to the Longin [41] method, modified by Bocherens [42]. Elemental analyses were performed using a Europa Scientific EA elemental analyzer connected to a Europa Scientific 20–20 IRMS for carbon and nitrogen isotope analysis at Iso-Analytical Limited, Crewe (UK). The uncertainty of isotopic measurements calculated on different standard replicates (IA-R042, IA-R038, IA-R046 and IA-R05, IAR06) was less than 0.1‰ (1 SD) for both nitrogen and carbon.

Due to the slow bone turnover rate in the femoral shaft, isotopic values from analyzed samples represent the average dietary signal for a vast period of time, spanning from adolescence through adulthood [43]. According to his biographers, Brahe spent the majority of his adult life in Denmark, arriving in Prague only 2 years before his death when becoming Royal Mathematician at the court-in-exile of the Holy Roman Emperor, Rudolf II; his wife spent 5 years in Prague. Thus, to characterize the dietary behavior of the two individuals, we used comparative datasets for northwestern European contexts. Human and animal isotopic data were taken from datasets from late medieval Denmark [44–46], early modern Belgium [47], and 18th to 20th centuries Copenhagen [48]. An early modern population sample from Prague (15th to 16th centuries merchants and 18th century soldiers [49]) was also included for comparison. The collagen extraction methods applied in these studies differed in several aspect including acid concentrations and duration of demineralization, the demineralization of bone chunks vs. powders, the use of NaOH or ultra-filtration. None of these factors, however, have been shown to have a significant impact on carbon and nitrogen isotopic values of bone collagen in experimental studies [50–53]. Thus, the data are considered to be well comparable.

Physical status estimation based on relative body fat

Researches demonstrated that the methods classically used to estimate body mass from the skeleton are not reliable for estimating individual body mass, nor they are reliable for estimating physical status or body size (i.e. emaciation, physiological or normal body mass, obesity) [54–56]. This is mostly because the data used to create the regressions for estimating body mass consist of average or estimated body masses for population samples or self-recalled body mass at 18 years of age [57–61]; and because the skeletal variables used do not change much after the end of the skeletal maturation and are thus not able to track potential changes in physical status during adulthood [57,61].

However, the femoral diaphysis is more labile and functionally adapts and remodels according to the biomechanical constrains imposed upon it [57,62,63]. Therefore, we built a decision tree based upon femoral bone data from a Danish sample of 36 males with known mass and body composition to estimate Brahe's physical status. The sample is part of a randomly constituted dataset of whole-body computed tomography (CT) scans performed on cadavers at the University of Copenhagen, Department of Forensic Medicine, Unit of Forensic Anthropology in Copenhagen, Denmark (described in [64]). No formal ethical consent is needed from Danish ethical committees to work with CT images of deceased humans. Autopsies are mandated by the police and CT scans are part of the routine investigation at the University of Copenhagen, Department of Forensic Medicine. The Department of Forensic Medicine adheres to Danish accreditation standards regarding data security. All personal data

are removed from the images; only age, sex, weight and height data were retained. Bodies were scanned within 3 days after death and exhibited very limited or no sign of decomposition. Age was recorded and bodies were weighed on an electronic scale with clothes removed prior to autopsy.

Body mass index is a common way of measuring physical status, but it does not measure fatness, and can therefore only serve as an approximate indication of obesity or emaciation, which are the result of an excess or a defect, respectively, of adipose tissue [65]. Therefore, we chose to use a more conservative definition of obesity based on body composition. At the tissue level, the body can be divided between fat mass (FM) and fat-free mass (FFM, i.e. the sum of muscles, organs and bone). FM and FFM were derived from the assessment of adipose, lean and skeletal tissue volumes on CT scans and known density of the founder (0.92 kg per liter), from which derived mass was subtracted from known weight (described in [64]). Body fat proportion (BF%) was calculated as $FM/(FM+FFM) \times 100$. Obesity is defined at the threshold of greater than or equal to 25 BF% for males [65]. The sample is composed of eight individuals of normal weight and 28 who were considered obese.

Decision trees were generated from the classification and regression tree (CART algorithm) [66]. Decision trees are devices used by investigators to determine the most discriminant variables with regard to categorical variables. Essentially, decision trees indicate which bone variables are decisive for classifying individuals into normal or obese categories. The number of terminal leaves in the decision trees is determined by minimizing the error of prediction using a leave-one-out cross-validation.

Only the left femora were used for analysis. To check for the assumption regarding the limited power of femoral external dimensions for estimating physical status, we measured the neck breadth, head supero-inferior breadth, head antero-posterior breadth, bicondylar breadth, and included all those dimensions into the variables that the tree could select for distinguishing between obese and normal categories. Additionally, precise data of the femoral diaphyseal bone were extracted using custom-built software that automatically reslices the bone to align it along the medial axis [67]: cortical, medullary, and total areas of cross-sections located at 20%, 35%, 50%, 65% and 80% of the femoral maximum length were recorded, as well as medio-lateral (ML) and antero-posterior subperiosteal and medullary diameters of the same cross-sections. All data were adjusted by maximum femoral length to minimize the effect of stature variation on the results. The most discriminant skeletal variables identified by the tree for classifying individuals between categories of physical status were then measured on a CT scan of Brahe's left femur, from which data were extracted following the same procedure.

Results

Description and diagnosis of pathological changes

The preserved skeletal remains show several pathological lesions, primarily concentrated in the vertebral column and, to a lesser extent, in the peripheral entheses (S1, S2 and S3 Tables). A detailed description of each of the pathological changes is provided below.

The cervical spine did not show pathological changes, except from slight osteophytosis on the anterior border of the lower plate of C7. On the contrary, the thoracic vertebrae exhibited major pathological changes in the form of massive bone formation on the vertebral bodies. All but the T1 and T2 vertebrae were affected. T3 and T4 were fused together by a bony bridge located on the left side and a forming bony bridge was present on the contralateral side. The section of the spine situated below (i.e. T5–T10) exhibited flowing ossifications restricted to the right side of the vertebral bodies, at the site of the anterior longitudinal ligament (Fig 2). These dense bony outgrowths projecting upward or downward were unfused but in contact

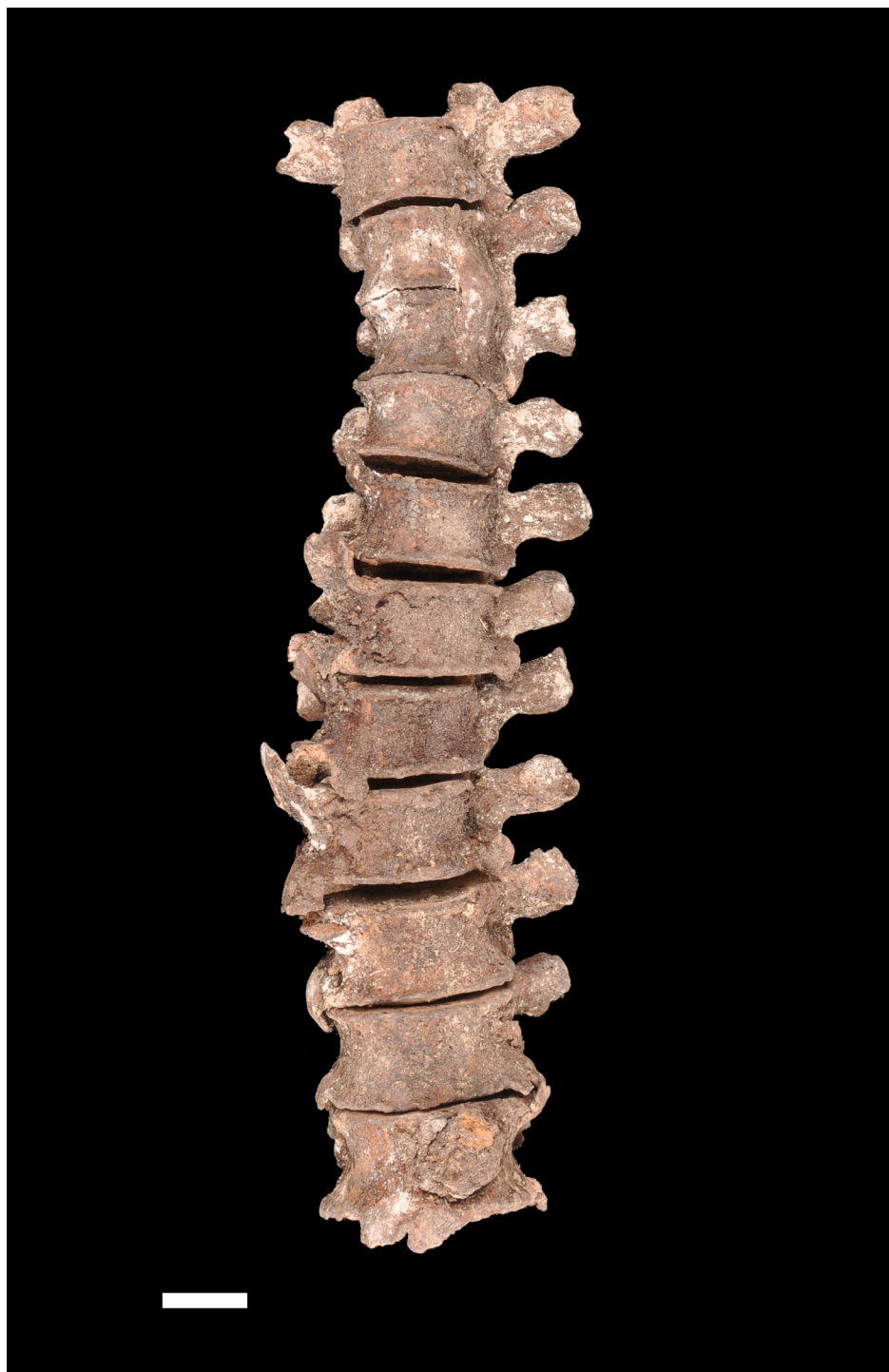

Fig 2. Anterior view of the thoracic spine (T2-T12). A flowing ossification is present along the right side of the vertebrae. Also note the left sided bony bridge that leads to fusion of T3 and T4. Scale: 2 cm (Photo Marek Jantač).

<https://doi.org/10.1371/journal.pone.0195920.g002>

and interdigitating. T11 and T12 were less severely affected, showing small bridging enthesophytes on both their right and left aspects. X-ray examination of the thoracic spine revealed that the bone formations had a dense cortex and coated the vertebral bodies without

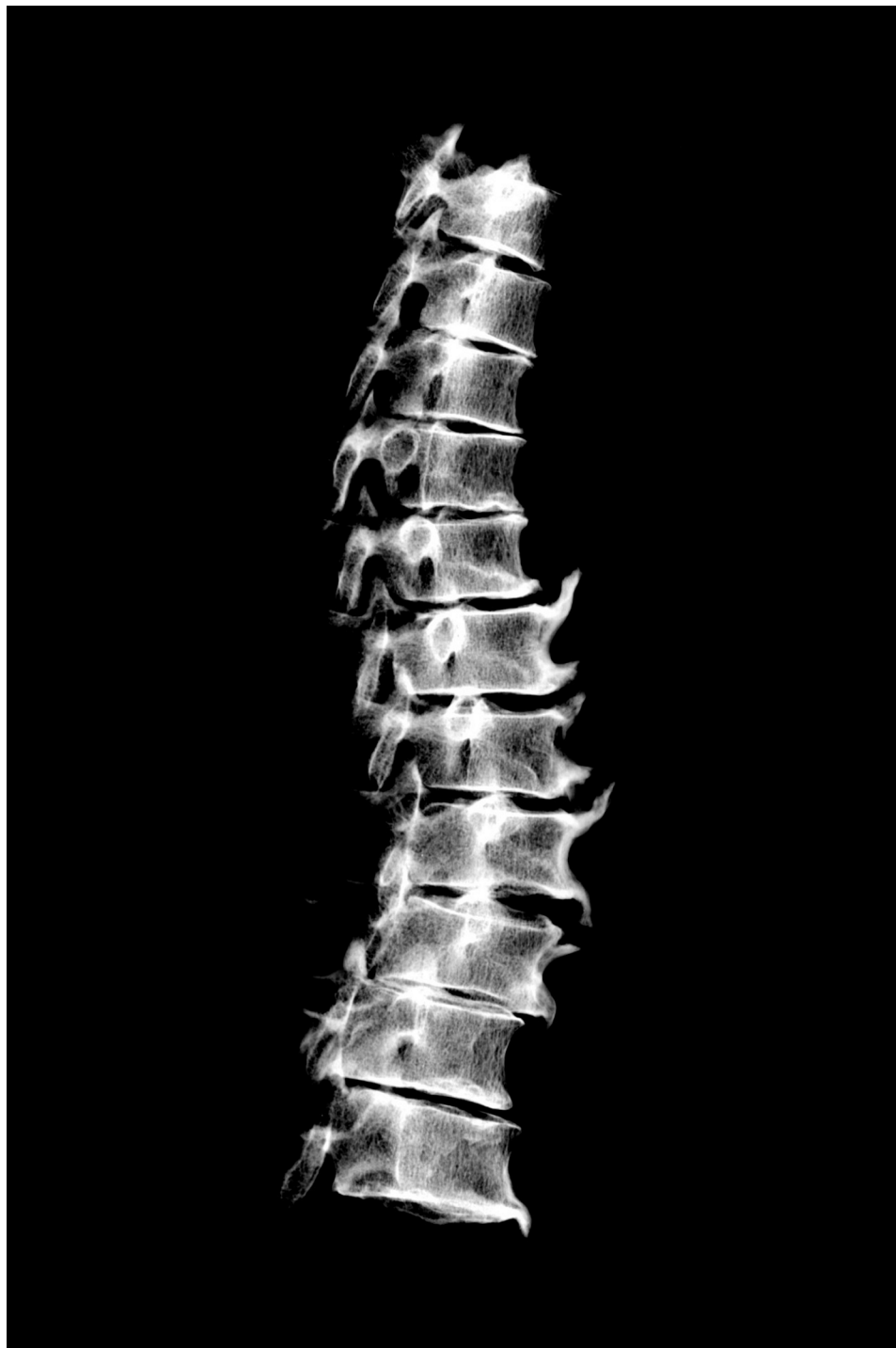

Fig 3. Radiograph of the T2–T12 thoracic vertebrae (*norma lateralis*). Note the ossification at the site of the anterior longitudinal ligament that coats the vertebral bodies.

<https://doi.org/10.1371/journal.pone.0195920.g003>

destruction of the normal, underlying cortical bone (Fig 3). No obvious changes in the trabecular organization of the vertebral bodies were apparent. Similar candle-flame-shaped ossifications were present bilaterally on the L1 and L2 vertebrae, extending down to L3 on the left

side. The last two lumbar vertebrae and the sacrum were unaffected by any pathologic lesion. Along the spine, the intervertebral spaces appeared to be preserved and no pathological changes were observed in the apophyseal joints either on macroscopic and radiologic examination.

Both hip bones showed some degree of hyperostosis at the attachment sites of ligaments, particularly those of the inguinal ligament (anterior superior iliac spine), iliolumbar ligament (posterior part of the inner lip of the iliac crest), iliofemoral ligament (anterior inferior iliac spine), and sacrotuberous ligament (medial margin of the ischial tuberosity). Marked exostoses were present on the posterior aspect of the iliac crests and both ischial tuberosities are grossly remodeled, showing an irregular surface with osseous production and foramina. On the right hip bone, small bony spurs had developed from the border of the superior and inferior pubic rami, projecting in the obturator foramen.

The right innominate also showed thick, smooth exostosis lying at the apex of the auricular surface (Fig 4). This bony outgrowth had been broken post-mortem but initially united the hip bone with the sacrum, as demonstrated by fitting surfaces with the remaining bone bridge at the sacrum. The sacroiliac fusion resulted from sacral ligaments ossification only, without intra-articular involvement. The synovial part of the auricular surface showed no pathological

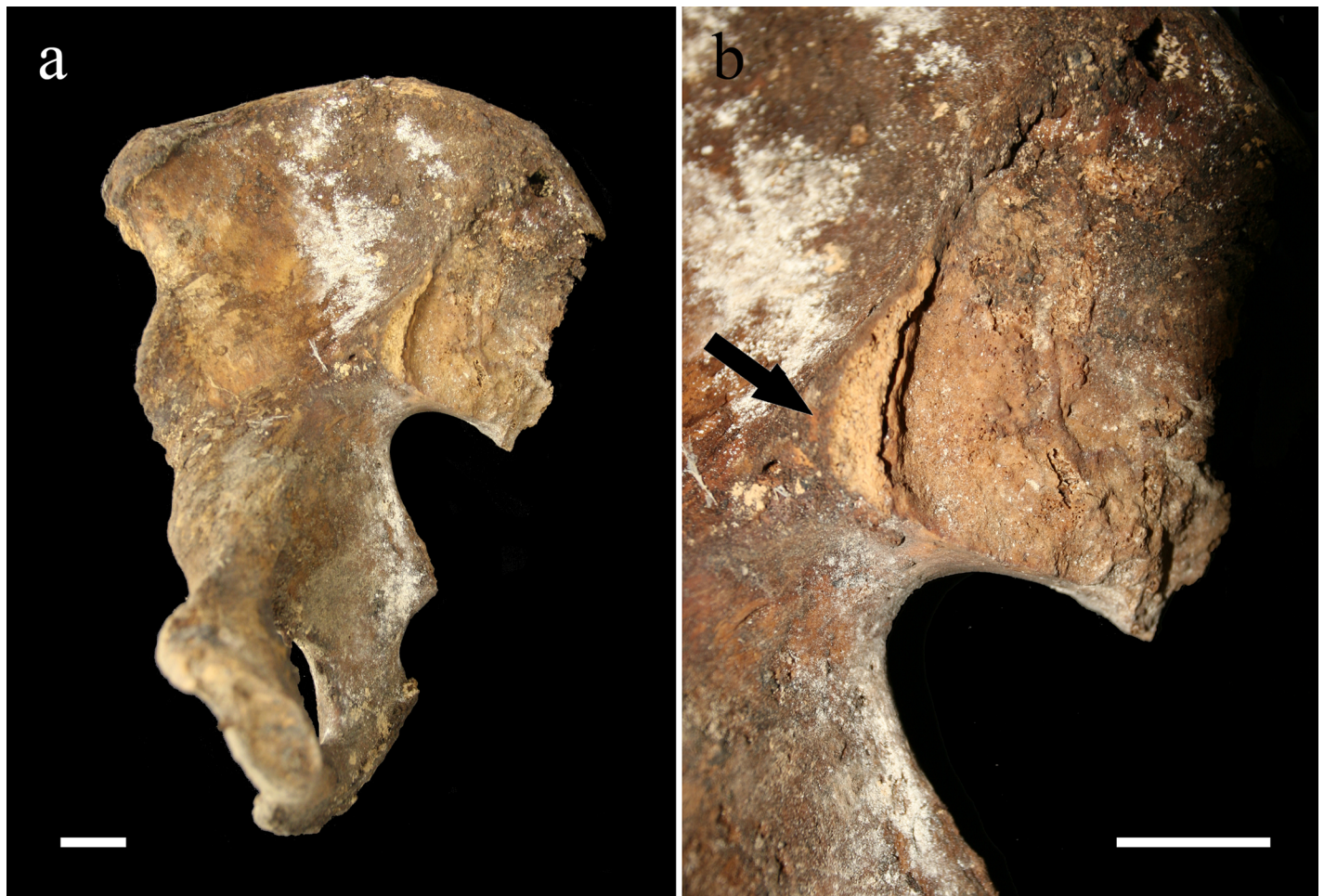

Fig 4. The right innominate (a) and close-up view of its sacroiliac region (b). The pictures show the broken bony bridge (arrow) that connected the hip bone to the sacrum. Scale: 2 cm (Photo Marek Jantač).

<https://doi.org/10.1371/journal.pone.0195920.g004>

changes except from surface remodeling due to aging, similar to what was observed at the left hip bone.

Only a few pathological changes were present in the upper limb bones. The sternal ends of both clavicles showed articular lesions evocative of osteoarthritis, i.e. marginal lipping (osteophytosis) and pitting on the joint surface. Slight osteophytosis was also present on the inferior margin of the left glenoid fossa. Apart from that, the only other bone modification observed was a large bony spur at the attachment site of the triceps brachii muscle on the left ulna. The contralateral bone was heavily damaged, making it impossible to assess whether or not it was also affected.

Entheseal changes were present bilaterally in the lower limb bones, especially in the femora, tibiae, and calcanei. The femora showed enthesophytes on the greater and lesser trochanters (attachment sites of the gluteus minimus and gluteus medius, and of the iliopsoas muscle, respectively), as well as bony spurs in the trochanteric fossa (insertion of the external obturator muscle) and formation of an irregular bony crest at the attachment site of the gluteus maximus muscle on the posterior shaft. A large bony crest was also apparent in the posterior aspect of both tibiae at the insertion of the soleus muscle. The right and left calcanei exhibited enthesophytes at the insertion of the Achilles tendon, as well as heel spurs that developed on the plantar aspect of the bones (Fig 5). The other foot bones (tarsal, metatarsal, and phalanges) only showed slight osteoarthritic changes.

Systematic X-ray examination of the bones did not reveal pathological changes, other than those identified through macroscopic examination.

Although hyperostotic lesions of the spine and the appendicular skeleton of Tycho Brahe may have resulted from various causes, in the current case their distribution throughout the skeleton and their anatomic features ruled out most of the possible diagnosis. Degenerative processes alone appear as an unlikely cause of recorded bone changes, notably those of the spine. In degenerative joint disease, osteophytes arise from the margins of the vertebral bodies and are horizontally oriented [23,68,69], in contrast to the massive, vertical bony outgrowths recorded here, which encroach on the lateral borders of the vertebral bodies. Moreover, bone fusions, such as those affecting the T3–T4 vertebrae and the right sacroiliac joint are an uncommon feature in degenerative joint disease, except in very old individuals [23,70]. The spondyloarthropathies (SpA), a group of inflammatory rheumatic disorders that share common genetic predisposing factors and clinical features, may cause vertebral and sacroiliac fusion, as well as extraspinous enthesitis [23,71–73]. However, these diseases generally involve both the vertebral bodies and the apophyseal joints, and the intervertebral space is not preserved [23,74]. Furthermore, in SpA sacroiliac ankylosis is due to synovial inflammation resulting in intra-articular destruction and fusion [75,76] and the enthesal changes are mainly osteolytic [77,78]. Here, the absence of zygapophyseal lesions, signs of sacroiliitis, or erosive lesions of entheses dismissed SpA as a possible diagnosis. Other rare causes of osseous outgrowths of the spine such as acromegaly, hypoparathyroidism, fluorosis, ochronosis, and sternoclavicular hyperostosis can also be ruled out, in the absence of evocative signs of those diseases elsewhere in the skeleton.

DISH is conversely a likely diagnosis of bone changes with regards to their anatomic features and their distribution in the skeleton. The presence of interdigitated exostoses in six adjacent thoracic vertebrae (not counting the T3–T4 ankylosis) in the absence of apophyseal joint ankyloses, sacroiliitis, and signs of degenerative disc disease fulfills Resnick and Niwayama's diagnostic criteria for the disease [17]. The diagnosis is reinforced by the right sided predominance of the flowing ossification in the thoracic spine. In this respect, it is noteworthy that the bone bridge uniting the left lateral aspect of T3 and T4 is located superior to the aorta, which runs from the lower border of T4 to the lower border of T12. The diagnosis of DISH in Brahe's




Fig 5. Macroscopic (a) and radiologic (b) aspects of the right calcaneus (medial view). Note the presence of the enthesophyte at the insertion of the triceps sural muscle (white arrows) and the heel spur on the plantar surface (grey arrows). Scale: 2 cm (Photo Marek Jantač).

<https://doi.org/10.1371/journal.pone.0195920.g005>

skeletal remains is also supported by the presence of symmetrical distributed ossification in entheses and ligaments that are reported to be frequently affected in patients with the condition, i.e. lesions in the pelvis (iliac crest, ischial tuberosity, sacrotuberous, and iliolumbar ligaments), trochanters, calcaneus (Achilles tendon and plantar aponeurosis), and olecranon (triceps brachii). Considering these extraspinal changes along with the spinal ones, the

diagnosis of DISH is confirmed using most sets of criteria used for paleopathological diagnosis of the disease (Table 1). Finally, the presence of sacroiliac ankylosis by a thick, smooth exostosis bridging between the apex of auricular surface of the ilium and the upper aspect of the sacral wing is also consistent with the diagnosis of DISH [23,38].

Reconstruction of diet from stable isotope analysis

For Tycho Brahe, the $\delta^{13}\text{C}$ was -19.0‰ and $\delta^{15}\text{N}$ was 14.7‰ . For his wife Kirsten, $\delta^{13}\text{C}$ was -19.4‰ and $\delta^{15}\text{N}$ was 13.4‰ . Due to the slow bone turnover rate in the femoral shaft, it is improbable that Tycho Brahe's isotopic values could be influenced significantly by any of the pathological conditions he suffered during the final period of his life [79]. Moreover, a study has shown that DISH is not among the pathological conditions that have an effect on the isotopic composition of bones [47]. There is no evidence that Kirsten suffered from a long-term chronic disease that could have influenced the results. The numeric values obtained can thus be considered as reliable and interpreted in terms of dietary habits.

Animal data taken from comparison datasets suggest some variation in carbon isotopic values according to geographic areas, with the Prague sample being slightly enriched in $\delta^{13}\text{C}$ compared to northwestern European contexts (Fig 6). Nitrogen isotopic values were similar between both contexts (with the exception of the modern Copenhagen sample, which shows slightly higher values), which makes them comparable, at least in terms of animal protein consumption. The human data of northwestern European medieval and early modern populations are usually interpreted as a reflection of a terrestrial based diet with a measurable input of marine protein [45–47]. However, much higher carbon isotopic values were observed in Danish populations from previous periods, who substantially relied on marine protein [80,81], so freshwater or anadromous origin of at least a part of consumed aquatic protein cannot be excluded [44,48]. Interestingly, Prague merchants show similar isotopic values [49], though the lower human-faunal carbon isotopic offsets make the freshwater origin of the aquatic protein more probable. The socioeconomic gradient in diet has been commonly observed, showing a higher amount of animal and/or aquatic protein in the diet of elites and urban populations. This is usually explained by the higher pressure on elite households to follow fasting prescriptions. Thus, the consumption of fish appears to be a marker of the pertinence to the upper class in the late medieval and early modern period [44–49].

In this light, the diet of both sampled individuals has a rather prestigious character with a high input of animal protein and/or aquatic resources (Fig 6). Their skeletal $\delta^{13}\text{C}$ are greater than 2‰ above the animal baseline. As the trophic level shift for carbon is around 1‰, this indicates a marine fish component in their diet [83]. However, as stated above, a freshwater component of the diet cannot be excluded. While Kirsten Jørgensdatter's nitrogen isotopic value and human-faunal offset is located within the mean + 1 SD range of the late medieval center of Ribe [45] and 19th–20th century Copenhagen [48], Tycho Brahe's $\delta^{15}\text{N}$ and human-faunal offset is markedly above this range (Table 2). In fact, his nitrogen isotopic value is located at or even above the upper range of the observed variability of all studied datasets. The isotopic values of both individuals are comparable to those of the highest European elites and royal families of that time [84–86]. The isotopic difference between both individuals (0.5 for $\delta^{13}\text{C}$ and 1.3 for $\delta^{15}\text{N}$) is slightly higher than in other identified couples [84,85], suggesting a higher input of animal (probably marine) protein into Tycho Brahe's diet.

Notably, before coming to Prague, Brahe had his manor and astronomic observatory on the island of Hven, between Denmark and Sweden, a place where marine foodstuffs were probably abundant. As a member of the elite classes, he could have access to the broad spectra of fish, including more expensive freshwater species such as pike [87,88]. Consumption of such fish,

Table 2. Bone collagen $\delta^{13}\text{C}$ and $\delta^{15}\text{N}$ and human-faunal offsets of the studied individuals and comparative datasets (mean \pm 1 SD).

Individual/region	Time period	Context	N	Bone sampled	$\delta^{13}\text{C}$	$\delta^{15}\text{N}$	$\Delta^{13}\text{C}_{\text{human-fauna}^a}$	$\Delta^{15}\text{N}_{\text{human-fauna}^a}$	Reference
Tycho Brahe	1546–1601	–	–	femur	–19.0	14.7	2.6 ^b	8.2 ^b	This study
Kirsten Jørgensdatter	1549–1604	–	–	femur	–19.4	13.4	2.2 ^b	6.9 ^b	This study
Denmark	12 th –16 th century AD	elites	29	tibia, femur, humerus	–19.4 \pm 0.5	12.5 \pm 0.9	2.2	6.0	[46]
Denmark	12 th –16 th century AD	peasants	55	tibia, femur, humerus	–19.9 \pm 0.4	11.6 \pm 0.8	1.7	5.1	[46]
Denmark	12 th –16 th century AD	urban (small center)	45	tibia, femur, humerus	–19.2 \pm 0.4	12.4 \pm 0.7	2.4	5.9	[45]
Denmark	13 th –15 th century AD	urban (large center)	54	tibia, femur, humerus	–19.2 \pm 0.5	12.9 \pm 0.9	2.4	6.4	[45]
Denmark	12 th –16 th century AD	peasants	69	rib	–19.3 \pm 0.6	11.9 \pm 0.7	2.3 ^b	5.4 ^b	[44]
Czech lands	15 th –16 th century AD	urban	12	femur	–19.6 \pm 0.4	12.2 \pm 0.9	1.3 ^c	5.6 ^c	[49]
Czech lands	18 th century AD	soldiers	19	femur	–19.8 \pm 0.6	9.7 \pm 1.1	1.1	3.1	[49]
Belgium	16 th –18 th century AD	elites	17	rib, long bones	–19.5 \pm 0.5	12.0 \pm 0.8	2.1	4.7	[47]
Belgium	16 th –18 th century AD	non-elites	12	rib, long bones	–19.9 \pm 0.4	11.5 \pm 0.9	1.7	4.2	[47]
Denmark	19 th –20 th century AD	urban middle and higher classes	111	phalanx (hand or foot)	–19.2 \pm 0.5	13.2 \pm 0.5	2.3	5.6	[48]
Spain	14 th century AD	royal family	4	rib, metatarsal	–18.6 \pm 0.4	12.5 \pm 0.6	0.6–2.6 ^d	6.1–7.9 ^d	[85]
England	15 th century AD	Richard III	1	rib	–18.7	14.9	2.6	7.7	[86]

^a As faunal data, the mean values of the main consumed domesticated species from the corresponding animal sample (cattle, sheep/goat, pig) were used.

^b Animal data published by Yoder [46] were used for comparison.

^c Animal data of the Czech medieval sample published by Frolík and Kaupová [82] were used for comparison.

^d Jiménez-Brobeil et al. [85] published only the mean data for particular species, due to the absence of original data, the presented interval indicates differences between species.

<https://doi.org/10.1371/journal.pone.0195920.t002>

as well other delicacies of the privileged people including high quality meat of young animals (e.g. lamb, veal) [89] or wildfowl (e.g. swans, herons, pheasants), could have contributed to the observed high $\delta^{15}\text{N}$ of both individuals. However, it is not possible to distinguish the contribution of these dietary items from present isotopic values.

Estimation of physical status from the femoral diaphysis

The decision tree generated from a Danish sample of 36 males determined that the most discriminant variables for classifying the whole sample between normal and obese categories were adjusted medullary ML breadths at 50%, 65%, and 80% of the maximum femoral length (MFL), and adjusted total area at 65% of the MFL (Fig 7; S4 and S5 Tables). The tree distinguishes almost perfectly the entire sample between normal or obese categories: 89% of the obese males have an adjusted medullary ML diameter at 50% of MFL that is smaller than 0.034 (leaf #3). When this is associated with a total area larger than 1.4, all individuals with obesity are distinguished from those with a normal BF% (leaf #7). Among individuals with an adjusted medullary ML diameter at 50% of MFL larger than 0.034 (leaf #2), those who have an associated medullary ML diameter at 65% larger than 0.036 are obese (leaf #5).

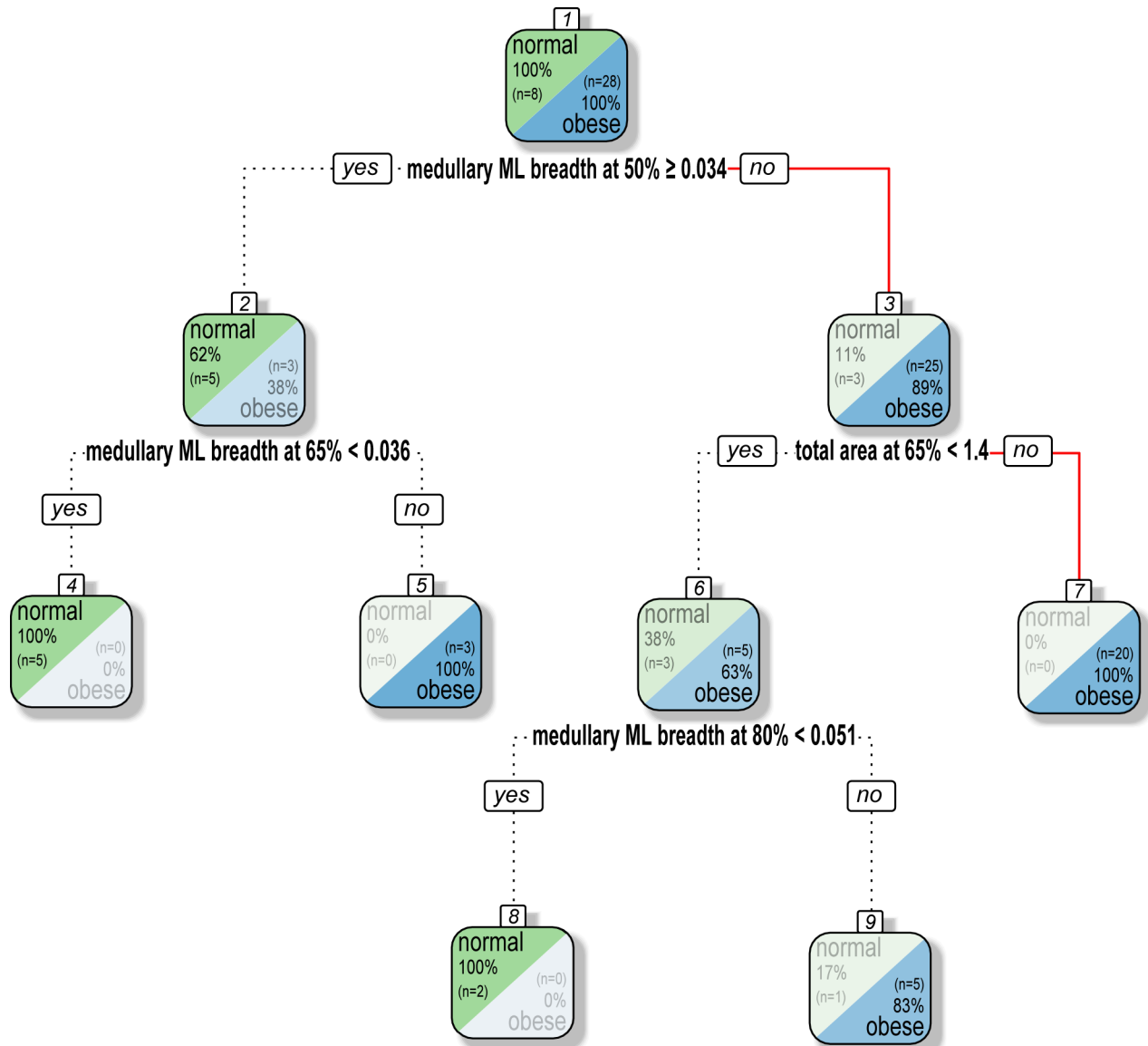


Fig 7. Decision tree to distinguish normal and obese categories based on body fat (BF)% data. Tycho Brahe’s classification path is identified by a plain red line. All data are adjusted according to maximum femoral length.

<https://doi.org/10.1371/journal.pone.0195920.g007>

Tycho Brahe has a ML diameter at MFL 50% of 0.031 with an associated adjusted total area of 1.5 on the slice located at 65% of MFL. He therefore falls into the leaves 3 and 7 (Fig 7) and is classified as obese with 100% reliability according to the data of the tested sample. Although the small sample size of the reference sample must be acknowledged (n = 36), the results strongly support the hypothesis that Brahe was overweight in the last years of his life.

Discussion

Our contribution provides conclusive evidence that Tycho Brahe suffered from DISH, a systemic disorder characterized by bone proliferation at spinal and extraspinal sites of the ligament and tendon attachments to bone. Moreover, isotope analysis of his skeletal remains shows that the famous astronomer had a rich diet with high protein intake. His physical status

estimation suggests that he also suffered from obesity. Hereafter, we review the risk factors associated with DISH and discuss its relationship with lifestyle and its possible impact on his physical condition, health, and premature death.

Epidemiology and biosocial determinants of DISH

Diffuse idiopathic skeletal hyperostosis, formerly referred to as Forestier's disease, was first comprehensively described by Forestier and Rotes-Querol in 1950 [90]. Since then, the condition has been the focus of many epidemiological studies, which revealed its distribution among various contemporary populations around the world. Regardless of the population considered, the disease has been shown to strongly correlate with age: it is an unusual finding in individuals under 40 years, and its prevalence increases markedly with advancing age [20,21,91]. It is also well recognized that DISH is more common in men, with a male/female ratio ranging from 1.5:1 to 2:1 in most clinical studies [91–94]. The prevalence of the condition also shows significant ethnic and geographic variation. In the over 50 years, it has been shown to range from 2.9% in the Korean population [95] to over 10% in some Caucasian populations (e.g. [94,96]). Higher prevalence rates have occasionally been reported, for example for two large Midwest populations of the United States where 25% of males and 15% of females over 50 years had DISH, and up to 35% of males and 26% of females over 70 years [97]. In the Old World, DISH is considered by some scholars to be more frequent in Northern European people [98]. For example, the condition has been reported to be common in the Finnish population, with 3.8% of males and 2.6% of females over 40 years being affected, and as many as 10.1% of males and 6.7% of females over 70 years [91]. It is noteworthy, however, that the prevalence of DISH is also high in some populations from central Europe, such as in Hungary, where prevalence rates of 27.3% and 12.8% have been reported for males and females over 50 years, respectively [96].

The prevalence of DISH in past populations is not as well ascertained as in modern times, and it has probably been underestimated during the last decades due to misdiagnosis of many cases as ankylosing spondylitis [99]. Since the pioneering studies of Rogers and colleagues in the 1980s [68,99,100], the disease has increasingly been recognized in paleopathology. Previous studies demonstrate that DISH has been present across the world for centuries, with ancient cases reported in Europe [101–103], Africa [36], Asia [104,105], the Americas [106,107] and Australia [108]. Such research also revealed that DISH is by no means a recent condition. Skeletal changes evocative of the condition have been reported in some Neanderthal remains from the Middle Paleolithic [109,110], in skeletons from the Neolithic period [111], and in mummies from ancient Egypt [112].

Europe is currently the geographic area in which the most is known on DISH in former times, notably during the medieval and post-medieval periods. Interestingly, the disease prevalence appears to vary markedly between social groups. The condition has been repeatedly reported to be more common in monastic contexts [26, 113–116]. This has been linked to the particular lifestyle of the monks [26], although it may also, in part, be due to the overrepresentation of older adult males in skeletal sample derived from such cemeteries [25]. DISH also appears to be more frequent in individuals of high social status [25,103,117,118]. As an example, the skeletons of Grand Dukes Cosimo I (1519–1574) and his son Ferdinand I (1549–1609) both show the typical features of the disease [103]. Johann Sporck (1595–1679), another high-ranking figure known to have acted as a General during the Thirty Years' War, also had the condition [119]. DISH was also reported, amongst other examples, in two 17th century Finnish aristocrats [117], and in four royal Egyptian mummies of the 18th–20th dynasties (Amenhotep III, Ramesses II, his son Merenptah, and Ramesses III) [112].

It has been postulated that the reasons for the association between DISH and high social status lie in lifestyle differences, and particularly in an over-rich diet in high-ranking individuals [25,26]. This hypothesis has previously been supported by the results of stable isotopic analyses, which revealed high $\delta^{15}\text{N}$ values in individuals diagnosed with DISH, thus demonstrating a diet rich in animal proteins [84,120,121]. Furthermore, written and artistic sources depict some famous DISH sufferers as obese individuals, for example the Grand Dukes of Florence [103] and the General Johann Sporck [119]. The current study provides confirmatory evidence of the influence of social status and nutritional habits on the onset and manifestation of this pathology. Indeed, Tycho Brahe was a person of high extraction who has been part of the elite throughout his lifetime. Furthermore, historical sources report that he became corpulent in the last years of his life [2,122]. Obesity is confirmed by our estimation of physical status based on femoral shaft dimensions. It is also obvious from the results of our dietary study that his diet had a prestigious character, with a very high input of animal protein and/or aquatic resources. Our results thus support the view that DISH is a significant marker of lifestyle.

DISH in a clinical context

At present, the exact etiology of DISH is still uncertain, but is most likely multifactorial [123]. Various causative agents have been suggested, including dietary, toxic, anatomic, environmental, endocrinologic, and metabolic factors [124–126]. A familial or genetic predisposition for the disease has also been proposed [127,128] but remains unproven.

DISH is reported to have life-threatening comorbidities, such as severe atherosclerotic cardiovascular disease and abdominal aortic calcification [129,130]. People with the condition have a significantly higher likelihood of being affected by coronary heart disease than non-DISH patients [131], and uncompensated or paroxysmal atrial fibrillation is more often encountered on hospital admission of patients with the condition [132]. More generally, various studies have reported that DISH carries a risk for stroke and cerebrovascular disease [133].

Besides cardiovascular comorbidities, DISH is associated with various metabolic comorbidities, including obesity, diabetes mellitus, gout, hypertension, hyperinsulinemia, dyslipidemia, and hyperuricemia [31,133]. These conditions extend beyond their simultaneous existence with DISH, but appear to be directly associated with one another. In an extensive review of clinical data, Pillai and Littlejohn [31] identified a trend in comorbidity of DISH, obesity, and adult onset (type 2) diabetes mellitus with disturbance in metabolism of growth hormone and related hormones, insulin and related hormones, and adipokines (i.e. cytokines secreted by adipose tissue). Adipokines are increased in obese individuals, and leptin (one of the adipokines) levels have been shown to promote an increase in cortical but not cancellous bone [134]. This is also supported by our results on physical status estimation based on cortical bone dimensions of the femoral diaphysis. Fat mass also correlates with the secretion of hormones from pancreatic beta cells and from adipocytes involved in reduction of bone resorption and/or osteoblast proliferation (for a review, see [135]). Owing to these metabolic derangements, patients with DISH have an increased likelihood of being affected by metabolic syndrome, and an increased risk for the development of coronary artery disease and stroke [19].

Of the various possible comorbidities, the association of DISH with obesity and late onset (type 2) diabetes are probably the better ascertained. It has been repeatedly reported in various clinical studies [20,91,92,96,126,136,137], although some others failed to confirm such a relationship [138,139]. In Tycho Brahe, the association of DISH with the first one of these conditions is evidenced by our results on physical status estimation. Whether or not he also suffered from diabetes mellitus cannot be determined with certainty, as this disease does not cause

pathognomonic signs in the skeleton [140]. Although some authors tentatively diagnosed the condition on the basis of skeletal lesions [141,142], a recent evaluation of 15 supposed musculoskeletal manifestations of diabetes mellitus (e.g. DISH, osteoarthritis, osteoporosis, gout, periodontal disease) in the William M. Bass Donated Skeletal Collection revealed that no single musculoskeletal variable can be used to predict the disease [143]. Brahe's skeleton exhibits some of these musculoskeletal manifestations, notably osteoarthritic changes and severe periodontal disease in the maxilla (for a detailed study of oral health status, see [144]). Other bone changes that can arise from diabetes, such as distal periostitis in foot phalanges, were absent, and there is no historical evidence that the astronomer suffered from secondary symptoms such as bad eyesight or gastric ulcers. That Brahe suffered from diabetes mellitus thus cannot be ascertained, but should still be viewed as a plausible hypothesis, given his dietary habits and the known high prevalence of DISH in type 2 diabetes patients [145,146].

Possible consequences on the health status and death of Tycho Brahe

DISH is generally an asymptomatic condition, with most affected individuals not even aware of its presence [19]. As a consequence, it has been referred to by some clinicians as a 'state' rather than a 'disease' [147]. Some patients may present back and/or neck pain, restriction of mobility of the spine, and peripheral joint stiffness [19,148]. The exact role of the condition in such clinical symptoms remains, however, a matter of controversy, as some studies conclude that the degree of pain and disability in patients with DISH is higher than in healthy individuals [21,92] whereas others have failed to confirm such an association [149]. In extreme cases, the abundance of new bone formation might be responsible for stiffening of the spine to the extent that patients develop postural abnormalities [150]; this can result in compression of the spinal cord or other structures, causing severe complications [151]. Such symptoms can be excluded in Brahe's case, considering the moderate spinal involvement he suffered. Rare complications resulting from large protruding cervical enthesophytes, such as myelopathy, dysphagia, aspiration pneumonia, esophageal obstruction, or laryngeal edema with severe dyspnea [151] can also be excluded as the axial changes on his skeleton are restricted to the thoracolumbar spine.

Whereas it is most likely that DISH represented only a minor inconvenience for Tycho Brahe and did not have any relevant impact on his daily life and health status, some comorbidities of the condition, if present, could have been life-threatening and may have played some role in the sudden illness he suffered at the end of his life. To discuss such a hypothesis, we must return to the recordings of his very last days, as described by his contemporaries. According to these textual accounts, the astronomer had two symptoms: the first was loss of consciousness (or coma) and the second was urinary retention.

What Brahe's contemporaries perceived or described as a coma has to be understood in the context of the 17th century. The analysis by Koehler and Wijdioc [152] of medical textbooks published between 1640 and 1960 provides valuable information on the subject. According to these authors "the term 'coma', from the Greek *koma*, meaning deep sleep, had already been used in the Hippocratic corpus (*Epidemica*) and later by Galen (second century AD). Subsequently, it was hardly used in the known literature up to the middle of the 17th century. The term is found again in Thomas Willis' (1621–75) influential *De anima brutorum* (1672), where lethargy (pathological sleep, which he localized in the outer cortex), 'coma' (heavy sleeping), *carus* (deprivation of the senses) and apoplexy (into which *carus* could turn and which he localized in the white matter) are mentioned, the sequence indicating increasingly deeper forms of unresponsiveness" [152]. They also note: "Thomas Sydenham (1624–89) mentioned the term 'coma' in several cases of fever" [152]. Apoplexy and stroke are amongst the causes of

'coma' most often encountered in this study. Although it is partly due to the methodology employed (i.e. systematic study of subject indexes and tables of contents, but also of chapters on apoplexy) this result suggests that symptoms of stroke were frequently referred to as 'coma' in 17th century medical treatises. In this view, it is noteworthy that DISH is associated with an elevated risk of stroke and cerebrovascular disease [133].

Acute urinary retention is defined as a sudden inability to urinate although the bladder is full [153]. Aside from being painful, it can lead to renal failure or bladder dysfunction if left unaddressed, and it can result in delirium in elderly patients [154]. The exact etiology of the condition is unclear and is thought to be multifactorial, resulting from a combination of mechanical (benign prostatic hypertrophy, urethral structure, clot retention) or dynamic obstruction (increased alpha-adrenergic activity, prostatic inflammation), bladder over-distension (immobility, constipation, drugs inhibiting bladder contractility, high alcohol intake), and neuropathic mechanisms (diabetic cystopathy, multiple sclerosis) [155]. In males, most cases are associated with benign prostatic hyperplasia [155–157], i.e. an enlargement of the prostate gland that occurs in almost all men as they age. In addition, diabetic neuropathy and stroke are frequent causes of acute urinary retention [153,158]. Thus, an association between DISH, diabetes, and benign prostatic hypertrophy could possibly have been the cause of Brahe's symptoms. These pathological states may be associated with a metabolic syndrome that is very likely to have occurred, as suggested by information on his lifestyle, as well as by our findings on his diet and his physical status.

Considering diabetes mellitus as a possible comorbidity with DISH and obesity in Tycho Brahe, two specific complications of this disease must be considered as possible causes of his death, namely diabetic ketoacidosis (DKA) and the hyperosmolar hyperglycemic state (HHS). DKA is an acute and possibly life-threatening metabolic complication of diabetes resulting from severe insulin deficiency, and subsequent hyperglycemia and metabolic acidosis [159]. It occurs most commonly in autoimmune type 1 diabetes but patients with type 2 diabetes are also at risk during the catabolic stress of acute illness, such as an infection [159,160]. To this extent, it is noteworthy that urinary tract infection is a common accompanying phenomenon in patients with diabetes mellitus, and is generally more severe and carries worse outcomes in patients with type 2 diabetes [161]. Symptoms of DKA include dehydration, diffuse abdominal pain, vomiting, tachypnea, confusion, and occasionally loss of consciousness [159,162], some of which are consistent with the description of Brahe's illness. However, DKA is generally accompanied by excess urination rather than urinary retention [159], making it a rather unlikely diagnosis.

HHS, on the other hand, is a syndrome characterized by extreme elevations in serum glucose concentrations and hyperosmolality, in the absence of significant ketoacidosis [159,163]. Contrary to DKA, it occurs more commonly in patients with type 2 diabetes [163]. Although the pathogenesis of HHS is not perfectly understood to date, the condition appears to result from synergistic factors including insulin deficiency and increased levels of counter-regulatory hormones [159]. As for DKA, the most common precipitating factor is infection [159,164]. Symptoms include signs of dehydration, weakness, legs cramps, delirium, and an altered level of consciousness that evolves not infrequently to profound lethargy or coma [159,162,164]. Although HHS typically causes increased urination, cases have also been reported where patients present with acute urinary retention associated with benign prostatic hypertrophy [165]. Thus, such a syndrome appears as a possible, although putative, cause of the symptoms Brahe endured during his very last days. This hypothesis is compatible with the known fatal outcome of his sudden illness, since mortality associated with HSS is between 10% and 20% in current clinical practice (i.e. about 10 times higher than in patients with DKA) [163].

Finally, another factor that could have conditioned the death of the astronomer, along with having an additive effect on his obesity and metabolic issues (e.g. promoting diabetes) is an excessive consumption of alcohol. In view of our knowledge of the way of life of renaissance noblemen, we can assume that Brahe consumed more alcohol than most of his contemporaries. Furthermore, historic accounts relate that he was notorious for drinking great quantities of wine and other alcoholic beverages [166,167]. Alcohol abuse may cause serious metabolic disturbances, among which alcoholic ketoacidosis, a condition due to the accumulation of β -hydroxybutyrate and acetoacetic acid in the body [168]. As in DKA, symptoms may include abdominal pain, vomiting, tachypnea, and occasionally altered consciousness [169]. This condition manifests itself suddenly, and constitutes in modern days a fairly common cause of sudden, unexpected death in heavy drinkers [170,171]. The so-called “ketoalcoholic death” [168] thus appears as a plausible, albeit hypothetical, diagnosis in Tycho Brahe.

Conclusions

Previous studies of skeletal and hair remains of Tycho Brahe have ruled out the possibility that he died from a violent death (chronic poisoning) and excluded chronic long-term kidney disease and renal osteodystrophy, nutritional osteomalacia, vitamin D and calcium deficiency from gastrointestinal malabsorption syndromes, osteopenia, or osteoporosis [5]. The current paleopathological study provides further evidence about his health status, by revealing that he suffered from both diffuse idiopathic skeletal hyperostosis and obesity. These results, along with those of the isotopic analysis, give a glimpse into the lifestyle of the famous astronomer, revealing the dietary excesses a 16th century high-ranking individual could have afforded (high caloric intake and presumably excessive alcohol consumption). They also reveal the possible health consequences such a prestigious way of life could have had. Although this study does not allow a definite diagnosis to be reached, it highlights plausible reasons for the sudden illness and premature death of the famous astronomer, notably conditions resulting from so-called civilization diseases, which occur with high frequency in DISH patients.

Supporting information

S1 Table. Grades of degenerative changes of the spine (spondylosis and spondyloarthrosis) in Tycho Brahe’s skeleton (according to classification systems of Vyhnanek, Stloukal 1971 and Üstündağ 2009 [15,16]).

(XLSX)

S2 Table. Grades of osteoarthritic changes in the appendicular skeleton of Tycho Brahe (according to classification system of Stloukal, Vyhnanek 1975 [14]).

(XLSX)

S3 Table. Stages of enthesal changes in main muscle attachment sites of Tycho Brahe (according to classification system of Villotte 2006 [13]).

(XLSX)

S4 Table. The values of femoral dimensions (maximum femoral length, medio-lateral endosteal breadth) of the reference sample used in the decision tree for physical status estimation of Tycho Brahe.

(XLSX)

S5 Table. The statistic values of femoral dimensions of the reference sample and Brahe’s values used in the decision tree for his physical status estimation.

(XLSX)

Acknowledgments

This work was financially supported by the Ministry of Culture of the Czech Republic (DKRVO 2017/18, 2018/17 and 2018/18, National Museum, 00023272) and the Charles University Grant Agency (grant no. 230516). We are grateful to Chiara Villa for granting access to the Danish sample of whole-body CT scans; to Marek Jantač for his photographic and X-ray documentation; and to Frédéric Santos for his invaluable help in statistics. Our thanks also go to Mgr. Vladimír Kelnar (Church of Our Lady before Týn) for his help in organizing the exhumation.

Author Contributions

Conceptualization: Sacha Kacki, Petr Velemínský, Jens Vellev, Jaroslav Brůžek.

Formal analysis: Sacha Kacki, Petr Velemínský, Sylva Kaupová, Alizé Lacoste Jeanson, Jaroslav Brůžek.

Funding acquisition: Petr Velemínský, Niels Lynnerup, Sylva Kaupová, Alizé Lacoste Jeanson, Jens Vellev.

Investigation: Sacha Kacki, Petr Velemínský, Sylva Kaupová, Alizé Lacoste Jeanson, Jaroslav Brůžek.

Methodology: Sacha Kacki, Petr Velemínský, Sylva Kaupová, Alizé Lacoste Jeanson, Jaroslav Brůžek.

Project administration: Petr Velemínský, Jaroslav Brůžek.

Resources: Niels Lynnerup, Ctibor Povýšil, Martin Horák, Jan Kučera, Kaare Lund Rasmussen, Jaroslav Podliska, Zdeněk Dragoun, Jiří Smolík, Jens Vellev.

Supervision: Petr Velemínský, Niels Lynnerup, Jaroslav Brůžek.

Visualization: Sacha Kacki, Sylva Kaupová, Alizé Lacoste Jeanson.

Writing – original draft: Sacha Kacki, Petr Velemínský, Sylva Kaupová, Alizé Lacoste Jeanson, Jaroslav Brůžek.

Writing – review & editing: Sacha Kacki, Petr Velemínský, Sylva Kaupová, Alizé Lacoste Jeanson, Jaroslav Brůžek.

References

1. Janovský I (2010) Tycho Brahe's death: facts and speculations. In: Hadravová A, Mahoney TJ, Hadrava P, editors. Kepler's heritage in the space age (400th anniversary of Astronomia nova). Prague: National Technical Museum. pp. 126–135.
2. Mikovec FB (1847) Tycho Brahe, Životopisný nástin—K třistaleté památce narození Tychona. Prague, J Pospíšil Press.
3. Vellev J (2006) Tycho Brahes begravelse i Prag. In: Grindler-Hansen P, editor. Tycho Brahes Verden Danmark i Europa 1550–1600 The World of Tycho Brahe. Copenhagen: The National Museum. pp. 229–243 (English summary, p. 277: 'Tycho Brahe's burial in Prague').
4. Gotfredsen E (1955) Tycho Brahe sidste sygdom og død [Tycho Brahe's last illness and death]. *Fund og Forskning* 2: 33–38.
5. Kučera J, Rasmussen KL, Kameník J, Kubešová M, Skytte L, Povýšil C, et al. (2017) Was He Murdered or Was He Not?—Part II: Multi-Elemental Analyses of Hair and Bone Samples from Tycho Brahe and Histopathology of His Bones. *Archaeometry* 59, 5: 918–933.
6. Gilder J, Gilder A-L (2004) Heavenly intrigue: Johannes Kepler, Tycho Brahe, and the murder behind one of history's greatest scientific discoveries. New York: Doubleday.
7. Andersen PH (2009) Kunstværket. Copenhagen: Books on Demand.

8. Dragoun Z, Podliska J (2010) Nálezová zpráva, Archeologický výzkum, Praha 1 –Staré Město, Kostel Matky Boží před Týnem, ppč. 623, výzkum NPÚ, ú.o.p. v hl. m. Praze č. 2010/37, archiv NZ NPÚ Praha čj. 3824/11; archiv NZ ARÚ AV ČR, Praha, př. č. TX-2011-2089.
9. Matiegka H (1901) Bericht über die Untersuchung der Gebeine Tycho Brahe's, Verlag der königlich böhmischen Gesellschaft der. Prague: Wissenschaften.
10. Velemínský P, Brůžek J (2011) Report of the Department of Anthropology, National Museum in Prague regarding the preliminary results of the Danish-Czech project—survey of the skeletal remains of Tycho Brahe (1546–1601). Prague: The Archive of National Museum. 5 p.
11. Rasmussen KL, Kučera J, Skytte L, Kameník J, Havránek V, Smolík J, et al. (2013) Was he murdered or was he not?—Part I: Analyses of mercury in the remains of Tycho Brahe. *Archaeometry* 55: 1187–1195.
12. Velemínský P, Brůžek J, Lynnerup N, Alexandersen V, Horák M, Dobisíková M, et al. (2013) Antropologicko-lékařský průzkum ostatků Tychona Brahe. Výstava: Výzkum hrobky a ostatků Tychona Brahe. Praha: Akademie věd ČR.
13. Villotte S (2006) Connaissances médicales actuelles, cotation des enthésopathies: nouvelle méthode. *Bulletins et Mémoires de la Société d'Anthropologie de Paris* 18: 65–85.
14. Stloukal M, Vyhnánek L (1975) Die Arthrose der grossen gelenke. *Homo* 26: 121–136.
15. Vyhnánek L, Stloukal M (1971) Arthrosa, spondylosa a jejich význam pro určování věku. In: Vlček E, editor. Symposium o určování stáří a pohlaví jedince na základě studia kostry. Praha: Národní muzeum. pp. 150–159.
16. Ůstündaġ H (2009) Schmorl's nodes in a post-medieval skeletal sample from Klostermarienberg, Austria. *International Journal of Osteoarchaeology* 19: 695–710.
17. Resnick D, Niwayama G (1976) Radiographic and pathologic features of spinal involvement in diffuse idiopathic skeletal hyperostosis (DISH). *Radiology* 119: 559–568. <https://doi.org/10.1148/119.3.559> PMID: 935390
18. Resnick D, Shaul SR, Robins JM (1975) Diffuse idiopathic skeletal hyperostosis (DISH): Forestier's disease with extraspinal manifestations. *Radiology* 115: 513–524. <https://doi.org/10.1148/15.3.513> PMID: 1129458
19. Mader R, Verlaan JJ, Buskila D (2013) Diffuse idiopathic skeletal hyperostosis: clinical features and pathogenic mechanisms. *Nature Reviews Rheumatology* 9: 741–750. <https://doi.org/10.1038/nrrheum.2013.165> PMID: 24189840
20. Julkunen H, Heinonen OP, Pyorala K (1971) Hyperostosis of the spine in an adult population. Its relation to hyperglycaemia and obesity. *Annals of the Rheumatic Diseases* 30: 605–612. PMID: 5130140
21. Utsinger PD (1985) Diffuse idiopathic skeletal hyperostosis. *Clinics of Rheumatic Diseases* 11: 325–329.
22. Waldron T (2008) *Palaeopathology: Cambridge Manuals in Archaeology*. New York: Cambridge University Press. 279 p.
23. Resnick D (2002) *Diagnosis of bone and joint disorders, fourth edition*. Philadelphia: W.B. Saunders Company. 4944 p.
24. Resnick D, Shapiro RF, Wiesner KB, Niwayama G, Utsinger PD, Shaul SR (1978) Diffuse idiopathic skeletal hyperostosis (DISH) [ankylosing hyperostosis of Forestier and Rotes-Querol]. *Seminars in Arthritis and Rheumatism* 7: 153–187. PMID: 341323
25. Kacki S, Villotte S (2006) Maladie hyperostotique et mode de vie: intérêt d'une démarche bio-archéologique. Exemple du cimetière du Couvent des Soeurs Grises de Beauvais (Oise), XVe-XVIIIe siècles. *Bulletins et Mémoires de la Société d'Anthropologie de Paris* 18: 55–64.
26. Rogers J, Waldron T (2001) DISH and the monastic way of life. *International Journal of Osteoarchaeology* 11: 357–365.
27. Paja L, Molnár E, Osz B, Tiszlavicz L, Palkó A, Coqueugnot H, et al. (2010) Diffuse idiopathic skeletal hyperostosis-appearance and diagnostics in Hungarian osteoarchaeological materials. *Acta Biologica Szegediensis* 54: 75–81.
28. Rogers J, Waldron T (1995) *A field guide to joint disease in archaeology*. Chichester: John Wiley & Sons. 119 p.
29. Goldberg RP, Carter BL (1978) Absence of thoracic osteophytosis in the area adjacent to the aorta: computed tomography demonstration. *Journal of Computer Assisted Tomography* 2: 173–175. PMID: 701503
30. Forestier J, Lagier R (1971) Ankylosing hyperostosis of the spine. *Clinical Orthopaedics and Related Research* 74: 65–83. PMID: 4993095

31. Pillai S, Littlejohn G (2014) Metabolic factors in diffuse idiopathic skeletal hyperostosis—a review of clinical data. *The Open Rheumatology Journal* 8: 116–128. <https://doi.org/10.2174/1874312901408010116> PMID: 25598855
32. Bywaters EGL, Doyle FH, Oakley N (1966) Senile hyperostotic ankylosing spondylosis (Forestier and Querol) in diabetes mellitus. *Arthritis & Rheumatism* 9: 495.
33. Harris J, Carter AR, Glick EN, Storey GO (1974) Ankylosing hyperostosis. I. Clinical and radiological features. *Annals of the Rheumatic Diseases* 33: 210–215. PMID: 4276454
34. Arlet J, Mazieres B (1985) La maladie hyperostotique. *La Revue de médecine interne* 6: 553–564.
35. Crubézy E, Crubézy-Ibáñez E (1993) Évaluation sur une série de squelettes de critères diagnostics de la maladie hyperostotique implications épidémiologiques. *Revue du rhumatisme* 60: 586–590.
36. Arriaza BT, Merbs CF, Rothschild BM (1993) Diffuse idiopathic skeletal hyperostosis in Meriotic Nubians from Semna South, Sudan. *American Journal of Physical Anthropology* 92: 243–248. <https://doi.org/10.1002/ajpa.1330920302> PMID: 8291616
37. Haller J, Resnick D, Miller CW, Schils JP, Kerr R, Bielecki D, et al. (1989) Diffuse idiopathic skeletal hyperostosis: diagnostic significance of radiographic abnormalities of the pelvis. *Radiology*: 835–839.
38. Waldron T, Rogers J (1990) An epidemiologic study of sacroiliac fusion in some human skeletal remains. *American Journal of Physical Anthropology* 83: 123–127. <https://doi.org/10.1002/ajpa.1330830114> PMID: 2221026
39. Fahy GE, Deter C, Pitfield R, Miskiewicz JJ, Mahoney P (2017) Bone deep: Variation in stable isotope ratios and histomorphometric measurements of bone remodelling within adult humans. *Journal of Archaeological Science* 87: 10–16.
40. Beaumont J, Geber J, Powers N, Wilson A, Lee-Thorp J, Montgomery J (2013) Victims and survivors: stable isotopes used to identify migrants from the Great Irish Famine to 19th century London. *American Journal of Physical Anthropology* 150: 87–98. <https://doi.org/10.1002/ajpa.22179> PMID: 23124593
41. Longin R (1971) New method of collagen extraction for radiocarbon dating. *Nature* 230: 241–242. PMID: 4926713
42. Bocherens H (1992) Biogéochimie isotopique (^{13}C , ^{15}N , ^{18}O) et paléontologie des vertébrés: applications à l'étude des réseaux trophiques révolus et des paléoenvironnements [PhD thesis]: Université Paris VI. 317 p.
43. Hedges RE, Clement JG, Thomas CDL, O'connell TC (2007) Collagen turnover in the adult femoral mid-shaft: Modeled from anthropogenic radiocarbon tracer measurements. *American Journal of Physical Anthropology* 133: 808–816. <https://doi.org/10.1002/ajpa.20598> PMID: 17405135
44. Turner SA (2013) Dietary Reconstruction in Medieval Holbæk, Denmark using Dental Microwear and Macrowear, Isotopic Analyses, and Dental Caries [Master thesis]: Georgia State University. 96 p.
45. Yoder C (2010) Diet in medieval Denmark: a regional and temporal comparison. *Journal of Archaeological Science* 37: 2224–2236.
46. Yoder C (2012) Let them eat cake? Status-based differences in diet in medieval Denmark. *Journal of Archaeological Science* 39: 1183–1193.
47. Quintelier K, Ervynck A, Müldner G, Neer W, Richards MP, Fuller BT (2014) Isotopic examination of links between diet, social differentiation, and DISH at the post-medieval Carmelite Friary of Aalst, Belgium. *American Journal of Physical Anthropology* 153: 203–213. <https://doi.org/10.1002/ajpa.22420> PMID: 24226894
48. Jørkov MLS, Gröcke DR (2016) Investigating adult diet during industrialization in Copenhagen based on stable isotope analysis of bone collagen and hair keratin. *Archaeological and Anthropological Sciences*: 1–15.
49. Salesse K, Dufour E, Castex D, Velemínský P, Santos F, Kuchařová H, et al. (2013) Life history of the individuals buried in the St. Benedict Cemetery (Prague, 15th–18th centuries): insights from ^{14}C dating and stable isotope ($\delta^{13}\text{C}$, $\delta^{15}\text{N}$, $\delta^{18}\text{O}$) analysis. *American Journal of Physical Anthropology* 151: 202–214. <https://doi.org/10.1002/ajpa.22267> PMID: 23588853
50. Jørkov MLS, Heinemeier J, Lynnerup N (2007) Evaluating bone collagen extraction methods for stable isotope analysis in dietary studies. *Journal of Archaeological Science* 34: 1824–1829.
51. Pestle WJ (2010) Chemical, elemental, and isotopic effects of acid concentration and treatment duration on ancient bone collagen: an exploratory study. *Journal of Archaeological Science* 37: 3124–3128.
52. Sealy J, Johnson M, Richards M, Nehlich O (2014) Comparison of two methods of extracting bone collagen for stable carbon and nitrogen isotope analysis: comparing whole bone demineralization with gelatinization and ultrafiltration. *Journal of Archaeological Science* 47: 64–69.

53. Tsutaya T, Gakuhari T, Asahara A, Yoneda M (2017) Isotopic comparison of gelatin extracted from bone powder with that from bone chunk and development of a framework for comparison of different extraction methods. *Journal of Archaeological Science: Reports* 11: 99–105.
54. Ruff CB (2000) Body mass prediction from skeletal frame size in elite athletes. *American Journal of Physical Anthropology* 113: 507–517 [https://doi.org/10.1002/1096-8644\(200012\)113:4<507::AID-AJPA5>3.0.CO;2-F](https://doi.org/10.1002/1096-8644(200012)113:4<507::AID-AJPA5>3.0.CO;2-F) PMID: 11102884
55. Chevalier T, Lefèvre P, Clarys JP, Beauthier J- P (2016) The accuracy of body mass prediction for elderly specimens: Implications for paleoanthropology and legal medicine. *Journal of Forensic and Legal Medicine* 43: 102–109. <https://doi.org/10.1016/j.jflm.2016.07.015> PMID: 27497725
56. Lacoste Jeanson A, Villa C, Lynnerup N, Brůžek J (2017) Body mass estimation methods from the skeleton: why should their use be avoided for estimating individual body mass? *Bulletins et Mémoires de la Société d'Anthropologie de Paris* 29: S21–S22.
57. Ruff CB, Scott WW, Liu AYC (1991) Articular and diaphyseal remodeling of the proximal femur with changes in body mass in adults. *American Journal of Physical Anthropology* 86: 397–413. <https://doi.org/10.1002/ajpa.1330860306> PMID: 1746645
58. McHenry HM (1992) Body size and proportions in early hominids. *American Journal of Physical Anthropology* 87: 407–431. <https://doi.org/10.1002/ajpa.1330870404> PMID: 1580350
59. Grine FE, Jungers WL, Tobias PV, Pearson OM (1995) Fossil Homo femur from Berg Aukas, northern Namibia. *American Journal of Physical Anthropology* 97: 151–185. <https://doi.org/10.1002/ajpa.1330970207> PMID: 7653506
60. Ruff CB, Niskanen M, Junno J-A, Jamison P (2005) Body mass prediction from stature and bi-iliac breadth in two high latitude populations, with application to earlier higher latitude humans. *Journal of Human Evolution* 48: 381–392. <https://doi.org/10.1016/j.jhevol.2004.11.009> PMID: 15788184
61. Ruff CB, Holt BM, Niskanen M, Sladěk V, Berner M, Garofalo E, et al. (2012) Stature and body mass estimation from skeletal remains in the European Holocene. *American Journal of Physical Anthropology* 148: 601–617. <https://doi.org/10.1002/ajpa.22087> PMID: 22639191
62. Moore MK, Schaefer E (2011) A comprehensive regression tree to estimate body weight from the skeleton. *Journal of Forensic Sciences* 56: 1115–1122. <https://doi.org/10.1111/j.1556-4029.2011.01819.x> PMID: 21644991
63. Elliott M, Kurki H, Weston DA, Collard M (2016) Estimating body mass from skeletal material: new predictive equations and methodological insights from analyses of a known-mass sample of humans. *Archaeological and Anthropological Sciences* 8: 731–750.
64. Lacoste Jeanson A, Dupej J, Villa C, Brůžek J (2017) Body composition estimation from selected slices: equations computed from a new semi-automatic thresholding method developed on whole-body CT scans. *PeerJ* 5: e3302. <https://doi.org/10.7717/peerj.3302> PMID: 28533960
65. WHO Expert Committee (1995) *Physical status: the use and interpretation of anthropometry*. Geneva: World Health Organisation. 452 p.
66. Breiman L (1984) *Classification and regression trees*. New York: Chapman & Hall: ITP International Thomson Publishing. 358 p.
67. Dupej J, Lacoste Jeanson A, Pelikán J, Brůžek J (2017) Semiautomatic extraction of cortical thickness and diaphyseal curvature from CT scans. *American Journal of Physical Anthropology* 2017; 00: 1–9.
68. Rogers J, Waldron T, Dieppe P, Watt I (1987) Arthropathies in palaeopathology: the basis of classification according to most probable cause. *Journal of Archaeological Science* 14: 179–193.
69. Lagier R (1987) Approche globale du concept d'arthrose par l'anatomopathologie. In: Simon L, Loyau G, editors. *L'arthrose: perspectives et réalités*. Paris: Masson. pp. 185–197.
70. Berne D, Goubier JN, Lemoine J, Saillant G (1999) The aging spine: natural evolution. *European Journal of Orthopaedic Surgery & Traumatology* 9: 125–133.
71. Moll JMH, Haslock I, Macrae IF, Wright V (1974) Associations between ankylosing spondylitis, psoriatic arthritis, Reiter's disease, the intestinal arthropathies, and Behcet's syndrome. *Medicine* 53: 343–364. PMID: 4604133
72. Wright V, Moll JMH (1976) *Seronegative polyarthritis*. Amsterdam: Elsevier. 488 p.
73. Dougados M, Linden SVD, Juhlin R, Huitfeldt B, Amor B, Calin A, et al. (1991) The European spondyloarthritis study group preliminary criteria for the classification of spondyloarthritis. *Arthritis & Rheumatism* 34: 1218–1227.
74. Rothschild BM, Woods RJ (1991) Spondyloarthritis: erosive arthritis in representative defleshed bones. *American Journal of Physical Anthropology* 85: 125–134. <https://doi.org/10.1002/ajpa.1330850202> PMID: 1882978

75. Ball J (1971) Enthesopathy of rheumatoid and ankylosing spondylitis. *Annals of Rheumatic Diseases* 30: 213–223.
76. Sieper J, Braun J, Rudwaleit M, Boonen A, Zink A (2002) Ankylosing spondylitis: an overview. *Annals of the Rheumatic Diseases* 61 (Suppl. III): iii8–iii18.
77. Paolaggi JB (1991) Enthésopathies inflammatoires. In: Simon L, Hérisson C, Rodineau J, editors. *Pathologie des insertions et enthésopathies*. Paris: Masson. pp. 41–48.
78. Villotte S, Kacki S (2009) Remodelages des enthèses fibrocartilagineuses dans les spondylarthropathies inflammatoires. L'exemple du cimetière du couvent des Soeurs Grises de Beauvais (Oise), XVe–XVIIIe siècles. *Bulletins et Mémoires de la Société d'Anthropologie de Paris* 21: 159–169.
79. Reitsemá LJ (2013) Beyond diet reconstruction: stable isotope applications to human physiology, health, and nutrition. *American Journal of Human Biology* 25: 445–456. <https://doi.org/10.1002/ajhb.22398> PMID: 23784719
80. Fischer A, Olsen J, Richards M, Heinemeier J, Sveinbjörnsdóttir ÁE, Bennike P (2007) Coast–inland mobility and diet in the Danish Mesolithic and Neolithic: evidence from stable isotope values of humans and dogs. *Journal of Archaeological Science* 34: 2125–2215.
81. Richards M, Douglas Price T (2003) Mesolithic and Neolithic subsistence in Denmark: new stable isotope data. *Current Anthropology* 44: 288–295.
82. Frolík J, Kaupová S (2016) Pohřebiště Pražského hradu a možnosti jejich sociální interpretace. *Archaeologia historica* 41: 101–122.
83. Schoeninger MJ, DeNiro MJ (1984) Nitrogen and carbon isotopic composition of bone collagen from marine and terrestrial animals. *Geochimica et Cosmochimica Acta* 48: 625–639.
84. Fornaciari G (2008) Food and disease at the renaissance courts of Naples and Florence: a paleonutritional study. *Appetite* 51: 10–14. <https://doi.org/10.1016/j.appet.2008.02.010> PMID: 18359535
85. Jiménez-Brobeil S, Laffranchi Z, Maroto R, Sánchez FL, Huertas AD (2016) How royals feasted in the court of Pedro I of Castile: A contribution of stable isotope study to medieval history. *Journal of Archaeological Science: Reports* 10: 424–430.
86. Lamb AL, Evans JE, Buckley R, Appleby J (2014) Multi-isotope analysis demonstrates significant lifestyle changes in King Richard III. *Journal of Archaeological Science* 50: 559–565.
87. Woolgar C (2001) Fast and feast: conspicuous consumption and the diet of the nobility in the 15th century. In: Hicks M., editor. *Revolution and Consumption in Late Medieval England*. Woodbridge: Boydell Press. pp. 7–25.
88. Serjeantson D, Woolgar C (2006) Fish consumption in medieval England. In: Woolgar C, Serjeantson D., Waldron T., editors. *Food in Medieval England: Diet and Nutrition*. Oxford: Oxford University Press. pp. 102–130.
89. Hedges RE, Reynard LM (2007) Nitrogen isotopes and the trophic level of humans in archaeology. *Journal of Archaeological Science* 34: 1240–1251.
90. Forestier J, Rotes-Querol J (1950) Senile ankylosing hyperostosis of the spine. *Annals of the Rheumatic Diseases* 9: 321–330. PMID: 14800245
91. Julkunen H, Heinonen OP, Knekt P, Maatela J (1975) The epidemiology of hyperostosis of the spine together with its symptoms and related mortality in a general population. *Scandinavian Journal of Rheumatology* 4: 23–27. PMID: 1153976
92. Mata S, Fortin PR, Fitzcharles MA, Starr MR, Joseph L, Watts CS, et al. (1997) A controlled study of diffuse idiopathic skeletal hyperostosis. Clinical features and functional status. *Medicine (Baltimore)* 76: 104–117.
93. Bloom RA (1984) The prevalence of ankylosing hyperostosis in a Jerusalem population—with description of a method of grading the extent of the disease. *Scandinavian Journal of Rheumatology* 13: 181–189. PMID: 6740271
94. Westerveld LA, van Ufford HMQ, Verlaan JJ, Oner FC (2008) The prevalence of diffuse idiopathic skeletal hyperostosis in an outpatient population in The Netherlands. *The Journal of Rheumatology* 35: 1635–1638. PMID: 18528963
95. Kim SK, Choi BR, Kim CG, Chung SH, Choe JY, Joo KB, et al. (2004) The prevalence of diffuse idiopathic skeletal hyperostosis in Korea. *The Journal of Rheumatology* 31: 2032–2035. PMID: 15468371
96. Kiss C, O'Neill TW, Mituszova M, Szilagyi M, Poór G (2002) The prevalence of diffuse idiopathic skeletal hyperostosis in a population-based study in Hungary. *Scandinavian Journal of Rheumatology* 31: 226–229. PMID: 12369655
97. Weinfeld RM, Olson PN, Maki DD, Griffiths HJ (1997) The prevalence of diffuse idiopathic skeletal hyperostosis (DISH) in two large American Midwest metropolitan hospital populations. *Skeletal Radiology* 26: 222–225. PMID: 9151370

98. Roberts C, Manchester K (2005) *The Archaeology of Disease*, 3rd edition. New York: Cornell University Press. 326 p.
99. Rogers J, Watt I, Dieppe P (1985) Paleopathology of spinal osteophytosis, vertebral ankylosis, ankylosing spondylitis, and vertebral hyperostosis. *Annals of the Rheumatic Diseases* 44: 113–120. PMID: [3883915](#)
100. Rogers J, Watt I, Dieppe P (1981) Arthritis in Saxon and mediaeval skeletons. *British Medical Journal* 283: 1668–1670. PMID: [6797606](#)
101. Reale B, Marchi D, Borgognini Tarli SM (1999) A case of diffuse idiopathic skeletal hyperostosis (DISH) from a medieval necropolis in southern Italy. *International Journal of Osteoarchaeology* 9: 369–373.
102. Mays S (2000) Diffuse idiopathic skeletal hyperostosis (DISH) in skeletons from two medieval English cemeteries. *Journal of Paleopathology* 12: 25–36.
103. Giuffra V, Giusiani S, Fornaciari A, Villari N, Vitiello A, Fornaciari G (2010) Diffuse idiopathic skeletal hyperostosis in the Medici, Grand Dukes of Florence (XVI century). *European Spine Journal* 19: 103–107.
104. Hukuda S, Inoue K, Ushiyama T, Saruhashi Y, Iwasaki A, Huang J, et al. (2000) Spinal degenerative lesions and spinal ligamentous ossifications in ancient Chinese populations of the Yellow River Civilization. *International Journal of Osteoarchaeology* 10: 108–124.
105. Kim MJ, Lee IS, Kim YS, Oh CS, Park JB, Shin MH, et al. (2012) Diffuse idiopathic skeletal hyperostosis cases found in Joseon Dynasty Human Sample Collection of Korea. *International Journal of Osteoarchaeology* 22: 235–244.
106. Arriaza BT (1993) Seronegative spondyloarthropathies and diffuse idiopathic skeletal hyperostosis in ancient northern Chile. *American Journal of Physical Anthropology* 91: 263–278. <https://doi.org/10.1002/ajpa.1330910302> PMID: [8333484](#)
107. Smith MO, Dorsz JR, Betsinger TK (2013) Diffuse idiopathic skeletal hyperostosis (DISH) in pre-Columbian North America: Evidence from the eastern Tennessee River Valley. *International Journal of Paleopathology* 3: 11–18. <https://doi.org/10.1016/j.ijpp.2013.03.001> PMID: [29539355](#)
108. Pretty GL, Kricun ME (1989) Prehistoric health status of the Roonka population. *World Archaeology* 21: 198–224. <https://doi.org/10.1080/00438243.1989.9980102> PMID: [16470996](#)
109. Crubézy E, Trinkaus E (1992) Shanidar 1: a case of hyperostotic disease (DISH) in the middle Paleolithic. *American Journal of Physical Anthropology* 89: 411–420. <https://doi.org/10.1002/ajpa.1330890402> PMID: [1463085](#)
110. Trinkaus E, Maley B, Buzhilova AP (2008) Brief communication: Paleopathology of the Kiik-Koba 1 Neandertal. *American Journal of Physical Anthropology* 137: 106–112. <https://doi.org/10.1002/ajpa.20833> PMID: [18357583](#)
111. Faccia K, Waters-Rist A, Lieverse AR, Bazaliiskii VI, Stock JT, Katzenberg MA (2016) Diffuse idiopathic skeletal hyperostosis (DISH) in a middle Holocene forager from Lake Baikal, Russia: Potential causes and the effect on quality of life. *Quaternary International* 405: 66–79.
112. Saleem SN, Hawass Z (2014) Brief report: Ankylosing spondylitis or diffuse idiopathic skeletal hyperostosis in royal Egyptian mummies of the 18th–20th dynasties? Computed tomography and archaeology studies. *Arthritis & Rheumatology* 66: 3311–3316.
113. Waldron T (1985) DISH at Merton Priory: evidence for a 'new' occupational disease? *British Medical Journal* 291: 1762–1763. PMID: [3936574](#)
114. De la Rúa C, Orúe JM (1993) Health conditions in a monastic community of the Basque Country. *Journal of Paleopathology* 4: 193–200.
115. Janssen H, Matt G (1999) Canons buried in the 'Stifskapel' of the Saint Servaas Basilica at Maastricht AD 1070–1521. A paleopathological study. *Barge's Anthropologica* 5: 1–40.
116. Verlaan JJ, Oner FC, Maat G (2007) Diffuse idiopathic skeletal hyperostosis in ancient clergymen. *European Spine Journal* 16: 1129–1135. <https://doi.org/10.1007/s00586-007-0342-x> PMID: [17390155](#)
117. Núñez M, Väre T, Junno JA, Niinimäki J, Niinimäki S, Niskanen M. DISH in two members of Finland's 17th-century upper class; 2013; Universitat Autònoma de Barcelona. pp. 477–488.
118. Jankauskas R (2003) The incidence of diffuse idiopathic skeletal hyperostosis and social status correlations in Lithuanian skeletal materials. *International Journal of Osteoarchaeology* 13: 289–293.
119. Dobisikova M, Vyhnánek L, Velemínský P, Kuzelka V, Cejkova I (1999) Palaeopathology and historical personality of General Johann Sporck (1595–1679). *International Journal of Osteoarchaeology* 9: 297–301.
120. Müldner G, Richards MP (2007) Diet and diversity at later medieval Fishergate: the isotopic evidence. *American Journal of Physical Anthropology* 134: 162–174. <https://doi.org/10.1002/ajpa.20647> PMID: [17568445](#)

121. Bondioli L, Nava A, Rossi PF, Sperduti A (2016) Diet and health in Central-Southern Italy during the Roman Imperial time. *Aacta IMEKO* 5: 19–25.
122. Brewster D (1846) *The martyrs of science or the lives of Galileo, Tycho Brahe, and Kepler*. London: John Murray. 258 p.
123. Pavelková A (2017) Diffuse idiopathic skeletal hyperostosis. In: Rovenský J, editor. *Gerontorheumatology* Springer. pp. 269–274.
124. Sarzi-Puttini P, Atzeni F (2004) New developments in our understanding of DISH (diffuse idiopathic skeletal hyperostosis). *Current Opinion in Rheumatology* 16: 287–292. PMID: [15103260](https://pubmed.ncbi.nlm.nih.gov/15103260/)
125. Cassim B, Mody GM, Rubin DL (1990) The prevalence of diffuse idiopathic skeletal hyperostosis in African blacks. *British Journal of Radiology* 29: 131–132.
126. Mader R, Lavi I (2009) Diabetes mellitus and hypertension as risk factors for early diffuse idiopathic skeletal hyperostosis (DISH). *Osteoarthritis and Cartilage* 17: 825–828. <https://doi.org/10.1016/j.joca.2008.12.004> PMID: [19176286](https://pubmed.ncbi.nlm.nih.gov/19176286/)
127. Pappone N, Di Girolamo C, Del Puente A, Scarpa R, Oriente P (1996) Diffuse idiopathic skeletal hyperostosis (DISH): A retrospective analysis. *Clinical Rheumatology* 15: 121–124. PMID: [8777843](https://pubmed.ncbi.nlm.nih.gov/8777843/)
128. Gorman C (2005) A family with diffuse idiopathic skeletal hyperostosis. *Annals of the Rheumatic Diseases* 64: 1794–1795. <https://doi.org/10.1136/ard.2004.033852> PMID: [16284348](https://pubmed.ncbi.nlm.nih.gov/16284348/)
129. Zincarelli C, Iervolino S, Di Minno MND, Miniero E, Rengo C, Di Gioia L, et al. (2012) Diffuse idiopathic skeletal hyperostosis prevalence in subjects with severe atherosclerotic cardiovascular diseases. *Arthritis care & research* 64: 1765–1769.
130. Pariente-Rodrigo E, Sgaramella GA, Olmos-Martínez JM, Pini-Valdivieso SF, Landeras-Alvaro R, Hernández-Hernández JL (2017) Relationship between diffuse idiopathic skeletal hyperostosis, abdominal aortic calcification and associated metabolic disorders: Data from the Camargo Cohort. *Medicina Clínica* 149: 196–202. <https://doi.org/10.1016/j.medcli.2017.01.030> PMID: [28283270](https://pubmed.ncbi.nlm.nih.gov/28283270/)
131. Mader R, Novofestovski I, Adawi M, Lavi I (2009) Metabolic syndrome and cardiovascular risk in patients with diffuse idiopathic skeletal hyperostosis. *Seminars in Arthritis and Rheumatism* 38: 361–365. <https://doi.org/10.1016/j.semarthrit.2008.01.010> PMID: [18304611](https://pubmed.ncbi.nlm.nih.gov/18304611/)
132. Mader R, Dubenski N (2005) Morbidity and mortality of hospitalized patients with diffuse idiopathic skeletal hyperostosis. *Rheumatology International* 26: 132–136. <https://doi.org/10.1007/s00296-004-0529-y> PMID: [16341904](https://pubmed.ncbi.nlm.nih.gov/16341904/)
133. Terzi R (2014) Extraskelatal symptoms and comorbidities of diffuse idiopathic skeletal hyperostosis. *World Journal of Clinical Cases* 2: 422–425. <https://doi.org/10.12998/wjcc.v2.i9.422> PMID: [25232544](https://pubmed.ncbi.nlm.nih.gov/25232544/)
134. Li H, Jiang LS, Dai LY (2007) Hormones and growth factors in the pathogenesis of spinal ligament ossification. *European Spine Journal* 16: 1075–1084. <https://doi.org/10.1007/s00586-007-0356-4> PMID: [17426989](https://pubmed.ncbi.nlm.nih.gov/17426989/)
135. Reid IR (2007) Relationships between fat and bone. *Osteoporosis International* 19: 595–606. <https://doi.org/10.1007/s00198-007-0492-z> PMID: [17965817](https://pubmed.ncbi.nlm.nih.gov/17965817/)
136. Hájková Z, Středa A, Škrha F (1965) Hyperostotic spondylosis and diabetes mellitus. *Annals of Rheumatic Diseases* 24: 536–543.
137. Kiss C, Szilagyi M, Paksy A, Poor G (2002) Risk factors for diffuse idiopathic skeletal hyperostosis: a case-control study. *Rheumatology* 41: 27–30. PMID: [11792876](https://pubmed.ncbi.nlm.nih.gov/11792876/)
138. Vezyroglou G, Mitropoulos A, Kyriazis N, Antoniadis C (1996) A metabolic syndrome in diffuse idiopathic skeletal hyperostosis. A controlled study. *Journal of Rheumatology* 23: 672–676. PMID: [8730125](https://pubmed.ncbi.nlm.nih.gov/8730125/)
139. Daragon A, Mejjad O, Czernichow P, Louvel JP, Vittecoq O, Durr A, et al. (1995) Vertebral hyperostosis and diabetes mellitus. A case-control study. *Annals of Rheumatic Diseases* 54: 375–378.
140. May SE (2014) *An investigation of diabetes mellitus in postmortem human remains [PhD thesis]*. Knoxville: University of Tennessee. 163 p.
141. Mihalache I, Radu C, Kelemen B (2014) Molecular diagnosis of pathologies in ancient human remains. A case study: the bioarchaeological study of a Neolithic skeleton displaying symptoms of diabetes. *Studia Universitatis Babeş-Bolyai, Biologia* 59: 135–144.
142. Dupras TL, Williams LJ, Willems H, Peeters C (2010) Pathological skeletal remains from ancient Egypt: the earliest case of diabetes mellitus? *Practical Diabetes International* 27: 358–363.
143. Upson-Taboas CF (2016) Musculoskeletal manifestations of diabetes mellitus in the William M. Bass donated skeletal collection. *American Journal of Physical Anthropology* 159 (S52): 320.
144. Alexandersen V (2011) Tycho Brahe dentition. Preliminary report (CT segmentation by medical student Pernille Heimdahl Holm). Unpublished.

145. Mazières B (2013) Diffuse idiopathic skeletal hyperostosis (Forestier-Rotes-Querol disease): what's new? *Joint Bone Spine* 80: 466–470. <https://doi.org/10.1016/j.jbspin.2013.02.011> PMID: 23566663
146. Agrawal RP, Gothwal S, Tantia P, Agrawal R, Rijhwani P, Sirohi P, et al. (2014) Prevalence of rheumatological manifestations in diabetic population from North-West India. *Journal of the Association of Physicians of India* 62: 788–792. PMID: 26259313
147. Hutton C (1989) DISH . . . a state not a disease? *British Journal of Rheumatology* 28: 277–278. PMID: 2525941
148. Holgate RL, Steyn M (2016) Diffuse idiopathic skeletal hyperostosis: diagnostic, clinical, and paleopathological considerations. *Clinical Anatomy* 29: 870–877. <https://doi.org/10.1002/ca.22716> PMID: 27004482
149. Schlapbach P, Beyeler C, Gerber NJ, Van der Linden SJ, Bürgi U, Fuchs WA, et al. (1989) Diffuse idiopathic skeletal hyperostosis (DISH) of the spine: a cause of back pain? A controlled study. *Rheumatology* 28: 299–303.
150. Olivieri I, D'angelo S, Cutro MS, Padula A, Peruz G, Montaruli M, et al. (2007) Diffuse idiopathic skeletal hyperostosis may give the typical postural abnormalities of advanced ankylosing spondylitis. *Rheumatology* 46: 1709–1711. <https://doi.org/10.1093/rheumatology/kem227> PMID: 17938137
151. Mader R (2002) Clinical manifestations of diffuse idiopathic skeletal hyperostosis of the cervical spine. *Seminars in Arthritis and Rheumatism* 32: 130–135. PMID: 12430101
152. Koehler PJ, Wijdicks EF (2008) Historical study of coma: looking back through medical and neurological texts. *Brain* 131: 877–889. <https://doi.org/10.1093/brain/awm332> PMID: 18208847
153. Gwyn E (2017) Acute urinary retention. *Hospital Medicine Clinics* 6: 67–78.
154. Thorne MB, Geraci SA (2009) Acute urinary retention in elderly men. *The American Journal of Medicine* 122: 815–819. <https://doi.org/10.1016/j.amjmed.2009.05.009> PMID: 19699373
155. Yoon PD, Chalasani V, Woo HH (2015) Systematic review and meta-analysis on management of acute urinary retention. *Prostate Cancer and Prostatic Diseases* 18: 297–302. <https://doi.org/10.1038/pcan.2015.15> PMID: 26195469
156. Muruganandham K, Dubey D, Kapoor R (2007) Acute urinary retention in benign prostatic hyperplasia: risk factors and current management. *Indian Journal of Urology* 23: 347–353. <https://doi.org/10.4103/0970-1591.35050> PMID: 19718286
157. Goldblatt L, Delmas V, Khoury R, Boccon-Gibod L (2007) Rétention aiguë d'urines. *Médecine d'urgence* 25-180-A-20.
158. Olapade-Olaopa EO, Morley RN, Carter CJ, Walmsley BH (1997) Diabetic cystopathy presenting as primary acute urinary retention in a previously undiagnosed young male diabetic patient. *Journal of Diabetes and its Complications* 11: 350–351. PMID: 9365877
159. Kitabchi AE, Umpierrez GE, Miles JM, Fisher JN (2009) Hyperglycemic crises in adult patients with diabetes. *Diabetes Care* 23: 1335–1343.
160. Newton CA, Raskin P (2004) Diabetic ketoacidosis in type 1 and type 2 diabetes mellitus: clinical and biochemical differences. *Archives of Internal Medicine* 164: 1925–1931. <https://doi.org/10.1001/archinte.164.17.1925> PMID: 15451769
161. Nitzan O, Elias M, Chazan B, Saliba W (2015) Urinary tract infections in patients with type 2 diabetes mellitus: review of prevalence, diagnosis, and management. *Diabetes, Metabolic Syndrome and Obesity: Targets and Therapy* 8: 129–136.
162. Ferri FF (2012) *Ferri's clinical advisor*. Philadelphia: Elsevier.
163. Pasquel FJ, Umpierrez GE (2014) Hyperosmolar hyperglycemic state: a historic review of the clinical presentation, diagnosis, and treatment. *Diabetes Care* 37: 3124–3131. <https://doi.org/10.2337/dc14-0984> PMID: 25342831
164. Stoner GD (2005) Hyperosmolar hyperglycemic state. *American Family Physician* 71: 1723–1730. PMID: 15887451
165. Salem HH, Ramsay I (1979) Hyperosmolar diabetes presenting as acute urinary retention: Report of three cases. *British Journal of Surgery* 66: 207–208. PMID: 427390
166. Christensen T (2012) *1616: the world in motion*. Berkeley: Counterpoint Press. 384 p.
167. Dawes GW (2016) *Galileo and the conflict between religion and science*. New York: Routledge. 198 p.
168. Thomsen JL, Felby S, Theilade P, Nielsen E (1995) Alcoholic ketoacidosis as a cause of death in forensic cases. *Forensic Science International* 75: 163–171. PMID: 8586340
169. Wrenn KD, Slovis CM, Minion GE, Rutkowski R (1991) The syndrome of alcoholic ketoacidosis. *The American Journal of Medicine* 91: 119–128. PMID: 1867237

170. Kadiš P, Balažic J, Marolt VF (1999) Alcoholic ketoacidosis: a cause of sudden death of chronic alcoholics. *Forensic Science International* 103: S53–S59.
171. Hockenull J, Dhillon W, Andrews R, Paterson S (2012) Investigation of markers to indicate and distinguish death due to alcoholic ketoacidosis, diabetic ketoacidosis and hyperosmolar hyperglycemic state using post-mortem samples. *Forensic Science International* 214: 142–147. <https://doi.org/10.1016/j.forsciint.2011.07.040> PMID: 21840144