



**HAL**  
open science

## Measuring chordae tension during transapical neochordae implantation: Toward understanding objective consequences of mitral valve repair

Daniel Grinberg, Pierre-Jean Cottinet, Sophie Thivolet, David Audigier, Jean-Fabien Capsal, Minh-Quyen Le, Jean-François Obadia

### ► To cite this version:

Daniel Grinberg, Pierre-Jean Cottinet, Sophie Thivolet, David Audigier, Jean-Fabien Capsal, et al.. Measuring chordae tension during transapical neochordae implantation: Toward understanding objective consequences of mitral valve repair. *Journal of Thoracic and Cardiovascular Surgery*, 2018, 10.1016/j.jtcvs.2018.10.029 . hal-02113882

**HAL Id: hal-02113882**

**<https://hal.science/hal-02113882>**

Submitted on 20 Dec 2021

**HAL** is a multi-disciplinary open access archive for the deposit and dissemination of scientific research documents, whether they are published or not. The documents may come from teaching and research institutions in France or abroad, or from public or private research centers.

L'archive ouverte pluridisciplinaire **HAL**, est destinée au dépôt et à la diffusion de documents scientifiques de niveau recherche, publiés ou non, émanant des établissements d'enseignement et de recherche français ou étrangers, des laboratoires publics ou privés.



Distributed under a Creative Commons Attribution - NonCommercial 4.0 International License

# Measuring chordae tension during transapical neochordae implantation: towards understanding objective consequences of mitral valve repair

Daniel GRINBERG, M.D.<sup>a,b,c</sup>,

Pierre-Jean COTTINET, Ph.D.<sup>b</sup>,

Sophie THIVOLET, M.D.<sup>a</sup>,

David AUDIGIER, Ph.D.<sup>b</sup>,

Jean-Fabien CAPSAL, Ph.D.<sup>b</sup>,

Minh-Quyen LE, Ph.D.<sup>b</sup>,

Jean-François OBADIA, M.D., PhD.<sup>a</sup>

## Departments and institutions

<sup>a</sup> Department of adult cardiac surgery – Hôpital cardiologique Louis Pradel – Lyon medical school -  
28, Avenue du Doyen Lépine, 69677 BRON Cedex – FRANCE

<sup>b</sup> Univ Lyon, INSA-Lyon, LGEF (Lab of electrical engineering and ferroelectricity), EA682, F-69621,  
Villeurbanne, France,

<sup>c</sup> Department of cardiovascular surgery – Mount Sinai Hospital – New York City - 1190 5th Avenue,  
10029 New York, USA

## Acknowledgements:

The authors thank Dr Anelechi Anyanwu, Young Joon KWON, MSE for their help in preparing the manuscript as well as the support from the Fulbright program and the “Federation Française de Cardiologie” Doctoral Fellowship program.

This work was also partially supported by the CIC of Hospice Civils de Lyon.

31  
32 **Conflict of interest** for this work: no conflict for any authors.

33  
34 **Disclosure:**

35 Daniel GRINBERG: N/A

36 Pierre-Jean COTTINET: N/A

37 Florent GANET: N/A

38 Matteo POZZI: N/A

39 Sophie THIVOLET: N/A

40 David AUDIGIER: N/A

41 Jean-Fabien CAPSAL: N/A

42 Minh-Quyen : N/A

43 Jean-François OBADIA :

- 44 - Resarch support: Boeringher, Saint Jude Medical, Abbott, Medtronic, Edwards –
- 45 - Consulting Fees/Honoraria: Edwards, Saint Jude Medical, Medtronic, Servier, Novartis –
- 46 - Royalty Income: Landanger, Delacroix-Chevalier

47  
48 **Funding:** private funding

49  
50  
51 **Corresponding author's complete contact information**

52 Daniel GRINBERG,  
53 Sinai BioDesign  
54 Icahn School of Medicine at Mount Sinai Hospital  
55 1428 Madison Ave, BMC-24  
56 New York NY 10029  
57 USA

58  
59 Phone: +1 (646)-683-8599

60 Fax : +1 (212)-659-6818

61 Email: [daniel.grinberg.pro@gmail.com](mailto:daniel.grinberg.pro@gmail.com) - [daniel.grinberg@mountsinai.org](mailto:daniel.grinberg@mountsinai.org)

62  
63  
64 **Clinical trial registry number:** N/A (Ethical committee certificate linked)

65  
66 **Article word count :** 3393 / 3500

67  
68 **Glossary Abbreviations**

69 MVr = Mitral valve repair

70 DMR = degenerative mitral regurgitation

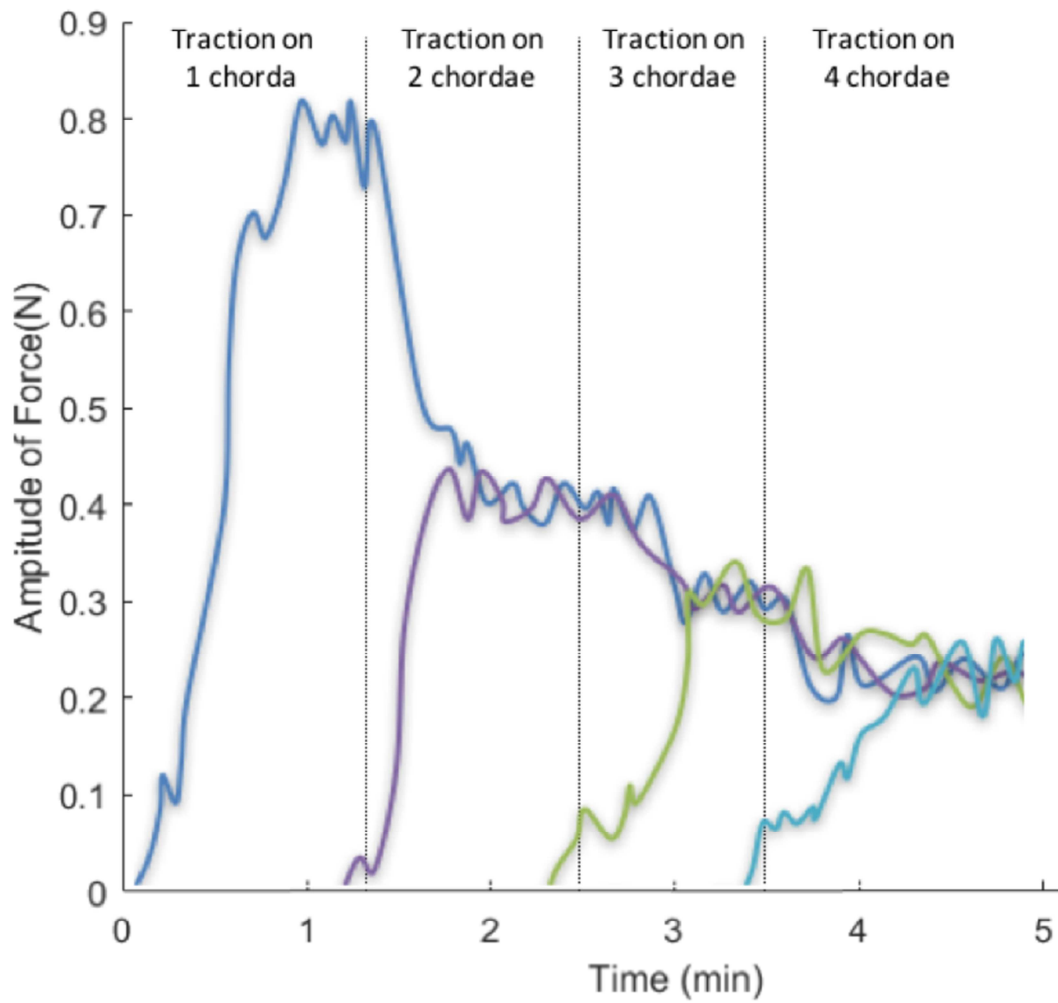
71 MR = mitral regurgitation

72 TEE = transesophageal echocardiography

73 3D-TEE = 3-dimentional TEE

74 **Central Picture** (83 characters)

75 Real-time choral tension measurements during a transapical neochordae implantation



76

77 **Central Message** (199 characters)

78 Tension applied on chordae sustaining P2 segment was 0,8 Newton and was spread homogeneously to  
79 all chordae. When normal physiology is restored, the subvalvular apparatus was in a low-stress state.

80

81 **Perspective** (382 characters)

82 We experienced a surgical strategy based on objective, quantitative parameters instead of only  
83 echocardiogram.

84 New tools are needed to explore hypotheses raised by this work.

85 The prognostic value of the measured tension has to be evaluated.

86 Our protocol is more precise and practical than the current standard for final adjustment of chordae  
87 length and could be used even without tension assessment.

88 **Structures Abstract** (250 words)

89 Objectives:

90 Complex structure of mitral valve and its central position in the heart limit assessment of mitral  
91 function to standardized calculated parameters assessed by medical imaging (echocardiography).

92 Novel techniques, which allow mitral repair (MVr) on a beating heart, offer the opportunity for  
93 innovative objective assessment in physiologic and pathologic conditions. Here we report the first  
94 data of real-time choral tension measurement during a transapical neochordae implantation.

95 Methods:

96 Seven patients with severe degenerative mitral regurgitation (DMR) due to posterior prolapse  
97 underwent transapical MVr using NeoChord®. During prolapse correction, the tension applied on the  
98 neochordae was measured; in addition to hemodynamic and echocardiographic parameters.

99 Results

100 The traction applied on one chorda sustaining the P2 segment was measured between 0.7 and 0.9  
101 Newtons, and oscillated with respiration.

102 When several neochordae were set in tension, this initial tension was spread homogeneously on each  
103 chorda (mean sum of the amplitude of tension  $0.98 \pm 0.08$  N).

104 To achieve an optimal echocardiographic correction, a complementary synchronous traction on all  
105 chordae was required. During this adjustment, the sum of the tension decreased (mean  $12 \pm 2$  %,  $p =$   
106  $.018$ ), suggesting that when normal physiology is restored, the valvular apparatus was in a low-stress  
107 state.

108 This method allowed us to apply a precise and reproducible technique, leading to a good procedural  
109 success rate with a low morbidity-mortality rate.

110 Conclusions

111 The tension applied on chordae during transapical implantation of neochordae for DMR can be  
112 measured, providing original data about the objective consequences of MVr on the mitral apparatus.

113 **I. Introduction**

114 Mitral valve repair (MVR) remains the gold standard for treating primary mitral regurgitation (MR)<sup>1</sup>.  
115 The technique has since evolved, and today the trend is to use more Gore-Tex to replace the elongated  
116 or ruptured chordae and to resect less tissue, thereby creating a larger surface of coaptation<sup>2</sup>. One of  
117 the main difficulties of this technique is to define the appropriate length of the chordae assessed on an  
118 empty non-beating heart.

119 A change of paradigm recently occurred with the introduction of novel techniques performed on  
120 beating hearts like transapical neochordae using the NeoChord DS 1000 (NeoChord Inc., Minneapolis,  
121 Minnesota, USA). These devices allow real-time adaptation of the repair thanks to an intraoperative  
122 transesophageal echocardiography (TEE) control.

123 We designed a device that enables a precise traction control on each chorda to determine the optimal  
124 length of the chordae during the NeoChord implantation, as well as measuring the tension applied on  
125 neochordae along this traction.

126 We also recorded original results on chordae tension *in vivo* that have not been previously described to  
127 our knowledge, illustrating the physiology and the pathophysiology of the mitral valve.

128

129 **II. Methods**

130 *II.1 PATIENTS*

131 Since the use of NeoChord is not yet included in international guidelines, it was only proposed to  
132 patients with severe symptomatic MR due to a posterior prolapses, involving mainly P2 segment (with  
133 a variable extension on P1 or P3, but never involving the commissures or the anterior leaflet) and  
134 considered as high-risk for conventional surgery (mainly due to frailty) after selection by our heart  
135 team.

136 Informed consent was obtained from each patient about the complete procedure and to acknowledge  
137 that their medical records will be collected in a registry.

138 This procedure has received the approval of the Ethical Committee of the French Society of  
139 Cardiology.

140 *II.2 ORIGINAL OPERATIVE TECHNIQUE*

141 The usual NeoChord implantation protocol<sup>3</sup> can be summarized as: access to the left ventricular apex;  
142 establishment of two apical purse strings for the introduction of the device after systemic  
143 heparinization; implantation of several neochordae through the free edge of the prolapsed leaflet under  
144 3-dimentional TEE (3D-TEE) control; fine adjustment of neochordae length by manual traction on  
145 each chordae to achieve the best coaptation under TEE control; fixing the chordae at the apex of the  
146 left ventricle at the predefined optimal length; protamine infusion, drainage, and closing.

147 Our conventional institutional anesthesiologic protocol was followed in order to maintain a mean  
148 blood pressure between 70 and 80 mmHg.

149 *II.3 MODIFICATION OF THE TECHNIQUE*

150 Using the original technique, the adjustment of the tension is delicate and approximate since it is  
151 performed manually.

152 To improve the safety, the precision, and the reproducibility of this adjustment, we developed and



153 patented a specific adjustment device in collaboration with a team of engineers (LGEF at INSA-Lyon)  
154 (Figure 1). The device consists of four identical units. Each unit consists of a crocodile clip system  
155 connected to a force sensor (the force range and the resolution of the load cell are  $\pm 10$  N and 0.01 N  
156 respectively) held on a manual linear axis system (micrometric leadscrew). It is, therefore, possible to  
157 independently adjust the transverse tension exerted on each chorda connected to the force device. The  
158 four units are fixed on a 120-mm-stroke-length linear table. Such a configuration enables the system  
159 to apply the same mechanical traction to all four chordae synchronously using the principal screw.  
160 The whole device remains lightweight, compact, and easy to transport.

161 Three to four NeoChords are usually required to hold the entire free-edge of the prolapsed segment,  
162 and this statement can be validated by performing a brief manual traction on all chordae under TEE  
163 control.

164 After this step the measurement tool is brought closer to the patient. The implanted neochordae are  
165 then connected to the force device through the crocodile clips.

166 The measurement procedure consisted of four steps, as follows (Table 1): (1) The chorda implanted in  
167 the best location (in the middle of the prolapse) was tracked alone until the best TEE control; (2) The  
168 other chordae were then tracked, one at a time, with an individual screw to achieve an equivalent  
169 tension on all chordae; (3) All neochordae were then tracked together under TEE control, until  
170 obtaining the optimal MVr (no residual MR, vanishing of leaflet billowing, and homogeneous and  
171 high coaptation height); (4) the chordae are then fixed at the apex of the left ventricle at the optimal  
172 length.

173 During all steps, we continuously recorded the chordae tension, electrocardiogram, radial blood  
174 pressure, 3D TEE, and surgical view (Figure 2, Video 1).

#### 175 *II.4 STATISTICAL ANALYSIS*

176 Baseline and demographic categorical variables were expressed as percentages, while quantitative  
177 variables were expressed as medians (first and third quartiles, interquartile range).

178 Chordae tensions were expressed as mean  $\pm$  standard deviation of peak-to-peak amplitude value  
179 because they are the physical parameters representing the force that sustained the mitral valve. It is  
180 therefore more relevant to know the extrema to not exceed the critical values. In addition, an average  
181 measurement is achieved in real time to avoid noise of the sensors and of the electronic conditioning.  
182 Categorical variables are presented as numbers with percentages.

183 The Wilcoxon paired test was used to compare chordal tension before and after optima correction. A  
184 P-value  $<0.05$  was considered to be significant. SPSS statistical software was used (IBM SPSS  
185 Statistics, version 24.0. Armonk, NY, USA).

186

187 **III. Results**

188 *III.1 CLINICAL RESULTS (ASIDE FROM INTRAOPERATIVE TENSION MEASUREMENTS)*

189 From 1 January 2016 to 1 September 2017, seven consecutive patients underwent transapical  
 190 neochordae implantation using the NeoChord DS 1000 (NeoChord Inc, Minneapolis, Minnesota,  
 191 USA). The characteristics and operative data of the seven patients are presented in

	All patients (n=7)	
<b>Baseline clinical data</b>		
Age	80	63 - 82
NYHA III/IV	5	(71)
Previous cardiac surgery	0	(0)
EuroSCORE 2	1,4	1,1 - 2,8
<b>Baseline Echocardiographic Data</b>		
LVEF (%)	66	57 - 68
SPAP (mmHg)	50	45 - 61
Severe MR	7	(100)
EROA (cm <sup>2</sup> )	0.51	0.47 - 0.58
Posterior prolapse	7	(100)
P2	5	(71)
P1/P2	1	(14)
P2/P3	1	(14)
volume LA (cm <sup>2</sup> )	33	27 - 36
LVDd (mm)	59,5	55 - 63
<b>Operative data</b>		
Number of neochordae implanted	3	3 - 4
Posterior localization	7	(100)
Operative time (min)	117	114 - 126
Autotransfusion volume (ml)	750	635 - 1025
Initial technical success	7	(100)
Conversion to conventional surgery	0	(0)
<b>30-day outcomes</b>		
ICU stay (days)	1	1 - 1,5
Hospital stay (days)	9	8 - 13
Discharge TTE		
None or mild MR	6	(86)
Moderate MR	1	(14)
Severe MR	0	(0)
Surgical revision for bleeding	0	(0)
Relevant Adverse Event		
Stroke	1	(14)
Perioperative infection	0	(0)
Transfusion	0	(0)

192

193 Table 2. The adjustment duration appears to have been reduced compared to the standard protocol.

194 The procedural success (defined as residual MR < Grade 2) was obtained in all patients.

195 The median per-procedural autologous autotransfusion volume (from cell-saver) was 750

196 ml (interquartile range 635-1025), and no patient required postoperative heterologous transfusion. The

197 mean hemoglobin level at discharge was 10.2 g dl<sup>-1</sup>. No perioperative infection and no deaths were

198 observed after a mean follow-up of 10 months (1–18 months).

199 During initial follow-up, one patient had an early recurrence of severe MR due to a tear in a cleft-like

200 indentation adjacent to the repaired P2 prolapse. He had a successful minimal-invasive MVr four

201 months after the NeoChord procedure.

### 202 *III.2 TENSIONS DATA DURING LENGTH ADJUSTMENT PHASE*

203 Traction of the chorda implanted in the best location until best correction (Step 1): The amplitude of

204 force increased progressively until it reached a plateau value between 0.7 and 0.9 N (Figure 3). This

205 value was similar for all patients. Interestingly in all evaluations, we noticed an oscillation in the

206 amplitude of tension of approximately 13 % that followed the respiratory cycles (Figure 3).

207 Traction of all chordae one after the other until homogeneous tension (Step 2): When we were setting

208 the tension of the chordae, one at a time, aiming to achieve the same tension in all chordae, we

209 observed a decrease in tension on chordae previously set in tension. At the end of Step 2, the tension

210 initially measured on the first chorda was divided by the number of chordae set in tension. For

211 example, when a tension of 0.8 N was observed with one chorda, it decreased to 0.2 to 0.3 N when

212 four chordae are set in tension (Figure 4).

213 At the end of Step 2 the mean of the sum of the amplitude of tension in all patients was  $0.98 \pm 0.08$  N.

214 A final adjustment under TEE control (Step 3): At this point of our protocol, some degree of

215 regurgitation usually persisted, thus requiring a final adjustment by synchronous traction on all of the

216 chordae, until optimal TEE results were achieved (no residual MR, vanishing of leaflet billowing and

217 homogeneous and high coaptation height).

218 While the initial mean of the sum of the amplitude of tension was  $0.98 \pm 0.08$  N before optimal  
219 correction of MR, it decreased gradually to  $0.87 \pm .07$  N following the correction of regurgitation,  
220 corresponding to a  $12 \pm 2$  % decrease (range: 10.3–14.1 %,  $p=,018$ ) during step 3 (Figure 5).

221

## 222 IV. Discussion

### 223 IV.1 WHAT DID WE ALREADY KNOW?

224 The study of objective physical consequences of mitral valve repair remains limited by the central  
225 position of the valve in the heart and its complex structure. To date, our knowledge about chordae  
226 tension has previously relied entirely on animal experimental models.

227 *In vitro* studies have been published using an ovine experimental model<sup>4-8</sup>. The valvular tissue is  
228 harvested *en masse* (ring, valve, and mitral sub-valvular apparatus). The valve and the papillary  
229 muscle are attached to a left ventricular simulator, which can mimic the physiological hemodynamic  
230 regimen of the left ventricle. A miniature C-shaped force transducer is sutured in the middle of a  
231 chorda. Interesting data were thus obtained, in particular concerning the differences in tension  
232 between marginal, struts, and basal chordae<sup>7</sup>. He and Lowers proposed an alternative method to  
233 reduce interference between the movements of the chordae and the valve<sup>9</sup>. This consisted of  
234 measuring the longitudinal tension of the chordae by an extrapolation of the measurement of the  
235 transverse tension of the chordae fibers. A small sensor (elliptical AFP4, Microstrain Inc., Williston,  
236 VT) is inserted within the same chordae. Both approaches remain highly experimental.

237 Few *in vivo* studies have been published using a porcine experimental model<sup>10</sup>. A dedicated in-line  
238 pre-mounted force transducer is inserted between the papillary muscle and the leaflet, and the strain  
239 gauge wire is exteriorized through the apex. This model is the one that most approaches our technique,  
240 and the measured tensions are close to the values reported here.

241 The transapical neochordae implantations allow direct measurements of the tension applied on the  
242 neochordae of a mitral valve in a human beating heart for the first time. These data, formerly  
243 inaccessible, are thus innovative.

244

245 *IV.2 WHAT DOES OUR STUDY REVEAL?*

246 Here we report data relevant to the function of the mitral subvalvular apparatus in a beating heart. Our  
247 tension measurements, recorded throughout the cardiac cycle (from prolapse to tethered chordae), led  
248 us to the following conclusions.

249

250 **THE TENSION APPLIED TO CHORDAE HOLDING ONE MITRAL SEGMENT IS RELATIVELY LOW (0,8 TO 1**  
251 **NEWTON).**

252 The stress-strain curves of a native chordae had been reported by Zuo, showing ultimate stress values  
253 around 35 MPa (equals to  $35 \text{ N mm}^{-2}$ )<sup>11</sup>. In other words, a rupture of chordae should happen if a  
254 traction is applied on a normal chorda of  $1 \text{ mm}^2$  and of a prolapsed area if the tension is 35-times  
255 superior to the physiologic traction. This is highly unlikely to happen, meaning that the ruptures of the  
256 chordae we encountered among our patients are likely a consequence of the fragility of the dystrophic  
257 chordae. Moreover, we noticed that the forces applied to the subvalvular apparatus vary with  
258 respiration. This might account for why some exceptional thoracic traumatism with the sudden  
259 increase of the intra-thoracic pressure can lead to traumatic rupture of normal chordae and acute  
260 MR<sup>12,13</sup>.

261 Gore-Tex<sup>®</sup> sutures (CV-4 or CV-5) are typically used as neochordae. The strength of these sutures is  
262 perfectly adapted as artificial chordae<sup>14</sup>.

263 The measures presented here are only valid for primary human chordae of 0.7 to 0.8 mm, and which  
264 are attached to the free edge of the leaflets. This is probably different for secondary chordae (basal  
265 chordae or strut chordae), which are thicker (1.2 to 1.3 mm) and are not involved in neochordae  
266 implantations. Our team has already reported the various functions of primary and secondary chordae,  
267 and it is important to distinguish their specific roles<sup>15</sup>.

268

269

270

271 **THE TENSION APPLIED TO CHORDAE HOLDING ONE MITRAL SEGMENT IS DIVIDED BY THE NUMBER**  
272 **OF CHORDAE SET IN TENSION.**

274 Tension decreased as the number of chordae set in tension increased. This finding, although intuitively  
275 expected, is physically confirmed here, with an almost strict mathematical correlation.

276 The spider's web-structure of the subvalvular apparatus, with numerous chordae and numerous  
277 implantation sites on the leaflets, is essential.

278 We could extrapolate that it is also necessary to use several chordae to fix a prolapse segment all  
279 along its free edge, moreover if it is a large prolapse segment. An increased number of chordae would  
280 likely make the repair less fragile and more durable.

281  
282 **THE TENSION OF THE SUBVALVULAR APPARATUS IS LOW WHEN THE CONTROL OF THE**  
283 **REGURGITATION IS OPTIMAL**

284 This is the most important finding of this study. The normal valve seems to work in a low-stress  
285 regimen. In other words, in a physiological state, the perfect systolic closure of the mitral valve with  
286 two coapted leaflets inside a 3D saddle shape annular plan corresponds to the situation with the lowest  
287 tension on the subvalvular apparatus.

288 Few physiological explanations can be suggested to explain this finding (Figure 6):

- 289 - As mentioned above, the total tension is divided by the number of chordae. After MR  
290 correction, the global tension is distributed between native and artificial chordae. Thus, the  
291 tension applied on neochordae (the only one that we can measure) is decreased.
- 292 - In the classical posterior prolapsed situation, the shape of the pathological leaflet formed a  
293 funnel, leading the blood flow toward the prolapsed area. Thus, the tension of the subvalvular  
294 apparatus of this zone is maximum.
- 295 - Because the two leaflets lean one against the other, the vertical vector of tension applied on the  
296 free edges (towards the left atrium) decrease and thus the measured tension on the primary  
297 chordae decrease.



298 The force of coaptation might increase. This hypothesis is supported by Falk et al who found  
299 that greater coaptation distance might contribute to a more durable result after repair<sup>16</sup>.

300 A part of the tension is transferred laterally, to the secondary chordae (not measured here), to  
301 the annulus and to the heart walls. Nielsen et al., also found a significant reduction of the  
302 tension on the secondary chordae after mitral ring annuloplasty, without affecting the tension  
303 on the primary chordae<sup>17</sup>.

304 - The absence of regurgitation is associated with a normal intraventricular blood flow, with a  
305 normal clockwise vortex<sup>18</sup>. The ejection flow is then directed more toward the outflow tract  
306 and less to the mitral valve lowering the chordae tension.

307 This observation gives a plausible proposition of the natural history of the primary MR. As the valve  
308 starts to leak, the tension on the chordae increases, leading to a vicious cycle and an accelerated  
309 progression of the regurgitation. Whereas restoring a large surface of coaptation increases this  
310 keystone effect, and decreases the stress on the chordae, ensuring the long-term stability of the  
311 surgical repair, as usually reported in clinical settings<sup>19-20</sup>.

312 While not directly supported by this paper, it is likely that downsizing annuloplasty leads to a greater  
313 apposition of the two leading leaflets, with the keystone effect leading to a decreased tension on the  
314 chordae.

315 While we are approaching the limits of existing tools to explore mitral valve function and the  
316 consequences of repair techniques, we are continuing to develop innovative tools (numerical  
317 simulation, medical imaging, new sensors) to assess these hypotheses.

318

319 *IV.3 CLINICAL IMPACT OF THE USE OF THE MEASURING PLATFORM*

320 In conventional surgical MVr, the only existing tool available to evaluate immediate success of a  
321 repair is the saline test (also potentially paired with an ink-test). When neochordae are implanted the  
322 length adjustment on arrested hearts relies mainly on the habits of the surgeons. Dozens of tips and  
323 tricks have been proposed<sup>21</sup>.

324 A change of paradigm recently occurred with the introduction of novel techniques performed on  
325 beating hearts like transapical neochordae implantations allowing real-time adaptation of the repair  
326 thanks to an intraoperative TEE control. It is also possible to fix the length of the chordae exactly to  
327 the optimal position; neither too long nor too short. This represents a potential advantage of  
328 transapical neochordae implantation over traditional surgical techniques.

329 This feature has been exploited in this work: additionally, to a strict morphological assessment, the  
330 plasty was optimized thanks to an objective parameter. Recent large cohort evaluating mid-term  
331 results of NeoChord reported 10% of technical failure despite initial good echocardiographic results<sup>23</sup>.

332 We can assume that for 10% of cases TEE was not sensitive enough alone in guidance for NeoChord  
333 placement and adjustment. We find that in optimal repairs chordae tension was minimum and  
334 homogeneously spread on all chordae. We can thus hypothesize that measurement of chordae tension  
335 could be use be useful in addition of TEE to insure optimal procedure. However, these beneficial  
336 characteristics remains to be validated by additional studies.

337 Finally, although our measuring device was initially developed to assess chordae tension, its use  
338 revealed interesting features for chordae length adjustment:

- 339 - Simplicity while avoiding iterative forceps manipulation on neochordae at cardiac apex,  
340 without increasing the operative time (operative time of our center with the use of the platform  
341 are similar with those reported by reference centers<sup>22</sup>). The set-up of the platform is simple.
- 342 - Precision thanks to a millimetric per-chorda or global adjustment.
- 343 - Safety thanks to permanent control of applied tension during the procedure avoiding excess  
344 traction on the frail valvular tissue.

345 Thus even without tension assessment, the use of the device may also be beneficial for safety and  
346 precision.

347

#### 348 *IV.4 LIMITATIONS OF OUR STUDY*

349 The neochordae (ePTFE CV4 GORE-TEX<sup>®</sup> suture, Gore Medical) attached to the valve comes out  
350 through the ventricle wall. The resistance of this passageway is not quantifiable, but it is probably  
351 minimal. Relative to the resistance, the length and traction direction of the neochord (from the free  
352 edge to the apex) are more important, which are different from those of the native chordae (from the  
353 free edge to the papillary muscle) (Figure 7). Even if the Neochord procedure recommends the  
354 introduction of the device as laterally as possible, we remain at some distance from the papillary  
355 muscles, and it is likely that the forces applied on the native chordae are slightly different<sup>10,24</sup>.  
356 Nevertheless, the global understanding of the sub-valvular function and its usefulness for assessment  
357 of the optimal length during this procedure remains valid.

#### 358 *IV.5 PERSPECTIVES*

359 Our findings have helped generate new hypotheses about mitral valve function, as well as raising  
360 many as yet unanswered questions.

361 Concerning clinical perspective, the prognostic value of measured tension and its ability to improve  
362 long-term success repair rate will be obtained thanks to the prospective follow-up of this cohort. In  
363 our center, the platform is used for all implantations. We are currently pursuing the optimization of the  
364 platform before its duplication to allow its assessment by other expert teams.

365 Concerning experimental perspectives, we reached some limits of our clinical model. *Ex-vivo* studies  
366 are currently performed to compare the different technologies for chordae tension measurement as  
367 well as measuring the impact of the differences in axis and length of neochordae implanted  
368 transapically compared to the conventional implantation. Larger project involving multiple  
369 technologies (medical imaging, numerical simulation) are required to better understand the changes in  
370 structure and flow occurring during transapicale neochordae implantations.

371 From a more global perspective, in conventional surgical repairs many different repairs techniques are  
372 continuously described, and multiple prosthetic devices are available (e.g. band, rigid annuloplasty  
373 ring, etc). Nonetheless, morphologic assessment tools failed to determine the best surgical options and  
374 the surgeon's expertise primes above objective concrete data.

375 New beating heart valve treatments have already grown in popularity as devices and quality of the 3D  
376 images improved. Percutaneous repair techniques have a single anatomical target, in opposition to the  
377 conventional surgery that often deals with multiple repair actions. Combo procedures appears  
378 promising. But as for conventional surgery, the role of annuloplasty to other techniques remains to be  
379 determined as well as the criteria for their implantations.

380 Original measuring tools allowing real-time intraoperative measurement (in addition to standard  
381 morphologic evaluation) could increase our capacity to treat patients with customized techniques  
382 guided by objective data during surgical and percutaneous interventions.

383

384 **V. Conclusion**

385 Transapical neochordae implantation conducted on a beating and functional heart, provides an  
386 excellent model for *in vivo* study of the tension forces on neochordae. This work brings original and  
387 useful data concerning the physiopathology of the sub-valvular apparatus: the tension applied on  
388 human chordae to sustain P2 segment of mitral posterior leaflet is low (1 Newton); this tension is  
389 divided by the number of chordae holding this segment; during MVr the lowest tension on all  
390 neochordae is observed when the control of the regurgitation is optimal. Such advances help to better  
391 understand MVr and, consequently, may play a role in the future treatment of MV disease.  
392 Along with this objective assessment, the tool developed allows a safe precise and reproducible  
393 procedure.


394 **References**

- 395
- 396 1. Carpentier A. Cardiac valve surgery--the "French correction". *J Thorac Cardiovasc Surg.*
- 397 1983;86(3):323-337. <http://www.ncbi.nlm.nih.gov/pubmed/6887954>.
- 398 2. Tourmousoglou C, Lalos S, Dougenis D. Mitral valve repair of isolated posterior leaflet prolapse: resect
- 399 or respect? *Interact Cardiovasc Thorac Surg.* 2014;19(6):1027-1035. doi:10.1093/icvts/ivu279
- 400 3. Colli A, Zucchetta F, Torregrossa G, et al. Transapical off-pump mitral valve repair with Neochord
- 401 Implantation ( TOP-MINI ): step-by-step guide. 2015;4(Mc):295-297. doi:10.3978/j.issn.2225-
- 402 319X.2015.05.01
- 403 4. Siefert AW, Rabbah J-PM, Pierce EL, Kunzelman KS, Yoganathan AP. Quantitative Evaluation of
- 404 Annuloplasty on Mitral Valve Chordae Tendineae Forces to Supplement Surgical Planning Model
- 405 Development. *Cardiovasc Eng Technol.* 2014;5(1):35-43. doi:10.1007/s13239-014-0175-9
- 406 5. Jimenez JH, Soerensen DD, He Z, Ritchie J, Yoganathan AP. Mitral valve function and chordal force
- 407 distribution using a flexible annulus model: an in vitro study. *Ann Biomed Eng.* 2005;33(5):557-566.
- 408 <http://www.ncbi.nlm.nih.gov/pubmed/15981857>.
- 409 6. Jimenez JH, Soerensen DD, He Z, Ritchie J, Yoganathan AP. Effects of papillary muscle position on
- 410 chordal force distribution: an in-vitro study. *J Heart Valve Dis.* 2005;14(3):295-302.
- 411 <http://www.ncbi.nlm.nih.gov/pubmed/15974521>.
- 412 7. Nielsen SL, Soerensen DD, Libergren P, Yoganathan AP, Nygaard H. Miniature C-shaped transducers
- 413 for chordae tendineae force measurements. *Ann Biomed Eng.* 2004;32(8):1050-1057.
- 414 <http://www.ncbi.nlm.nih.gov/pubmed/15446501>.
- 415 8. Nielsen SL, Nygaard H, Fontaine AA, et al. Chordal force distribution determines systolic mitral leaflet
- 416 configuration and severity of functional mitral regurgitation. *J Am Coll Cardiol.* 1999;33(3):843-853.
- 417 <http://www.ncbi.nlm.nih.gov/pubmed/10080490>.
- 418 9. He Z, Jowers C. A novel method to measure mitral valve chordal tension. *J Biomech Eng.*
- 419 2009;131(1):014501. doi:10.1115/1.3005160
- 420 10. Jensen H, Jensen MO, Waziri F, et al. Transapical neochord implantation: Is tension of artificial chordae
- 421 tendineae dependent on the insertion site? *J Thorac Cardiovasc Surg.* 2014;148(1):138-143.
- 422 doi:10.1016/j.jtcvs.2013.07.068
- 423 11. Zuo K, Pham T, Li K, Martin C, He Z, Sun W. Characterization of biomechanical properties of aged
- 424 human and ovine mitral valve chordae tendineae. *J Mech Behav Biomed Mater.* 2016;62:607-618.
- 425 doi:10.1016/j.jmbbm.2016.05.034
- 426 12. Luecke T, Pelosi P. Clinical review: Positive end-expiratory pressure and cardiac output. *Crit Care.*
- 427 2005;9(6):607-621. doi:10.1186/cc3877
- 428 13. Santamore WP, Bove AA, Heckman JL. Right and left ventricular pressure-volume response to positive
- 429 end-expiratory pressure. *Am J Physiol.* 1984;246:H114-H119.
- 430 14. Dang MC, Thacker JG, Hwang JCS, Rodeheaver GT, Melton SM, Edlich RF. Some Biomechanical
- 431 Considerations of Polytetrafluoroethylene Sutures. *Arch Surg.* 1990;125(5):647-650.
- 432 doi:10.1001/archsurg.1990.01410170095020

- 433 15. Obadia JF, Casali C, Chassignolle JF, Janier M. Mitral subvalvular apparatus: different functions of  
434 primary and secondary chordae. *Circulation*. 1997;96(9):3124-3128.  
435 doi:https://doi.org/10.1161/01.CIR.96.9.3124
- 436 16. Falk V, Seeburger J, Czesla M, et al. How does the use of polytetrafluoroethylene neochordae for  
437 posterior mitral valve prolapse (loop technique) compare with leaflet resection? A prospective  
438 randomized trial. *J Thorac Cardiovasc Surg*. 2008;136(5):1205; discussion 1205-6.  
439 doi:10.1016/j.jtcvs.2008.07.028
- 440 17. Nielsen SL, Lomholt M, Johansen P, Hansen SB, Andersen NT, Hasenkam JM. Mitral ring annuloplasty  
441 relieves tension of the secondary but not primary chordae tendineae in the anterior mitral leaflet. *J*  
442 *Thorac Cardiovasc Surg*. 2011;141(3):732-737. doi:10.1016/j.jtcvs.2010.05.011
- 443 18. Nakashima K, Itatani K, Kitamura T, et al. Energy dynamics of the intraventricular vortex after mitral  
444 valve surgery. *Heart Vessels*. 2017;0(0):1-7. doi:10.1007/s00380-017-0967-6
- 445 19. David TE, Armstrong S, McCrindle BW, Manlhiot C. *Late Outcomes of Mitral Valve Repair for Mitral*  
446 *Regurgitation Due to Degenerative Disease.*; 2013. doi:10.1161/CIRCULATIONAHA.112.000699
- 447 20. Lazam S, Vanoverschelde J-L, Tribouilloy C, et al. Twenty-Year Outcome After Mitral Repair Versus  
448 Replacement for Severe Degenerative Mitral Regurgitation: Analysis of a Large, Prospective,  
449 Multicenter, International Registry. *Circulation*. 2017;135(5):410-422.  
450 doi:10.1161/CIRCULATIONAHA.116.023340
- 451 21. Ibrahim M, Rao C, Athanasiou T. Artificial chordae for degenerative mitral valve disease: critical  
452 analysis of current techniques. *Interact Cardiovasc Thorac Surg*. 2012;15(6):1019-1032.  
453 doi:10.1093/icvts/ivs387
- 454 22. Colli A, Bagozzi L, Banchelli F, et al. Learning curve analysis of transapical NeoChord mitral valve  
455 repair†. *Eur J Cardio-Thoracic Surg*. 2018;54(July):273-280. doi:10.1093/ejcts/ezy046
- 456 23. Colli A, Manzan E, Aidietis A, et al. An early European experience with transapical off-pump mitral  
457 valve repair with NeoChord implantation†. *Eur J Cardio-Thoracic Surg*. 2018;0(May):1-7.  
458 doi:10.1093/ejcts/ezy064
- 459 24. Caimmi PP, Sabbatini M, Fusaro L, Borrone A, Cannas M. A study of the mechanical properties of  
460 ePTFE suture used as artificial mitral chordae. *J Card Surg*. 2016;31(8):498-502.  
461 doi:10.1111/jocs.12799
- 462  
463

464 **VI. Figures and tables**

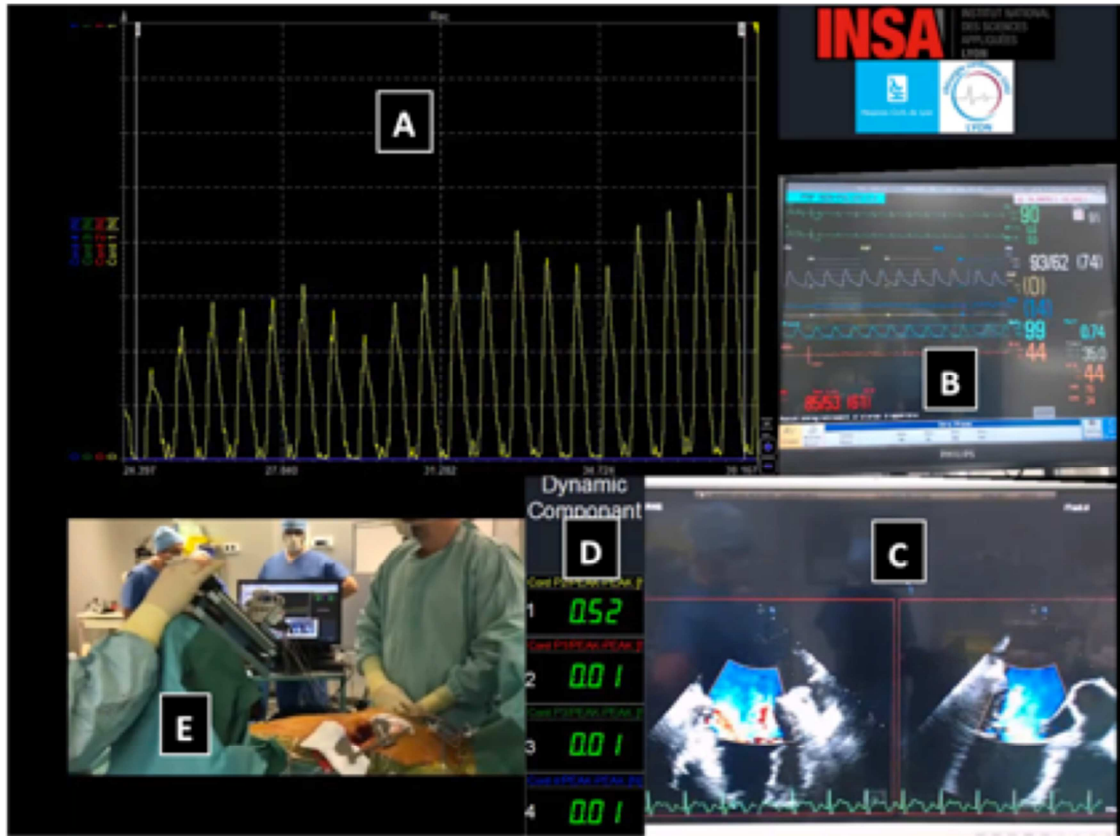
465



466

467 **Figure 1. The novel chordae tension measuring device** allows the assessment of tension applied on neochordae during a  
468 transapical implantation. This pictures shows the platform after fixation of three neochordae. Each neochordae is attached  
469 to a piezo-resistive sensor thanks to a crocodile clip. The micrometer screw system allows pulling of each chordae one  
470 after the other or all simultaneously.





471

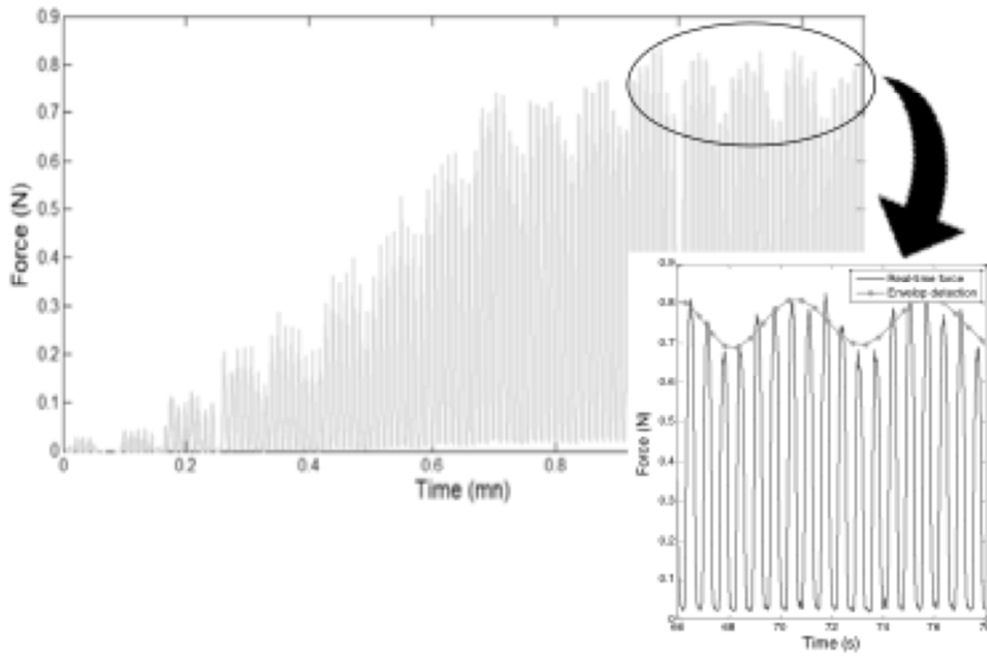
472

473

474

475

Figure 2. The intraoperative screen control shows simultaneously: Chordae tension curve (A) ; Hemodynamic parameters (B) ; Trans-Esophageal Echocardiography X-plan view (C) ; Chordae tension value for each sensors (D) ; and Operative View (E). These screenshot was taken during Step 1 of the procedure : a single chorda was pulled, and the tension increased progressively (yellow curve, value 0.52 N).

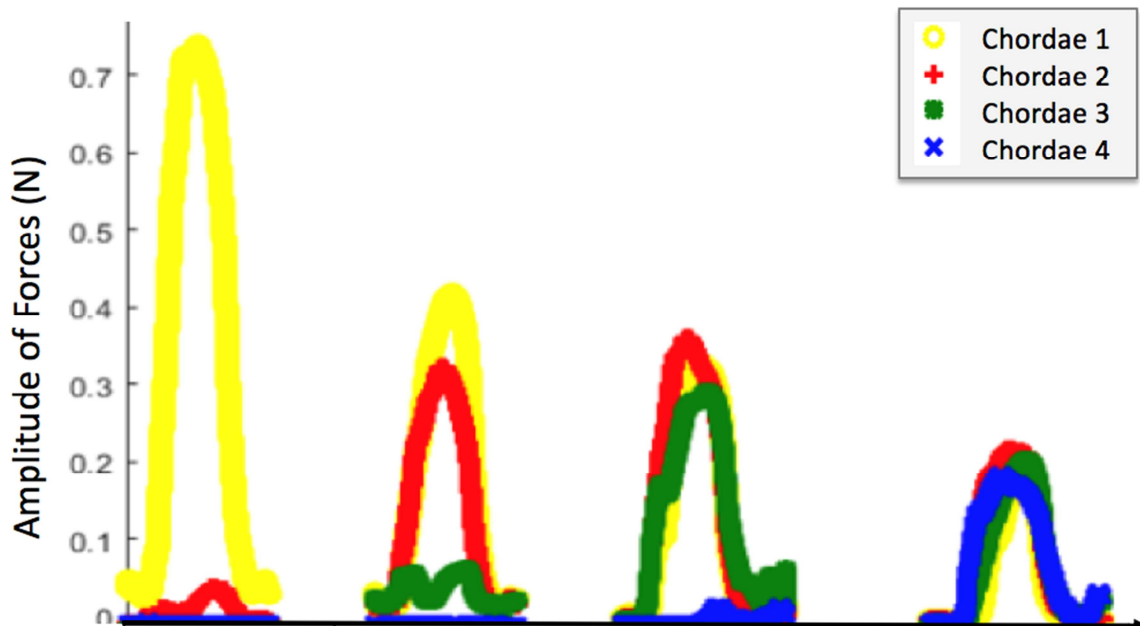


476

477 **Figure 3. The amplitude of tension during Step 1 of the protocol:** we started pulling the first chordae implanted in the  
 478 middle of the prolapse zone. During this traction the amplitude of tension increased until it reached a plateau value  
 479 between 0.7 and 0.9 N. The tension oscillated, and the oscillation corresponded to the mechanical ventilation.

480

481



	Step 1	Step 2		
	Traction on a 1 <sup>st</sup> chordae	Consecutively traction on a 2 <sup>nd</sup> chordae	Consecutively traction on a 3 <sup>rd</sup> chordae	Consecutively traction on a 4 <sup>th</sup> chordae
AOT in chord 1 (yellow)	0.79	0.41	0.35	0.21
AOT in chord 2 (red)	0	0.39	0.32	0.24
AOT in chord 3 (green)	0	0	0.30	0.22
AOT in chord 4 (blue)	0	0	0	0.20

482

483

484

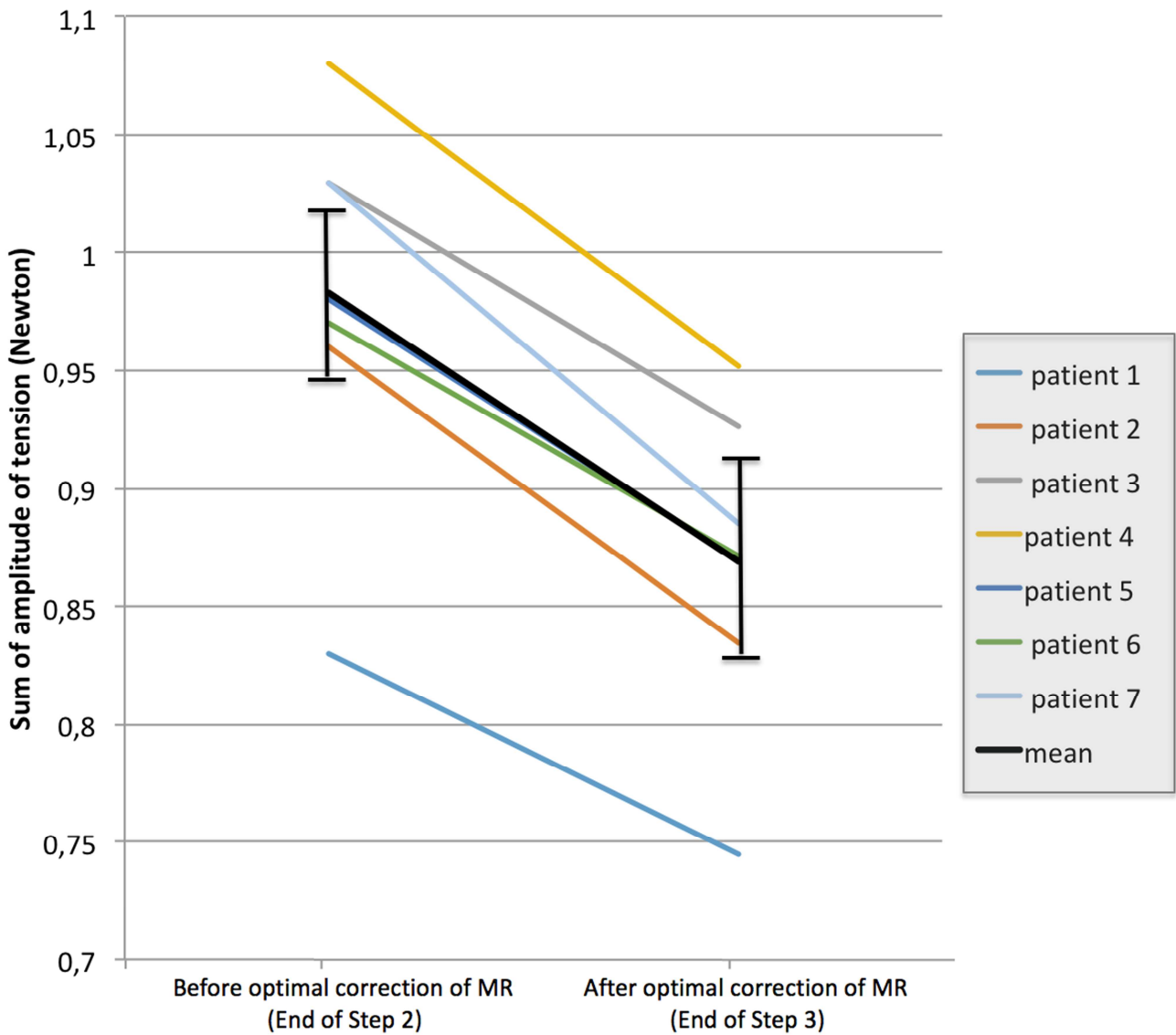
485

Figure 4. Schematic representation of the evolution of Amplitude Of Tension (AOT, in Newton) in chordae during Step 2: While pulling the first chorda (yellow), the amplitude of tension was 0.79 N. The other chordae were then pulled consecutively. At the end of this phase the initial tension was divided by the total number of chordae set in tension.

486

487

488



489

490

**Figure 5. The sum of tension on all chordae before and after obtaining of an optimal echocardiographic correction**

491

**(Step 3).** When all chordae were pulled to distribute tension equally to each chorda, a residual MR or a billowing might

492

persist, and an additional fine simultaneous traction on all chordae was required. After achieving a perfect

493

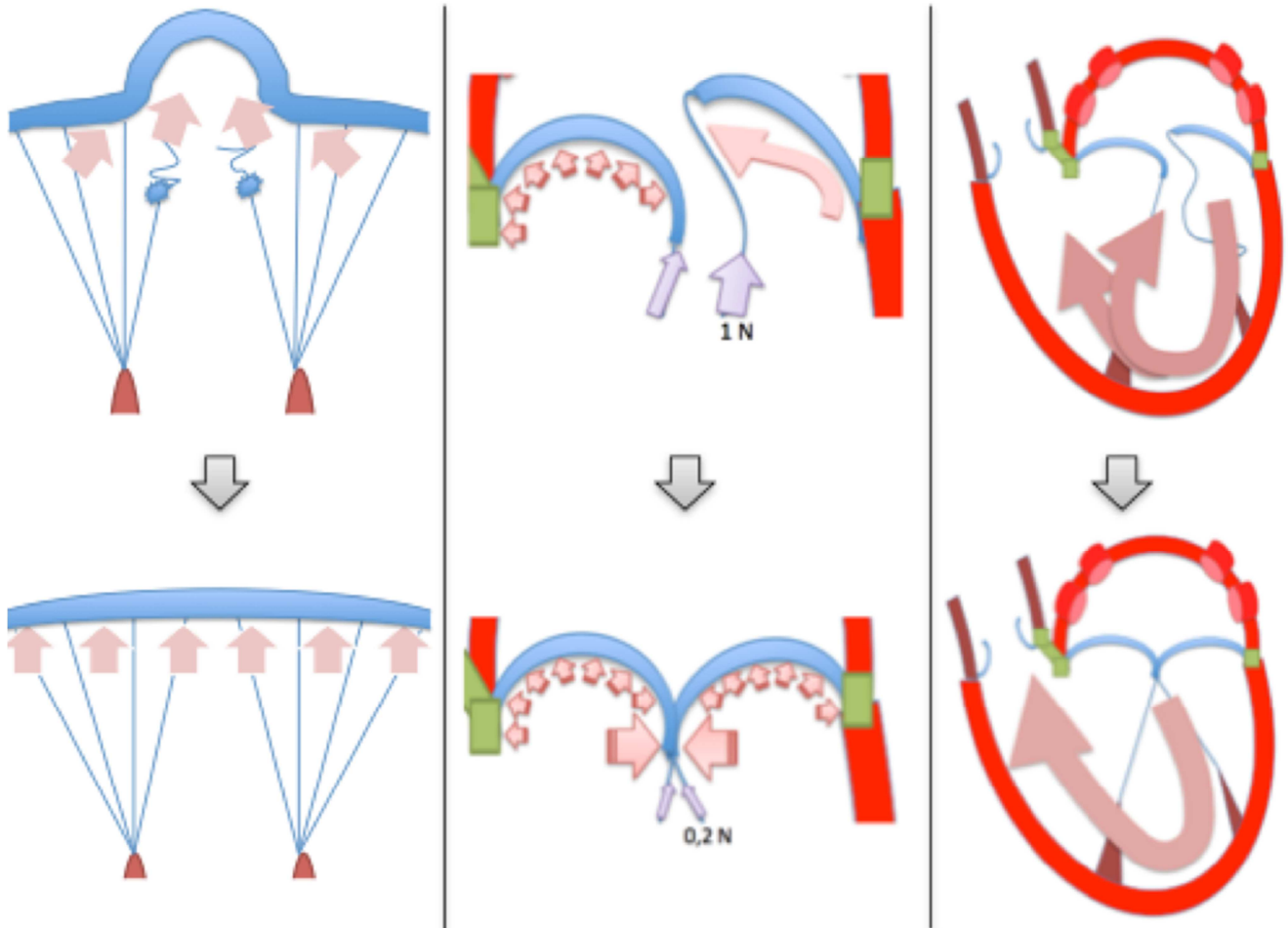
echocardiographic results, the mean sum of amplitude of tension decreased from  $0.98 \pm 0.08$  to  $0.87 \pm 0.07$  N,

494

corresponding to significant reduction of  $12 \pm 2\%$  ( $p = .018$ ). In a “physiological-like” state, the subvalvular apparatus

495

was in a low-stress state.



496

497

**Figure 6. Hypotheses explaining the change in chordae tension under normal and pathological states.**

498

Three main hypotheses may participate to the reduction in total chordal tension occurring during the fine adjustment of

499

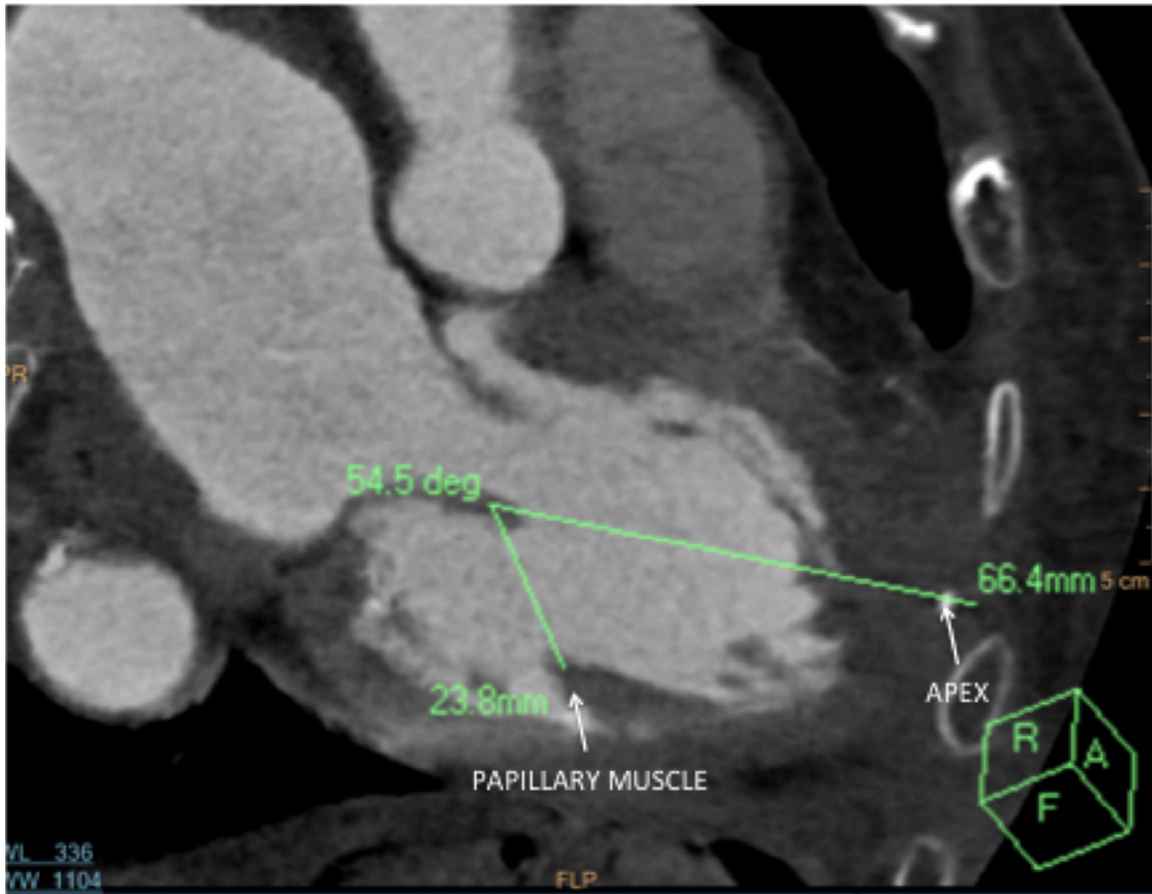
chordae traction: The loss of “funnel effect” directing the flow towards the prolapse zone (left); The mutual abutment of

500

the leaflets edge-to-edge with a “key-stone effect” (middle); and the return to normal clockwise intraventricular vortex

501

with an ejection flow directed toward the outflow tract and no toward mitral leaflets (right).



**Figure 7. Difference in axis between native chordae and transapical neochordae.**

In this case the apical neochordae insertion site was marked with a metal clip during the procedure. A postoperative CT-scan was performed allowing the visualization of the free edge of the posterior leaflet, the summit of the posterior papillary muscle, and the apex. The angle of the native chordae (between the papillary muscle and the free edge of the leaflet) and the neochordae (between the clip and the free edge of the leaflet) was 54°. The length of the native chordae was also shorter than that of the neochordae.

Step 1	Traction of the chorda implanted in the best location until best correction
Step 2	Traction of all chordae one after the other until homogeneous tension
Step 3	Synchronous traction until optimal TEE correction
Step 4	Fixation of the chordae at the apex of the left ventricle at the optimal length

**Table 1- Steps of the measurement protocol**