



## Five-year outcomes of the First Distal Uninstrumented Vertebra after posterior fusion for Adolescent Idiopathic Scoliosis Lenke 1 or 2

Jean-Luc Clément, Frederico Solla, Antoine Tran, Christian Morin, Walid Lakhal, Jérôme Sales de Gauzy, Julien Leroux, Jean-Marie Gennari, François-Henri Parent, Gaby Kreichati, et al.

### ► To cite this version:

Jean-Luc Clément, Frederico Solla, Antoine Tran, Christian Morin, Walid Lakhal, et al.. Five-year outcomes of the First Distal Uninstrumented Vertebra after posterior fusion for Adolescent Idiopathic Scoliosis Lenke 1 or 2. *Orthopaedics & Traumatology: Surgery & Research*, 2017, 103 (5), pp.727-731. 10.1016/j.otsr.2017.04.006 . hal-02100386

**HAL Id: hal-02100386**

**<https://hal.science/hal-02100386>**

Submitted on 15 Apr 2019

**HAL** is a multi-disciplinary open access archive for the deposit and dissemination of scientific research documents, whether they are published or not. The documents may come from teaching and research institutions in France or abroad, or from public or private research centers.

L'archive ouverte pluridisciplinaire **HAL**, est destinée au dépôt et à la diffusion de documents scientifiques de niveau recherche, publiés ou non, émanant des établissements d'enseignement et de recherche français ou étrangers, des laboratoires publics ou privés.




## Open Archive Toulouse Archive Ouverte (OATAO)

OATAO is an open access repository that collects the work of Toulouse researchers and makes it freely available over the web where possible.

This is an author-deposited version published in: <http://oatao.univ-toulouse.fr/Eprints> ID: 23131

**To link to this article:** DOI:10.1016/j.otsr.2017.04.006

URL: <https://doi.org/10.1016/j.otsr.2017.04.006>

**To cite this version:** Clément, Jean-Luc and Solla, Frederico and Tran, Antoine and Morin, Christian and Lakhal, Walid and Sales de Gauzy, Jérôme  and Leroux, Julien and Gennari, Jean-Marie and Parent, François-Henri and Kreichati, Gaby and Wolf, Stéphane and Obeid, Ibrahim *Five-year outcomes of the First Distal Uninstrumented Vertebra after posterior fusion for Adolescent Idiopathic Scoliosis Lenke 1 or 2.* (2017) Orthopaedics & Traumatology: Surgery & Research, 103 (5). 727-731. ISSN 1877-0568

Any correspondence concerning this service should be sent to the repository administrator: [staff-oatao@listes-diff.inp-toulouse.fr](mailto:staff-oatao@listes-diff.inp-toulouse.fr)

# Five-year outcomes of the First Distal Uninstrumented Vertebra after posterior fusion for Adolescent Idiopathic Scoliosis Lenke 1 or 2<sup>☆</sup>

J.-L. Clément<sup>a,\*</sup>, F. Solla<sup>a</sup>, A. Tran<sup>a</sup>, C. Morin<sup>b</sup>, W. Lakhal<sup>c</sup>, J. Sales de Gauzy<sup>d</sup>, J. Leroux<sup>e</sup>, J.-M. Gennari<sup>f</sup>, F.-H. Parent<sup>g</sup>, G. Kreichati<sup>h</sup>, S. Wolf<sup>i</sup>, I. Obeid<sup>j</sup>

<sup>a</sup> Hôpitaux pédiatriques de Nice, CHU Lenval, 57, avenue de la Californie, 06200 Nice, France

<sup>b</sup> Institut Calot, rue du Dr-Calot, 68608 Berck-sur-Mer, France

<sup>c</sup> Hôpital Clocheville, 49, boulevard Béranger, 37000 Tours, France

<sup>d</sup> Hôpital d'enfants, 330, avenue de Grande-Bretagne, 31300 Toulouse, France

<sup>e</sup> Hôpital Charles-Nicolas, 1, rue de Germont, 76031 Rouen, France

<sup>f</sup> Hôpital Nord, chemin des Bourrely, 13045 Marseille, France

<sup>g</sup> Centre du rachis, 6, rue de Bellinière, 49800 Trelaze, France

<sup>h</sup> Hôtel-Dieu de France Hospital, boulevard Alfred-Naccache, Achrafieh, Beirut, Lebanon

<sup>i</sup> Hôpital Saint-Joseph, 185, rue Raymond-Losserand, 75014 Paris, France

<sup>j</sup> Hôpital Pellegrin, place Amélie-Raba-Léon, 33076 Bordeaux, France

## Keywords:

Adolescent idiopathic scoliosis  
Posterior fusion  
Angulation of the first non-instrumented vertebra  
Lowest instrumented vertebra  
Last touched vertebra  
Loss of correction

**Background:** Tilt of the First Distal Uninstrumented Vertebra (FDUV) reflects changes in the main curve and compensatory lumbar curve after posterior fusion to treat thoracic Adolescent Idiopathic Scoliosis (AIS).

**Hypothesis:** FDUV tilt 5 years or more post-fusion depends chiefly on reduction of the main curve and on other factors such as selection of the last instrumented vertebra.

**Material and method:** A multicenter retrospective cohort of 182 patients with Lenke 1 or 2 AIS treated with posterior instrumentation and followed up for a mean of 8 years and a minimum of 5 years was studied. The patients were divided into two groups based on whether tilt of the upper endplate of the FDUV was  $\leq 5^\circ$  or  $> 5^\circ$  at last follow-up. Variables associated with tilt were identified by multiple logistic regression.

**Results:** Six variables were significantly associated with FDUVtilt: percentage of correction at last follow-up, correction loss, lumbar modifier B, number of instrumented vertebrae, inclusion within the instrumentation of the distal neutral vertebra, and inclusion within the instrumentation of the lowest vertebra intersected by the central sacral vertical line.

**Discussion and conclusion:** The main variables associated with FDUVtilt  $\leq 5^\circ$  were a final correction percentage  $\geq 60\%$  and absence of correction loss between the postoperative period and last follow-up. Given the stable reduction provided by contemporary instrumentations, we recommend selective thoracic fusion of Lenke 1 or 2 AIS with lumbar modifiers A, B, and C. The lowest instrumented vertebra should be either the neutral vertebra or the vertebra intersected by the central sacral vertical line if it is distal to the neutral vertebra.

**Level of evidence IV:** Retrospective multicenter study.

## 1. Introduction

Advances in spinal instrumentation systems have significantly improved the surgical correction of Adolescent Idiopathic Scoliosis (AIS). The treatment objectives remain the same: to correct the deformity, to achieve good spinal balance in the coronal and sagittal planes, and to prevent worsening of the instrumented and non-instrumented curves.

Preserving lumbar mobility is also an objective in patients with Lenke 1 or 2 AIS. Correction of the main curve results in spontaneous

<sup>☆</sup> This study was performed under the aegis of the *Groupe d'Étude de la Scoliose* round table discussion in March 2015.

\* Corresponding author. Hôpitaux pédiatriques de Nice, CHU Lenval, 57, avenue de la Californie, 06200 Nice, France.

E-mail addresses: [clement.jluc@wanadoo.fr](mailto:clement.jluc@wanadoo.fr),

correction of the compensatory non-instrumented lumbar curve, which can however progress subsequently [1–3]. Optimal selection of the Lowest Instrumented Vertebra (LIV) is crucial. Based on a study of 42 patients with thoracic AIS, Suk et al. recommended selecting the Neutral Vertebra (NV) when it was the same or one level distal to the End Vertebra (EV) of the main curve and NV-1 if more than two levels separated the EV from the NV [4]. Wang et al. suggested selecting EV + 1 as the LIV [5] and Matsumoto et al., the Last Touched Vertebra (LTV) defined as the lowest vertebra intersected by the Central Sacral Vertical Line (CSVL) [6]. Miyanji et al. distinguished two curve patterns based on the direction of the L4 tilt [7]. Sarlak et al. argued for selecting the EV as the LIV [8], whereas Takahashi et al. [9] recommended choosing the level immediately below the stable vertebra.

These studies describe the strategies used by their authors, with the outcomes assessed after only 2 years. Clearly, there is no consensus. Nevertheless, there is general agreement that LIV selection is crucial to ensure optimal curve outcomes. It should be borne in mind that 2 years is too short for definitive prognostic conclusions.

We selected the tilt of the first distal non-instrumented vertebra (*FDUVtilt*) as a marker for curve outcomes. The objective of this study was two-fold: to identify the variables associated with *FDUVtilt* 5 years after instrumentation and to determine criteria for selecting the LIV.

## 2. Materials and methods

### 2.1. Patients

The study was approved by the appropriate ethics committee (*Commission de Protection des Personnes*) and by the French Data Protection Authority (*Commission Nationale de l'Informatique et des Libertés*).

The 10 participating centres included a total of 182 patients (156 females and 26males) who underwent posterior instrumentation to treat Lenke 1 ( $n = 141$ ) or Lenke 2 ( $n = 41$ ) AIS, at a mean age of 14.8 years and were then followed-up for at least 5 years (mean, 8.3 years). The lumbar modifier was A in 111 patients, B in 31 patients, and C in 40 patients. At last follow-up, completed Scoliosis Research Society health-related quality of life questionnaires (SRS-30) were collected from 115 patients.

### 2.2. Operative techniques

Hybrid hook-screw instrumentation was used in most patients. The mean number of instrumented vertebrae was 10.6 and the mean number of anchors was 11.7, yielding an implant density of 55%.

The LIV was between T11 and L4. Selective thoracic fusion was performed in 169 patients. The instrumentation was extended to the lumbar spine in 15 patients with B or C lumbar modifiers.

**Table 2**

Preoperative angulation, reducibility, and percentage of correction in the two groups defined based on tilt of the first distal uninstrumented vertebra.

182 AIS Lenke 1 or 2	All	FDUV – 5°	FDUV + 5°	<i>P</i> value univariate	<i>P</i> value multivariate
Preop. main curve angulation (°)	54°	53°	54°	NS	NS
Initial correction (%)	60%	62%	59%	NS	NS
Final correction (%)	54%	60%	51%	0.0016	0.026
Loss of correction (%)	6%	2%	8%	0.0035	0.03
Reducibility of main curve (bending)	48%	47%	49%	NS	NS
Preop. lumbar curve angulation (°)	30°	31°	30°	NS	NS

AIS: Adolescent Idiopathic Scoliosis; FDUV: First Distal Uninstrumented Vertebra; Preop.: preoperatively.

**Table 1**

Distribution of the patients between the two groups defined based on tilt of the first distal uninstrumented vertebra.

182 AIS Lenke 1 or 2	FDUV – 5°	FDUV + 5°	<i>P</i> value
Patients	64 (35%)	118 (65%)	
FDUVtilt postop. (°)	3.5°	7.6°	<0.0001
FDUVtilt at last FU (°)	2.7°	11.5°	<0.0001
Change from postop/to last FU	– 0.8°	+ 3.9°	<0.0001

AIS: Adolescent Idiopathic Scoliosis; FDUV: First Distal Uninstrumented Vertebra; FDUVtilt: tilt of the First Distal Uninstrumented Vertebra, in degrees (°); postop.: postoperatively; FU: Follow-Up.

### 2.3. Study variables

Anteroposterior and lateral radiographs were obtained preoperatively, postoperatively, and at last follow-up. The clinical and radiographic data were entered into the KEOPS-Spine database [10]. The measurements were then performed automatically by the Keops-Analyzer software after a senior surgeon (JLC) identified each vertebra, as well as the NV of the main curve and the LTV. The position of the LIV relative to the NV was recorded as follows: NV-1 if the LIV was the vertebra immediately cephalad to the NV, NV-2 if the LIV was the second vertebra cephalad to the NV, NV + 1 and NV + 2 if the LIV was the first or second vertebra distal to the NV, and so on. The same notation was used to record the position of the LIV relative to the LTV.

The primary outcome measure was *FDUVtilt* at last follow-up. The patients were divided into two groups depending on whether *FDUVtilt* was  $\leq 5^\circ$  (64 patients, 35%, FDUV-5° group) or  $> 5^\circ$  (118 patients, 65%, FDUV + 5° group) (Table 1). All clinical and radiographic variables were analysed in these two groups.

### 2.4. Statistical analyses

SAS version 9.0 software (SAS Institute, Cary, NC, USA) was used for the statistical analyses. Means were compared by applying the Wilcoxon test or Student test and percentages by applying the chi-square test. Pearson's test was chosen to assess correlations among study variables. Based on the results of the univariate analysis, published data, and personal opinion, 13 variables were selected as potentially relevant and used to build a multiple logistic regression model. Values of *P* lower than 0.05 were taken to indicate significant differences.

## 3. Results

### 3.1. Study variables in the two groups

The percentage of correction of the main curve at last follow-up was 60% in the FDUV-5° group and 51% in the FDUV + 5° ( $P = 0.0016$ ) (Table 2). Loss of correction between the postoperative evaluation and last follow-up was 2% in the FDUV-5° group and 8% in the FDUV + 5° group ( $P = 0.0035$ ). The two groups were not significantly different regarding the preoperative angle of the main curve or distal lumbar compensatory curve, curve

**Table 3**

Distribution of lumbar modifiers in the twogroups defined based on tilt of the First Distal Uninstrumented Vertebra.

Lumbar modifier	All (n = 182)	FDUV- 5° (n = 64)	FDUV + 5° (n = 118)	P value chi <sup>2</sup>
A	111	30 (27%)	81 (73%)	0.016
B	31	15 (48%)	16 (52%)	
C	40	19 (47%)	21 (53%)	

FDUV: First Distal Uninstrumented Vertebra.

**Table 4**

Distribution of patients according to the location of the last instrumented vertebra relative to the neutral vertebra and last touched vertebra.

Location of LIV	Global	VNID- 5°	VNID + 5°	P value chi <sup>2</sup>
NV-1 or NV-2	29	6 (20%)	23 (79%)	0.045
NV or NV + 1	117	40 (34%)	77 (65%)	
NV + 2	21	11 (52%)	10 (48%)	
NV + 3 and NV + 4	15	7 (46%)	8 (53%)	0.03
LTV negative	25	4 (16%)	21 (84%)	
LTV or LTV positive	157	60 (38%)	97 (62%)	

LIV: Last Instrumented Vertebra; NV: Neutral Vertebra; LTV: Last Touched Vertebra defined as the last vertebra intersected by the central sacral vertical line.

**Table 5**

Results of the multivariate analysis of factors associated with tilt of the first distal instrumented vertebra at a mean of 8 years after surgery.

Significant factors	P value	Odds ratio	Confidence interval
B lumbar modifier	0.007	0.04	0.006; 0.272
Number of instrumented vertebrae	0.035	0.541	0.305; 0.957
Correction at last follow-up	0.026	0.007	0.001; 0.556
Loss of correction	0.008	0.03	0.002; 0.398

reducibility on lateral-bending radiographs, or initial percentage of correction.

Mean number of anchors was 13 in the FDUV-5° group and 11 in the FDUV + 5° group ( $P=0.04$ ). The number of instrumented vertebrae was 11 in the FDUV-5° group and 10 in the FDUV + 5° group ( $P=0.006$ ). Implant density, which was not significantly different between the two groups, correlated positively with the percentage of correction ( $P<0.00001$ ) and negatively with correction loss ( $P=0.0001$ ).

The proportion of patients with the A lumbar modifier was higher in the FDUV + 5° group (73%) than in the FDUV-5° (27%) group, and the opposite was true for the proportions of patients with the B or C modifier (Table 3).

Among patients whose LIV was NV-1 or NV-2, 79% were in the FDUV + 5° group. On the other hand, among patients whose LIV was NV or NV +, the proportion with FDUV-5° was higher than when the LIV was at other levels ( $P=0.045$ ).

When the LIV was above the LTV, the proportion of FDUV + 5° patients was 84% ( $P=0.03$ ) (Table 4).

### 3.2. Results of the multivariate analysis

Four variables showed significant and independent associations with FDUVtilt (Table 5).

No significant differences were found between the two groups for any of the other study variables including presence or absence of a neutral disc determined by closure of the first non-instrumented disc on the preoperative lateral-bending radiographs, spinal alignment in the coronal and sagittal planes, and sagittal parameters.

The analysis of the 115 available SRS 30 quality-of-life questionnaires showed no significant difference between the two groups.

## 4. Discussion

### 4.1. Study rationale

The 5° FDUVtilt cut-off chosen to separate satisfactory from less satisfactory outcomes was based on a review of publications on the LIV. Adding-on, which indicates an unfavourable outcome, is defined as distal migration of the NV combined with either more than 5 mm of FDUV translation relative to the CSVL or a greater than 5° increase in FDUVtilt 1 year after surgery [5]. These changes indicate worsening of both the main curve and the lumbar compensatory curve.

In our study, 3 patients had distal NV migration between the preoperative evaluation and last follow-up. All 3 patients had an FDUVtilt value greater than 5° and were therefore in the FDUV + 5° group.

Measuring lateral vertebral translation in mm requires calibration of the radiographs, which is not always available.

Finally, we felt that a 5° increase in FDUVtilt was not sufficient to characterize curve outcomes. In our study, 43 patients had a 5° increase in FDUVtilt during follow-up. In all of them, FDUVtilt was greater than 5° at the initial postoperative evaluation. Among the 62 patients whose FDUVtilt decreased, 26 had less than 5° of FDUVtilt postoperatively and remained in the FDUV-5° group at last follow-up and 14 switched from more to less than 5° of FDUVtilt due to the decrease. The remaining 22 patients had more than 5° of FDUVtilt initially followed by a decrease that was not sufficient to bring them into the FDUV-5° group 5 years after surgery. We are aware that the 5° cut-off is a demanding criterion and that many patients whose FDUVtilt is greater than 5° have satisfactory outcomes, particularly if the FDUVtilt value is declining. Nevertheless, we believe that the optimal outcome is defined as a fused segment seated on a horizontal vertebra.

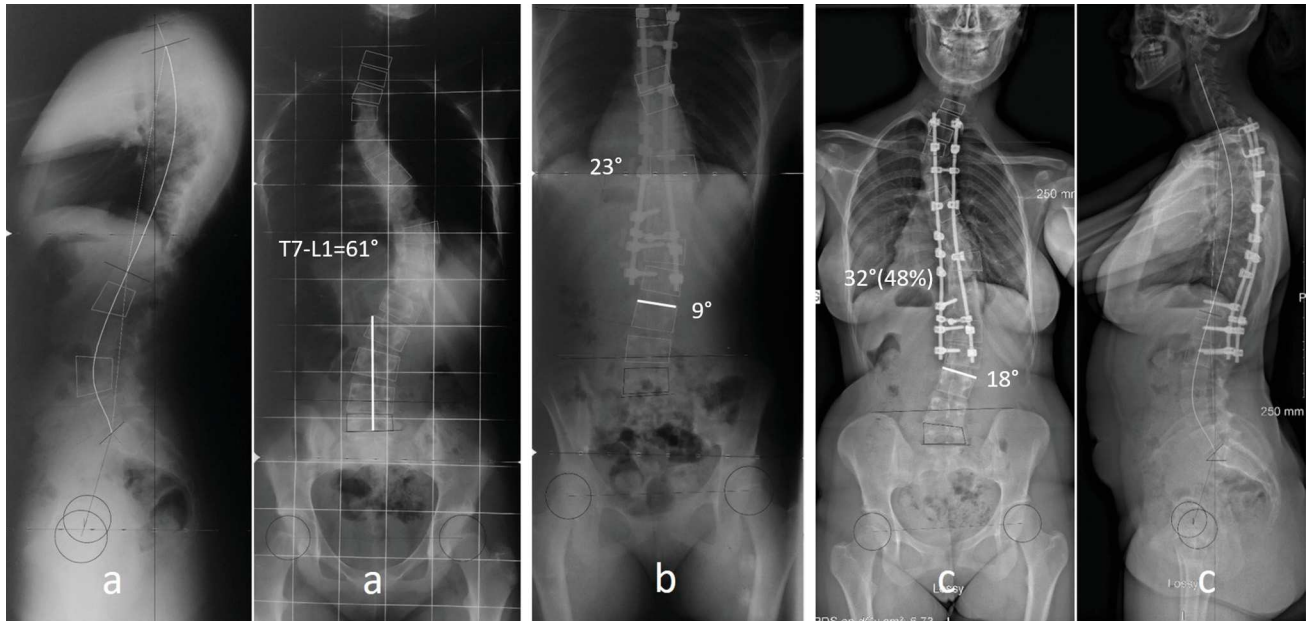
### 4.2. Study limitations

The retrospective design is the main limitation. Strengths of the study are the long follow-up; multicenter recruitment; automatic computer-assisted analysis of radiographic parameters (Keops Analyser software[10]), which provides better repeatability and reproducibility than do conventional measurements; and statistical analysis performed by an independent operator.

### 4.3. Parameters associated with FDUVtilt

Both percentage of correction and correction loss at last follow-up were associated with FDUVtilt, confirming our working





**Fig. 1.** Patient in the FDUV + 5° group, Lenke 2A Adolescent Idiopathic Scoliosis, 14 years of age. Loss of correction. The last instrumented vertebra is at NV-2. (a) Preoperative radiographs: NV at L4; (b) Radiograph 1 month after T2-L2 instrumentation with the last instrumented vertebra at NV-2; (c) Radiographs 5 years after surgery.

hypothesis (Fig. 1). A percentage of correction  $\geq 60\%$  at last follow-up, which was associated with  $\leq 20^\circ$  of final angulation, seems to be the requirement for obtaining an FDUVtilt value below  $5^\circ$  (Fig. 2).

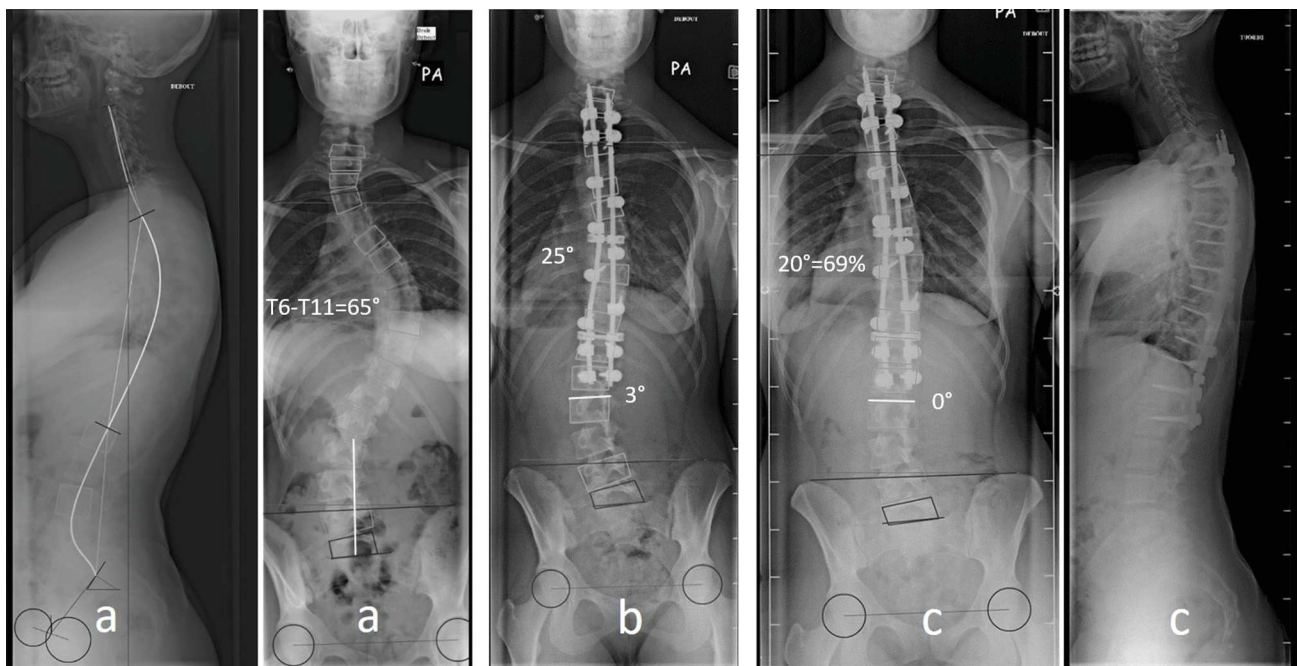
Furthermore, between the postoperative evaluation and last follow-up, FDUVtilt decreased in the FDUV-5° group but increased in the FDUV + 5° (Table 1), in correlation with the correction loss. An improvement in FDUVtilt is ascribable to the potential of the non-instrumented lumbar compensatory curve to improve over time, as reported previously [11–13].

One might expect that an FDUVtilt value below  $5^\circ$  after instrumentation can only be expected when the curve is moderate and flexible. However, in our study, the two groups were

not significantly different regarding initial curve angulation or reducibility on lateral-bending radiographs.

Among lumbar modifiers, C was more common in the FDUV-5° group and A in the FDUV + 5° group (Table 3). Thus, FDUVtilt at last follow-up was less marked when the compensatory curve was initially more severe. This finding demonstrates the potential for the compensatory curve to correct spontaneously in response to correction of the main thoracic curve [12,13]. It should, nevertheless, be interpreted with caution, as some patients with the B or C modifier underwent non-selective instrumentation.

The quality of the correction is well known to correlate with implant density [14]. The number of anchors was fairly low in



**Fig. 2.** Patient in the FDUV-5° group, Lenke 2A Adolescent Idiopathic Scoliosis, 14 years of age. Stable correction. Last instrumented vertebra is at NV + 1. (a) Preoperative radiographs: NV at T12; (b) Radiograph 1 month after T2-L1 instrumentation with the last instrumented vertebra at NV + 1; (c) Radiographs 5 years after surgery.

our study, because all patients had surgery before 2010. Implant density was not significantly associated with *FDUVtilt*. Nevertheless, *FDUVtilt* was associated with both the number of anchors and instrumentation length. This last is probably the relevant factor, as its increase necessarily leads to an increase in the number of anchors. However, in our study, implant density correlated negatively with correction loss and positively with the percentage of correction of the main curve. These correlations confirm the major role for the number of anchors in the quality of the reduction [14].

Quality of life was not significantly different between the two groups. *FDUVtilt* is not perceived by the patient. It was not associated with any of the five SRS 30 domains.

#### 4.4. Selecting the LIV

Our findings (Table 4) constitute a strong argument against instrumentations that are shorter than the NV. Long instrumentations are more satisfactory but compromise the mobility of the lumbar spine. Results were best when the LIV was at NV + 2.

The LTV is also important to consider. Among patients whose instrumentation was shorter than the LTV, 84% were in the *FDUV* + 5° group.

Selection of the LIV involves striking the best compromise between preserving lumbar spine mobility and achieving a horizontal *FDUV*. Several criteria have been suggested based on studies with 2 years of follow-up [4–9]. With a mean follow-up of 8 years, our study argues against very short instrumentations. Stopping the instrumentation at NV-1 or NV-2 is associated with an increased risk of *FDUVtilt* > 5°. We suggest stopping the instrumentation at the NV as a good compromise between instrumentation length and lumbar spine mobility. However, if the LTV is distal to the NV, we recommend extending the instrumentation down to the LTV. When the thoracic curve is long with an NV at L3 or L4, to preserve lumbar spine mobility, the instrumentation can be stopped at NV-1 provided the LTV is cephalad to the NV.

## 5. Conclusions

A final percentage of correction greater than 60% and absence of correction loss between the postoperative evaluation and last follow-up were the main factors associated with an *FDUVtilt* lower than 5° in our study of 182 patients managed by posterior instrumentation for Lenke 1 or 2 AIS and followed-up for a mean of 8 years.

We recommend selective thoracic fusion for Lenke 1 or 2 AIS, regardless of whether the lumbar modifier is A, B, or C. We believe the LIV should be the distal NV of the main thoracic curve or the LTV if this last is distal to the NV.

## Disclosure of interest

The authors declare that they have no competing interest.

## References

- [1] Richards BS. Lumbar curve response in type II idiopathic scoliosis after posterior instrumentation of the thoracic curve. *Spine* 1992;17:S282–6.
- [2] Lenke LG, Betz RR, Bridwell KH, Harms J, Clements DH, Lowe TG. Spontaneous lumbar curve coronal correction after selective anterior or posterior thoracic fusion in adolescent idiopathic scoliosis. *Spine* 1999;24:1663–72.
- [3] Patel PN, UpasaniVV, BastromTP, Marks MC, PawelekJB, Betz RR, et al. Spontaneous lumbar curve correction in selective thoracic fusions of idiopathic scoliosis: a comparison of anterior and posterior approaches. *Spine* 2008;33:1068–73.
- [4] Suk SI, Lee SM, Chung ER, Kim JH, Kim WJ, Sohn HM. Determination of distal fusion level with segmental pedicle screw fixation in single thoracic idiopathic scoliosis. *Spine* 2003;28:484–91.
- [5] Wang Y, Hansen ES, Hoy K, Wu C, Bünger CE. Distal adding-on phenomenon in Lenke 1A scoliosis: risk factor identification and treatment strategy comparison. *Spine* 2011;36:1113–22.
- [6] Matsumoto M, Watanabe K, Hosogane N, Kawakami N, Tsuji T, Uno K, et al. Postoperative distal adding-on and related factors in Lenke 1A curve. *Spine* 2013;38:737–44.
- [7] Miyajiri F, Pawelek JB, Van Salim SE, Upasani VV, Newton PO. Is the lumbar modifier useful in surgical decision making? Defining two distinct Lenke 1A curve patterns. *Spine* 2008;33:2545–51.
- [8] Sarlak AY, Atmaca H, Kim WJ, Musaoglu R, Tosun B. Radiographic features of the Lenke 1A curves to help to determine the optimum distal fusion level selection. *Spine* 2011;36:1592–9.
- [9] Takahashi J, Newton PO, Ugrinow VL, Bastrom TP. Selective thoracic fusion in adolescent idiopathic scoliosis: factors influencing the selection of the optimal lowest instrumented vertebra. *Spine* 2011;36:1131–41.
- [10] Maillot C, Ferrero E, Fort D, Heyberger C, Le Huec. Reproducibility and repeatability of a new computerized software for sagittal spinopelvic and scoliosis curvature radiologic measurements: Keops. *Eur Spine J* 2015;24:1574–81.
- [11] Lowe TG, Lenke L, Betz R, Newton P, Clements D, Haber T, et al. Distal junctional kyphosis of adolescent idiopathic thoracic curves following anterior or posterior instrumented fusion: Incidence, risk factors and prevention. *Spine* 2006;31:299–302.
- [12] Ilgenfritz RM, Yaszay B, Bastrom TP, Newton PO, Harms Study Group. Lenke 1C and 5C spinal deformities fused selectively: 5 year outcomes of the uninstrumented compensatory curves. *Spine* 2013;38:650–8.
- [13] Ishikawa M, Cao K, Pang L, Watanabe K, Yagi M, Hosogane N, et al. Postoperative behavior of thoracolumbar/lumbar curve and coronal balance after posterior thoracic fusion for Lenke 1C and 2C adolescent idiopathic scoliosis. *J Orthop Sci* 2015;20:31–7.
- [14] Clements DH, Betz RD, Newton PO, Rohmiller M, Marks MC, Bastrom T. Correlation of scoliosis curve correction with the number and type of fixation anchors. *Spine* 2009;34:2147–50.