



HAL
open science

Titanium vs cobalt chromium: what is the best rod material to enhance adolescent idiopathic scoliosis correction with sublaminar bands?

Audrey Angelliaume, Emmanuelle Ferrero, Keyvan Mazda, Malo Le Hanneur, Franck Accadbled, Jérôme Sales de Gauzy, Brice Ilharreborde

► **To cite this version:**

Audrey Angelliaume, Emmanuelle Ferrero, Keyvan Mazda, Malo Le Hanneur, Franck Accadbled, et al.. Titanium vs cobalt chromium: what is the best rod material to enhance adolescent idiopathic scoliosis correction with sublaminar bands?. *European Spine Journal*, 2017, 26 (6), pp.1732-1738. 10.1007/s00586-016-4838-0 . hal-02100243

HAL Id: hal-02100243

<https://hal.science/hal-02100243v1>

Submitted on 15 Apr 2019

HAL is a multi-disciplinary open access archive for the deposit and dissemination of scientific research documents, whether they are published or not. The documents may come from teaching and research institutions in France or abroad, or from public or private research centers.

L'archive ouverte pluridisciplinaire **HAL**, est destinée au dépôt et à la diffusion de documents scientifiques de niveau recherche, publiés ou non, émanant des établissements d'enseignement et de recherche français ou étrangers, des laboratoires publics ou privés.





Open Archive Toulouse Archive Ouverte (OATAO)

OATAO is an open access repository that collects the work of Toulouse researchers and makes it freely available over the web where possible.

This is an author-deposited version published in: <http://oatao.univ-toulouse.fr/>
Eprints ID: 23133

To link to this article : DOI:10.1007/s00586-016-4838-0

URL : <https://doi.org/10.1007/s00586-016-4838-0>

To cite this version: Angelliaume, Audrey and Ferrero, Emmanuelle and Mazda, Keyvan and Le Hanneur, Malo and Accadbled, Franck  and Sales de Gauzy, Jérôme  and Ilharreborde, Brice *Titanium vs cobalt chromium: what is the best rod material to enhance adolescent idiopathic scoliosis correction with sublaminar bands?* (2017) *European Spine Journal*, 26 (6). 1732-1738. ISSN 0940-6719

Any correspondence concerning this service should be sent to the repository administrator:
staff-oatao@listes-diff.inp-toulouse.fr

Titanium vs cobalt chromium: what is the best rod material to enhance adolescent idiopathic scoliosis correction with sublaminar bands?

Audrey Angelliaume¹ · E. Ferrero¹ · K. Mazda¹ · M. Le Hanneur¹ · F. Accabled² · J. Sales de Gauzy² · B. Ilharreborde¹

Abstract

Purpose Cobalt chromium (CoCr) rods have recently gained popularity in adolescent idiopathic scoliosis (AIS) surgical treatment, replacing titanium (Ti) rods, with promising frontal correction rates in all-screw constructs. Posteromedial translation has been shown to emphasize thoracic sagittal correction, but the influence of rod material in this correction technique has never been investigated. The aim of this study was to compare the postoperative correction between Ti and CoCr rods for the treatment of thoracic AIS using posteromedial translation technique.

Methods 70 patients operated for thoracic (Lenke 1 or 2) AIS, in 2 institutions, between 2010 and 2013, were included. All patients underwent posterior fusion with hybrid constructs using posteromedial translation technique. The only difference between groups in the surgical procedure was the rod material (Ti or CoCr rods). Radiological measurements were compared preoperatively, postoperatively and at last follow-up (minimum 2 years).

Results Preoperatively, groups were similar in terms of coronal and sagittal parameters. Postoperatively, no significant difference was observed between Ti and CoCr regarding frontal corrections, even when the preoperative flexibility of the curves was taken into account ($p = 0.13$). CoCr rods allowed greater restoration of T4T12 thoracic

kyphosis, which remained stable over time ($p = 0.01$). Most common postoperative complication was proximal junctional kyphosis ($n = 4$). However, no significant difference was found between groups regarding postoperative complications rate.

Conclusion CoCr and Ti rods both provide significant and stable frontal correction in AIS treated with posteromedial translation technique using hybrid constructs. However, CoCr might be considered to emphasize sagittal correction in hypokyphotic patients.

Keywords Adolescent idiopathic scoliosis · Sublaminar bands · Cobalt–chromium rods · Hypokyphosis · Posteromedial translation

Introduction

The goal of adolescent idiopathic scoliosis (AIS) surgery is to achieve a tridimensional correction of the deformity, balanced over the pelvis and stable over time. The main factor influencing postoperative correction remains curve flexibility, but the type of implants and rod material also play a role. Nowadays, titanium rods (Ti) have progressively replaced stainless steel ones (SS), reducing imaging artefact and overall postoperative infection rate [1]. However, Ti rods are more elastic and therefore reduce the possibility to apply in situ bending during correction manoeuvres. Cobalt chromium (CoCr) rods have recently gained popularity in AIS, offering the advantages of Ti but with mechanical properties closer to those of SS [2]. CoCr might therefore allow the application of greater correction forces and better stability over time. The first clinical study in AIS only involved all-screw constructs, and reported a higher correction rate in the coronal plane with CoCr

✉ Audrey Angelliaume
angelliaume.audrey@gmail.com

¹ Department of Paediatric Orthopaedics, Robert Debré Hospital, Paris Diderot University, 48 Boulevard Sérurier, 75019 Paris, France

² Department of Paediatric Orthopaedics, Purpan University Hospital, Place du Docteur Baylac, 31059 Toulouse, France

compared to stainless steel [3]. Recent studies have emphasized the efficiency of posteromedial translation using sublaminar bands in the restoration of sagittal alignment [4–6]. In this technique, the correction forces are directly applied to the spine through the bands, and the spine is pulled posteriorly to the precontoured rods when tension is applied, until reaching the ultimate tensile strength of the polyester. Therefore, the stiffness of the rods might be even more decisive in hybrid constructs than in all-screw ones. No information can be found to date concerning the optimal rod alloy in AIS when sublaminar bands are used for thoracic correction. Hence, the aim of the present study was to compare the radiological outcomes of Lenke 1 and 2 AIS treated by posteromedial translation using hybrid constructs with either CoCr or Ti rods.

Materials and methods

Patients

After IRB approval, all consecutive Lenke 1 and Lenke 2 AIS patients, operated between January 2010 and December 2013 using hybrid constructs in two distinct paediatric orthopaedic departments were included. Demographic, radiographic and surgical data were collected [7]. Patients with previous spine surgery were excluded.

Surgical procedure

Fusion levels, implants number and localization at thoracic levels were selected according to the same criteria in each centre (Fig. 1) [8]. The upper instrumented level was a neutral vertebra on traction film and should be above the apex of the thoracic kyphosis. The lower instrumented level was a neutral lumbar vertebra touched by the central sacral vertical line on coronal X-rays and a stable vertebra on bendings films. Posteromedial translation was the technique used for thoracic correction, using the progressive tension transmitted by the polyester bands (Jazz, Implanet, Bordeaux, France). The only difference regarding operative strategy between both departments was the rod material used for correction (CoCr in centre 1 and Ti CP in centre 2). No patient underwent prior anterior release before posterior fusion, neither Ponte osteotomies. The same perioperative blood saving strategy was used, associating intraoperative cell saver and tranexamic acid. All the procedures were performed under spinal cord monitoring.

Radiological measurements

All patients underwent low-dose stereoradiographs using the EOS system (EOS imaging, Paris, France)

preoperatively, postoperatively (within 1 month) and at latest follow-up (minimum 2 years) [9, 10]. Spinal measurements were performed using SterEOS software (EOS imaging, Paris, France), by an experienced independent spinal surgeon. The following coronal radiographic parameters were recorded: Cobb angles of the main curve and contra-curves, ilio-lumbar angle (ILA, angle between the upper endplate of L4 and the line joining the sacroiliac joints), T1 tilt (measured between the horizontal reference line and the upper endplate of T1) and the frontal alignment [appreciated by the offset between the central sacral vertical line (CSVL) and the centre of C7]. Sagittal parameters included: T1T12 and T4T12 thoracic kyphosis (TK), L1S1 lumbar lordosis (LL), and pelvic parameters. Sagittal alignment was appreciated by the sagittal vertical axis (SVA), defined by the offset between the vertical C7 plumbline and the posterosuperior corner of S1 (the measurement was considered as positive if directed forwards and negative if directed backwards). In addition, the Cincinnati Correction Index (CCI), described by Vora et al. to take into account the preoperative flexibility, was calculated as follows: $CCI = \frac{\text{postoperative correction (\%)}}{\text{preoperative flexibility (\%)}}$ [11].

Statistical analysis

Statistical analysis was performed using SPSS software, version 20 (IBM, Armonk, NY, USA). Continuous variables were expressed as means and standard deviations. Radiological parameters were compared between groups using Student's *t* tests. To compare categorical variables, Chi-square or Fisher tests were used as appropriate. A $p < 0.05$ was considered statistically significant.

Results

Patients and surgical procedures

Seventy patients were included (35 in centre 1 and 35 in centre 2), with comparable preoperative demographic data (Table 1). Preoperatively, Cobb angle of the main and contra-curve and sagittal parameters were not significantly different between groups ($p = 0.04$) (Table 2). Mean number of hypokyphotic patients (i.e. T4T12 $<20^\circ$) averaged 54.2% in both groups. Mean number of levels fused was significantly higher in the CoCr group (13 vs 12), with a more proximal upper instrumented vertebra in CoCr group. Nevertheless, the mean number of instrumented thoracic levels was not statistically different (10 ± 1 in group 1 and 2). In both groups, T3 was the most frequent upper instrumented level selected (Fig. 2). L3 was the most frequent level chosen for distal fixation (Fig. 3). Mean

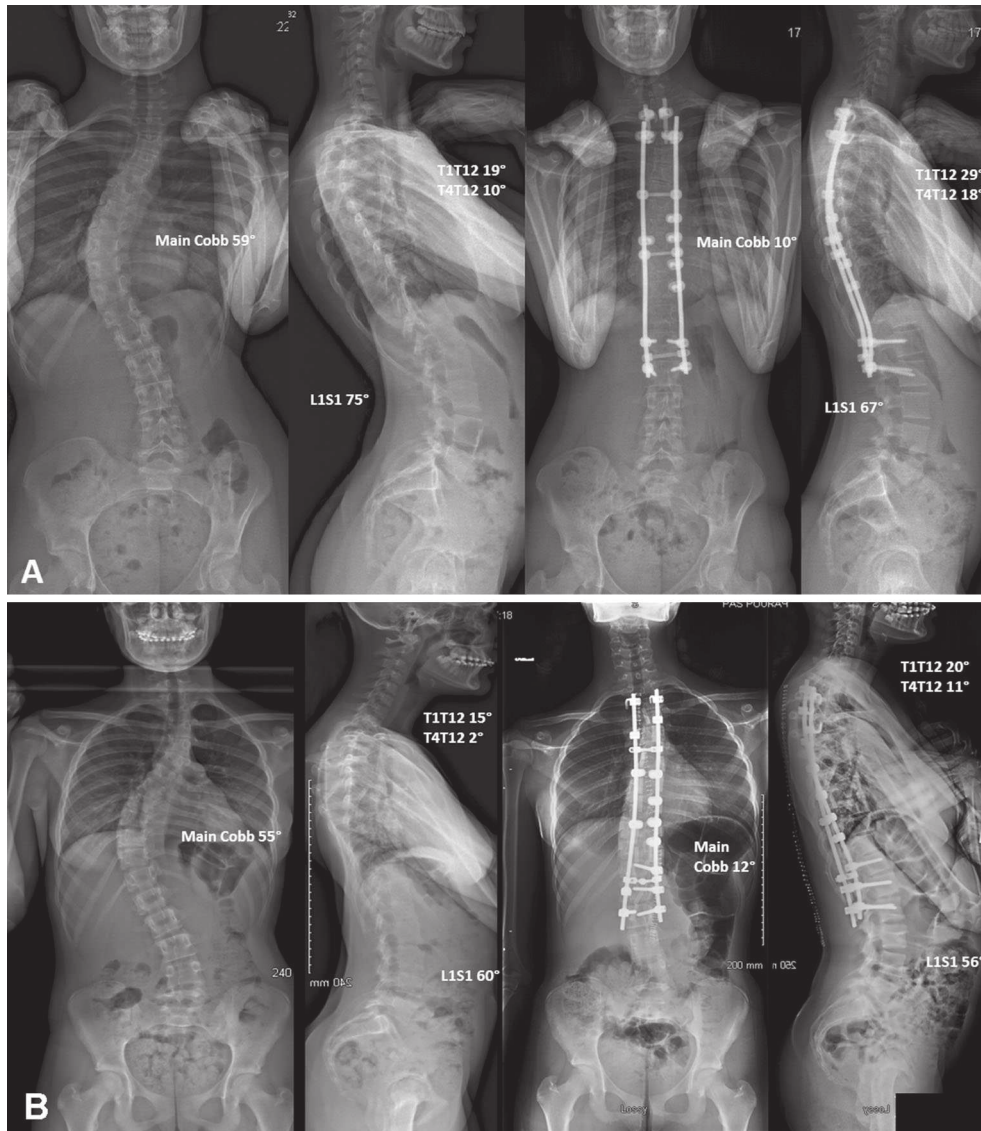


Fig. 1 Preoperative and postoperative radiographs of AIS patients corrected by posteromedial translation using hybrid constructs with CoCr rods (a) or Ti rods (b)

Table 1 Demographic and surgical data comparison between groups

	Ti group (n = 35)	CoCr group (n = 35)	p
Age (years)	16.6 ± 4	15.7 ± 2	0.25
Gender (% of female)	80	89	0.51
Risser grade	3.4 ± 2	3.4 ± 2	0.94
Follow-up (months)	28 ± 3	27 ± 2	0.46
Number of levels fused	12 ± 1	13 ± 1	<0.001
Number of sublaminar bands	5 ± 1	5 ± 1	0.37

number of sublaminar bands used for correction of the main thoracic curve was not statistically different between groups, while one more screw was used on average at lumbar levels in the CoCr group (Table 1).

Postoperative correction

No significant difference was found between Ti and CoCr rods regarding coronal postoperative correction of the main curve ($p = 0.09$) (Table 3). Postoperative frontal correction rates averaged 70.6% with Ti and 70.9% with CoCr ($p = 0.07$), and no significant loss of correction was observed at latest examination (Table 4).

The only difference between groups was reported in the sagittal plane, with significantly greater postoperative T4T12 kyphosis in the CoCr group, both postoperatively and at latest follow-up ($p = 0.01$ and $p = 0.01$, respectively). Similarly, at latest follow-up, an increase in T1T12 kyphosis was observed: $11^\circ \pm 11$ with CoCr and $3^\circ \pm 12$ with Ti ($p = 0.008$). The number of hypokyphotic patients

Table 2 Preoperative radiological measurements comparison between groups ($N = 70$)

	Ti group ($n = 35$)	CoCr group ($n = 35$)	p
Main Cobb ($^{\circ}$)	58 ± 11	55 ± 10	0.25
PF (%)	40	49	0.05
Proximal Cobb ($^{\circ}$)	33 ± 7	31 ± 9	0.32
Distal Cobb ($^{\circ}$)	32 ± 11	30 ± 11	0.74
T1 tilt ($^{\circ}$)	5 ± 4	6 ± 5	0.25
Ilio-lumbar angle ($^{\circ}$)	7 ± 6	10 ± 6	0.08
CSVL (mm)	10 ± 10	15 ± 14	0.11
T1T12 thoracic kyphosis ($^{\circ}$)	31 ± 12	30 ± 15	0.69
T4T12 thoracic kyphosis ($^{\circ}$)	21 ± 14	21 ± 13	1.00
L1S1 lumbar lordosis ($^{\circ}$)	52 ± 17	55 ± 13	0.29
SVA (mm)	17 ± 25	9 ± 25	0.22
N of patients with T4T12 $<20^{\circ}$	19	19	1.00

PF preoperative flexibility, CSVL central sacral vertical line, SVA sacral vertical axis, N number

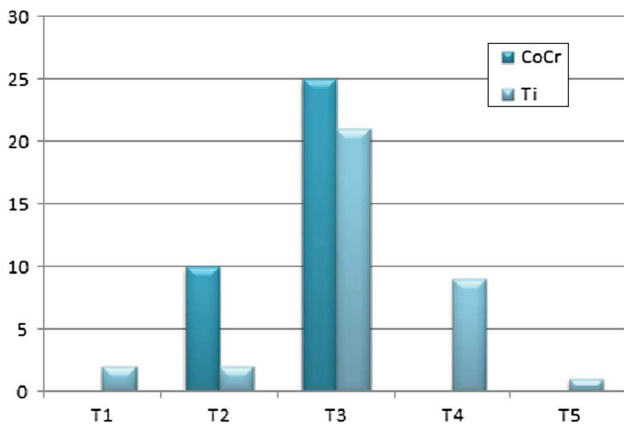


Fig. 2 Upper instrumented level distribution of the cohort

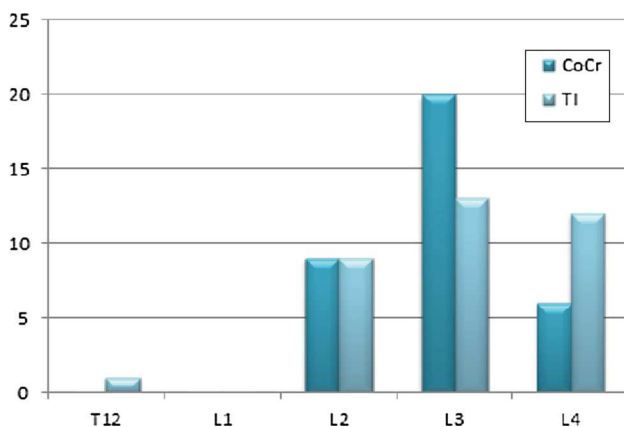


Fig. 3 Lower instrumented level distribution of the cohort

Table 3 Coronal parameters comparison between groups, postoperatively and at last follow-up

	Ti group ($n = 35$)	CoCr group ($n = 35$)	p
Post operative			
Main curve ($^{\circ}$)	17 ± 8	16 ± 8	0.73
CCI	2.5 ± 3	1.8 ± 1.1	0.13
Proximal curve ($^{\circ}$)	20 ± 7	23 ± 7	0.08
Distal curve ($^{\circ}$)	9 ± 7	6 ± 5	0.14
CSVL (mm)	12 ± 9	10 ± 9	0.41
T1 tilt ($^{\circ}$)	7 ± 4	8 ± 5	0.11
Last follow-up			
Main curve ($^{\circ}$)	19 ± 8	19 ± 8	0.64
CCI	2.4 ± 3	1.7 ± 1	0.09
Proximal curve ($^{\circ}$)	22 ± 7	22 ± 6	0.83
Distal curve ($^{\circ}$)	10 ± 7	8 ± 5	0.08
CSVL (mm)	9 ± 9	8 ± 6	0.51
T1 tilt ($^{\circ}$)	7 ± 6	7 ± 4	0.96

POC postoperative correction, CCI Cincinnati Correction Index, CSVL central sacral vertical line

Table 4 Mean change between postoperative and latest follow-up in radiological measurements

	Ti group ($n = 35$)	CoCr group ($n = 35$)	p
Main curve ($^{\circ}$)	$+4 \pm 3$	$+4 \pm 5$	0.40
Proximal curve ($^{\circ}$)	$+5 \pm 4$	$+4 \pm 3$	0.20
Distal curve ($^{\circ}$)	$+4 \pm 4$	$+3 \pm 2$	0.12
T1 tilt ($^{\circ}$)	-1 ± 5	-1 ± 4	0.13
T1T12 thoracic kyphosis ($^{\circ}$)	$+3 \pm 5$	$+5 \pm 5$	0.11
T4T12 thoracic kyphosis ($^{\circ}$)	$+4 \pm 5$	$+5 \pm 6$	0.72
L1S1 lumbar lordosis ($^{\circ}$)	$+7 \pm 9$	$+9 \pm 7$	0.20
SVA (mm)	-2 ± 27	-5 ± 28	0.65

SVA sagittal vertical axis

was significantly decreased in both groups, but remained greater in the Ti group (16 vs 7, $p = 0.04$) (Table 5).

Complications

No infection, no instrumentation failure and no pseudarthrosis were reported in the cohort during the follow-up period. However, according to Yagi et al. criteria, two radiological proximal junctional kyphosis (PJK) occurred in each group (total four PJK, 5.7%) [12]. Among them, one patient was symptomatic (ligamentous type) in the CoCr group and required revision surgery, which consisted in a proximal extension two levels above. Patients who developed radiological PJK were not statistically different from the rest of the cohort in terms of preoperative sagittal

Table 5 Sagittal parameters comparison between groups, postoperatively and at latest follow-up

	Ti group (<i>n</i> = 35)	CoCr group (<i>n</i> = 35)	<i>p</i>
Postoperative			
T1T12 thoracic kyphosis (°)	32 ± 8	37 ± 9	0.04
T4T12 thoracic kyphosis (°)	19 ± 9	22 ± 7	0.01
L1S1 lumbar lordosis (°)	45 ± 14	43 ± 9	0.51
SVA (mm)	16 ± 22	23 ± 25	0.25
Last follow up			
T1T12 thoracic kyphosis (°)	34 ± 8	40 ± 10	0.01
T4T12 thoracic kyphosis (°)	20 ± 9	26 ± 8	0.01
L1S1 lumbar lordosis (°)	53 ± 17	53 ± 10	0.89
SVA (mm)	8 ± 24	−4 ± 22	0.05

SVA sagittal vertical axis, *n* number

alignment, but their postoperative SVA was shifted posteriorly in all cases (−25 mm on average).

Discussion

Rods material in AIS

The main challenge in AIS surgery is to correct the deformity in 3D and obtain a stable fusion to avoid revision surgery [13, 14]. The stiffness of the rods is therefore essential not only for initial correction, but also to hold the corrected spine until fusion occurs. SS rods have been for long the most popular ones, with various diameters, but they were progressively replaced by Ti rods, reducing imaging artefacts and postoperative infection rates [1]. Easier to bend and to connect to anchors in deformity surgery, Ti rods are significantly more flexible, and therefore reduce the ability to apply in situ bending during the correction due to their elasticity. CoCr rods present the advantages of Ti, but with mechanical properties closer to those of SS [2]. Hence, in vitro studies confirmed that they could allow the application of greater correction forces (42% compared to Ti and 10% compared to SS) and better stability over time [2]. As a result, 5.5 diameter CoCr rods have recently gained popularity, and Lamerain et al. reported, in one of the first in vivo comparative study, improved frontal correction rates and better stability over time in all-pedicle screw constructs, in comparison with same diameter SS rods [3]. Authors also reported a good hypokyphosis correction with CoCr rods and pedicle screws constructs in AIS patients [12].

Ti and CoCr rods in posteromedial translation

Recent studies have emphasized the efficiency of posteromedial translation using sublaminar bands in the restoration of sagittal alignment [4]. Rods mechanical properties are probably even more important in this correction technique, since the concept is to progressively bring the spine to the precontoured rods when the polyester bands are tensioned. The forces applied remain efficient to correct the deformity until one of the events occurs: (1) lamina breakage, (2) band breakage or (3) plastic deformation of the concave rod. The first mode of failure almost never happens in healthy AIS, while band breakage can be avoided with experience. However, the stiffer the rod the less plastic deformation is observed and for that reason CoCr was promising.

Results of the current study confirm that posteromedial translation is an efficient technique for AIS correction, at least for coronal correction with both Ti and CoCr rods. Average postoperative main Cobb angle correction was 71%, consistent with previous literature, and without significant difference between materials (*p* = 0.08) (Table 3) [5, 16–18]. This finding can be partly explained by the fact that most of the thoracic AIS were young and still flexible, and that the correction forces needed did not reach the plastic limit of the rods.

However, CoCr rods appeared to be more efficient to restore the thoracic sagittal alignment, with greater T4T12 kyphosis gain (*p* = 0.01) and less hypokyphotic patients at follow-up (Table 5). The iatrogenic flattening effect, previously reported with CoCr in all-pedicle screw constructs, was not observed, and might be more related to the correction technique [19]. This result indicates that the spine is first translated medially during correction, and that the last but most difficult step is then to pull the vertebrae posteriorly. This translation can be limited by the plastic deformation of the rod in stiff spines. Interestingly, a spontaneous slight increase in both T1T12 and T4T12 kyphosis was noted in both groups during follow-up, even though the change did not reach significance (Fig. 4; Table 4). This tendency which had already been observed in all-screw constructs needs to be further investigated in the future [3]. Nevertheless, immediate postoperative corrections remained stable over time and no significant loss of correction was observed at latest examination.

The overall complication rate was low in the current series, and we were not able to find any influence of the type of instrumentation. One of our concerns was to compare both materials in terms of risk of PJK. As a matter of fact, CoCr allows better thoracic sagittal realignment, improving balance and therefore potentially reducing the risk of adjacent segment disease in a biomechanical point of view, but at the

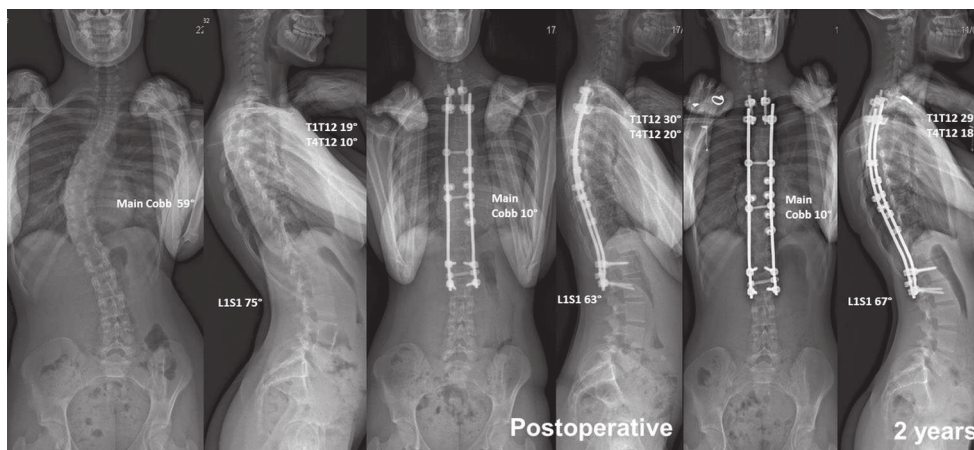


Fig. 4 Preoperative, postoperative and latest anteroposterior and lateral radiographs of a Lenke 1 AIS patient, showing a 4° spontaneous increase in T4T12 kyphosis during follow-up

expense of a greater rigidity at the upper end of the construct, which can also be considered as a PJK mechanical risk factor. Since 2 PJK were reported in each group, no conclusion can be drawn, and larger series remain necessary to answer this key question. Moreover, sublaminar or subtransversal polyester bands have been reported as safe technique for surgical correction, but remained demanding technique with short learning curve [5, 20–22].

Besides cost, the only drawback of CoCr is that it produces more artefacts on MRI than Ti. However, Ahmad et al. concluded that spinal canal or neural element evaluation remained sufficient and not clinically different with both materials [23].

Limitations

Several limitations can be noted in the current study. First, it was retrospective and involved two distinct centres. Even though the only difference in surgical planning was the rod material, a randomized control trial would have provided more relevant data. Second, the comparison was only radiological, and clinical outcomes need to be further assessed and compared in the future. Finally, the follow-up period was relatively short (28 months on average), but it is now accepted that loss of coronal correction in AIS usually occurs during the first two postoperative years [24].

Conclusion

In conclusion, CoCr and Ti rods provide similar coronal correction in flexible thoracic AIS. However, CoCr might be considered in order to emphasize sagittal correction in hypokyphotic patients.

Compliance with ethical standards

Conflict of interest None.

References

1. Glotzbecker MP, Riedel MD, Vitale MG, Matsumoto H, Roye DP, Erickson M et al (2013) What's the evidence? Systematic literature review of risk factors and preventive strategies for surgical site infection following pediatric spine surgery. *J Pediatr Orthop* 33(5):479–487
2. Serhan H, Mhatre D, Newton P, Giorgio P, Sturm P (2013) Would CoCr rods provide better correctional forces than stainless steel or titanium for rigid scoliosis curves? *J Spinal Disord Tech* 26(2):E70–E74
3. Lamerain M, Bachy M, Delpont M, Kabbaj R, Mary P, Vialle R (2014) CoCr rods provide better frontal correction of adolescent idiopathic scoliosis treated by all-pedicle screw fixation. *Eur Spine J* 23(6):1190–1196
4. Ilharreborde B, Even J, Lefevre Y, Fitoussi F, Presedo A, Penneçot G-F et al (2010) Hybrid constructs for tridimensional correction of the thoracic spine in adolescent idiopathic scoliosis: a comparative analysis of universal clamps versus hooks. *Spine* 35(3):306–314
5. Mazda K, Ilharreborde B, Even J, Lefevre Y, Fitoussi F, Penneçot G-F (2009) Efficacy and safety of posteromedial translation for correction of thoracic curves in adolescent idiopathic scoliosis using a new connection to the spine: the Universal Clamp. *Eur Spine J Off Publ Eur Spine Soc Eur Spinal Deform Soc Eur Sect Cerv Spine Res Soc* 18(2):158–169
6. Sales de Gauzy J, Jouve J-L, Ilharreborde B, Blondel B, Accadbled F, Mazda K (2014) Use of the Universal Clamp in adolescent idiopathic scoliosis. *Eur Spine J Off Publ Eur Spine Soc Eur Spinal Deform Soc Eur Sect Cerv Spine Res Soc* 23(Suppl 4):S446–S451
7. Lenke LG (2005) Lenke classification system of adolescent idiopathic scoliosis: treatment recommendations. *Instr Course Lect* 54:537–542
8. Ilharreborde B, Morel E, Fitoussi F, Presedo A, Souchet P, Penneçot G-F et al (2008) Planification du niveau supérieur d'arthrodèse dans les scolioses idiopathiques thoraciques de l'adolescent: étude prospective de 103 cas. *Rev Chir Orthopédique Réparatrice Appar Mot* 94(5):481–489

9. Faro FD, Marks MC, Pawelek J, Newton PO (2004) Evaluation of a functional position for lateral radiograph acquisition in adolescent idiopathic scoliosis. *Spine* 29(20):2284–2289
10. Ilharreborde B, Steffen JS, Nectoux E, Vital JM, Mazda K, Skalli W et al (2011) Angle measurement reproducibility using EOS three-dimensional reconstructions in adolescent idiopathic scoliosis treated by posterior instrumentation. *Spine* 36(20):E1306–E1313
11. Vora V, Crawford A, Babekhir N, Boachie-Adjei O, Lenke L, Peskin M et al (2007) A pedicle screw construct gives an enhanced posterior correction of adolescent idiopathic scoliosis when compared with other constructs: myth or reality. *Spine* 32(17):1869–1874
12. Lamerain M, Bachy M, Dubory A, Kabbaj R, Scemama C, Vialle R (2016) All-pedicle screw fixation with 6-mm-diameter cobalt-chromium rods provides optimized sagittal correction of adolescent idiopathic scoliosis. *Clin Spine Surg*. doi:10.1097/BSD.0000000000000413
13. Yagi M, Rahm M, Gaines R, Maziad A, Ross T, Kim HJ et al (2014) Characterization and surgical outcomes of proximal junctional failure in surgically treated patients with adult spinal deformity. *Spine* 39(10):E607–E614
14. Hwang SW, Samdani AF, Marks M, Bastrom T, Garg H, Lonner B et al (2013) Five-year clinical and radiographic outcomes using pedicle screw only constructs in the treatment of adolescent idiopathic scoliosis. *Eur Spine J Off Publ Eur Spine Soc Eur Spinal Deform Soc Eur Sect Cerv Spine Res Soc* 22(6):1292–1299
15. Kim YJ, Lenke LG, Bridwell KH, Kim J, Cho SK, Cheh G et al (2007) Proximal junctional kyphosis in adolescent idiopathic scoliosis after 3 different types of posterior segmental spinal instrumentation and fusions: incidence and risk factor analysis of 410 cases. *Spine* 32(24):2731–2738
16. Ilharreborde B, Sebag G, Skalli W, Mazda K (2013) Adolescent idiopathic scoliosis treated with posteromedial translation: radiologic evaluation with a 3D low-dose system. *Eur Spine J Off Publ Eur Spine Soc Eur Spinal Deform Soc Eur Sect Cerv Spine Res Soc* 22(11):2382–2391
17. Bridwell KH, Hanson DS, Rhee JM, Lenke LG, Baldus C, Blanke K (2002) Correction of thoracic adolescent idiopathic scoliosis with segmental hooks, rods, and Wisconsin wires posteriorly: it's bad and obsolete, correct? *Spine* 27(18):2059–2066
18. Delorme S, Labelle H, Aubin CE, de Guise JA, Rivard CH, Poitras B et al (2000) A three-dimensional radiographic comparison of Cotrel-Dubousset and Colorado instrumentations for the correction of idiopathic scoliosis. *Spine* 25(2):205–210
19. Cheng I, Kim Y, Gupta MC, Bridwell KH, Hurford RK, Lee SS et al (2005) Apical sublaminar wires versus pedicle screws— which provides better results for surgical correction of adolescent idiopathic scoliosis? *Spine* 30(18):2104–2112
20. Polirsztok E, Gavaret M, Gsell T, Suprano I, Choufani E, Bollini G, Jouve JL (2015) Sublaminar bands: are they safe? *Eur Spine J* 24(7):1441–1449
21. Strickland BA, Sayama C, Briceño V, Lam SK, Luerssen TG, Jea A (2015) Use of subtransverse process polyester bands in pediatric spine surgery: a case series of 4 patients with a minimum of 12 months' follow-up. *J Neurosurg Pediatr*. doi:10.3171/2015.6.PEDS15255
22. Desai SK, Sayama C, Vener D, Brayton A, Briceño V, Luerssen TG, Jea A (2015) The feasibility and safety of using sublaminar polyester bands in hybrid spinal constructs in children and transitional adults for neuromuscular scoliosis. *J Neurosurg Pediatr* 15(3):328–337. doi:10.3171/2014.9.PEDS1468 (Epub 2015 Jan 2)
23. Ahmad FU, Sidani C, Fourzali R, Wang MY (2013) Postoperative magnetic resonance imaging artifact with cobalt-chromium versus titanium spinal instrumentation: presented at the 2013 joint spine section meeting. Clinical article. *J Neurosurg Spine*. 19(5):629–636
24. Remes V, Helenius I, Schlenzka D, Yrjönen T, Ylikoski M, Poussa M (2004) Cotrel-Dubousset (CD) or Universal Spine System (USS) instrumentation in adolescent idiopathic scoliosis (AIS): comparison of midterm clinical, functional, and radiologic outcomes. *Spine* 29(18):2024–2030