



**HAL**  
open science

## Reconstruction of cranial vault defect with polyetheretherketone implants

Pierre Brandicourt, Franck Delanoé, Franck-Emmanuel Roux, Florian Jalbert,  
David Brauge, Frédéric Lauwers

► **To cite this version:**

Pierre Brandicourt, Franck Delanoé, Franck-Emmanuel Roux, Florian Jalbert, David Brauge, et al..  
Reconstruction of cranial vault defect with polyetheretherketone implants. World Neurosurgery, 2017,  
105, pp.783-789. 10.1016/j.wneu.2017.04.049 . hal-02094262

**HAL Id: hal-02094262**

**<https://hal.science/hal-02094262>**

Submitted on 9 Apr 2019

**HAL** is a multi-disciplinary open access archive for the deposit and dissemination of scientific research documents, whether they are published or not. The documents may come from teaching and research institutions in France or abroad, or from public or private research centers.

L'archive ouverte pluridisciplinaire **HAL**, est destinée au dépôt et à la diffusion de documents scientifiques de niveau recherche, publiés ou non, émanant des établissements d'enseignement et de recherche français ou étrangers, des laboratoires publics ou privés.



## Open Archive Toulouse Archive Ouverte

OATAO is an open access repository that collects the work of Toulouse researchers and makes it freely available over the web where possible

This is an author's version published in: <http://oatao.univ-toulouse.fr/23138>

### Official URL:

<https://doi.org/10.1016/j.wneu.2017.04.049>

### To cite this version:

Brandicourt, Pierre and Delanoé, Franck and Roux, Franck-Emmanuel and Jalbert, Florian and Brauge, David and Lauwers, Frédéric Reconstruction of cranial vault defect with polyetheretherketone implants.

Any correspondence concerning this service should be sent to the repository administrator: [tech-oatao@listes-diff.inp-toulouse.fr](mailto:tech-oatao@listes-diff.inp-toulouse.fr)

# Reconstruction of Cranial Vault Defect with Polyetheretherketone Implants

Pierre Brandicourt<sup>1</sup>, Franck Delanoé<sup>2</sup>, Franck-Emmanuel Roux<sup>1</sup>, Florian Jalbert<sup>2</sup>, David Brauge<sup>1</sup>, Frédéric Lauwers<sup>2</sup>

■ **OBJECT:** Reconstruction of a cranial vault defect is a frequent challenge in neurosurgery. Polyetheretherketone (PEEK) is used in many types of prostheses and has been employed for 10 years in our institution (University Hospital of Toulouse, France). The objectives of this study are to describe the benefits and drawbacks of reconstructing the cranial vault defect with a PEEK prosthesis.

■ **METHODS:** Clinical data of the 37 patients who received a reconstruction with a custom-made PEEK prosthesis from 2007–2015 were retrospectively analysed. Operative technique, postoperative complications, and patient's satisfaction with the aesthetic result—on a scale ranging from 1 (very dissatisfied) to 5 (very satisfied)—were studied.

■ **RESULTS:** Average follow-up was 4.3 years (from 2 months–9 years). The placement of the prosthesis was performed 195 days on average (from 0–1051 days, standard deviation 258 days) after the initial bone flap removal. One infection (2.7%), which required the removal of the prosthesis, was described. Six patients (16%) were reoperated by the maxillofacial surgery team to treat a lack of temporal projection related to muscle atrophy, using a fat cell autograft taken from the abdominal region. Overall, 30 patients (81%) answered the question about their aesthetic satisfaction, with good results on the satisfaction scale (average 4.5; from 3–5).

■ **CONCLUSION:** The use of a PEEK prosthesis in cranial vault defect reconstruction is a reliable technique with a high patient satisfaction rate and few complications. Corrections of the temporal muscle atrophy by fat grafting may be performed in addition, without increasing the rate of complications.

## INTRODUCTION

Decompressive craniectomies used in intractable elevated intracranial pressure raise the issue of cranial bone reconstruction. Many authors have reported elevated rates of complications with autologous bone reconstructions, such as aseptic bone resorptions, skin or bone flap infections, or brain abscesses.<sup>1</sup> Many different methods of cranial bone reconstruction have been described in the past, such as metal prostheses (gold, silver, aluminium, titanium) and allografts from cadavers or autografts using a rib or scapula.<sup>2</sup> Currently, a choice of synthetic materials is available for the procedure: methyl methacrylate, hydroxyapatite, ceramic, or acrylic resin.<sup>3</sup> Polyetheretherketone (PEEK), manufactured for the first time in 1978 and marketed since 1981, is a linear, polyaromatic, semi-crystalline polymer that has many advantages.<sup>4</sup> It is a tough, rigid, biocompatible material that is used in the fabrication of many prostheses in orthodontics or orthopedic surgery.<sup>5,6</sup> However, few studies of its use are available in the neurosurgical literature.<sup>7</sup> The objectives of this study were to evaluate the complications and aesthetic result concerning patients in whom the cranial vault was rebuilt with a PEEK prosthesis because of a defect. The patients were all treated in a single institution.

## MATERIAL AND METHODS

We retrospectively studied all patients who received a PEEK custom-made implant as part of the reconstruction of a cranial vault defect at the University Hospital of Toulouse between 2007 and 2015. Thirty-seven patients were analyzed: 15 women (40%) and 22 men (60%), with an average age of 40 years (from 12–80 years old; standard deviation [SD] 15). Because of the various indications of PEEK implants, 3 different groups were formed according to their surgical history (**Figure 1**). The first group of patients underwent a craniotomy or decompressive craniectomy with an autologous cranioplasty, followed by removal of the autologous flap for osteitis or aseptic lysis (**Table 1**). The second group comprised patients who had never had autologous

### Key words

- Cranioplasty
- Polyetheretherketone
- Prosthesis
- Reconstruction of the cranial vault

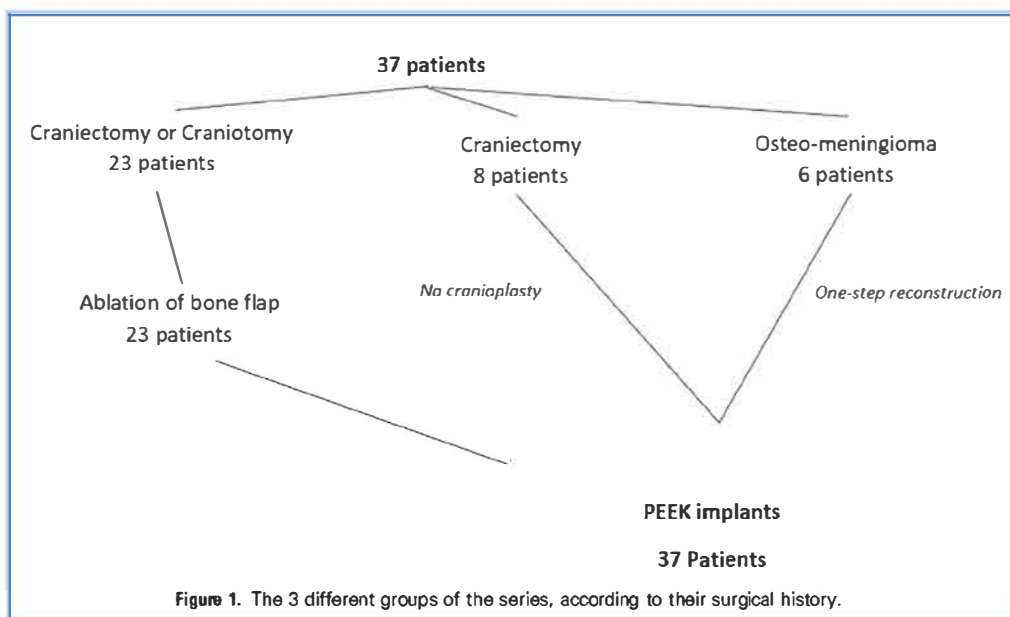
### Abbreviations and Acronyms

- CT: Computed tomography
- PEEK: Polyetheretherketone
- SD: Standard deviation

From the Departments of <sup>1</sup>Neurosurgery and <sup>2</sup>Maxillofacial Surgery, Hospital Center University of Toulouse, Paul Sabatier University, Toulouse, France

To whom correspondence should be addressed: Pierre Brandicourt, M.D.  
[E mail: pierre.brandicourt@gmail.com]

<http://dx.doi.org/10.1016/j.wneu.2017.04.049>



cranioplasty (i.e., they had decompressive craniectomy without autologous cranioplasty because of flap infection or a complex cranial fracture) (Table 2). The last group was composed of

patients who had received 1-step surgery for ablation and reconstruction of an osteomeningioma (Table 3). Each patient was presented to the pharmacovigilance committee, which validated the cost for the prosthesis and gave its agreement for surgery.

For this study, operative data (length of stay, operative time) and postoperative complications (infection, hematoma, hydrocephalus) were reviewed. To evaluate the aesthetic results, each

**Table 1.** Characteristics of Group of 23 Patients with Decompressive Craniotomy and Autologous Cranioplasty

Patients	
Total	23 patients
Women	9
Men	14
Average age at time of decompressive craniectomy/craniotomy	28.1 years
Median Glasgow score after decompressive craniectomy/craniotomy	14 (7–15)
Cause of decompressive craniectomy:	
Traumatic brain injury	12
Intracranial hemorrhage	6
Various (stroke, raised intracranial pressure, spontaneous infection)	3
Meningioma	2
Average age during the autologous cranioplasty	28.4 years
Average time between decompressive craniectomy/craniotomy and autologous cranioplasty	101.6 days
Average time between autologous cranioplasty and removal of bone flap	775.2 days
Cause	
Aseptic lysis	12
Osteitis	11

**Table 2.** Characteristics of Group of 8 Patients Who Had Craniectomy without Autologous Cranioplasty

Patients	
Total	8 patients
Women	3
Men	5
Average age at time of decompressive craniectomy	42.15 years
Median of Glasgow scores after the decompressive craniectomy	14 (13–15)
Indication of craniectomy	
Traumatic brain injury	4
Intracranial hematoma	2
Infection	1
Meningioma	1
Reason for no autologous cranioplasty:	
Decompressive craniectomy carried out abroad (not possible to transfer the bone flap)	2
Depressed bone fractures, multiple fractures of the flap	2
Other	4

**Table 3. Characteristics of Group of 6 Patients Who Had 1-Step Implant for Osteomeningioma**

Patients	
Total	6 patients
Women	3
Men	3
Average age	47.9 years

patient was contacted by phone and questioned on the aesthetic (self-assessment) result of the prosthesis. A scale similar to that employed by Rosenthal et al<sup>7</sup> and ranging from 1 (very dissatisfied) to 5 (very satisfied) was used (Table 4). Implant costs (including taxes) were calculated and depended on the number of PEEK blocks (prosthesis volume) needed to make the prostheses.

#### TECHNICAL SPECIFICITY: MANUFACTURE OF THE PROSTHESIS

After the decision to implant a PEEK prosthesis with the patient's agreement, a 3-dimensional (3D) high-resolution computed tomography (CT) scan with millimeter slices was made so that the ideal implant conformation could be calculated according to the defect to be filled. This CT scan was sent to the manufacturer, and the suggested area of resection (if there was a lysis component or persistent bone fragment) and implant design were sent to the surgeons in a portable document format file. The project was validated (or modified then validated) before fabrication of the implant started. Depending on the size of the defect, the implant could be made of 1–3 pieces. A total of 24 implants were provided by the Synthes Holding AG, Solothurn, Switzerland/West Chester, Pennsylvania (2007–2015) and 13 by the Stryker Corporation, Kalamazoo, Michigan (2013–2016).

#### TECHNICAL SPECIFICITY: RECONSTRUCTION IN 1 STEP

This technique was used to design implants in preoperative planning before excision of large osteomeningiomas. It allowed the prosthesis to be ready for use before the intervention, thus avoiding further surgery for cranial vault reconstruction. From a 3D high-resolution CT scan, the lesion was bounded using the open-source software Osirix to create a 3D volume with the planned bone resection. The PEEK prosthesis was then designed on the basis of this tracking. An STL file (widely used for rapid

**Table 4. Scale of Satisfaction with Aesthetic Result**

Satisfaction	
Very dissatisfied	1
Little satisfied	2
Neutral	3
Satisfied	4
Very satisfied	5

prototyping, 3D printing and computer-aided manufacturing) containing the limits predefined for the excision was then provided by the manufacturer to be integrated in the neuronavigation software (Brainlab Kolibri, Munich, Germany). In the operating room, a monoblock excision, guided by the neuronavigation software and predefined limits, was conducted by a double neurosurgical and maxillofacial team. The prosthesis was then fixed immediately.

#### TECHNICAL SPECIFICITY: LIPOSTRUCTURE TECHNIQUE

During follow-up, based on a request from the patient, secondary corrections could be made on the temporal muscle projection, which was often atrophied after several cranial surgeries and frontotemporoparietal approaches. In such cases, lipostucture can be used to correct a lack of temporal projection related to muscle atrophy and improve the aesthetic results for long-term reconstruction, using  $\geq 1$  injections of autologous fat.

Described in 1995 by Sydney R. Coleman, lipostucture is a fat cell autograft technique in which fat cells are taken from the abdominal region most of the time.<sup>8</sup> After being purified by centrifugation, the cells are fed back into a 3D lattice and provide good results in soft tissue reconstruction.

#### RESULTS

The mean follow-up was 4.3 years (from 2.7 months to 9.1 years, SD 2.7 years). The average age at the time of reconstruction was 35.7 years (4.8–77, SD 16.2 years). Implantation of the bone flap was often performed more than 6 months after craniectomy. The average delay was 195 days (from 0–1051, SD 258.4). The average operating time was 2 hours and 19 minutes (from 1 hour and 8 minutes to 4 hours and 57 minutes, SD 1 hour). The average hospitalization time was 6.8 days (from 3–18 days, SD 2.8 days). Figure 2 illustrates the intraoperative implantation of the prosthesis. Depending on the defect size, 1–3 blocks of PEEK were used to make the implant, with an average cost per implant of 7896 euros (from 3200–17107 euros, SD 2840 euros).

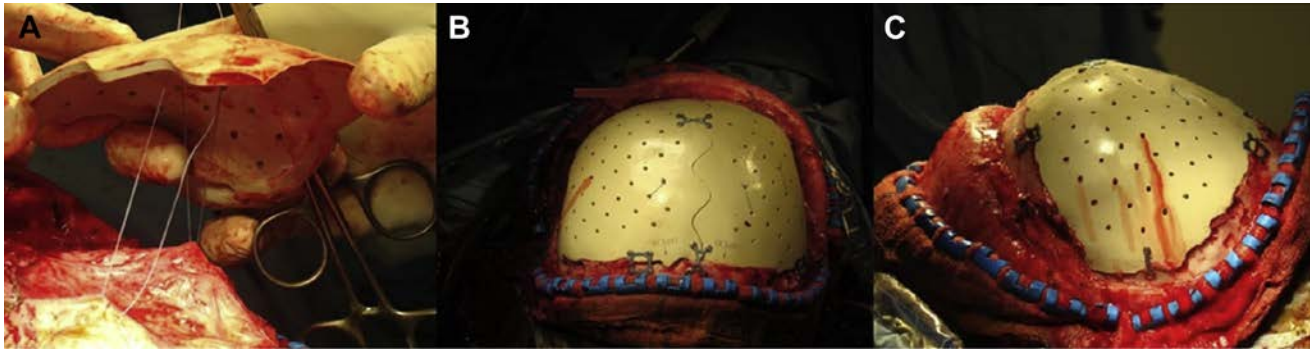
#### Postoperative Complications of Prosthetic Cranioplasty

Three subcutaneous hematomas occurred in the immediate postoperative period, which did not require any surgery. An infection of the PEEK prosthesis was observed in 1 patient whose autologous cranioplasty flap had already been infected (*Pseudomonas aeruginosa* infection of the operating site). A PEEK prosthesis was implemented 91 days after ablation of this flap, and antibiotic treatment was given. Unfortunately, he had to be reoperated 3 months later for a new empyema (*P. aeruginosa*), with removal of the prosthesis.

#### Technical and Aesthetic Results

A correction (drilling) of the prosthesis during the operation was used in only 2 cases (5.4%) in order to improve its implementation. In 6 patients (16%), a defect in the projection of the temporal muscle was noticed postoperatively, leading to 11 lipofilling procedures in these patients (1–3 procedures/patient). The lipofilling was often performed a long time after the insertion of the prosthesis (on average 800 days; SD 440 days). No complications were reported.





**Figure 2.** Intraoperative implantation of the prosthesis. Bifrontal cranial vault reconstruction of a 23 year old patient, injured in a traffic accident, with serious head injury requiring a bifrontal decompressive flap. An autologous cranioplasty was performed 66 days after the decompressive craniectomy but became infected 3 weeks later. A methicillin sensitive *Staphylococcus aureus* infection of the surgical site was diagnosed and

necessitated the removal of the bony component. After antibiotic treatment, a bifrontal polyetheretherketone prosthesis was implanted, 153 days after removal of the component. **(A)** Exposure of cranial defect and suspension of the dura. **(B)** Fixing of the implant with screw and plates. **(C)** Photo of the perfect implantation of the tailored prosthesis.

Thirty patients responded to the survey on their satisfaction with the aesthetic result of the reconstruction. Five could not be reached (by phone or letter). At the last follow-up, 2 patients had died from complications of their initial brain injury. As shown in **Figure 3**, a majority of patients (19) were very satisfied (an example of the aesthetic result is shown in **Figure 4**). **Table 5** details all the complications and aesthetic results for the whole cohort and 3 groups of this study.

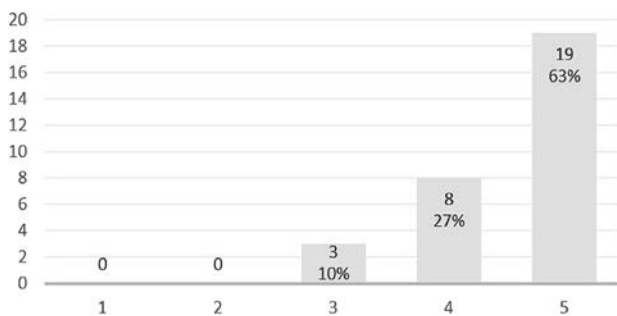
## DISCUSSION

This large cohort of patients who received cranial vault reconstruction with a PEEK prosthesis illustrates the multiple indications of this material for cranial vault reconstruction. The PEEK material can be used with very few complications after aseptic or septic bone resorption, post-traumatic decompressive craniectomy, or for osteomeningioma-scheduled bone sacrifice. The excellent level of aesthetic satisfaction of patients and the perfect intraoperative adaptation of the prosthesis attest to the

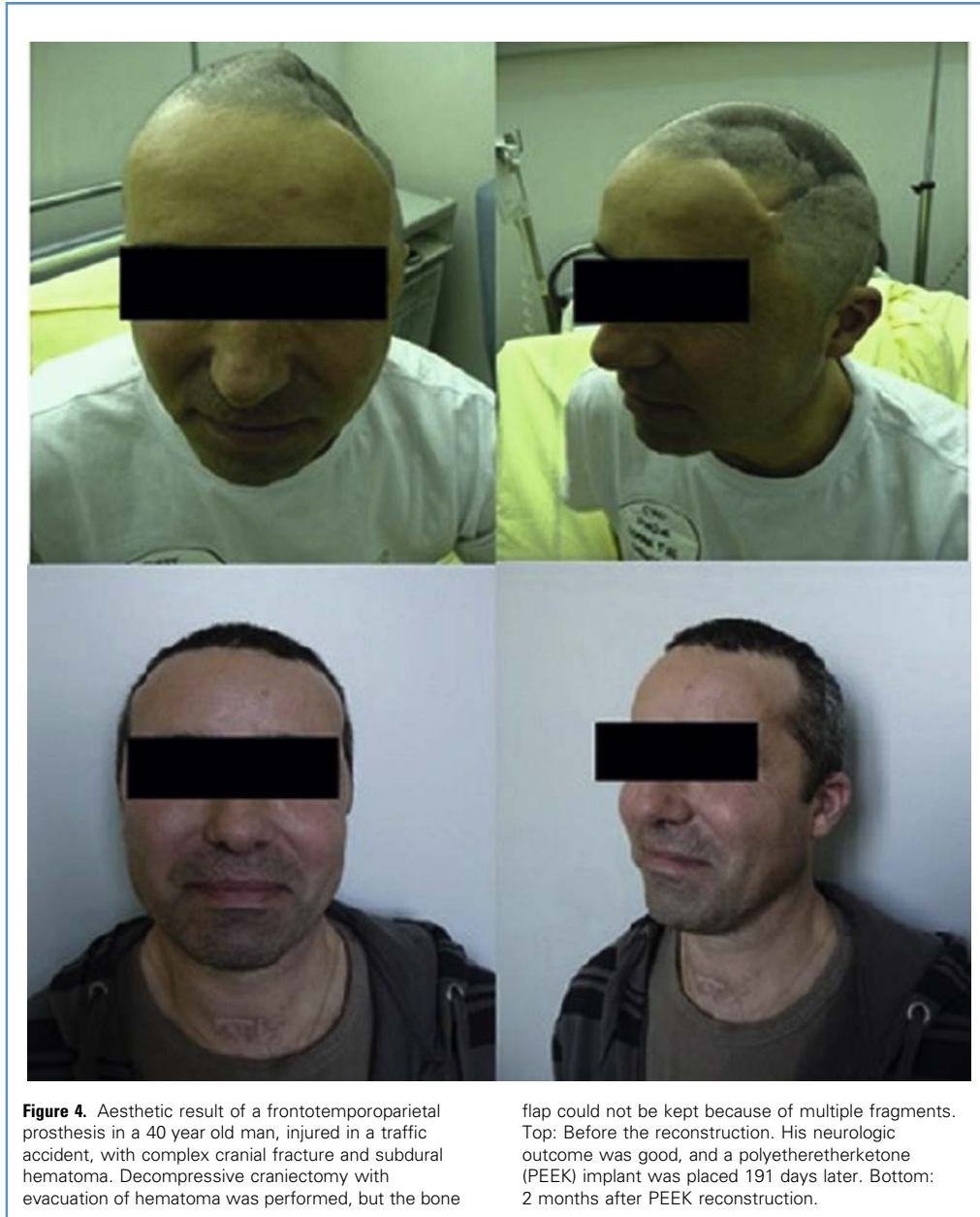interest and usefulness of prostheses that are custom-made from a high-resolution scan of the patient, making it possible to obtain personalized reconstruction with few complications. Our results are in line with those of Rosenthal et al,<sup>7</sup> who published a neurosurgical series of PEEK reconstructions from 3 different centers, showing a significant infection rate of 7.6% and secondary ablation of the prosthesis in 9.1% of patients but otherwise high levels of satisfaction.

PEEK material is increasingly used in neurosurgery or other surgical specialties.<sup>9-13</sup> Its compatibility with biologic and radiologic techniques (absence of artifacts in CT and MRI) make it a first-choice material. The biomechanical characteristics of PEEK prostheses are also interesting. PEEK is a comfortable material that is less dense and lighter than other implants. The Young's modulus, or elastic modulus, of PEEK and bone are similar. It does not conduct heat as a metallic implant would.<sup>14</sup> PEEK implants are frequently used for trauma and orthopedic and spinal defects.<sup>6</sup> Jonkergouw et al<sup>15</sup> found a much higher rate of infection (13%) for 40 patients in 2 different centers with PEEK prostheses and 12.5% of secondary removal of prostheses due to infection. Hanasono<sup>16</sup> reported a series of 6 patients with 0% of infections. In a comparative study between PEEK and titanium cranioplasty, Thien et al<sup>17</sup> did not show significant differences in terms of complications between the 2 materials but detected a trend toward fewer complications with the PEEK.

However, other techniques and materials are available for cranial vault reconstruction.<sup>2-3</sup> Hydroxyapatite, a mineral component of bone, has been described as safe and effective<sup>18</sup> but with low mechanical resistance and thus a risk of fracture of the cranial implant.<sup>19-21</sup> Huang et al<sup>22</sup> reported a series of 22 patients rebuilt with implants in solid polymethylmethacrylate. They reported a good satisfaction result in 20 patients and no infection but secondary removal of the implant to correct a cosmetic defect in 2 of them. In another series described by Lee et al,<sup>23</sup> 17 patients received a



**Figure 3.** Bar graph showing the results for patients' satisfaction. Among 30 patients who responded to the questionnaire, 19 were very satisfied, 8 satisfied, and 3 neutral.



**Figure 4.** Aesthetic result of a frontotemporoparietal prosthesis in a 40 year old man, injured in a traffic accident, with complex cranial fracture and subdural hematoma. Decompressive craniectomy with evacuation of hematoma was performed, but the bone

flap could not be kept because of multiple fragments. Top: Before the reconstruction. His neurologic outcome was good, and a polyetheretherketone (PEEK) implant was placed 191 days later. Bottom: 2 months after PEEK reconstruction.

prosthesis in polymethylmethacrylate with an infection rate of 5.8%. Kumar et al<sup>24</sup> described a series of 5 patients with a large defect to fill (longer axis of >15 cm). They used a porous polyethylene prosthesis and reported no complications. Williams et al,<sup>25</sup> in a series of 151 titanium cranioplasties, showed that the main complication was an infection of the material in 4% of their patients. This statement matched results for the series of Klinger et al,<sup>26</sup> who showed an infection rate of 5.8% in 120 patients receiving acrylic cranioplasty for cranial vault reconstruction. The infection rate of 2.8% in our series is not greater than the latest available data from the literature.

To the best of our knowledge, there are no recommendations in the literature on the necessary waiting period between the removal of an infected bone flap and the placing of a cranial prosthesis. For Cheng et al<sup>27</sup> and Matsuno et al,<sup>28</sup> multiple operations and short delays are risk factors of infection in cranioplasties. To reduce the risk of such infection, a longer period should be proposed to these patients. However, the timing of cranioplasty remains open to discussion. In a meta-analysis of 18 articles, Yadla et al<sup>29</sup> showed that early reintervention (<3 months) was not associated with a higher risk of infection. Nevertheless, the best timing regarding the infection complication rate remains debated.<sup>30</sup> Further studies

**Table 5. Results and Complications After Implantation of Prosthesis**

	Whole Cohort	Decompressive Craniotomy with Autologous Cranioplasty Group	Decompressive Craniectomy without Previous Autologous Cranioplasty Group	1-Step Prosthesis Group
Number of patients	36	23	8	6
Median Glasgow score after reconstruction	15 (7–15)	15 (7–15)	15 (14–15)	15 (15–15)
Length of hospitalization in days	6.8 (3–18, SD 2.8)	7 (4–18, SD 3.3)	5.4 (3–8, SD 1.9)	7.8 (6–10, SD 1.5)
Subcutaneous hematoma	3	2	0	1
Intracranial fluid collection	0	0	0	0
Infection				
Superficial	0	0	0	0
Deep	1	1	0	0
Lipostructure				
Number of patients	5	3	2	1
Number of procedures	10	5	2	3
Average satisfaction score	4.5 (3–5)	4.6 (3–5)	4.4 (3–5)	4.4 (4–5)
Follow up (years)	4.3 (0.2–9.1, SD 2.7)	5.1 (0.2–9.1, SD 2.8)	2.5 (0.4–6.9, SD 2.3)	3.9 (1.6–6.5, SD 1.8)

are needed to better understand the risks associated with the timing of the surgery.

A temporal projection defect is a common problem in neurosurgery after a pterional or frontotemporoparietal flap and various corrections have already been proposed.<sup>31–33</sup> In our series, 16% of patients were corrected by autograft of fat tissue by lipostructure.<sup>34</sup> These patients reported a high level of satisfaction. This original method, coupled with a prosthetic cranioplasty, constitutes a simple and effective solution. No infections or other complications were reported in these patients. It allows the temporal projection to be increased

using fat taken from the abdominal area, with a transplant survival rate of 90%.<sup>8</sup>

## CONCLUSION

This study reports the largest series of PEEK prosthesis cranial vault reconstructions from a single institution. With a very low rate of complications, in terms of infection and secondary implant removal, the use of PEEK should form part of the armamentarium available to the surgeon in the reconstruction of cranial vault defects. In addition, coupled with autologous fat injection to correct a temporal projection defect, it offers excellent rates of patient satisfaction.

## REFERENCES

1. Wachter D, Reineke K, Behm T, Rohde V. Cranioplasty after decompressive hemicraniectomy: underestimated surgery-associated complications? *Clin Neurol Neurosurg*. 2013;115:1293–1297.
2. Harris DA, Fong AJ, Buchanan EP, Monson L, Khechoyan D, Lam S. History of synthetic materials in alloplastic cranioplasty. *Neurosurg Focus*. 2014;36:E20.
3. Shah AM, Jung H, Skirboll S. Materials used in cranioplasty: a history and analysis. *Neurosurg Focus*. 2014;36:E19.
4. Abdullah MR, Goharian A, Abdul Kadir MR, Wahit MU. Biomechanical and bioactivity concepts of polyetheretherketone composites for use in orthopedic implants a review: bio mechanical and bioactivity concepts of PEEK. *J Biomed Mater Res A*. 2015;103:3689–3702.
5. Schwitala A, Müller WD. PEEK dental implants: a review of the literature. *J Oral Implantol*. 2013;39:743–749.
6. Kurtz SM, Devine JN. PEEK biomaterials in trauma, orthopedic, and spinal implants. *Biomaterials*. 2007;28:4845–4869.
7. Rosenthal G, Ng I, Moscovici S, Lee KK, Lay T, Martin C, et al. Polyetheretherketone implants for the repair of large cranial defects: a 3-center experience. *Neurosurgery*. 2014;75:523–529.
8. Coleman SR. Structural fat grafting: more than a permanent filler. *Plast Reconstr Surg*. 2006;118(suppl 3):108S–120S.
9. Goodson ML, Farr D, Keith D, Banks RJ. Use of two-piece polyetheretherketone (PEEK) implants in orbitozygomatic reconstruction. *Br J Oral Maxillofac Surg*. 2012;50:268–269.
10. Scolozzi P, Martinez A, Jaques B. Complex orbito-fronto-temporal reconstruction using computer-designed PEEK implant. *J Craniofac Surg*. 2007;18:224–228.
11. Najeeb S, Zafar MS, Khurshid Z, Siddiqui F. Applications of polyetheretherketone (PEEK) in oral implantology and prosthodontics. *J Prosthodont Res*. 2016;60:12–19.
12. Jalbert F, Lauwers F. Custom-made implants for craniofacial reconstruction. *Rev Stomatol Chir Maxillo-faciale Chir Orale*. 2013;114:211–218.
13. Jalbert F, Boetto S, Nadon F, Lauwers F, Schmidt E, Lopez R. One-step primary reconstruction for complex craniofacial resection with PEEK custom-made implants. *J Cranio-Maxillofac Surg*. 2014;42:141–148.
14. Lethaus B, Safi Y, ter Laak-Poort M, Kloss-Brandstätter A, Banki F, Robbenmenke C, et al. Cranioplasty with customized titanium and PEEK implants in a mechanical stress model. *J Neurotrauma*. 2012;29:1077–1083.



15. Jonkergouw J, van de Vijfeijken SE, Nout E, Theys T, Van de Castele E, Folkersma H, et al. Outcome in patient-specific PEEK cranioplasty: a two-center cohort study of 40 implants. *J Cranio-Maxillofac Surg.* 2016;44:1266-1272.
16. Hanasono MM, Goel N, DeMonte F. Calvarial reconstruction with polyetheretherketone implants. *Ann Plast Surg.* 2009;62:653-655.
17. Thien A, King NK, Ang BT, Wang E, Ng I. Comparison of polyetheretherketone and titanium cranioplasty after decompressive craniectomy. *World Neurosurg.* 2015;83:176-180.
18. Stefani R, Esposito G, Zanotti B, Iaccarino C, Fontanella MM, Servadei F. Use of "custom made" porous hydroxyapatite implants for cranioplasty: postoperative analysis of complications in 1549 patients. *Surg Neurol Int.* 2013;4:12.
19. Adetchessi AT, Pech-Gourg G, Metellus P, Fuentes S. [Fracture of macroporous hydroxyapatite prosthesis]. *Neurochirurgie.* 2012;58:382-385.
20. Staffa G, Nataloni A, Compagnone C, Servadei F. Custom made cranioplasty prostheses in porous hydroxy-apatite using 3D design techniques: 7 years experience in 25 patients. *Acta Neurochir (Wien).* 2007;149:161-170.
21. Hardy H, Tollard E, Derrey S, Delcampe P, Peron JM, Freger P, et al. [Clinical and ossification outcome of custom-made hydroxyapatite prosthesis for large skull defect]. *Neurochirurgie.* 2012;58:25-29.
22. Huang GJ, Zhong S, Susarla SM, Swanson EW, Huang J, Gordon CR. Craniofacial reconstruction with poly(methyl methacrylate) customized cranial implants. *J Craniofac Surg.* 2015;26:64-70.
23. Lee SC, Wu CT, Lee ST, Chen PJ. Cranioplasty using polymethyl methacrylate prostheses. *J Clin Neurosci.* 2009;16:56-63.
24. Kumar NG, Sreenivas M, Gowda S. Cranioplasty of large cranial defects with porous polyethylene implants. *J Craniofac Surg.* 2016;27:e333-e335.
25. Williams LR, Fan KF, Bentley RP. Custom-made titanium cranioplasty: early and late complications of 151 cranioplasties and review of the literature. *Int J Oral Maxillofac Surg.* 2015;44:599-608.
26. Klinger DR, Madden C, Beshay J, White J, Gambrell K, Rickert K. Autologous and acrylic cranioplasty: a review of 10 years and 258 cases. *World Neurosurg.* 2014;82:e525-e530.
27. Cheng YK, Weng HH, Yang JT, Lee MH, Wang TC, Chang CN. Factors affecting graft infection after cranioplasty. *J Clin Neurosci.* 2008;15:1115-1119.
28. Matsuno A, Tanaka H, Iwamuro H, Takanashi S, Miyawaki S, Nakashima M, et al. Analyses of the factors influencing bone graft infection after delayed cranioplasty. *Acta Neurochir (Wien).* 2006;148:535-540.
29. Yadla S, Campbell PG, Chitale R, Maltenfort MG, Jabbour P, Sharan AD. Effect of early surgery, material, and method of flap preservation on cranioplasty infections: a systematic review. *Neurosurgery.* 2011;68:1124-1129.
30. Corallo F, De Cola MC, Lo Buono V, Marra A, De Luca R, Trinchera A, et al. Early vs late cranioplasty: what is better? *Int J Neurosci.* 2017;127:688-693.
31. Choudhry OJ, Christiano LD, Arnaout O, Adel JG, Liu JK. Reconstruction of pterional defects after frontotemporal and orbitozygomatic craniotomy using Medpor Titan implant: cosmetic results in 98 patients. *Clin Neurol Neurosurg.* 2013;115:1716-1720.
32. Badie B. Cosmetic reconstruction of temporal defect following peritonal craniotomy. *Surg Neurol.* 1996;45:383-384.
33. Kubo S, Takimoto H, Kato A, Yoshimine T. Endoscopic cranioplasty with calcium phosphate cement for pterional bone defect after frontotemporal craniotomy: technical note. *Neurosurgery.* 2002;51:1094-1096.
34. Coleman SR. Facial recontouring with lipostucture. *Clin Plast Surg.* 1997;24:347-367.