



## Double homemade fenestrated stent graft for total endovascular aortic arch repair

Ludovic Canaud, Baris Ata Ozdemir, Lucien Chassin-Trubert, Julien Sfeir,  
Pierre Alric, Thomas Gandet

### ► To cite this version:

Ludovic Canaud, Baris Ata Ozdemir, Lucien Chassin-Trubert, Julien Sfeir, Pierre Alric, et al.. Double homemade fenestrated stent graft for total endovascular aortic arch repair. *Journal of Vascular Surgery*, 2019, 10.1016/j.jvs.2018.11.054 . hal-02092475

**HAL Id: hal-02092475**

**<https://hal.science/hal-02092475>**

Submitted on 18 May 2020

**HAL** is a multi-disciplinary open access archive for the deposit and dissemination of scientific research documents, whether they are published or not. The documents may come from teaching and research institutions in France or abroad, or from public or private research centers.

L'archive ouverte pluridisciplinaire **HAL**, est destinée au dépôt et à la diffusion de documents scientifiques de niveau recherche, publiés ou non, émanant des établissements d'enseignement et de recherche français ou étrangers, des laboratoires publics ou privés.

# Double homemade fenestrated stent graft for total endovascular aortic arch repair

Ludovic Canaud, MD, PhD, Baris Ata Ozdemir, FRCS, PhD, Lucien Chassin-Trubert, MD, Julien Sfeir, MD, Pierre Alric, MD, PhD, and Thomas Gandet, MD, *Montpellier, France*

## ABSTRACT

**Objective:** The aim of this retrospective analysis was to evaluate the outcomes of physician-modified double fenestrated stent grafts for total endovascular aortic arch repair: one proximal large fenestration for the brachiocephalic trunk and the left common carotid artery and one distal fenestration for the left subclavian artery (LSA).

**Methods:** From January 2017 through February 2018, 17 patients (88.2% elective) underwent thoracic endovascular aortic repair (TEVAR) with double homemade fenestrated stent graft for total endovascular aortic arch repair to maintain supra-aortic trunk patency. Indications were degenerative aortic arch aneurysm ( $n = 7$ ), dissecting aortic arch aneurysms subsequent to surgical treatment of acute type A dissections ( $n = 6$ ), chronic complicated type B aortic dissection ( $n = 3$ ), and acute complicated type B aortic dissection ( $n = 1$ ). Routine postoperative follow-up imaging with computed tomography angiography was performed to assess TEVAR and supra-aortic trunks patency and endoleak.

**Results:** The median time for stent graft modification was 19 minutes (range, 16-20 minutes). Endovascular exclusion of the aortic arch was achieved in all the cases. One LSA catheterization failed and LSA revascularization was performed by carotid axillary bypass and coverage of the LSA fenestration by additional stent graft placement. Additional planned endovascular procedures were required in three patients: closure of supra-aortic trunks re-entry tears in two cases of dissecting aortic arch aneurysms and one transcatheter aortic valve replacement for severe native aortic valve regurgitation. One stroke, with no long-term deficit, was observed. No patients died. All left supra-aortic trunks are patent. No type I endoleak was observed. We only observed one patient with a type II endoleak. During a mean follow up of  $7 \pm 2$  months, there were no conversions to open surgical repair, aortic rupture, paraplegia, or retrograde dissection.

**Conclusions:** Double homemade fenestrated TEVAR is both feasible and effective for maintaining the patency of the supra-aortic trunks and allows total endovascular aortic arch repair. Durability concerns will need to be assessed in additional studies with long-term follow-up.

**Keywords:** Thoracic aorta; Aortic arch; Aorta; Physician-modified thoracic stent grafts; TEVAR

Open surgery remains the gold standard in aortic arch repair for aneurysms or dissections. Mortality and morbidity associated with transverse aortic arch replacement in the standard risk population has decreased over the past few decades with the implementation of various modifications of the surgical technique. Various strategies have been developed to limit the morbidity and mortality associated with open surgical repair, the major concern being neurologic morbidity with a reported rate of perioperative stroke ranging from 5% to 12%.<sup>1,2</sup> Selective cerebral perfusion associated with hypothermia during circulatory arrest seems to reduce neurologic morbidity.<sup>3</sup> Despite these recent advances, aortic arch

reconstruction remains challenging, particularly in elderly patients, those requiring emergency repair, or those with major pre-existing comorbidities. Many patients are deemed unsuitable for open repair.<sup>4</sup>

Dake et al<sup>5</sup> first reported the use of stent grafting to treat descending thoracic aortic pathology and the results of endovascular repair since then have been good. The aortic arch, however, continues to be a challenge for the endovascular approach. Landing zones are limited and there is the requirement to preserve the blood flow to supra-aortic trunks. Typically, debranching is a necessity at the time of thoracic endovascular aortic repair (TEVAR). The alternate strategy of the chimney technique in combination with TEVAR significantly risks type I endoleak arising from the gutter spaces. Branched stent grafts have been proposed that permit completely percutaneous aortic arch repair.<sup>6</sup> The disadvantages of this modular approach include the time required to manufacture and deliver custom-made stent grafts for urgent cases and the high costs associated with these sorts of modular devices. Most notably, there is a high rate of embolization associated with this approach, probably related to the complexity of deploying a multibranched unibody stent graft.<sup>7</sup> The results of inner branched endograft repair of the aortic arch in contemporary series demonstrates an

---

From the Department of Thoracic and Vascular Surgery, Arnaud de Villeneuve Hospital.

Author conflict of interest: none.

improvement in patient outcome when compared with the early experience of the approach published in 2014.<sup>8,9</sup>

An alternative option is a physician-modified thoracic stent graft. This procedure involves the deployment of a conventional stent graft device, the fashioning of customized fenestrations, and reconstraining the device into the delivery system. Our group has previously published good early results for aortic arch aneurysms using a single fenestration combined or not with cervical debranching.<sup>10</sup> To achieve a completely endovascular aortic exclusion of the arch, we sought to review our experience with of double homemade fenestrated stent grafts that permit total endovascular aortic arch repair: one proximal large fenestration for the brachiocephalic trunk (BT) and the left common carotid artery (LCCA) and one distal fenestration for the left subclavian artery (LSA).

## METHODS

**Patients.** Protocol and informed consent were approved by the institutional review boards. All patients gave written consent, and the local authorities approved the study. Patients treated using physician-modified thoracic stent grafts for the treatment of aortic arch lesions in one tertiary referential center were included (A de Villeneuve Hospital, Montpellier, France). All patients were at high surgical risk owing to serious comorbidities (American Society of Anesthesiologists score of  $\geq$ III or emergent repair). All aortic arch lesions are discussed between vascular and cardiothoracic surgeons and the latter is routinely involved during the endovascular procedure.

Our practice of TEVAR with physician modified double fenestrated stent grafts commenced in January 2017. Essentially, the stent graft has two fenestrations: one proximal large fenestration for the BT and the LCCA. The size of the proximal fenestration was laterally 2 mm larger than that of the BT and LCCA orifices and one distal fenestration for the LSA of appropriate size relative to the diameter of the LSA. The distance between both fenestrations is the distance between the LCCA and LSA as measured on the preoperative computed tomography (CT) scan.

Patients with zone 1 aortic arch lesions or zone 0 saccular aneurysms on the lesser curvature of the arch are appropriate for this approach if the lengths of the proximal and distal neck (length from distal end of aneurysm to celiac artery) are at least 20 mm and if the proximal and distal neck diameters are between 20 and 40 mm (Table I). Zone 0 aortic arch lesions, except saccular aneurysms on the lesser curvature of the arch, were deemed unsuitable because the size of the proximal fenestration was proximally and laterally larger than that of the BT and LCCA orifice, increasing the risk of endoleak. Preoperative CT angiography (CTA) was performed on the whole cohort. A prospective database was

- **Type of Research:** Retrospective single-institution cross-sectional cohort study
- **Key Findings:** Seventeen patients underwent thoracic endovascular aortic repair with double homemade fenestrated stent graft for total endovascular aortic arch repair. One stroke without permanent sequelae was noted. There were no deaths. All left supra-aortic trunks were patent. No type I endoleak was observed.
- **Take Home Message:** Double homemade fenestrated stent graft allows total endovascular aortic arch repair; however, durability should be evaluated in additional studies with long-term follow-up.

routinely updated with demographic, anatomic, and intraoperative and postoperative details. Follow-up CTA was performed at 1 week, 3 and 6 months, and annually thereafter.

**Planning, sizing, and device preparation.** At the beginning of our experience we used a vascular imaging workstation (Aquarius WS; Terarecon Inc, Mateo, Calif) and currently we use the EndoSize Workstation (Therenva, Nanjing, France) with centerline luminal reconstructions. Stent grafts of adequate length and diameter were identified to seal between a minimum of 2 cm of healthy aorta at each end. The stent graft (oversizing of <10% in acute aortic dissection and 10%-15% for other indications).

The planning of a custom two-fenestration thoracic stent graft is similar to an abdominal graft, except that the greater curvature line, rather than the centerline of flow, is used to measure lengths including the distance between the aortic branches (Supplementary Video 1, online only). The centerline of flow views are still used to measure aortic diameters as well as determine the "clock positions" for the origin of each supra-aortic trunk vessel. The diameters of the BT, LCCA, and LSA were determined from axial images.

Volume-rendered reconstructions identified the ideal C-arm angulation values required to evaluate the arch. The stent graft alterations, starting prior to the initiation of anesthesia, were performed on a back table. Only the segment to be altered plus one further stent is unsheathed (Fig 1; Supplementary Video 1, online only). Fenestrations are fashioned in accordance with the preoperative measurements.

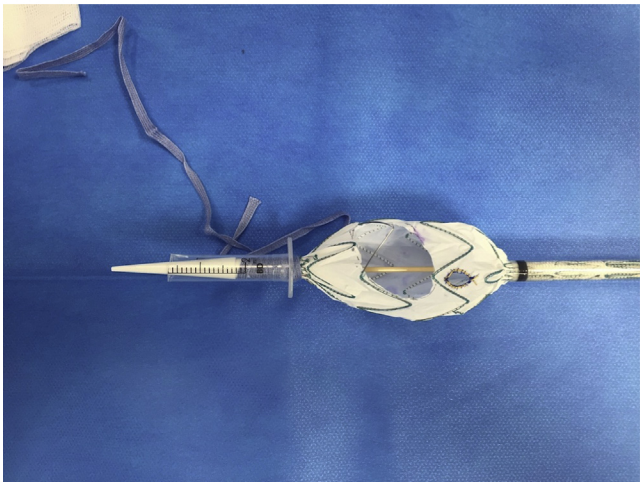
The proximal large fenestration for the BT and the LCCA of appropriate size (2 mm larger laterally than that of the BT and LCCA orifices) is made without removing the stent graft stent struts.

The distal circular fenestration for the LSA matched the diameter of the native vessel origin. The site of the LSA



**Table 1.** Inclusion and exclusion criteria used for double homemade fenestrated stent graft for total endovascular aortic arch repair

Inclusion criteria
Proximal and distal neck
Length: >20 mm
Diameter >20 mm and <40 mm
Zone 1 aortic arch lesions
Zone 0 saccular aneurysms at the lesser curvature of the arch
Emergent or elective cases
Exclusion criteria
Zone 0 aortic arch lesions, except saccular aneurysms at the lesser curvature of the arch



**Fig 1.** The Valiant thoracic stent graft was partially unsheathed. The proximal large fenestration for the brachiocephalic trunk (BT) and the left common carotid artery (LCCA) is made without removing the stent graft stent struts. The distal circular fenestration for the left subclavian artery (LSA) of appropriate size orifice is made with no stents struts crossing the fenestration lumen. Radiopaque markers are positioned and delineated the fenestration for the LSA.

fenestration was chosen such that it was not crossed by stent struts. Clock position is used to determine the position of the LSA relative to the position of the BT and LCCA island using the reconstructed images.

For the proximal large fenestration, to avoid damage to the fabric the fenestration was created using a size 11 blade. At least 5 mm of fabric seems to be required between the proximal fenestration and the proximal edge of the stent graft to not compromise the integrity and stability of the graft. A cautery device is used to fashion the LSA fenestration. A nitinol wire (loop of a snare, EV3 Amplatz Goose Neck Snare, Medtronic, Santa Rosa, Calif) is sutured around the fenestration both to reinforce seal (dilation of a covered stent against the nitinol ring) and to mark the position.

**Technique.** Placement of the double fenestrated stent graft is based on the principle that accurate placement of the LSA fenestration secured by covered stent placement will appropriately align the proximal fenestration for the BT and LCCA the position has been determined by preoperative axial imaging.

General anesthesia and surgical exposures of the femoral artery were used in all patients. Heparin was administered because the stent graft is passed over an extra-stiff guide wire guide wire. Angiographic runs were achieved using a pigtail catheter, advanced percutaneously through the contralateral femoral.

Around the time of stent graft unsheathing, the mean blood pressure is decreased to roughly 80 mmHg. Because we required a variable amount of time to cannulate the LSA fenestration, we did not use rapid pacing during stent graft deployment. An angiogram strictly perpendicular to the LSA is obtained to achieve clock face alignment. Because the origins of the supra-aortic trunks are from the arch's cranial aspect, the delivery system is positioned such that the stent graft fenestrations are oriented superiorly when introduced into the arch. Specifically, the LSA marker is aligned with the LSA. If misaligned, the stent graft was pulled back in the descending thoracic aorta, rotated to adjust the position of fenestration, and reintroduced into the aortic arch. Large axial adjustments in the arch are ill-advised because of the risk of embolization and indeed because of the poor torquability of the stent graft in this location. Through left brachial access the tip of a 7F sheath is positioned at the origin of the LSA. The stent graft is partly unsheathed. Through the brachial sheath, a 0.035-inch guidewire is passed through the fenestration into the stent graft followed by the 7F brachial sheath. Stent graft deployment is completed. A balloon-expandable covered stent (8-10 mm diameter by 38 or 59 mm length; iCAST, Atrium, Hudson, NH) is deployed protruding approximately 5 mm into the aortic stent graft lumen, with the remaining length in the LSA. The proximal part of the covered stent is flared with a 14- to 20-mm balloon.

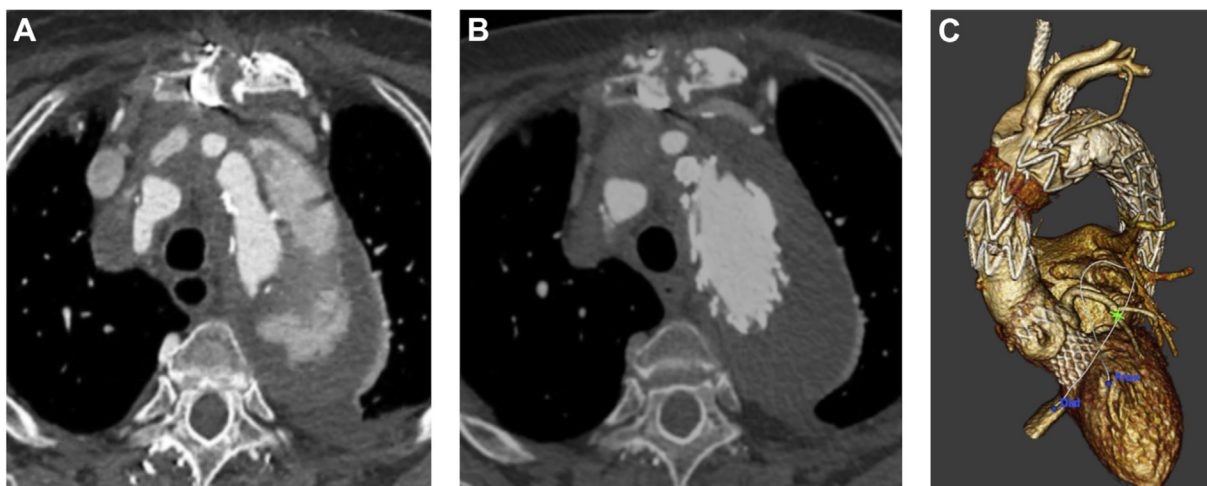
Serial surveillance CTAs at 1 week, then 3, 6, and 12 months, and annually thereafter are performed (Fig 2). Ultrasound imaging was limited to cases of clinically or CTA-identified concerns.

**RESULTS**

From January 2017 through February 2018, 17 patients underwent TEVAR with double homemade fenestrated stent graft for total endovascular aortic arch repair to preserve the patency of the supra-aortic trunks (Table II). There were 14 men and three women (mean age, 69.6 ± 14 years; range, 43-83 years).

Of the operations performed, 88.2% % (n = 15) were elective. There were 7 degenerative aortic arch aneurysms, 6 dissecting aortic arch aneurysms subsequent





**Fig 2. (A)** A computed tomography (CT) scan showed a dissecting aortic arch aneurysm (6 cm) aneurysms subsequent to surgical treatment of acute type A dissections. **(B)** A CT scan showed exclusion of the dissecting aortic arch aneurysm (6 cm) aneurysms subsequent to surgical treatment of acute type A dissections after deployment of a double homemade fenestrated stent graft. **(C)** Three-dimensional volume rendering reconstruction showed the double homemade fenestrated stent graft and patency of the supra-aortic trunks.

**Table II.** Characteristics of the patients

Characteristic	
Male sex	14 (82.2)
Age, years	69.6 (43-83)
High blood pressure	16 (94.1)
Dyslipidemia	9 (52.9)
Diabetes mellitus	4 (23.5)
Chronic obstructive pulmonary disease	6 (25.5)
Coronary arterial diseases	4 (23.5)
Left ventricular ejection fraction of <40%	3 (17.6)
Prior thoracic aorta surgery	8 (47.5)
Emergent cases	2 (11.8)
Values are presented as number (%) or median (range).	

to surgical treatment of acute type A dissections, 3 chronic complicated type B aortic dissections, and 1 acute complicated type B aortic dissection constituted the indications (Table III).

During the time of the study, 17 patients underwent open aortic arch replacement and two patients had zone 0 hybrid aortic arch repair. The Valiant device (Medtronic) was the only stent graft used. On average, 1.8 stent grafts (range, 1-2) were deployed (mean proximal seal length,  $26.5 \pm 4.0$  mm). The mean length of the proximal fenestration was 21 mm (range, 18-25 mm). Mean length between the fenestrations was 5.3 mm (range, 5-8 mm). Associated endovascular procedures included transcatheter aortic valve replacement in one case and supra-aortic trunks reentry tear closure by covered stent graft placement in two cases.

**Thirty-day outcomes.** The median duration for stent graft modification was 19 minutes (range, 16-20 minutes). Endovascular exclusion of the aortic arch was achieved in all cases (Supplementary Video 2, online only). One LSA catheterization failed and LSA revascularization was performed by carotid axillary bypass and coverage of the LSA fenestration by additional stent graft placement. The fenestration was misaligned. We believe that this was an error of deployment rather than a sizing error. The patient had a small diameter aorta (24 mm), and the fenestration ended up on the right side of the LSA. Although we could touch the radiopaque marker with the guidewire, we could not cannulate the fenestration. Before full deployment, aortography was performed using contralateral femoral access to confirm the patency of the BT and of the LCCA. This patient was the third in our experience. One stroke with no long-term deficit was observed. In this patient, near complete visual loss was observed immediately postoperatively. A CT scan of the brain demonstrated hypodense lesions in both occipital lobes and numerous old and new infarcts in all other territories. He had full recovery by day 4. The patient had an irregular thrombus-lined aorta. The overall mortality was 0% (Table IV). All left supra-aortic trunks were patent. No type I endoleak has been identified. One type II endoleak (from the LSA) without sac expansion is currently observed. No paraplegia or retrograde dissection was observed.

**Follow-up.** After a  $7 \pm 2$  months of surveillance, there were no conversions to open surgical repair, aortic rupture, paraplegia, or retrograde dissection. All supra-aortic trunks are patent.

**Table III.** Indications for endovascular aortic arch repair

Indications	
Degenerative saccular aortic arch aneurysms at the lesser curvature of the arch	4 (23.5)
Zone 1 degenerative aortic arch aneurysms	3 (17.6)
Zone 1 dissecting aortic arch aneurysms subsequent to surgical treatment of acute type A dissections	6 (35.2)
Zone 1 chronic complicated type B aortic dissection	3 (17.6)
Zone 1 acute complicated type B aortic dissection	1 (5.8)
Mean aortic aneurysm diameter mm	63 (44-97)
Values are presented as number (%) or median (range).	

**Table IV.** Thirty-day outcomes

Mean operative time, minutes	96 (45-164)
Median volume of contrast media, mL	94 (60-155)
Median dose-area product, Gy/cm <sup>2</sup>	42 (21-55)
ICU stay, days	1.1
Hospital stay, day	6.1
Early postoperative complications	
In-hospital death	0 (0)
Endoleak	
Type I	0 (0)
Type II	1 (5.8)
Type III	0 (0)
Early secondary procedures	0 (0)
Cerebrovascular events	1 (5.8)
SCI	0 (0)
Late postoperative complications	
Cardiovascular events	1 (5.8)
Mortality	0 (0)
Endoleak	
Type I	0 (0)
Type II	1 (5.8)
Type III	0 (0)
Late secondary procedure	0 (0)
ICU, Intensive care unit; SCI, spinal cord injury. Values are presented as number (%) or median (range), unless otherwise indicated.	

**DISCUSSION**

This study reports our experience with physician-modified double fenestrated stent grafts for total endovascular aortic arch repair. With no aortic mortality or type I endoleaks, and patency of all the supra-aortic trunks, it can be concluded that this method is feasible and delivers promising early outcomes. The specific feature of this double fenestrated device is its simple handling during operation with the proximal fenestrations being directed to the orifices of the BT and LCCA automatically when the LSA fenestration is catheterized and secured by covered stent placement. The large proximal fenestration accommodates the trunks with a low risk of occlusion. Bare metal or covered stents are not required for these branches. Aligning the graft based on only the LSA

fenestration is one of the most important intraoperative advantages of our approach. The deployment algorithm actively steers the operator away from superfluous manipulations of the device within the arch and avoids guide-wire manipulation in the BT and in the LCCA. We believe that is likely to be the reason for the significantly lower procedural stroke risk as compared with other approaches. This approach is an off-label use of the Valiant stent graft. Our group has a large experience with complex thoracic endovascular repairs (>800 TEVARs performed). The risk of technical failure with the double fenestrated approach may be increased if performed by unexperienced teams. Before achieving total endovascular aortic arch repair, we have gained experience performing homemade proximal scalloped stent grafts, physician fenestrated stent grafts for TEVAR of zone 2 aortic lesions,<sup>11,12</sup> and single fenestrated stent grafts for TEVAR of zone 0 and zone 1 aortic lesions combined with cervical debranching procedures.<sup>10</sup>

There are special anatomic considerations when using this technique. Zone 0 aortic arch lesions, except saccular aneurysms at the lesser curvature of the arch, were deemed unsuitable because the size of the proximal fenestration was proximally and laterally larger than that of the BT and LCCA orifice, increasing the risk of endoleak. They can be treated using a branched stent graft. Of note, altered branched stent grafts for thoracoabdominal aortic aneurysms are presently underinvestigated; therefore, a homemade branched thoracic stent graft can also be anticipated for the arch.<sup>13</sup>

All such systems are modified, necessitating precise preoperative preparation. Confirming that fenestrations are properly oriented toward the supra-aortic trunk origins is critical. As with all custom modified devices, malrotation and malalignment of the fenestration and vessel origin can arise. Achieving proper alignment of the fenestrations is easier when implanting short stent grafts. However, in most cases, a second distal stent graft will be required and a 5-cm overlap between the two stent grafts is required, which is why our preference is to use a 150-mm length graft. In two emergent cases, to achieve correct oversize, we used stent grafts of 200 mm in length because shorter stent grafts were not available in our stock at this time. Slight rotational adjustments



of the stent graft to finetune the position of fenestrations once the first few stents are deployed remains possible; this factor increases the risk of cerebral embolization. One stroke without permanent sequelae was observed. Although it is possible that the conformation of the arch may change after insertion of the semirigid stent graft, altering the orientation of the trunks, we did not encounter this complication in this series. It may be necessary to manipulate a semiconstrained or partially deployed arch stent graft to orient fenestrations correctly. The addition of reducing ties could be used to facilitate longitudinal and rotational movements of the stent graft, allowing for the adjustment of the position of fenestrations to facilitate cannulation of target vessels. We would, however, be concerned that additional manipulation in the arch could increase the neurologic morbidity.

We did not use wire reinforcement of the large fenestration. We are not concerned about durability because we are using the same design as the Zenith Fenestrated stent graft system (Cook Medical, Bloomington, Ind) where large fenestrations are not reinforced by a nitinol ring.<sup>14</sup>

We do not feel that the absence of a radiologic marker for the BT/LCCA is dangerous. Procedure and device preparation planning using a dedicated three-dimensional vascular imaging workstation is crucial. Furthermore, to decrease the risk of inadvertent coverage of the supra-aortic trunk, the proximal fenestration is 2 mm larger laterally than that of the BT and LCCA orifices. During the procedure, innominate artery blood flow is closely monitored using a right radial artery pressure arterial line. The adequacy of cerebral perfusion was systematically assessed using near-infrared spectroscopy. We must also acknowledge that we are a group with a large experience with complex thoracic endovascular repairs (>800 cases done so far) and our approach may be at risk of technical failure if performed by inexperienced teams. The outcomes reported of our experience—17 cases without any inadvertent coverage of the BT and LSA—support, however, the appropriateness of the approach in experienced hands.

Using an unstented fenestration for the innominate and LCCA increases the theoretical risk of stent graft migration and shuttering. However, the stent graft is anchored by the LSA stenting and proximal scalloped TEVAR is an established technique, and no cases of stent graft migration have been reported.<sup>15</sup>

The bailout strategies in case of failure of placement of the larger fenestration, are first to pull back the partly unsheathed stent graft, in the descending thoracic aorta and to deploy the stent graft in the descending aorta. In this situation supra-aortic debranching is required to complete the TEVAR, thus treating the aortic arch lesion and covering the fenestration of the first graft. Alternatively, if the pull-back attempt fails, left carotid and brachiocephalic chimney grafts can be inserted after

bilateral carotid exposure. Third, if the chimney attempt fails, complete rerouting of the supra-aortic trunks via a median sternotomy would have to be performed.

In case of type I endoleak placement of a large bare metal stent (Zenith Dissection Endovascular stent [Cook Medical] or E-XL [Jotec GmbH, Hechingen, Germany]) into the arch extending into zone 0 to enhance the stability of the fenestrated graft could be proposed. In case of type I endoleak perfused by the proximal fenestration, a complete rerouting of the supra-aortic trunks via a median sternotomy and additional stent graft placement would be required.

Compared with other endovascular techniques, the double homemade fenestrated stent graft led to fewer neurologic complications. This finding can be explained by several factors. First, with careful preoperative planning, the simple handling of the device during operation decreases manipulations in the aortic arch. Namely, the proximal fenestration is appropriately directed to the orifices of the BT and LCCA automatically when the LSA fenestration is catheterized. Second, no manipulation, clamping, catheterization, or stenting of the BT and LCCA is required.

We anticipate that the excellent neurologic outcomes of the double fenestrated approach stem from the minimization of wire, catheter, and device manipulations in the arch and, indeed, total avoidance in the innominate and LCCA. For this reason, although we are reluctant to stent these vessels, we acknowledge that an unstented fenestration increases the theoretical risk of stent graft migration with time and shuttering. It should be noted that the aortic stent graft is anchored by the LSA stenting and proximal scalloped TEVAR is an established technique, and no cases of stent graft migration have been reported. It should also be noted that significant migration—enough to cause shuttering of either the innominate or left common carotid—would likely lead to a large type IA endoleak with perfusion of the supra-aortic trunks. Nevertheless, because significant shuttering without endoleak could lead to severe complications, regular and careful surveillance of these patients is required.

The resilience of physician-modified stent grafts is a critical concern. Fabric durability in this context is unclear. Metal and material failure are recognized complications of stent grafting. Modifications may alter the overall ring stability of the graft. Routine radiologic examination to date in this series has not identified any stent fractures. The continuing interaction between the stent graft and the covered stent will require close observation because of the potential for stent collapse or fracture. Delayed type III endoleaks between components is also a possibility.

The disadvantages are the necessity for the physician to spend time modifying the stent graft, a lack of industrial quality control after device modification, and the lack of a sizeable body of evidence supporting its use. The modification of commercially available devices by physicians



may void any guarantee of safety by the manufacturer, and a systematic evaluation of such devices is best done within a protocol approved at the institutional and/or regulatory level.

The Medtronic stent graft was used because of our wide-ranging experience with and knowledge of this device. Furthermore, the tip capture helps with the accuracy of deployment. Alternative stent grafts suitable for this strategy are the Bolton (Bolton Medical, Sunrise, Fla) and the Cook Alpha (Cook Medical). The mechanism of deployment of the Gore device (W. L. Gore & Associates, Inc, Flagstaff, Ariz) does not allow reloading into the sheath.

Several alternatives exist that facilitate a satisfactory proximal seal for TEVAR. Both surgical debranching and the chimney technique are possible strategies for proximal landing of stent grafts while preserving branch blood flow. The former requires an additional invasive procedure. The latter is less invasive, but there are concerns about type I gutter endoleaks between components.

In situ retrograde laser fenestration of the LSA is a viable and effective technique. In a report of 22 patients, technical success was 100% with no major operative complications related to the technique.<sup>7</sup>

Custom-made branched devices are currently available. The world experience with 38 branched arch devices was first reported as a multicenter experience in 2014 by Haulon et al.<sup>7</sup> These investigators reported a 13% mortality rate, a 16% stroke rate, a technical failure rate of 15.8%, and a secondary procedure rate of 19.6%. Factors such as the planning and manufacturing delays, anatomic and technical restrictions, as well as expense limit the widespread uptake of this technology, particularly for emergent cases. In particular, the technical challenges of branch catheterization results in an intrinsically high risk of cerebral embolism. The results of inner branched endograft repair of the aortic arch in contemporary series demonstrates an improvement in patient outcome when compared with the early experience of the approach published in 2014.<sup>8,9</sup>

Some Japanese units have described extensive experience with custom large fenestration arch TEVAR, augmenting the safety margin during deployment. In a recent study,<sup>16</sup> this approach was used to treat those with a short seal zone distal to the LCCA (mean length, 11 mm; range, 5-15 mm). There was a 32.4% type Ia endoleak rate at discharge and 16.2% of aneurysms enlarged at follow-up. The exclusively large fenestrations combined with the absence of supra-aortic trunk cannulation (like the LSA in our experience) to accurately align the fenestration to the target vessels may have led to a greater tendency to type I endoleak.

In the absence of an off-the-shelf stent graft, many individuals with emergent (rapidly expanding, symptomatic, or ruptured) aneurysms, notably those who are poor candidates for open repair, have limited options with the exception of physician modification. Naturally, further

data are needed to confirm the applicability of this approach and establish durability. Extended careful surveillance of these stent grafts is required to evaluate and ensure the durability of the repair because of the possibility for mechanical failure.

## CONCLUSIONS

The use of double homemade fenestrated stent graft is both feasible and effective for maintaining the patency of the supra-aortic trunks and allows for total endovascular aortic arch repair. Worries about durability need to be evaluated in further studies with longer follow-up times.

## AUTHOR CONTRIBUTIONS

Conception and design: LC, BO, LT, JS, PA, TC  
Analysis and interpretation: LC, BO, LT, JS, PA, TC  
Data collection: LC, BO, LT, JS, PA, TC  
Writing the article: LC, BO, LT, JS, PA, TC  
Critical revision of the article: LC, BO, LT, JS, PA, TC  
Final approval of the article: LC, BO, LT, JS, PA, TC  
Statistical analysis: Not applicable  
Obtained funding: Not applicable  
Overall responsibility: LC

## REFERENCES

1. Estrera AL, Miller CC 3rd, Lee TY, Shah P, Safi HJ. Ascending and transverse aortic arch repair: the impact of retrograde cerebral perfusion. *Circulation* 2008;118:160-6.
2. Minatoya K, Ogino H, Matsuda H, Sasaki H, Tanaka H, Kobayashi J, et al. Is conventional aortic arch surgery justifiable in octogenarians? *J Thorac Cardiovasc Surg* 2010;139:641-5.
3. Kazui T, Yamashita K, Washiyama N, Terada H, Bashar AH, Suzuki K, et al. Usefulness of antegrade selective cerebral perfusion during aortic arch operations. *Ann Thorac Surg* 2002;74:1806-9.
4. Kurazumi H, Mikamo A, Kudo T, Suzuki R, Takahashi M, Shirasawa B, et al. Aortic arch surgery in octogenarians: is it justified? *Eur J Cardiothorac Surg* 2014;46:672-7.
5. Dake MD, Miller DC, Semba CP, Mitchell RS, Walker PJ, Liddell RP. Transluminal placement of endovascular stent-grafts for the treatment of descending thoracic aortic aneurysms. *N Engl J Med* 1994;331:1729-34.
6. Abraham CZ, Lioupis C. Treatment of aortic arch aneurysms with a modular transfemoral multibranched stent-graft: initial experience. *J Thorac Cardiovasc Surg* 2013;145:110-7.
7. Haulon S, Greenberg RK, Spear R, Eagleton M, Abraham C, Lioupis C, et al. Global experience with an inner branched arch endograft. *J Thorac Cardiovasc Surg* 2014;148:1709-16.
8. Spear R, Hertault A, Van Calster K, Settembre N, Delloye M, Azzaoui R, et al. Complex endovascular repair of post-dissection arch and thoracoabdominal aneurysms. *J Vasc Surg* 2018;67:685-93.
9. Pear R, Haulon S, Ohki T, Tsilimparis N, Kanaoka Y, Milne CP, et al. Editor's choice - subsequent results for arch aneurysm repair with inner branched endografts. *Eur J Vasc Endovasc Surg* 2016;51:380-5.
10. Canaud L, Baba T, Gandet T, Narayama K, Ozdemir BA, Shibata T, et al. Physician-modified thoracic stent-grafts for the treatment of aortic arch lesions. *J Endovasc Ther* 2017;24:542-8.
11. Canaud L, Gandet T, Khantalin I, Ozdemir BA, Marty-Ané CH, Alric P. Homemade proximal scalloped stent graft for

thoracic endovascular aortic repair of zone 2 acute aortic syndrome. *J Thorac Cardiovasc Surg* 2016;152:1301-6.

12. Canaud L, Morishita K, Gandet T, Sfeir J, Bommart S, Alric P, et al. Homemade fenestrated stent-graft for thoracic endovascular aortic repair of zone 2 aortic lesions. *J Thorac Cardiovasc Surg* 2018;155:488-93.
13. Georgiadis GS, van Herwaarden JA, Antoniou GA, Hazenberg CE, Giannoukas AD, Lazarides MK, et al. Systematic review of off-the-shelf or physician modified fenestrated and branched endografts. *J Endovasc Ther* 2016;23:98-109.
14. de Almeida Sandri G, Ribeiro MS, Macedo TA, Vrtiska T, Oderich GS. Planning endovascular aortic repair with standard and fenestrated-branched endografts. *J Cardiovasc Surg (Torino)* 2017;58:204-17.
15. Ben Abdallah I, El Batti S, Sapoval M, Abou Rjeili M, Fabiani JN, Julia P, et al. Proximal scallop in thoracic endovascular aortic aneurysm repair to overcome neck issues in the arch. *Eur J Vasc Endovasc Surg* 2016;51:343-9.
16. Kurimoto Y, Maruyama R, Ujihira K, Nishioka N, Hasegawa K, Iba Y, et al. Thoracic endovascular aortic repair for challenging aortic arch diseases using fenestrated stent grafts from zone 0. *Ann Thorac Surg* 2015;100:24-33.