



**HAL**  
open science

## Trans-iliac Bypass for Critical Limb Ischaemia with Groin Necrosis: A Case Report

Youcef Lounes, Baris Ozdemir, Pierre Alric, Ludovic Canaud

► **To cite this version:**

Youcef Lounes, Baris Ozdemir, Pierre Alric, Ludovic Canaud. Trans-iliac Bypass for Critical Limb Ischaemia with Groin Necrosis: A Case Report. *EJVES Short Reports*, 2019, 42, pp.31-33. 10.1016/j.ejvssr.2019.01.002 . hal-02092460

**HAL Id: hal-02092460**

**<https://hal.science/hal-02092460>**

Submitted on 11 Jun 2020

**HAL** is a multi-disciplinary open access archive for the deposit and dissemination of scientific research documents, whether they are published or not. The documents may come from teaching and research institutions in France or abroad, or from public or private research centers.

L'archive ouverte pluridisciplinaire **HAL**, est destinée au dépôt et à la diffusion de documents scientifiques de niveau recherche, publiés ou non, émanant des établissements d'enseignement et de recherche français ou étrangers, des laboratoires publics ou privés.

# Trans-iliac Bypass for Critical Limb Ischaemia with Groin Necrosis: A Case Report

Youcef Lounes<sup>\*</sup>, Baris A. Ozdemir, Pierre Alric, Ludovic Canaud

Vascular and Thoracic Surgery, CHRU of Montpellier, France

**Introduction:** Infections at the level of the groin involving native or prosthetic vessels are typically bypassed using the obturator canal. However, extensive wounds or infections, particularly those involving the medial compartment of the thigh, can preclude this approach.

**Report:** A 66 year old male with diabetes mellitus presented after several previous revascularisations of the femoral artery with extensive necrosis of the groin and critical limb ischaemia with necrotic changes in the toes. An iliopopliteal bypass through the iliac wing was planned because of the extent of the infection.

**Discussion:** The post-operative course was uneventful with complete resolution of tissue loss at one year follow up.

## INTRODUCTION

The treatment of combined critical limb ischaemia and surgical site infection is challenging for the vascular specialist. The majority of such cases with groin surgical site infection can be treated by trans-obturator bypass in conjunction with local debridement.<sup>1</sup> However, an extensive medial wound, particularly involving the medial thigh compartment, can preclude this approach.

## REPORT

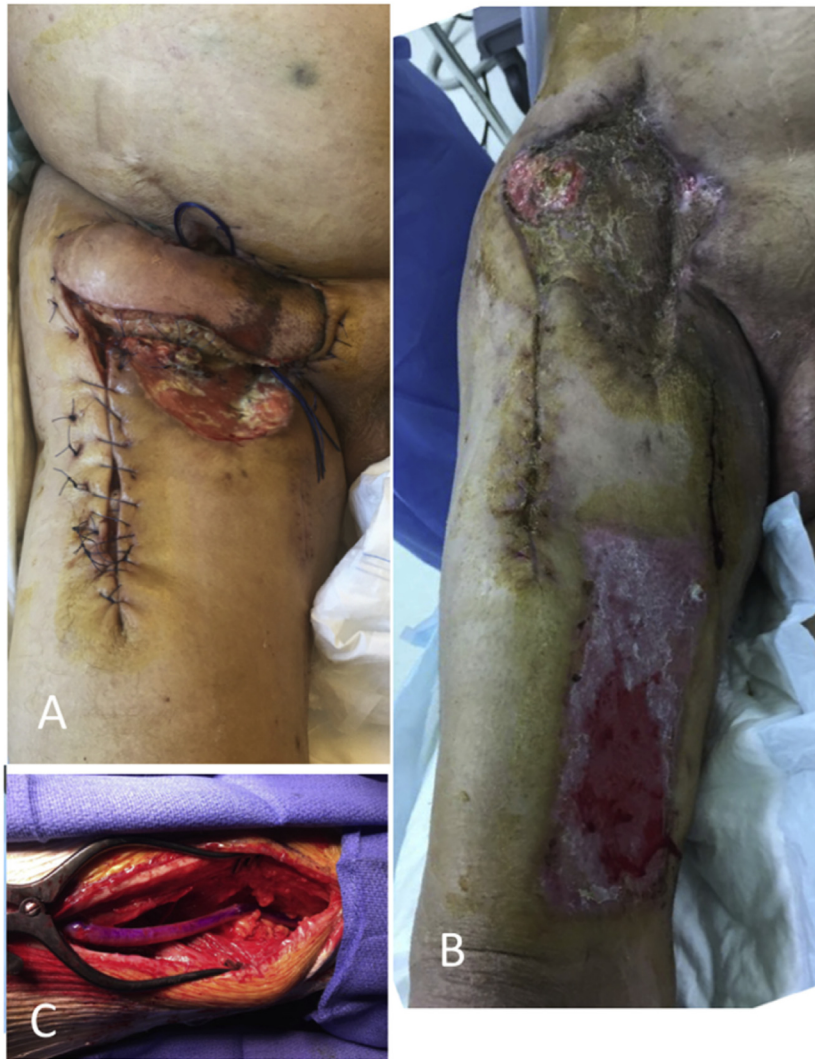The patient was a 66 year old male, ex-smoker with diabetes, dyslipidaemia, COPD, and peptic ulceration who had been treated previously with a very short distal external iliac to origin of profunda femoris artery prosthetic bypass, with reimplantation of the superficial femoral artery for claudication. At six months he was readmitted with graft infection (methicillin sensitive staphylococcus aureus), associated

groin wound dehiscence, and critical ischaemia secondary to occlusion of the superficial femoral artery. The prosthetic graft was explanted and in situ reconstruction was performed using a composite bypass of cryopreserved allograft to the profunda femoris. Patency of the superficial femoral artery could not be restored intra-operatively and therefore a saphenous vein jump graft was performed to the above knee popliteal artery. Surgical transfer of the sartorius muscle was used to protect the graft. Cefazolin was administered for 30 days. The post-operative course was complicated by extensive necrosis of the groin wound. This was managed with a myocutaneous flap (Fig. 1A), topical negative pressure wound therapy, and split skin grafting. He was readmitted at one month with recurrent critical limb ischaemia associated with necrotic toes. Salvage of the occluded above knee popliteal bypass by thrombectomy was unsuccessful.

As a consequence of the extensive groin and medial thigh wounds (Fig. 1B), a common iliac to popliteal bypass, through the iliac wing was selected for revascularisation. A retroperitoneal approach was used to expose the common iliac artery to which was anastomosed an 8 mm reinforced PTFE graft. The 1 cm fenestration in the iliac wing was formed from without (lateral to medial), initially by drilling four holes and then completing the process with a chisel.

<sup>\*</sup> Corresponding author. Vascular and Endovascular Surgery, Hospital Arnaud de Villeneuve, 371 avenue Doyen Gaston Giraud, 34295 Montpellier, France.

E-mail address: [youcefounes@gmail.com](mailto:youcefounes@gmail.com) (Youcef Lounes).



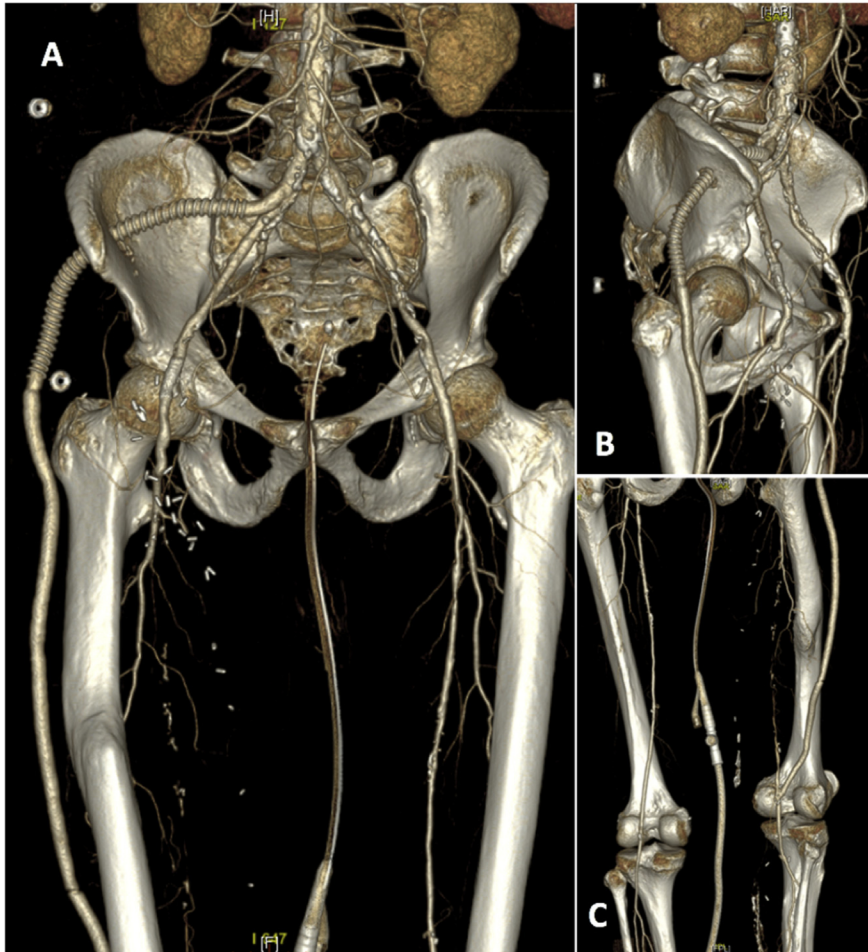
**Figure 1.** Wound of the groin (A) myocutaneous flap after groin necrosis. (B) Pre-operative status. (C) Distal anastomosis to the popliteal artery by lateral exposure.

From the fenestration the bypass was tunnelled deep to fascia lata. Popliteal artery exposure was via a lateral approach. The distal anastomosis was constructed, using a cold stored venous allograft, to the retro-articular popliteal artery laterally (Fig. 1C). Cefazolin was administered for a further 15 days. The post-operative course was uneventful (Fig. 2), with complete resolution of tissue loss after minor amputation. The patient had significant hip pain requiring one week of morphine. With physiotherapy the patient could walk fully independently after one month. At one year follow up, the bypass remains patent without graft or wound infection.

## DISCUSSION

Trans-iliac bypass is reported only infrequently in the literature, but appears to be a safe approach with acceptable patency.<sup>2-5</sup> Proximal anastomosis to the aorta<sup>2</sup> or the common iliac artery<sup>3-5</sup> is preferred to avoid kinking

of the graft. If required, the distal anastomosis can reach as far as the tibial artery<sup>2</sup> by lateral exposure. Favre et al.<sup>4</sup> report five cases with nine to 24vmonth follow up with no cases of graft thrombosis. Similarly, Katsamouris et al.<sup>5</sup> described four cases with no graft thrombosis at six to 55 months. No cases of closure of the iliac wing fenestration from osteogenesis have been observed.<sup>2-5</sup> Prosthetic grafts were used in the majority,<sup>2-5</sup> but a vein or a composite bypass may be preferable in bypasses to the below knee arteries. One case<sup>3</sup> of trans-iliac bypass with a lateral approach to the popliteal artery is described. This approach to the retro-articular part of the popliteal artery is both more accessible and has a straighter course. The major advantage of the trans-iliac bypass is the graft's increased distance from the site of infection relative to the trans-obturator bypass. It is also easier to perform. The principal disadvantages are the limited experience that can be gleaned from the literature, and the transitory



**Figure 2.** Post-operative computed tomography with three dimensional reconstructions, (A) anterior view, (B) lateral view, (C) posterior view, showing the distal anastomosis to the retro-articular popliteal artery.

post-operative pain, of which both the patient and the surgical team should be aware.

In conclusion, the trans-iliac iliopopliteal approach is both feasible and useful in cases of extensive groin and medial compartment infection.

#### CONFLICTS OF INTEREST

None.

#### FUNDING

None.

#### REFERENCES

1 Nevelsteen A, Mees U, Deleersnijder J, Suy R. Obturator bypass: a sixteen year experience with 55 cases. *Ann Vasc Surg* 1987;**1**: 558–63.

2 Heldenberg E, Lorber J, Cheyn D, Bass A. Transiliac wing alternate route bypass for infected groin vascular graft. *J Vasc Surg* 2014;**60**:504–5.

3 Donayre CE, Ewbanks P, Ayers B, de Virgilio C, Klein SR. Iliac to popliteal artery bypass through the iliac wing: an alternative extracavitary route for management of complex groin injuries. *Ann Vasc Surg* 1999;**13**:209–15.

4 Favre JP, Gournier JP, Barral X. Trans-osseous ilio-femoral bypass. A new extra-anatomical by-pass. *J Cardiovasc Surg (Torino)* 1993;**34**:455–9.

5 Katsamouris AN, Giannoukas AD, Alamanos E, Karniadakis S, Petrakis I, Drositis I, et al. Experience with new techniques for extraanatomic arterial reconstruction of the lower limb. *Ann Vasc Surg* 2000;**14**:444–9.