



HAL
open science

Liver fibrosis staging using supersonic shear imaging : a clinical study on 142 patients

Eric Bavu, Jean-Luc Gennisson, Bruno-Félix Osmanski, Jeremy Bercoff, Mathias Fink, Vincent Mallet, Philippe Sogni, Anaïs Vallet-Pichard, Bertrand Nalpas, Mickael Tanter, et al.

► To cite this version:

Eric Bavu, Jean-Luc Gennisson, Bruno-Félix Osmanski, Jeremy Bercoff, Mathias Fink, et al.. Liver fibrosis staging using supersonic shear imaging : a clinical study on 142 patients. 2009 IEEE International Ultrasonics Symposium, Sep 2009, Roma, France. hal-02088300

HAL Id: hal-02088300

<https://hal.science/hal-02088300>

Submitted on 2 Apr 2019

HAL is a multi-disciplinary open access archive for the deposit and dissemination of scientific research documents, whether they are published or not. The documents may come from teaching and research institutions in France or abroad, or from public or private research centers.


L'archive ouverte pluridisciplinaire **HAL**, est destinée au dépôt et à la diffusion de documents scientifiques de niveau recherche, publiés ou non, émanant des établissements d'enseignement et de recherche français ou étrangers, des laboratoires publics ou privés.

Éric Bavi¹, Jean-Luc Gennisson¹, Bruno-Félix Osmanski², Jérémy Bercoff², Mathias Fink¹, Vincent Mallet³, Philippe Sogni³, Anaïs Vallet-Pichard³, Bertrand Nalpas³, Mickaël Tanter¹ and Stanislas Pol³

¹ Institut Langevin Ondes et Images, Laboratoire Ondes et Acoustique, ESPCI ParisTech, CNRS UMR 7587, INSERM ERL 979, Paris, France.

² SuperSonic Imagine, Aix en Provence, France.

³ Service d'Hépatologie, Hôpital Cochin, Paris, France.



BACKGROUND AND AIMS : Liver biopsy is still considered as the “gold standard” to assess the liver fibrosis level, despite strong limitations. We aim at showing the performances of SSI for the staging of liver fibrosis in patients with chronic liver disease, and at making a comparison with the performances of Fibroscan (FS).

1. MATERIAL AND METHODS

COHORT :

- 142 consecutive patients with chronic liver disease.
- Reference fibrosis level assessed by two experienced pathologists using liver biopsy and surrogate serum markers (Fib-4, APRI, Forns).
- Fibroscan examination on the same day.
- 104 patients with successful measurements (blood samples, Fibroscan and SSI) included in statistical study.

SUPERSONIC SHEAR IMAGING SEQUENCE :

- “Pushing beams” at increasing depths of the tissues (remote acoustic radiation force inducing a shear wave) using a curved ultrasonic probe (2.5 MHz, 128 elements).
- Movie of tissues displacement field induced by the shear waves, acquired by an ultrafast echographic device (4000 frames/sec) using the same ultrasonic probe.
- The liver's tissues stiffness (Young's modulus) is then derived from the propagation velocity ($E = 3\rho v_s^2$).

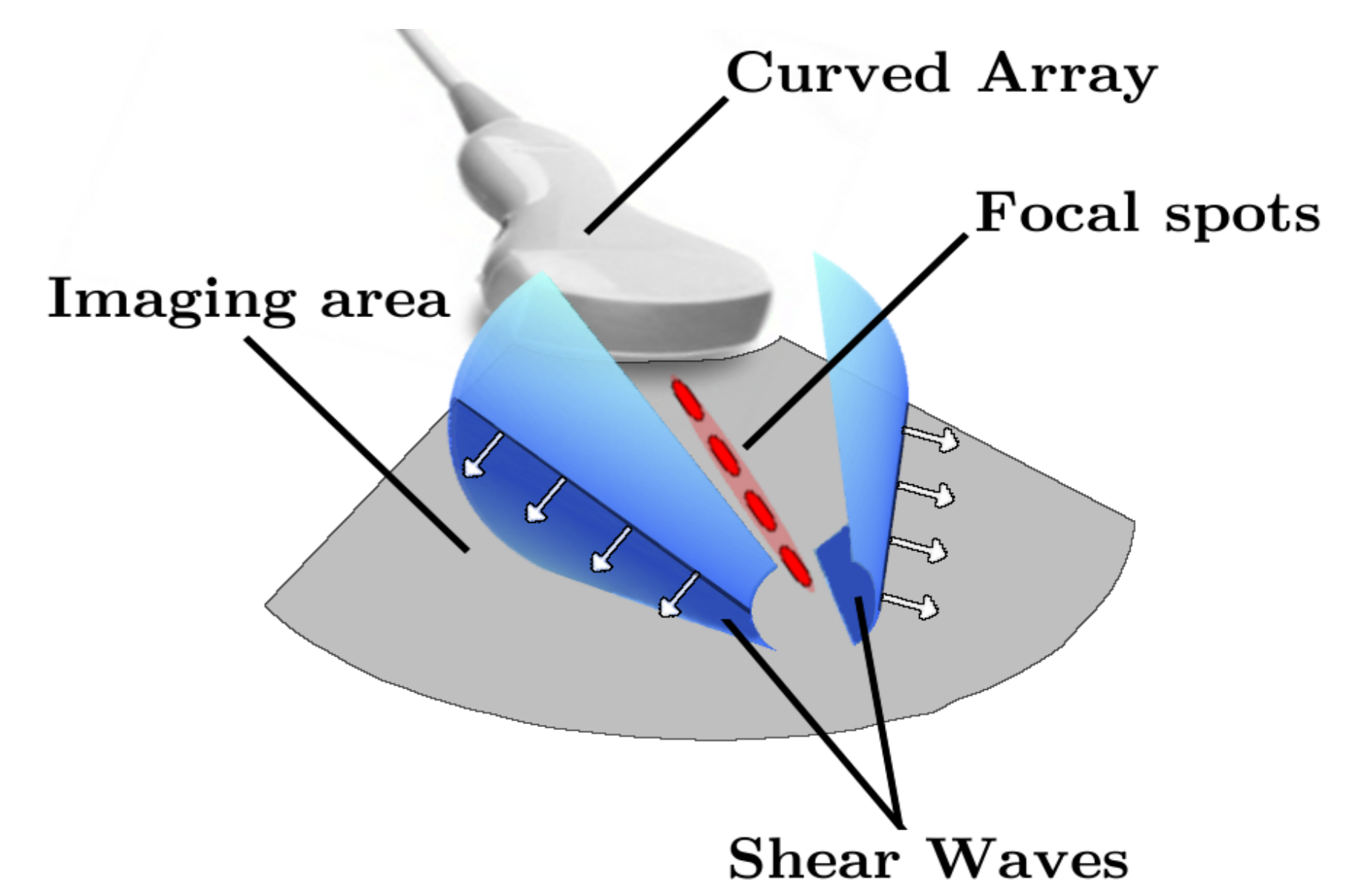


Fig. 2: Generation of a conical shear wave from pushing beams at increasing depths

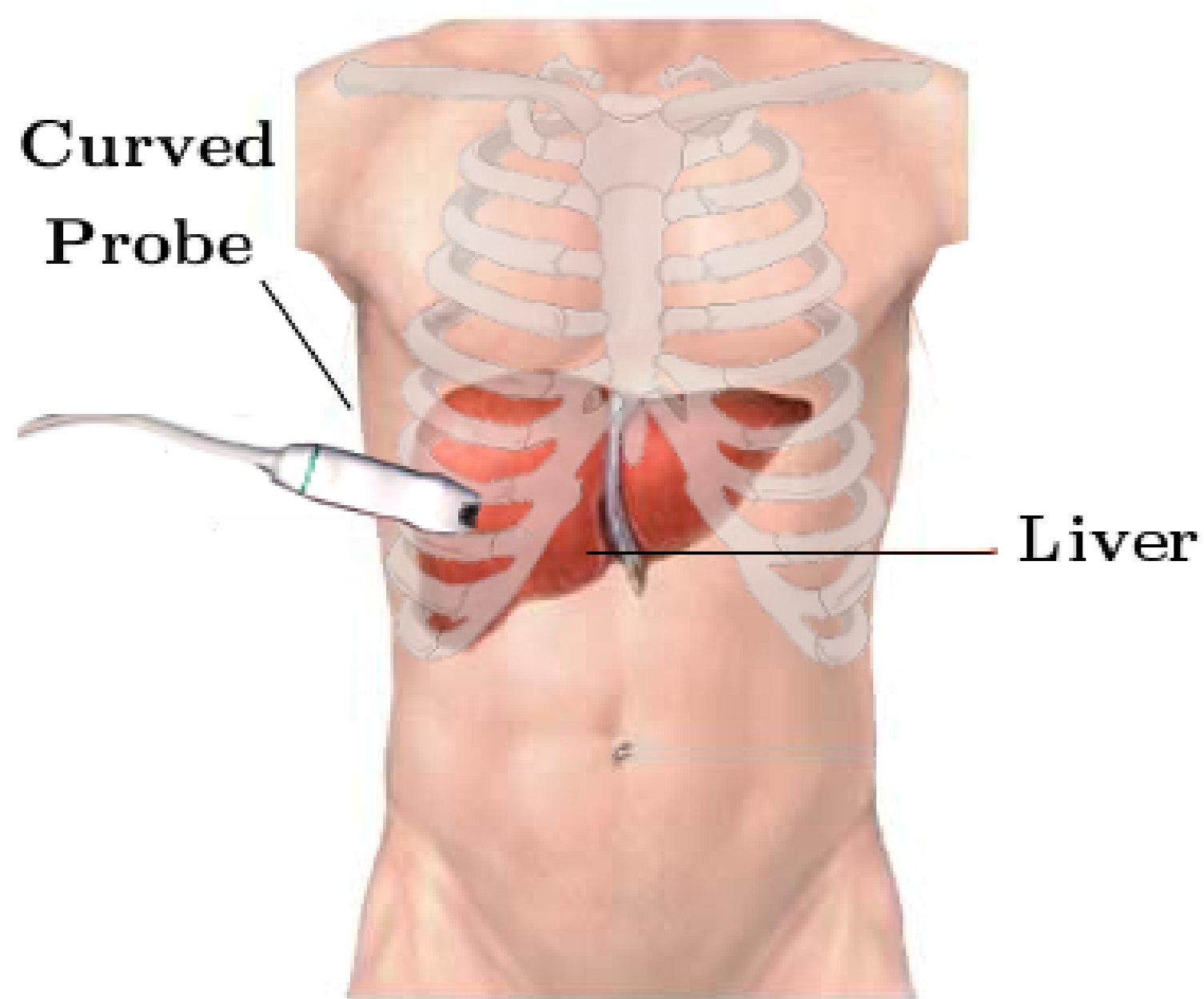


Fig. 1: Probe positioning for the SSI liver elasticity measurement

EACH MEASUREMENT SEQUENCE LASTS LESS THAN 2 SEC.

2. LIVER STIFFNESS MAPPING

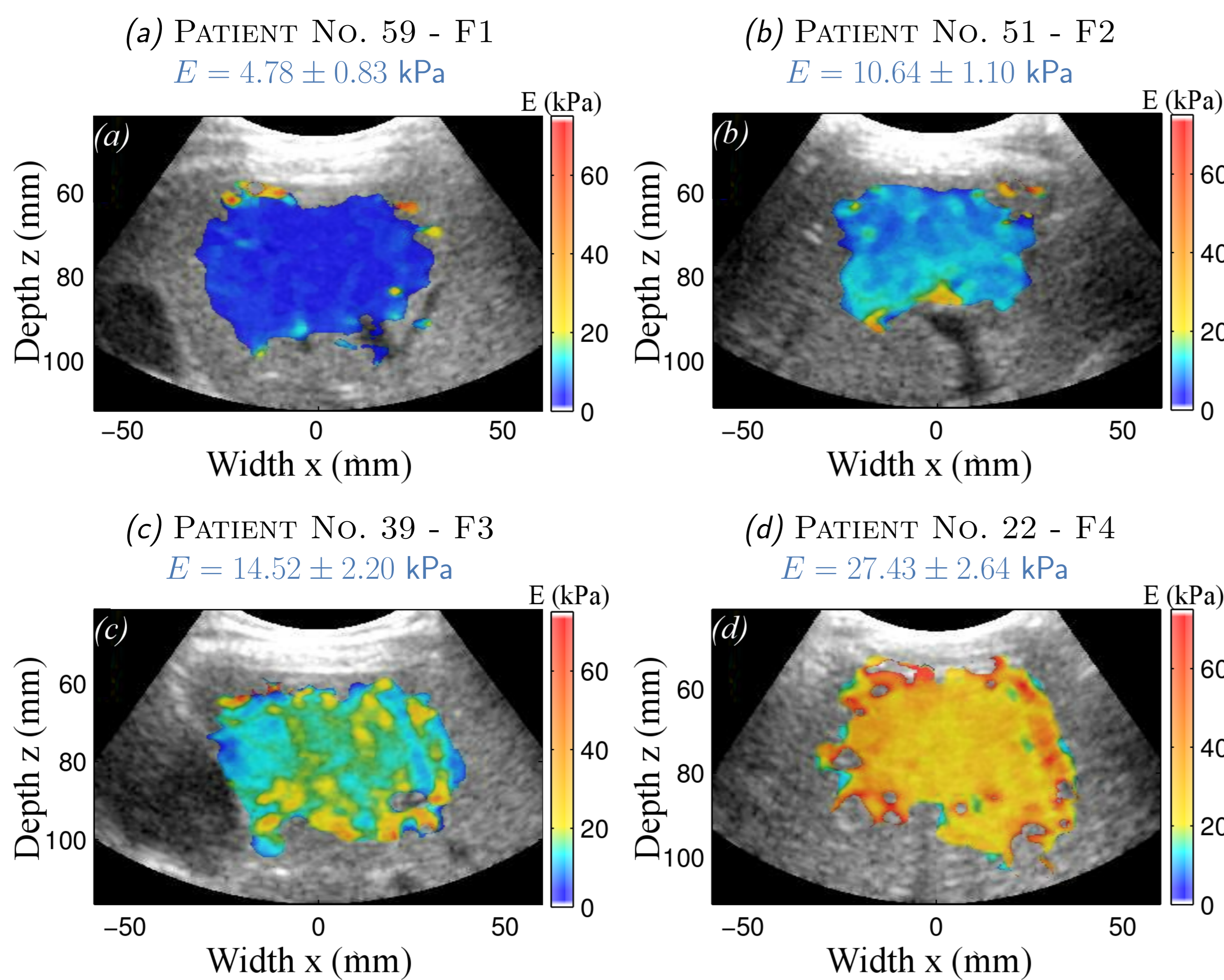


Figure 3 : Bidimensional liver elasticity maps assessed using SSI for 4 patients with different fibrosis levels, superimposed with corresponding B-scans

MAPS OF LARGE AREA OF THE LIVER : $16.39 \text{ cm}^2 \pm 2.77 \text{ cm}^2$.
LIVER HETEROGENEITIES ARE LESS LIKELY TO INTRODUCE BIASES IN THE ELASTICITY MEASUREMENT WITH SSI(2D) THAN WITH FIBROSCAN(1D).

3. FIBROSIS LEVEL STAGING

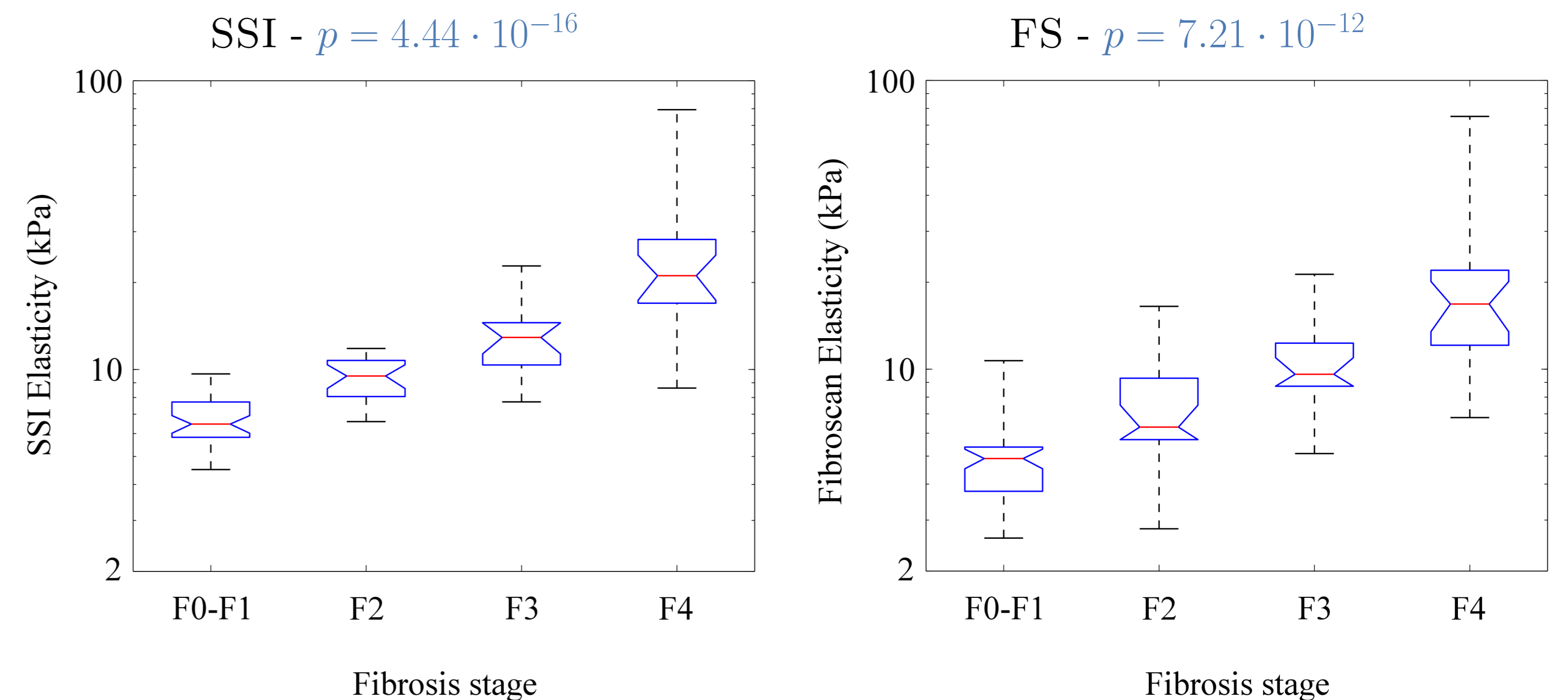


Figure 4 : Box and Whisker : Analysis of Variance for fibrosis level staging

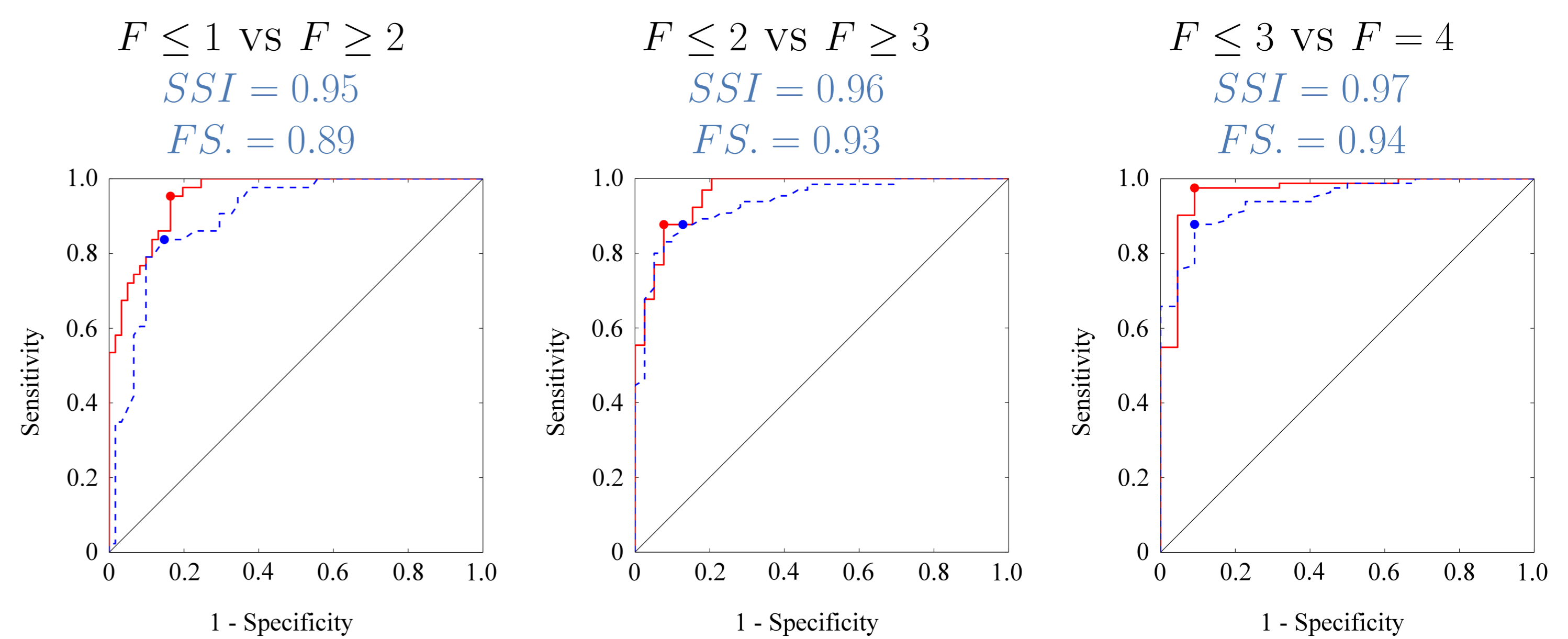


Figure 5 : ROC analysis - Solid Red : SSI - Dashed Blue : Fibroscan

SUPERSONIC SHEAR IMAGING HAS BETTER PERFORMANCES FOR LIVER FIBROSIS STAGING THAN FIBROSCAN, FOR EACH FIBROSIS LEVEL.

4. SHEAR WAVE SPECTROSCOPY

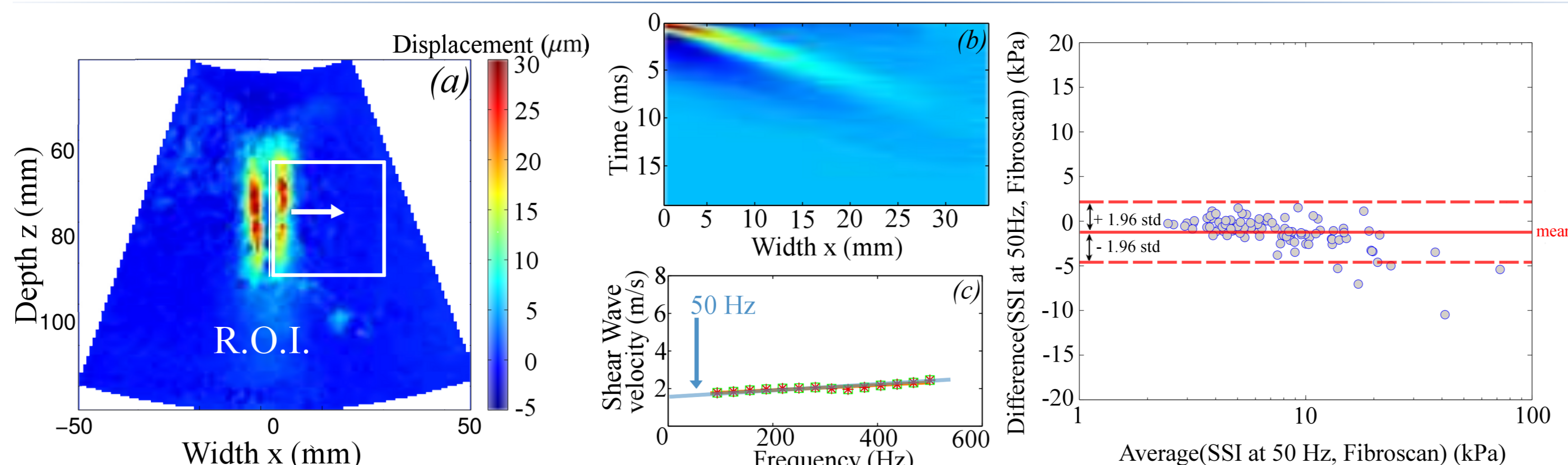


Figure 6 : (a) R.O.I for dispersion calculation - (b) Space-time representation - (c) Shear wave velocity analysis : agreement between SSI dispersion curve

Figure 7 : Bland-Altman

filtered at 50Hz and FS.

SUPERSONIC SHEAR IMAGING ALLOWS A LARGE BANDWIDTH MEASUREMENT - SHEAR WAVE VELOCITY ASSESSED BY SSI HAS A GOOD AGREEMENT WITH FIBROSCAN AT 50 HZ

CONCLUSIONS AND PERSPECTIVES

SUPERSONIC SHEAR IMAGING APPEARS TO BE A FAST, SIMPLE, AND RELIABLE METHOD FOR NON-INVASIVE LIVER FIBROSIS STAGING.

LARGE LIVER AREA MAPPED - LARGE FREQUENCY BANDWIDTH : BETTER DIAGNOSTIC ACCURACY FOR EACH FIBROSIS STAGES THAN FIBROSCAN (1D, 50HZ CENTRAL FREQUENCY, SMALL BANDWIDTH).

SSI ELASTOGRAPHY COULD REPLACE FIBROSCAN AS A ROUTINE EXAMINATION AND AVOID A LIVER BIOPSY FOR MANY PATIENTS.

SHEAR WAVE SPECTROSCOPY CURRENTLY UNDER DEVELOPMENT FOR LIVER ACTIVITY STAGING.