



**HAL**  
open science

## The Lymphoid Variant of Hypereosinophilic Syndrome

Guillaume Lefevre, Marie-Christine Copin, Delphine Staumont-Sallé, Martine Avenel-Audran, Hélène Aubert, Alain Taïeb, Gilles Salles, Hervé Maisonneuve, Kamel Ghomari, Felix Ackerman, et al.

► **To cite this version:**

Guillaume Lefevre, Marie-Christine Copin, Delphine Staumont-Sallé, Martine Avenel-Audran, Hélène Aubert, et al.. The Lymphoid Variant of Hypereosinophilic Syndrome. *Medicine*, 2014, 93 (17), pp.255-266. 10.1097/MD.0000000000000088 . hal-02083252

**HAL Id: hal-02083252**

**<https://hal.science/hal-02083252v1>**

Submitted on 10 Sep 2024

**HAL** is a multi-disciplinary open access archive for the deposit and dissemination of scientific research documents, whether they are published or not. The documents may come from teaching and research institutions in France or abroad, or from public or private research centers.

L'archive ouverte pluridisciplinaire **HAL**, est destinée au dépôt et à la diffusion de documents scientifiques de niveau recherche, publiés ou non, émanant des établissements d'enseignement et de recherche français ou étrangers, des laboratoires publics ou privés.

# The Lymphoid Variant of Hypereosinophilic Syndrome

## Study of 21 Patients With CD3-CD4+ Aberrant T-Cell Phenotype

Guillaume Lefèvre, MD, Marie-Christine Copin, MD, PhD, Delphine Staumont-Sallé, MD, PhD, Martine Avenel-Audran, MD, Hélène Aubert, MD, Alain Taieb, MD, PhD, Gilles Salles, MD, PhD, Hervé Maisonneuve, MD, Kamel Ghomari, MD, Félix Ackerman, MD, Fanny Legrand, PharmD, PhD, André Baruchel, MD, PhD, David Launay, MD, PhD, Louis Terriou, MD, Christian Leclech, MD, Chahera Khouatra, MD, Chafika Morati-Hafsaoui, MD, Myriam Labalette, MD, PhD, Raphaël Borie, MD, François Cotton, MD, PhD, Noémie Le Gouellec, MD, Franck Morschhauser, MD, PhD, Jacques Trauet, Catherine Roche-Lestienne, PhD, Monique Capron, PharmD, PhD, Pierre-Yves Hatron, MD, PhD, Lionel Prin, MD, PhD, Jean-Emmanuel Kahn, MD, PhD, and French Eosinophil Network

**Abstract:** The CD3-CD4+ aberrant T-cell phenotype is the most described in the lymphoid variant of hypereosinophilic syndrome (L-HES), a rare form of HES. Only a few cases have been reported, and data for these patients are scarce. To describe characteristics and outcome of CD3-CD4+ L-HES patients, we conducted a national multicentric retrospective study in the French Eosinophil Network. All patients who met the recent criteria of hypereosinophilia (HE) or HES and who had a persistent CD3-CD4+ T-cell subset on blood T-cell phenotyping were included. Clinical and laboratory data were retrospectively collected by

chart review. CD3-CD4+ L-HES was diagnosed in 21 patients (13 females, median age 42 years [range, 5–75 yr]). Half (48%) had a history of atopic manifestations. Clinical manifestations were dermatologic (81%), superficial adenopathy (62%), rheumatologic (29%), gastrointestinal (24%), pulmonary (19%), neurologic (10%), and cardiovascular (5%). The median absolute CD3-CD4+ T-cell count was 0.35 G/L (range, 0.01–28.3), with a clonal TCR $\gamma\delta$  rearrangement in 76% of patients. The mean follow-up duration after HES diagnosis was 6.9  $\pm$  5.1 years. All patients treated with oral corticosteroids (CS) (n=18) obtained remission, but 16 required CS-sparing treatments. One patient had a T-cell lymphoma 8 years after diagnosis, and 3 deaths occurred during follow-up.

In conclusion, clinical manifestations related to CD3-CD4+ T cell-associated L-HES are not limited to skin, and can involve all tissue or organs affected in other types of HE. Contrary to FIP1L1-PDGFR $\alpha$  chronic eosinophilic leukemia patients, CS are always effective in these patients, but CS-sparing treatments are frequently needed. The occurrence of T-cell lymphoma, although rare in our cohort, remains a major concern during follow-up.

(*Medicine* 2014;93: 255–266)

From the Institut d'Immunologie, Réseau Eosinophile, EA2686 (GL, FL, DL, ML, JT, JEK), Service d'Immunologie Clinique et de Médecine Interne, Centre de Référence Maladies Auto-Immunes Systémiques (GL, DL, LT, NLG, PYH), Institut de Pathologie (MCC), Service de Dermatologie (DSS), Service des Maladies du Sang (FM), Institut de Génétique Médicale, U837 Inserm (CRL), Réseau Eosinophile, U995 Inserm (MC), CHRU de Lille, Université Lille Nord de France, Lille; Service de Dermatologie (MAA, CL), CHU d'Angers, L'UNAM Université, Angers; Service de Dermatologie et Dermatologie Pédiatrique, Centre de Référence pour les Maladies Rares de la Peau, U1035 (AT), CHU de Bordeaux, Bordeaux; Service d'Hématologie (GS) and Service de Radiologie, CREATIS, UMR5220 CNRS, U1044 Inserm (FC), Hôpital Sud, Service de Pneumologie, Centre de Référence pour les Maladies Pulmonaires Rares (CK), Hospices Civils de Lyon, Université Claude Bernard Lyon I, Lyon; Service d'Onco-Hématologie (HM), Centre Hospitalier de La Roche-Sur-Yon, La Roche-Sur-Yon; Service d'Onco-Hématologie (KG), Centre Hospitalier de Beauvais, Beauvais; Service de Médecine Interne (FA), Hôpital Bicêtre, APHP, Université Paris Sud XI, Le Kremlin-Bicêtre; Service d'Hématologie et Immunologie Pédiatrique (AB), Hôpital Robert Debré, APHP, Université Paris Diderot and Service de Pneumologie A, Centre de Compétence Maladies Pulmonaires Rares (RB), Hôpital Bichat, APHP, Paris; Service de Médecine Interne (CMH), Centre Hospitalier d'Annecy, Annecy; Service de Médecine Interne, Hôpital Foch, Suresne; EA4340, Biomarqueurs en Cancérologie et en Onco-Hématologie, Université Versailles-Saint-Quentin-en-Yvelines (JEK), France.

Correspondence: Guillaume Lefèvre, Institut d'Immunologie, Réseau Eosinophile, Centre de Biologie Pathologie, CHRU de Lille, Boulevard J Leclercq, 59037 Lille Cedex, France (e-mail: guillaume.lefevre@chru-lille.fr).

Financial support and conflicts of interest: This work was supported by 2 national Programme Hospitalier de Recherche Clinique, 2003 (RESEOPIL) and 2008 (HELPEO). The authors have no conflicts of interest to disclose.

Supplemental digital content is available for this article. Direct URL citation is provided in the HTML and PDF versions of this article on the journal's website (www.md-journal.com).

Copyright © 2014 by Lippincott Williams & Wilkins.  
ISSN: 0025-7974

DOI: 10.1097/MD.0000000000000088

**Abbreviations:** AEC = absolute eosinophil count, AITL = angio-immunoblastic T-cell lymphoma, CEL = chronic eosinophilic leukemia, CHR = complete hematologic response, CS = corticosteroids, EAE = episodic angioedema, F/P = fusion gene FIP1L1-PDGFR $\alpha$ , HE = hypereosinophilia, HES = hypereosinophilic syndrome, IL-5 = interleukin, L-HES = lymphoid variant of hypereosinophilic syndrome, LN = lymph nodes, PHR = partial hematologic response, TCR $\gamma\delta$  = T-cell receptor gamma and delta chain.

## INTRODUCTION

Hypereosinophilic syndrome (HES), whose definition has been revised in a recent experts' Working Conference, is now defined by the presence of 1) persistent blood hypereosinophilia (HE) > 1.5 G/L on 2 examinations and/or tissue HE, 2) organ damage and/or dysfunction attributable to tissue HE, and 3) exclusion of other explanations for organ dysfunction.<sup>34</sup>

After the initial clinical evaluation and laboratory tests, 3 types of HES may be distinguished. Primary or neoplastic HES (HES<sub>N</sub>) is a disorder characterized by clonal eosinophils (chronic eosinophilic leukemia or CEL) and/or a myeloid disorder as defined by the World Health Organization (WHO) classification. CEL is mostly associated with the fusion gene FIP1L1-PDGFR<sub>A</sub> (F/P+).<sup>26,34</sup> Secondary or reactive HES (HES<sub>R</sub>) refers to a group of conditions in which eosinophil expansion is induced, most of the time, by eosinophilopoietic cytokines. Lastly, HE and HES of undetermined significance (HE<sub>US</sub>, HES<sub>US</sub>) are diagnosed when there is no evidence for clonal or reactive HE.

Among HES<sub>R</sub>, the lymphoid variant of HES (L-HES) is defined by the presence of a Th2 T-cell subset overproducing interleukin-5 (IL-5).<sup>8,26,31,34</sup> To our knowledge, the first well-defined case was described by Cogan et al in 1994.<sup>8</sup> The concept of L-HES was definitively established by Simon et al, who identified various abnormal Th2 cell subsets in 16 of 60 (27%) HES patients.<sup>31</sup> At present, our understanding of the disease is that the overproduction of IL-5 by Th2 cells is responsible for blood and tissue HE, leading to clinical manifestations, while the expansion of the abnormal T-cell subset is usually asymptomatic, with the exception of a few cases evolving to T-cell lymphoma.

Among these T-cells overproducing IL-5, many different abnormal T-cell immunophenotypes have been described, among which 3 seem more frequent in L-HES: CD3-CD4+, CD3+CD4+CD7-, and CD3+CD4-CD8- TCR $\alpha\beta$ +.<sup>26,31</sup> A clonal rearrangement of TCR is frequently, although not systematically, observed in these abnormal T-cells. Recently, an original case of L-HES was described in a patient with an Epstein-Barr virus (EBV)-infected T-cell clone producing eosinophilopoietic cytokines.<sup>12</sup> Due to the heterogeneity of the T-cell abnormalities identified in L-HES, there is no definitive diagnosis-criteria of L-HES: the presence of an abnormal immunophenotype and/or a clonal TCR rearrangement are usually required, but the identification of an overproduction of IL-5 (in supernatant culture of purified abnormal T-cells, by flow cytometry or serum dosage) is not currently needed and not applicable in routine practice.<sup>25</sup> Among the heterogeneous group of L-HES, the CD3-CD4+ immunophenotype is the most frequently identified, in which overproduction of IL-5 has systematically been confirmed when tested. To date 27 CD3-CD4+ L-HES and 3 HE patients have been reported in single case reports or cases series.<sup>1,2,4,5,11,15,17,20,26,27,30-33,37</sup>

Since the first described cases of L-HES associated with CD3-CD4+ aberrant T-cell subset, no large case series have been reported in the literature. To better describe this "CD3-CD4+ L-HES" subgroup, we here report 20 new patients (including 1 HE) and additional data for 1 previously reported patient<sup>30</sup> followed in the French Eosinophil Network. To our knowledge this is the largest retrospective multicentric study reporting the epidemiologic, clinical, and laboratory characteristics of this entity.

## METHODS

### Patients

This retrospective survey was initiated by the French Eosinophil Network which comprises 27 university and general hospitals all over France. The study was approved by the Lille Hospital Ethical Committee and carried out in accordance with the Helsinki convention.

All consecutive HES patients with a documented presence of CD3-CD4+ aberrant subset and a negative F/P fusion gene research (F/P- patients) were included between 1995 and 2013. One patient (Patient 8) has previously been reported.<sup>30</sup> All satisfied criteria for HES (n=20) or HE (n=1, no organ damage or clinical manifestation) according to the last updated consensus definitions.<sup>34</sup>

### Data Collection

All patients' demographic, clinical, and laboratory data were recorded by the practitioners in charge of these patients, and were reviewed by 2 investigators of this study (GL, JEK). Clinical manifestations were systematically recorded, especially dermatologic, pulmonary, gastrointestinal, rheumatologic, cardiovascular, and neurologic manifestations; and peripheral adenopathy. All biopsy-proven eosinophil tissue infiltrates were noted.

All the biological parameters relevant in HES diagnosis were recorded: eosinophilia duration, mean and peak of absolute eosinophil count (AEC), total serum gammaglobulins, serum IgE, vitamin B12 and tryptase levels.

### Multiparameter Flow Cytometry T-Cell Phenotyping

Fifteen patients had at least 1 T-cell phenotyping centrally performed in Lille University Hospital's Immunology Laboratory. Phenotyping was performed on whole blood within 24 hours by flow cytometry using a 4-color Beckman Coulter Navios. We considered only patients with a persistent CD3-CD4+ population and/or CD3-CD4+ above 2% of total peripheral T-cells. Additional markers were used to complete the identification of aberrant T-cell subsets. Fluorochrome-coupled antibodies (CD45, CD3, CD3 $\epsilon$ , CD4, CD8, CD7, CD2, CD5, TCR $\alpha\beta$ , TCR $\gamma\delta$ ) were purchased from Beckman Coulter and/or BD Biosciences. Intracytoplasmic CD3 $\epsilon$  and TCR $\alpha\beta$  expression was detected after fixation and permeabilization with the Cytotfix/Cytoperm kit (Becton Dickinson, CA). All other patients (n=6) had T-cell phenotyping in the local university hospital with appropriated markers and control isotypes. T-cell receptor gamma and delta chain (TCR $\gamma\delta$ ) rearrangement analysis was performed as previously described for all patients.<sup>24</sup>

### Response to Treatment

Complete clinical remission under corticosteroids (CS) was defined by the disappearance of symptoms. A partial clinical remission was defined as an improvement without disappearance of symptoms. A complete hematologic response (CHR) was defined by a decrease of AEC under 0.5 G/L, and a partial hematologic response (PHR) by a decrease of AEC of more than 50% without going below 0.5 G/L. Response to second-line treatments given in association with CS was defined as a complete response (complete clinical and hematologic response), a partial response (partial clinical and/or biological response), or an absence of response (no clinical improvement, no hematologic response). Dose of CS-dependency was defined by dose of CS under which the patient had some repeated clinical relapses (and not only hematologic relapses).

TABLE 1. Demographic and Clinical Characteristics of CD3-CD4+ L-HES Patients

Patient	Age (yr) <sup>a</sup>	Sex	Duration (yr) of HE, and/or Symptoms Before Diagnosis <sup>†</sup>	Atopic History	Clinical Manifestations									
					Dermatologic	Rheumatologic	Gastrointestinal	Pulmonary	Neurologic	Cardiovascular	Superficial LN	Other		
1	43	F	2		EAE, urticaria		Acute diarrhea and abdominal pain with EAE					Yes		
2	43	F	11		Pruritus, urticarial plaques	Wrist arthritis, carpal tunnel syndrome	Chronic diarrhea	Acute bronchitis				No		
3	54	M	2		Pruritus, urticarial plaques, EAE	Polyarthritides (hands, wrists, knees, ankles)						Yes		
4	53	M	7		EAE							No		
5	51	F	10	A, E	Diffuse pruritic maculo-papules							Yes		
6	31	F	4	E	E	Bilateral extensor tenosynovitis						No		
7	61	F	22				Chronic diarrhea and abdominal pain					Yes		
8	18	M	7	A, E	EAE, E	Polyarthritides (MCP and IP joints), extensor tenosynovitis						Yes	Splenomegaly	
9	50	F	4	R	Macular rash, pruritus		Chronic diarrhea and abdominal pain					No		
10	43	F	0		Maculo-papules	Polyarthralgia, carpal tunnel syndrome						Yes		
11	38	F	18	A, E	Pruritus							Ischemic embolic stroke	Multiple coronary and supra-aortic vessels aneurysms	Yes
12	68	M	2	R	Papules, pruritus							No		

(Continued)

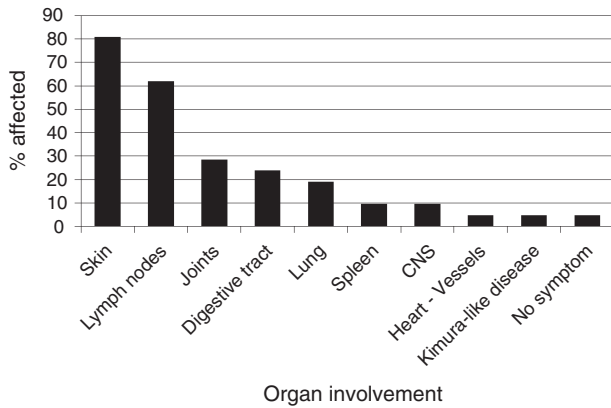
TABLE 1. (Continued)

		Clinical Manifestations										
Patient	Age (yr)*	Sex	Duration (yr) of HE and/or Symptoms Before Diagnosis†	Atopic History	Dermatologic	Rheumatologic	Gastrointestinal	Pulmonary	Neurologic	Cardiovascular	Superficial LN	Other
13	36	M	1	A, R	Pruritus				Diplopia, aseptic meningitis		Yes	Hypertrophy of the tonsils
14	5	F	0		EAE, urticaria			Asthma, ground glass on CT-scan			Yes	
15	20	M	0	A				Asthma, eosinophilic alveolitis, alveolar opacities on CT-scan			No	
16	18	F	5		E	Polyarthralgia (MCP and IP joints, knees)					Yes	
17	75	F	6								No	
18	42	M	3	E, R	E						Yes	Hypertrophy of the tonsils, the lacrimal and parotid glands. Subcutaneous masses
19	42	F	0		Pruritus		Chronic diarrhea				No	
20	17	F	0					Dyspnea, pleural effusion, eosinophilic alveolitis, alveolar opacities on CT-scan			Yes	
21	16	M	5	E	EAE, E						Yes	Splenomegaly

Abbreviations: A = asthma, CT-scan = computed tomography scan, E = eczema, EAE = episodic angioedema, IP = interphalangeal joints, LN = lymph nodes, MCP = metacarpophalangeal joints, R = rhinitis.

\*Age, at HES diagnosis.

†Disease duration: in 5 patients, HES diagnosis was made soon after the first symptoms occurred and disease duration is noted ?.



**FIGURE 1.** Clinical manifestations of CD3-CD4+ L-HES patients in the French Eosinophil Network. (CNS = central nervous system.)

**RESULTS**

**Demographic and Clinical Characteristics**

Twenty-one patients followed in the French Eosinophil Network were included (Table 1): 13 were female (62%), and the median age at HES diagnosis was 42 years (range, 5–75 yr). Ten (48%) had an atopic history, including eczema (n=6), asthma (n=5), and rhinosinusitis (n=4): 7 patients had childhood-onset atopy (Patients 5, 6, 8, 13, 15, 18, 21) and 3 had adult-onset atopy for many years before HES diagnosis (Patients 9, 11, 12). Nine patients had a median HE duration of 7 years (range, 1–22 yr) before the first HES symptoms. One patient (Patient 17) had isolated HE (without any clinical manifestation or visceral involvement) for 6 years.

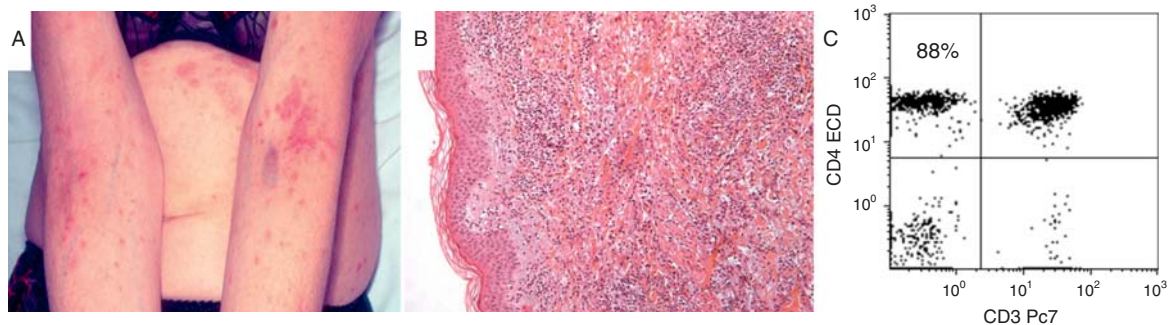
Skin involvement was the most common HES symptom (n=17, 81%) (Figure 1). Different cutaneous manifestations could be combined in a single patient and included diffused isolated pruritus (n=7), episodic angioedema (EAE) (n=6), diffuse eczema-like lesions (n=5), urticarial plaques (n=4), papular lesions (n=2) (Figure 2A), macular rash (n=1), and maculopapular lesions (n=1). Peripheral adenopathy was frequent (n=13, 62%). Only 2 patients had splenomegaly (10%). Rheumatologic manifestations (n=6, 29%) included inflammatory arthralgia (n=2) and bilateral distal polyarthritis with synovitis or tenosynovitis (n=4) (Figure 3A). Gastroin-

testinal manifestations (n=5, 24%) included chronic diarrhea (n=4) with (n=2) or without (n=2) abdominal pain, and acute recurrent abdominal pain related to an intestinal angioedema crisis (n=1). Four patients (15%) had pulmonary involvement, 3 classified as eosinophilic pneumonia (Figure 4A). Neurologic manifestations were present in 2 patients: Patient 13 had diplopia and aseptic meningitis with an abnormal brain magnetic resonance imaging (Figure 5A), Patient 11 had an ischemic embolic stroke. This last patient had multiple arterial aneurysms on supraortic vessels (including 1 on the left carotid bulb responsible for the stroke), multiple aneurysms on coronary arteries (responsible for a “silent” myocardial infarction), and a thoracic aortic ectasia. No evidence for vasculitis (that is, periarteritis nodosa, eosinophilic granulomatosis with polyangiitis) was identified, and the patient was classified as L-HES according to HE and recurrent immunophenotypes showing a persistent circulating CD3-CD4+ T-cell subset. Patient 18 had refractory generalized eczema and “Kimura-like” disease with parotid gland enlargement (biopsy demonstrated an infiltration by eosinophils, without IgG4+ plasma cells), cervical lymph nodes, subcutaneous swelling, but also lacrimal gland enlargement (infiltration by eosinophils) and hypertrophy of the tonsils, with a persistent circulating CD3-CD4+ subset.

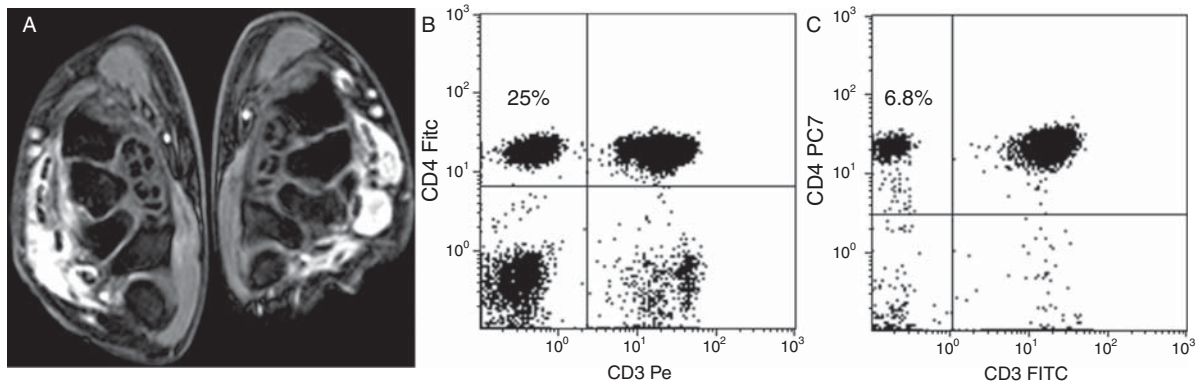
**Laboratory and Histologic Findings**

The mean AEC at diagnosis was  $5.1 \pm 5$  G/L (range, 1.5–15.5) and the mean of highest AEC recorded during the follow-up was  $11.4 \pm 11.9$  G/L (range, 2.2–52) (Table 2). Total serum IgG levels were increased in 3 of 15 patients (20%; data not available for 6 patients; range, 15–16.9 g/L). Total IgM levels were increased in 6 of 15 patients (40%; data not available for 6 patients; range, 3.2–15 g/L), including 5 patients with EAE (Patients 1, 4, 8, 14, and 21) defining Gleich syndrome.<sup>23</sup> Serum IgE level was increased in 18 patients (86%). B12 vitamin and tryptase levels were available in 16 patients: tryptase was increased in Patient 13 (21.9 mg/L for normal value <13.5 mg/L) and vitamin B12 and tryptase were both increased in Patient 14 (tryptase 15.8 mg/L for normal value <13.5 mg/L, B12 vitamin 1043 pmol/L for normal values between 190 and 980).

Only 6 patients had a high total lymphocyte count on diagnosis (29%; range, 4.5–29.5 G/L). The median absolute CD3-CD4+ lymphocyte count was 0.35 G/L (range, 0.01–28.3),



**FIGURE 2.** Fifty-one-year-old woman with CD3-CD4+ L-HES, skin lesions and peripheral enlarged lymph nodes (Patient 5). Skin lesions were pruritic maculo-papulous and predominated in the inframammary folds and abdomen, the folds of the elbows and the wrists (A). On histologic examination, the dermis was infiltrated by numerous eosinophils and some lymphocytes without epidermotropism (B). Laboratory investigations found a high (4.6 G/L) and persistent (peak 5 G/L) eosinophils count and a CD3-CD4+ aberrant T-cell subset on T-cell phenotyping (88% of total lymphocytes, 4.3 G/L) (C).



**FIGURE 3.** Thirty-one-year-old woman with CD3-CD4+ L-HES and articular involvement (Patient 6). She presented a bilateral extensor digitorum tenosynovitis confirmed by a magnetic resonance imaging (here 3D water selective fluid scan or 3D-WATS-f sequences) (A). Synovial biopsy showed an infiltration by eosinophils. T-cell phenotyping showed a circulating CD3-CD4+ aberrant T-cell subset (25% of total lymphocytes, 0.7 G/L) (B), which decreased with low-dose corticosteroids until the last evaluation more than 3 years after diagnosis (6.8% of total lymphocytes, 0.12 G/L) (C).

and the median percentage of CD3-CD4+ lymphocytes among total lymphocytes was 17% (range, 0.5%–96%) (see Table 2, Figure 2C, Figure 3C and 3D, Figure 4B–E, and Figure 6B). Other available phenotype surface markers are described in Table 2: the most common associated phenotype characteristics were CD2+, CD5+/+, CD7– (sometimes for only a part of the CD3-CD4+ subset), TCR $\alpha\beta$ –. Despite the absence of CD3 complex on cell surfaces, an intracellular CD3 $\epsilon$  chain was detected whenever it was tested for (8/8 patients). A clonal TCR $\gamma\delta$  rearrangement was detected in 16 patients (76%) at diagnosis: 3 of the 5 patients without clonal TCR $\gamma\delta$  rearrangement had a CD3-CD4+ population of less than 10% of total lymphocytes (see Table 2).

Fifteen patients had bone marrow (BM) cytology and/or histology: a high eosinophil count and/or infiltration by eosinophils were reported in 12 cases. An extensive tissue infiltration by eosinophils was noted in 10 patients (see Table 2, Figure 2B). Two patients who had pulmonary symptoms had eosinophilic alveolitis on bronchoalveolar lavage.

Five patients had a BM karyotype at diagnosis (Patients 1, 12, 14, 19, 21). Patient 13, who had a large CD3-CD4+ subset, had a blood karyotype showing numerous chromosomal abnormalities at diagnosis. Patient 8, who also had a large CD3-CD4+ subset, had a first blood karyotype at diagnosis (in 1999) which showed a trisomy 7 on a few cells, and a second one 12 years later (in 2011) showing a complex karyotype on half of the studied cells (see Table 2 for details).

### Response to Treatment and Follow-Up

Oral CS given as monotherapy were the first-line therapy in 18 patients. The initial dose was highly variable among patients. Roughly, 7 patients received a “high-dose” > 0.5 mg/kg per day and 11 patients a “low-dose”  $\leq$  0.5 mg/kg per day. Complete clinical remission was observed in 16 cases, a partial remission in the last 2 cases (both treated with low-dose CS). Complete biological remission was observed in 14 patients, a partial remission in the 4 last cases (all treated with low-dose CS). Clinical and/or biological relapses occurred under corticosteroid tapering in all patients for whom data were available ( $n=16$ ): dose-dependency was usually comprised between 10 and 25 mg/d. (See Table S1, Supplemental Digital Content 1, for details on the response

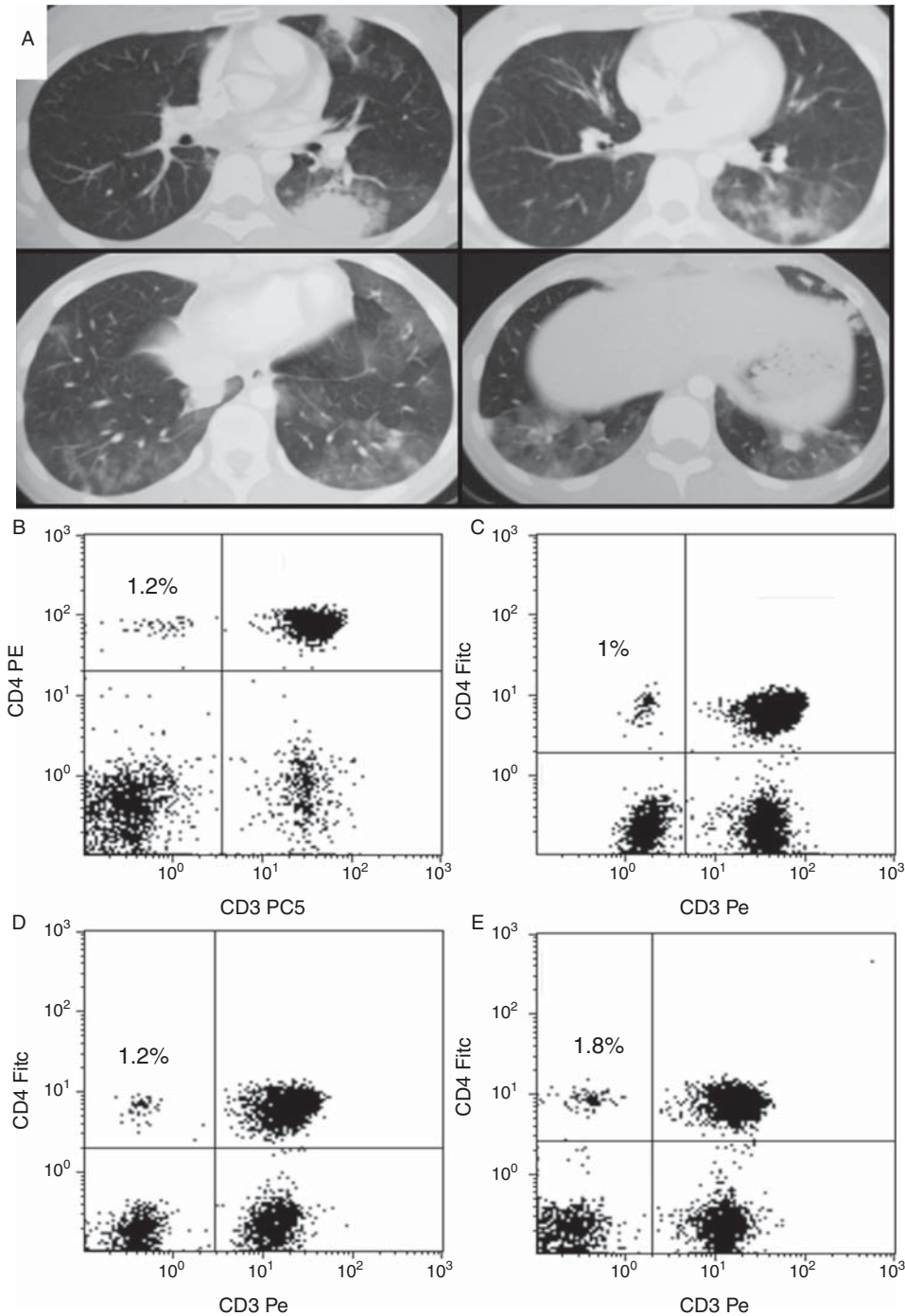
to CS and second-line treatment in CD3-CD4+ L-HES patients <http://links.lww.com/MD/A38>).

Many treatments were given as steroid-sparing therapies: interferon- $\alpha$  ( $n=8$ ), intravenous mepolizumab ( $n=5$ , included in mepolizumab trial),<sup>29</sup> cyclosporin A ( $n=5$ ), imatinib ( $n=4$ ), methotrexate ( $n=4$ ), hydroxycarbamide ( $n=3$ ), and alemtuzumab ( $n=1$ ). Complete or partial response was reported for each patient: interferon- $\alpha$  was effective in 7 of 8 patients, mepolizumab in 4/5, cyclosporin A in 3/5, imatinib in 1/4 patients, methotrexate in none of 4 patients, hydroxycarbamide in 1/3, alemtuzumab in 1 patient (Figure 6).

The mean follow-up duration after HES diagnosis was  $6.9 \pm 5.1$  years. As CS and other immunomodulatory or cytotoxic agents could cause lymphopenia and thus modify the CD3-CD4+ percentages, we estimated CD3-CD4+ evolution under treatment only on the absolute count of CD3-CD4+ cells. At the end of the follow-up, 20 patients had at least 1 T-cell phenotyping control: 6 patients (30%) had a significant increase in the CD3-CD4+ population (above 30% of the initial absolute count), while 10 patients (50%) had a decrease in their CD3-CD4+ (lower than 30% of the initial absolute count), all of them with treatment, 3 of them with CS alone (Patients 6, 20, 21). Seventeen patients had at least a second TCR $\gamma\delta$  analysis: 7 (41%) had no T-cell clonality at the end of follow-up, among whom 4 had previously had a clonal TCR $\gamma\delta$  rearrangement (see Table 2). Only 1 lymphoma occurred, 8 years after HES diagnosis (Patient 3): skin and bone marrow biopsy demonstrated angioimmunoblastic T-cell lymphoma (AITL). The patient died 4 months later of lymphoma extension despite appropriate chemotherapy. Of the 21 patients, 2 others died during follow-up: Patient 1 died of unknown causes almost 3 years after L-HES diagnosis (sudden death), Patient 5 died of severe sepsis after allogeneic stem cell transplantation for supposed AITL, but retrospective examination of histologic data excluded a lymphoma according to 2008 WHO classification.

### DISCUSSION

To our knowledge, the current study is the first large multicenter series of CD3-CD4+ L-HES cases reported. We describe 20 new patients in addition to 1 (Patient 8) already reported 10 years ago.<sup>30</sup>



**FIGURE 4.** Seventeen-year-old woman with CD3-CD4+ L-HES and pulmonary involvement (Patient 20). Computed-tomography scan (A) showed multiple bilateral alveolar condensations. Repeated T-cell phenotyping (gated on total lymphocytes) on diagnosis in April 2010 (B), in November 2011 (C), June 2012 (D), and December 2012 (E) showed a small but persistent CD3-CD4+ aberrant T-cell subset.

As nearly half of the patients were atopic before CD3-CD4+ L-HES diagnosis, our report highlights the fact that L-HES should be considered in atopic patients who have HE. Changes in skin lesions, appearance of new symptoms (that is, gastrointestinal, rheumatologic, pulmonary symptoms) and/or appearance of marked HE in atopic patients should lead the physician to consider HES,<sup>16</sup> and notably L-HES.

In the 26 of 27 previous published CD3-CD4+ L-HES cases with available clinical data, all patients except 1 had cutaneous manifestations: skin involvement is also the most frequent clinical manifestation in the current study (see Figure S1, Supplemental Digital Content 2, for a comparison of clinical manifestations in CD3-CD4+ L-HES patients in the current study and in previously



TABLE 2. Laboratory and Histologic Characteristics of CD3-CD4+ L-HES Patients

Patient	Eosinophils		CD3-CD4+ Lymphocytes			Interval Between First and Last T-Cell Phenotyping (yr)	Other T-Cell Markers	Karyotype <sup>‡</sup>	TCR $\gamma$ $\delta$ Rearr. <sup>§</sup>	Serum IgE at Diagnosis (UJ/mL)	Serum IgM at Diagnosis (g/L) <sup>**</sup>
	Highest AEC*	Bone Marrow or Tissue Infiltration	CD3-CD4+ Lymphocytes on First T-Cell Phenotyping, G/L (%) <sup>†</sup>	CD3-CD4+ Lymphocytes on Last T-Cell Phenotyping, G/L (%) <sup>†</sup>	Interval Between First and Last T-Cell Phenotyping (yr)						
1	20	BM	0.63 (39%)	12.5 (81%)	1.20	CD2+ CD5+ CD7+/- CD25+ icCD3e+ mTCR $\alpha\beta$ -	46, XX [14]	Y/Y	322	10,8	
2	11,0	BM, colon	0.15 (7%)	0.1 (6.7%)	5.2	CD5+ CD10- mTCR $\alpha\beta$ -	n.a	N/N	720	N	
3	4,5		0.01 (0.5%)	0.68 (25%)	1.10	CD2+ CD5+ icCD3e+	n.a	Y/Y	140	N	
4	13		0.14 (10%)	0.27 (9.6%)	2.30	CD2+ CD5+ CD7- CD25+	n.a	N/N	780	3,2	
5	5	BM, LN, skin	4.3 (88%)	7.5 (90%)	0.80	mTCR $\alpha\beta$ -	n.a	Y/n.a	580	3,3,5	
6	3	Synovial biopsy	0.70 (25%)	0.12 (6.8%)	3.20	mTCR $\alpha\beta$ -	n.a	Y/N	>5000	N	
7	23	Colon, LN	0.13 (17%)	0.017 (3.4%)	3.10	CD2+ CD5+ CD7- CD25 +/- mTCR $\alpha\beta$ -	n.a	Y/Y	350	N	
8	11,8	BM, LN, skin	28.3 (96%)	53 (98%)	11.20	CD2+ CD5+ CD7- CD10- icCD3e+	(1999) 46, XY [19], 46, XY,+7 [3] (2011) 46, XY [7] 46, XY,-1,t (1;12)(p35;q23), +5, der(5)t(5;?)q35;?), del(6)(q13q16), del(6)(p22), der(7)t(7;?)p15;?), der(9)t(9;?)q32;?) [8]	Y/Y	1580	3,71	
9	28,8	BM, duodenum, ileum, colon	0.82 (34%)	2.0 (58.8%)	6.60	CD2+ CD5+ CD7+/- mTCR $\alpha\beta$ -	n.a	N/Y	830	N	
10	3,5	Skin	0.19 (11%)	0.1 (16.7%)	1.50	mTCR $\alpha\beta$ -	n.a	Y/n.a	460	N	
11	3	BM	0.10 (7%)	0.1 (6.3%)	5.00	mTCR $\alpha\beta$ -	n.a	Y/N	>5000	N	
12	2,2	BM, skin	1.07 (39%)	1.20 (52%)	3.20	CD2+ CD5+ CD7+/- mTCR $\alpha\beta$ -	46, XY [25]	N/Y	11970	N	
13	4,9	BM	3.5 (79%)	1.5 (65%)	0.60	CD2+ CD5+ CD7- CD25- icCD3e+ mTCR $\alpha\beta$ -	46, XY [11] 46, XY,t (5;16)(q15-21;q22-23) [4] 46, XY, del (6)(q16q22) [11]	Y/n.a	>10000	N	
14	52	BM	0.41 (6%)	0.09 (6%)	5.60	mTCR $\alpha\beta$ - icCD3e+	46, XX	Y/Y	560	15	
15	9,1	Bronchus, BAL	0.05 (3%)	0.0	4.40	n.a	n.a	N/N	3000	N	
16	4,2	BM	0.07 (22%)	0.12 (6.9%)	7.00	n.a	n.a	Y/Y	4840	N	

17	6,1		0.07 (5%)	0.07 (6.5%)	1.80	CD2+ CD5+ CD7+/- icCD3e+ mTCRαβ- icTCRαβ+	n.a	Y/Y	20	N	
18	4,5	Skin, lacrimal and parotid glands	4.29 (78%)	0.3 (24%)	1.90	CD5+ mTCRαβ- icCD3e+ CD2+ CD5+ CD7- icCD3e+ mTCRαβ- icTCRαβ+	n.a	Y/Y	2800	N	
19	8	BM, colon	0.75 (29%)	n.a	n.a	CD2+ CD5+ CD7- mTCRαβ-	46, XX	Y/n.a	1200	N	
20	4,6	BAL	0.06 (1.2%)	0.016 (1.8%)	2.70		n.a	Y/N	520	N	
21	18	BM	0.35 (6%)	0.046 (3.3%)	0.30	CD2+ CD5+ CD7-	46, XY	Y/N	100	3,8	

Abbreviations: AEC = absolute eosinophils count, BAL = bronchoalveolar lavage, BM = bone marrow, icCD3 or icTCRαβ = intracellular expression of CD3 or TCRαβ, LN = lymph node, mTCRαβ = membranous expression of TCRαβ, n.a = not available, TCRγδ rearr = T-Cell Receptor γδ rearrangement.  
 †Eosinophils absolute counts in G/L.  
 ‡CD3-CD4+ lymphocytes in G/L and percentage of total lymphocytes absolute count.  
 §All karyotypes were made on BM, except for Patients 8 and 13 for whom karyotypes were made on blood cells.  
 ¶T-Cell Receptor γδ rearrangement present (Y) or absent (N) on diagnosis and on last search.  
 ¶¶Assay of serum IgE was performed locally, but due to a lack of standardization, laboratory positivity thresholds were between 100 and 200 U/mL for all laboratories.  
 \*\*\*Serum IgM level in g/L, normal values < 2.5 g/L in all centers. Only high values are reported and normal values are noted 'N'.

reported cases <http://links.lww.com/MD/A40>). Cutaneous lesions are polymorphic and nonspecific, and the same patient can have different skin manifestations. EAE cases have already been reported in CD3-CD4+ patients,<sup>10,15,27,28,33,37</sup> sometimes in association with an increased level of IgE and polyclonal IgM.<sup>15,27</sup> The current study highlights the need for careful detection of CD3-CD4+ in patients with EAE.

Three more patients recently reported had an aberrant CD3-CD4+ T-cell phenotype and HE without associated symptoms, like Patient 17 in the current series.<sup>7</sup>

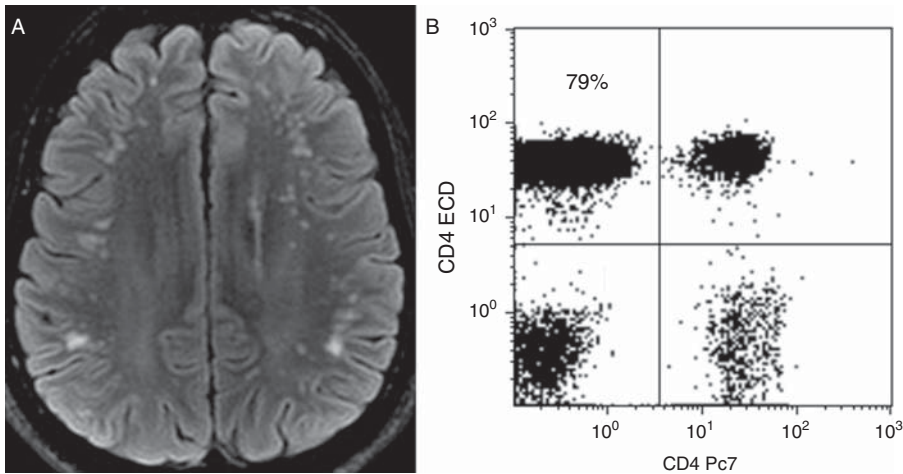
In the previous series of 27 patients, only 4 had arthralgia/arthritis,<sup>2,4,26,27</sup> 1 had gastrointestinal manifestations<sup>26</sup> and 3 had pulmonary manifestations.<sup>2,8,32</sup> Interestingly, Patient 6 with a biopsy-proven synovial infiltration by eosinophils resembles patients initially described by Butterfield et al as having “NERDS” (nodules, eosinophilia, rheumatism, dermatitis, and swelling).<sup>6</sup> Synovitis and tenosynovitis with HE also strongly suggest the detection of CD3-CD4+ T-cells.

Patient 11, who also had multiple supraaortic vessel aneurysms, was the only patient with cardiac involvement. In previously reported CD3-CD4+ L-HES patients, only 2 cases of cardiac involvement have been reported: 1 patient had endocardial thickening and moderate decrease of left ventricular ejection fraction,<sup>20</sup> and the second had ventricular thrombosis and endomyocardial fibrosis.<sup>4</sup> To our knowledge, only 4 HES patients have been reported to have multiple coronary aneurysms.<sup>19,21,22,35</sup> Patient 18 had an original presentation of “Kimura-like” disease. Kimura disease is usually described in young Asian males, and clinical manifestations associate parotid enlargement, subcutaneous swelling of the head and neck, and lymphadenopathy. Some authors have described an increase in Th2 cells in Kimura disease patients despite normal circulating T-cell phenotyping.<sup>36</sup>

Three patients in the current study had only digestive (Patient 7) or pulmonary symptoms (Patients 15 and 20) without any other manifestations except superficial lymphadenopathy: this highlights that “eosinophil-associated single-organ diseases” should be explored like any HE-associated disorder to test the hypothesis of L-HES. Finally, clinical manifestations in L-HES differ from those in CEL patients, who more frequently have cardiac and pulmonary involvement and splenomegaly, and more rarely have dermatologic manifestations.<sup>13</sup> (See Table S2, Supplemental Digital Content 2, for a comparison of baseline characteristics between F/P+ CEL patients<sup>31</sup> and CD3-CD4+ L-HES patients from the current study in the French Eosinophil Network <http://links.lww.com/MD/A39>).

The current study also confirms that patients with CD3-CD4+ L-HES share many laboratory characteristics that are unlike those of F/P+ CEL patients. The typical biological profile of L-HES includes elevated IgE level and normal serum B12 vitamin and tryptase values, contrary to F/P+ patients.<sup>13</sup>

Most of the previously reported cases, except 1 with 0.6% of total lymphocytes having a CD3-CD4+ phenotype,<sup>26</sup> described a large abnormal subset, often greater than 30% of total lymphocytes. In our experience, CD3-CD4+ T-cells are absent from lymphocyte phenotyping of healthy subjects. In the current study, 9 patients initially had a CD3-CD4+ T-cell subset ≤10% of total lymphocytes. This emphasizes that T-cell phenotyping should look carefully at small CD3-CD4+ populations in the HES context, and be renewed if clinical manifestations are evocative of L-HES.



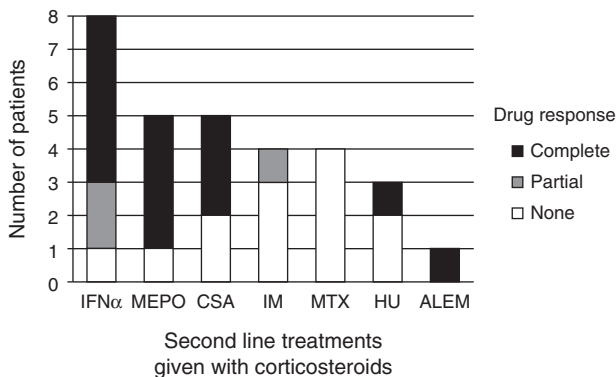
**FIGURE 5.** Thirty-six-year-old man with CD3-CD4+ L-HES and diplopia revealing a neuro-meningeal involvement. Cerebrospinal fluid analysis found 22 atypical lymphocytes per microliters but no eosinophil, and brain magnetic resonance imaging (MRI) showed multiple punctate signal abnormalities on subcortical white matter in the fronto-temporal and parietal lobes on T2-weighted fluid-attenuated inversion recovery (FLAIR) images (A). T-cells phenotyping found a large circulating CD3-CD4+ T-cell subset (79% of total lymphocytes count, 3.5 G/L) (B).

A monoclonal T-cell subset has been described in 20 of 24 (83%) previously reported CD3-CD4+ L-HES patients on the basis of Southern blot or TCR rearrangement analysis by PCR.<sup>1,2,4,8,10,11,15,26,27,31–33,37</sup> The current study confirms that a clonal T-cell receptor rearrangement detection is frequent at diagnosis and during follow-up, except in patients having a small CD3-CD4+ subset or for those in whom the CD3-CD4+ T-cell count decreased under treatment. Indeed, despite T-cell phenotyping demonstrating an aberrant T-cell subset, TCR rearrangements have not been found in 24% of patients at diagnosis and in 42% of patients who had a control. To confirm their clonal nature, purification of CD3-CD4+ T-cells by cell sorting could be performed to search a TCR rearrangement, but it is not done in standard follow-up. Finally, many studies have reported a T-cell clone in the context of HES, but only on the basis of a clonal TCR rearrangement (without the idea of a second test for confirmation) and without T-cell phenotyping abnormalities.<sup>11,18</sup> As TCR rearrangement has also been reported in

CEL patients, isolated positive TCR $\gamma\delta$  rearrangement, without abnormalities on T-cell phenotyping, should be considered with caution and should not lead to L-HES diagnosis unless a second PCR confirmed a rearrangement.<sup>25</sup> One of the limits of the current study is that IL-5 production by the CD3-CD4+ aberrant T-cell subsets has not been systematically analyzed. Nevertheless, there are many observations showing that CD3-CD4+ cells produce IL-5, and for this reason, cytokine production evaluation is not required routinely for the diagnosis of L-HES.<sup>26,34</sup>

The clinical condition of all patients treated with CS improved. HE also decreased in all of them, contrary to F/P+ patients for whom eosinophilia was always refractory to CS.<sup>13,18</sup> Half of the patients had a significant decrease of CD3-CD4+ T-cells on the last T-cell phenotyping (more than -30% of the initial absolute count), even under CS given as monotherapy, which is important to consider in a disease in which T-cells are central to pathophysiology. In previous reports, decrease of CD3-CD4+ T-cells has rarely been reported under CS<sup>5,27</sup> or under interferon- $\alpha$  therapy.<sup>8,31</sup> Our data are retrospective and relate to 21 patients only, and must therefore be interpreted with caution. Nevertheless, according to previous reported cases and the current study, CS should be the first therapeutic line in treating CD3-CD4+ L-HES. If a steroid-sparing therapy is needed, interferon- $\alpha$ , cyclosporin A, and mepolizumab are appropriate therapeutic choices to control clinical manifestations and HE, and sparing steroid consumption. Indeed, even though mepolizumab is as efficient in disease control and helpful for CS-tapering in L-HES as in HES<sub>US</sub>, some authors have recommended maintaining low-dose CS to potentially target T-cells, in association with mepolizumab, which only targets eosinophils.<sup>25,29</sup>

Different T-cell lymphoma histologic features have been reported in 8 of 27 previously reported patients with CD3-CD4+ L-HES.<sup>1,2,17,23,31,33</sup> Surprisingly, only 1 of our patients had histologic features compatible with AITL, and 3 other patients with lymphocytes and eosinophils infiltrated lymph nodes did not (Patients 5, 7, 8). Because of common biological and histologic characteristics with L-HES, diagnosis of such T-cell lymphomas during the course of L-HES



**FIGURE 6.** Efficiency of second-line treatments in association with corticosteroids. ALEM = alemtuzumab, CSA = cyclosporin A, HU = hydroxycarbamide, IFN $\alpha$  = interferon  $\alpha$  or peg-interferon  $\alpha$ , IM = imatinib, MEPO = mepolizumab, MTX = methotrexate.

remains a challenge, as in Patient 5 of our study. Indeed, CD3-CD4+CD7- T cells are found in lymph node biopsies or in peripheral blood in patients with AITL, which can also be revealed by generalized skin lesions and HE.<sup>3,14</sup>

Finally, cytogenetic abnormalities have been previously described in 4 L-HES patients.<sup>2,32</sup> One patient with a chromosome 1 breakpoint,<sup>2,8</sup> and 1 patient with a 6q deletion both secondarily developed T-cell lymphoma.<sup>14</sup> Unfortunately, we could not perform cytogenetic analysis in Patient 3, who developed AITL. In our series, 2 patients had blood karyotype abnormalities. Patient 8 was already reported with trisomy 7 at diagnosis.<sup>30</sup> Twelve years after diagnosis, his blood karyotype revealed complex clonal abnormalities with, among others, a 6q deletion: histologic examination of skin and lymph nodes had excluded T-cell lymphoma. Another patient of our series with an aggressive form of L-HES had both a (5;16) translocation and a 6q deletion. Prospective studies are needed to confirm that repeated blood karyotypes could be used in lymphoma screening in selected patients with high CD3-CD4+ T-cell subsets.

In conclusion, the present study confirms that CD3-CD4+ L-HES should be considered in many clinical situations associated with HE. Skin involvement is the most frequent but not exclusive clinical manifestation. Aberrant CD3-CD4+ T-cell subsets can be really low among blood lymphocytes.

Clinical and biological remissions remain the rule under CS, but steroid-sparing treatments are often required because of frequent CS dependency. T-cell lymphoma remains a complication that must be suspected even after many years of L-HES follow-up.

#### ACKNOWLEDGMENTS

The authors acknowledge all of the persons involved in the French Eosinophil Network (alphabetical order): Maité Balden, Yamina Benallal, Olivier Blétry, Jean-Francois Cordier, Vincent Cottin, Marie Delbeke, Virginie Dutoit-Lefevre, Sylvie Fievet, Laurence Fofana, Solène Gatault, Nathalie Grardel, Aline Renneville, Christophe Roumier, and Amandine Verhaeghe.

#### NOTE ADDED IN PROOF

The authors report that another case of AITL occurred in this cohort (Patient 8) since the paper was submitted for publication.

#### REFERENCES

1. Bagot M, Bodemer C, Wechsler J, et al. [Non epidermotropic T lymphoma preceded for several years by hypereosinophilic syndrome]. *Ann Dermatol Venerol*. 1990;117:883–885.
2. Bank I, Amarglio N, Reshef A, et al. The hypereosinophilic syndrome associated with CD4+CD3- helper type 2 (Th2) lymphocytes. *Leuk Lymphoma*. 2001;42:123–133.
3. Baseggio L, Berger F, Morel D, et al. Identification of circulating CD10 positive T cells in angioimmunoblastic T-cell lymphoma. *Leukemia*. 2006;20:296–303.
4. Bergua JM, Prieto-Pliego E, Roman-Barbera A, et al. Resolution of left and right ventricular thrombosis secondary to hypereosinophilic syndrome (lymphoproliferative variant) with reduced intensity conditioning allogeneic stem cell transplantation. *Ann Hematol*. 2008;87:937–938.

5. Brugnoli D, Airo P, Rossi G, et al. A case of hypereosinophilic syndrome is associated with the expansion of a CD3-CD4+ T-cell population able to secrete large amounts of interleukin-5. *Blood*. 1996;87:1416–1422.
6. Butterfield JH, Leiferman KM, Gleich GJ. Nodules, eosinophilia, rheumatism, dermatitis and swelling (NERDS): a novel eosinophilic disorder. *Clin Exp Allergy*. 1993;23:571–580.
7. Chen YY, Khoury P, Ware JM, et al. Marked and persistent eosinophilia in the absence of clinical manifestations. *J Allergy Clin Immunol*. 2014;133:1195–1202. Epub 2013 Aug 26.
8. Cogan E, Schandene L, Crusiaux A, et al. Brief report: clonal proliferation of type 2 helper T cells in a man with the hypereosinophilic syndrome. *N Engl J Med*. 1994;330:535–538.
9. Galimberti S, Ciabatti E, Ottimo F, et al. Cell clonality in hypereosinophilic syndrome: what pathogenetic role. *Clin Exp Rheumatol*. 2007;25:17–22.
10. Gonzalez Delgado P, de la Sen Fernandez ML, Soriano Gomis V, et al. Cyclical hypereosinophilia with skin manifestations and a clonal T cell population. *J Investig Allergol Clin Immunol*. 2008;18:401–403.
11. Helbig G, Wiczorkiewicz A, Dziaczkowska-Suszek J, et al. T-cell abnormalities are present at high frequencies in patients with hypereosinophilic syndrome. *Haematologica*. 2009;94:1236–1241.
12. Klion AD, Mejia R, Cowen EW, et al. Chronic active Epstein-Barr virus infection: a novel cause of lymphocytic variant hypereosinophilic syndrome. *Blood*. 2013;121:2364–2366.
13. Legrand F, Renneville A, Macintyre E, et al. On behalf of the French Eosinophil Network. The Spectrum of FIP1L1-PDGFR $\alpha$ -associated chronic eosinophilic leukemia: new insights based on a survey of 44 cases. *Medicine (Baltimore)*. 2013;92:e1–e9.
14. Merchant SH, Amin MB, Viswanatha DS. Morphologic and immunophenotypic analysis of angioimmunoblastic T-cell lymphoma: emphasis on phenotypic aberrancies for early diagnosis. *Am J Clin Pathol*. 2006;126:29–38.
15. Morgan SJ, Prince HM, Westerman DA, et al. Clonal T-helper lymphocytes and elevated IL-5 levels in episodic angioedema and eosinophilia (Gleich's syndrome). *Leuk Lymphoma*. 2003;44:1623–1625.
16. Neve S, Beukers S, Kirtschig G. Hypereosinophilic syndrome in an atopic patient. *Clin Exp Dermatol*. 2009;34:e643–e646.
17. O'Shea JJ, Jaffe ES, Lane HC, et al. Peripheral T cell lymphoma presenting as hypereosinophilia with vasculitis. Clinical, pathologic, and immunologic features. *Am J Med*. 1987;82:539–545.
18. Ogbogu PU, Bochner BS, Butterfield JH, et al. Hypereosinophilic syndrome: a multicenter, retrospective analysis of clinical characteristics and response to therapy. *J Allergy Clin Immunol*. 2009;124:1319–1325.
19. Okinaka T, Isaka N, Nakano T. Coexistence of giant aneurysm of sinus of Valsalva and coronary artery aneurysm associated with idiopathic hypereosinophilic syndrome. *Heart*. 2000;84:E7.
20. Pitini V, Teti D, Arrigo C, et al. Alemtuzumab therapy for refractory idiopathic hypereosinophilic syndrome with abnormal T cells: a case report. *Br J Haematol*. 2004;127:477.
21. Poommipanit PB, Lensky M, Tobis J. Eosinophilic arteritis with coronary aneurysms and stenoses. *J Invasive Cardiol*. 2005;17:266–269.
22. Puri R, Dundon BK, Leong DP, et al. Hypereosinophilic syndrome associated with multiple coronary aneurysms. *Int J Cardiol*. 2009;133:e43–e45.
23. Ravot M, Sibille C, Roufosse F, et al. 6q- is an early and persistent chromosomal aberration in CD3-CD4+ T-cell clones associated with the lymphocytic variant of hypereosinophilic syndrome. *Haematologica*. 2005;90:753–765.

24. Roche-Lestienne C, Lepers S, Soenen-Cornu V, et al. Molecular characterization of the idiopathic hypereosinophilic syndrome (HES) in 35 French patients with normal conventional cytogenetics. *Leukemia*. 2005;19:792–798.
25. Roufosse F. Hypereosinophilic syndrome variants: diagnostic and therapeutic considerations. *Haematologica*. 2009;94:1188–1193.
26. Roufosse F, Cogan E, Goldman M. Lymphocytic variant hypereosinophilic syndromes. *Immunol Allergy Clin North Am*. 2007;27:389–413.
27. Roufosse F, Schandene L, Sibille C, et al. Clonal Th2 lymphocytes in patients with the idiopathic hypereosinophilic syndrome. *Br J Haematol*. 2000;109:540–548.
28. Roufosse F, Simonart T, Cogan E. Skin lesions as the only manifestation of the idiopathic hypereosinophilic syndrome. *Br J Dermatol*. 2001;144:639.
29. Roufosse FE, Kahn JE, Gleich GJ, et al. Long-term safety of mepolizumab for the treatment of hypereosinophilic syndromes. *J Allergy Clin Immunol*. 2013;131:461–467.
30. Roumier AS, Gardel N, Lai JL, et al. Hypereosinophilia with abnormal T cells, trisomy 7 and elevated TARC serum level. *Haematologica*. 2003;88:ECR24.
31. Simon HU, Plotz SG, Dummer R, et al. Abnormal clones of T cells producing interleukin-5 in idiopathic eosinophilia. *N Engl J Med*. 1999;341:1112–1120.
32. Sugimoto K, Tamayose K, Sasaki M, et al. More than 13 years of hypereosinophilia associated with clonal CD3-CD4+ lymphocytosis of TH2/TH0 type. *Int J Hematol*. 2002;75:281–284.
33. Vaklavas C, Tefferi A, Butterfield J, et al. “Idiopathic” eosinophilia with an Occult T-cell clone: prevalence and clinical course. *Leuk Res*. 2007;31:691–694.
34. Valent P, Klion AD, Horny HP, et al. Contemporary consensus proposal on criteria and classification of eosinophilic disorders and related syndromes. *J Allergy Clin Immunol*. 2012;130:607–612.
35. Wieser M, Emmert MY, Rusch D, et al. Impressive combination of multiple sinus valsalvae and coronary aneurysms due to hypereosinophilic syndrome. *Ann Thorac Surg*. 2010;90:e77.
36. Yamazaki K, Kawashima H, Sato S, et al. Increased CD45RO+ CD62L+ CD4+ T-cell subpopulation responsible for Th2 response in Kimura’s disease. *Human Immunol*. 2013;74:1097–1102.
37. Zenone T, Felman P, Malcus C, et al. Indolent course of a patient with hypereosinophilic syndrome associated with clonal T-cell proliferation. *Am J Med*. 1999;107:509–511.