



**HAL**  
open science

## **Mycobacterium chimaera Pulmonary Disease in Cystic Fibrosis Patients, France, 2010–2017**

R. Larcher, Manon Lounnas, Yann Dumont, Anne-Laure Michon, Lucas Bonzon, Raphaël Chiron, Christian Carrière, Kada Klouche, Sylvain Godreuil

► **To cite this version:**

R. Larcher, Manon Lounnas, Yann Dumont, Anne-Laure Michon, Lucas Bonzon, et al.. Mycobacterium chimaera Pulmonary Disease in Cystic Fibrosis Patients, France, 2010–2017. *Emerging Infectious Diseases*, 2019, 25 (3), pp.611-613. 10.3201/eid2503.181590 . hal-02069924

**HAL Id: hal-02069924**

**<https://hal.science/hal-02069924>**

Submitted on 8 Jun 2020

**HAL** is a multi-disciplinary open access archive for the deposit and dissemination of scientific research documents, whether they are published or not. The documents may come from teaching and research institutions in France or abroad, or from public or private research centers.

L'archive ouverte pluridisciplinaire **HAL**, est destinée au dépôt et à la diffusion de documents scientifiques de niveau recherche, publiés ou non, émanant des établissements d'enseignement et de recherche français ou étrangers, des laboratoires publics ou privés.

# ***Mycobacterium chimaera*** **Pulmonary Disease in** **Cystic Fibrosis Patients,** **France, 2010–2017**

**Romarc Larcher, Manon Lounnas,  
Yann Dumont, Anne-Laure Michon,  
Lucas Bonzon, Raphael Chiron,  
Christian Carriere, Kada Klouche, Sylvain Godreuil**

Author affiliations: University of Montpellier, Montpellier, France (R. Larcher, M. Lounnas, C. Carriere, K. Klouche, S. Godreuil); Montpellier University Hospital, Montpellier (R. Larcher, Y. Dumont, A.-L. Michon, L. Bonzon, R. Chiron, C. Carriere, K. Klouche, S. Godreuil)

We report *Mycobacterium chimaera* pulmonary disease in 4 patients given a diagnosis of cystic fibrosis in a university hospital in Montpellier, France. All patients had *M. chimaera*-positive expectorated sputum specimens, clinical symptoms of pulmonary exacerbation, or a decrease in spirometry test results that improved after specific treatment.

*Mycobacterium chimaera* is a member of the *Mycobacterium avium* complex, which was elevated to species rank in 2004. *M. chimaera* was reported by Tortoli et al. (1) as a cause of human lung disease but has been widely known as the bacteria responsible for an outbreak of endocarditis and disseminated infection after cardiac surgery in 2013 (2).

Although virulence and pathogenicity of *M. chimaera* in lung disease are currently debated, several cases of *M. chimaera* lung infections have been reported in settings of chronic obstructive pulmonary disease, malignancy, or immunosuppression (3–5). We found 1 case of *M. chimaera* infection in a patient with cystic fibrosis (6). Other nontuberculous mycobacteria (NTM), especially *M. abscessus* and *M. intracellulare*, are well-known pathogens in such a setting (7). We report *M. chimaera* pulmonary disease in 4 patients with cystic fibrosis.

After reviewing data for 248 patients who were examined at the Cystic Fibrosis Center of Montpellier, France, during 2010–2017, we observed that 24 (9.7%) of 248 patients had  $\geq 1$  respiratory smear sample positive for NTM; for 4 (16.7%) of 24, the sample was positive for *M. chimaera*. The 4 case-patients were Caucasian, age 8–21 years, and who had a newborn diagnosis of cystic fibrosis, preexisting respiratory impairment, and digestive malabsorption. The association of an increased cough and sputum production, breathlessness, and fatigue with

a reduction in forced expiratory volume in 1 s (FEV1) or forced vital capacity (FVC) was diagnosed as pulmonary exacerbation (7) for all patients (Figure). Diagnosis was confirmed by computed tomography by the presence of bronchiectasis and nodules (tree-in-bud pattern) for case-patients 1 and 3.

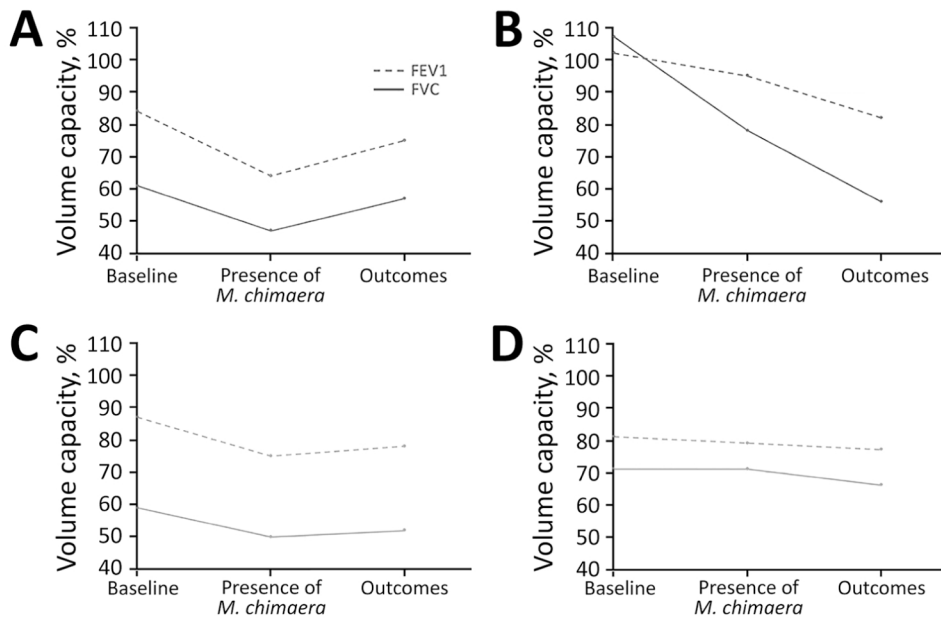
Respiratory specimens collected every 3–6 months for 1 year were digested and decontaminated by using the sodium dodecyl sulfate–NaOH method and then centrifuged using fluorescence microscopy. Sputum samples from all patients were negative for acid-fast bacilli. Samples were cultured on solid and liquid media (BACTEC MGIT 960 System; Becton Dickinson Diagnostic Systems, <https://www.bd.com>) which identified, after 11–41 days, mycobacteria from  $\geq 2$  separate sputum samples.

We performed species identification by using a commercial kit (GenoType NTM-DR assay; Hain Lifescience, <https://www.hain-lifescience.de>) and identified isolates as *M. chimaera*. We also performed molecular identification of isolates as *M. chimaera* as described (1,8). All isolates were susceptible to macrolides and aminoglycosides. We also isolated several other microorganisms: *Pseudomonas aeruginosa* and methicillin-resistant *Staphylococcus aureus* from case-patient 1; *Haemophilus influenzae* from case-patient 2; *M. avium* and *Stenotrophomonas maltophilia* from case-patient 3; and *M. abscessus*, methicillin-resistant *S. epidermidis*, and *P. aeruginosa* from case-patient 4.

Azithromycin, rifampin, and ethambutol (in combination) and ceftazidime, tobramycin, and inhaled colistin were given to case-patient 1. No antimicrobial drugs were given to case-patient 2. Azithromycin and rifampin (in combination) and inhaled colistin were given to case-patient 3. Clarithromycin and linezolid were given to case-patient 4. All 4 case-patients required physiotherapy.

All case-patients were followed up for  $\geq 1$  year after the first positive smears for *M. chimaera* were obtained. We found a substantial reduction in symptoms of pulmonary exacerbations and sterilization of sputum specimens for patients given macrolides and rifampin with or without aminoglycosides after 3 months, as well as improvement in FEV1 and FVC after 6 months. In contrast, patients not given treatment (case-patient 2) or given only partial treatment with an anti-NTM antimicrobial drug regimen (case-patient 4) showed a decrease in FEV1 and FVC after 6 months (Figure) and slight recovery or no change after 1 year.

Therefore, we hypothesized that *M. chimaera* showed virulence and pathogenicity in our patients because of their clinical picture and evolution. We are aware that the diagnosis of NTM diseases according to American Thoracic Society criteria (9) might not be made with complete certainty because definitive exclusion of other diagnoses was often



**Figure.** Evolution of lung function for 4 cystic fibrosis patients with *Mycobacterium chimaera* pulmonary disease, France, 2010–2017. A) Case-patient 1, B) case-patient 2, C) case-patient 3, D) case-patient 4. Case-patients 1 and 3 were given specific treatment for *M. chimaera* disease for 3 months; case-patient 2 was not given specific treatment; case-patient 4 was given only partial treatment. FEV1, forced expiratory volume in 1 s; FVC, forced vital capacity.

difficult for cystic fibrosis patients. Several confounding factors, such as co-infection with conventional pathogens, were observed, which could explain the observed favorable outcome. However, specific treatment against NTM improved outcome, which strengthens our presumption of the potential pathogenic role of *M. chimaera* in lung disease of patients with cystic fibrosis.

Cystic fibrosis transmembrane conductance regulator disorder results in mucus retention and bronchiectasis that favor repeated respiratory tract infection, including NTM diseases (7). In these circumstances, cystic fibrosis might promote *M. chimaera* infection in a similar manner to that in patients with chronic obstructive pulmonary disease. The lack of improvement of respiratory function for case-patient 4, who had been given treatment for infection with other pathogens, but only partially for *M. chimaera*, supports our hypothesis. However, whether *M. chimaera* is only a surrogate of respiratory impairment without any virulence or a real pathogenic microorganism remains unknown. In conclusion, *M. chimaera* lung disease should prompt physicians to consider this bacteria as an emergent pathogen in cystic fibrosis patients.

### Acknowledgments

We thank the patients at the Cystic Fibrosis Center of Montpellier and all members of the Bacteriology Department of Montpellier University Hospital for participating in this study.

### About the Author

Dr. Larcher is a clinical fellow in the Intensive Care Medicine Department at the University Hospital of Montpellier. He is also a PhD student in the PhyMedEx Laboratory at the University of

Montpellier, in association with the French Institute of Health and Medical Research and the French National Center for Scientific Research. His primary research interests are sepsis and infectious diseases in critically ill patients.

### References

- Tortoli E, Rindi L, Garcia MJ, Chiaradonna P, Dei R, Garzelli C, et al. Proposal to elevate the genetic variant MAC-A, included in the *Mycobacterium avium* complex, to species rank as *Mycobacterium chimaera* sp. nov. *Int J Syst Evol Microbiol.* 2004; 54:1277–85. <http://dx.doi.org/10.1099/ijs.0.02777-0>
- van Ingen J, Kohl TA, Kranzer K, Hasse B, Keller PM, Katarzyna Szafrńska A, et al. Global outbreak of severe *Mycobacterium chimaera* disease after cardiac surgery: a molecular epidemiological study. *Lancet Infect Dis.* 2017;17: 1033–41. [http://dx.doi.org/10.1016/S1473-3099\(17\)30324-9](http://dx.doi.org/10.1016/S1473-3099(17)30324-9)
- Bills ND, Hinrichs SH, Aden TA, Wickert RS, Iwen PC. Molecular identification of *Mycobacterium chimaera* as a cause of infection in a patient with chronic obstructive pulmonary disease. *Diagn Microbiol Infect Dis.* 2009;63:292–5. <http://dx.doi.org/10.1016/j.diagmicrobio.2008.12.002>
- Boyle DP, Zembower TR, Reddy S, Qi C. Comparison of clinical features, virulence, and relapse among *Mycobacterium avium* complex species. *Am J Respir Crit Care Med.* 2015;191:1310–7. <http://dx.doi.org/10.1164/rccm.201501-0067OC>
- Moon SM, Kim S-Y, Jhun BW, Lee H, Park HY, Jeon K, et al. Clinical characteristics and treatment outcomes of pulmonary disease caused by *Mycobacterium chimaera*. *Diagn Microbiol Infect Dis.* 2016;86:382–4. <http://dx.doi.org/10.1016/j.diagmicrobio.2016.09.016>
- Cohen-Bacrie S, David M, Stremmler N, Dubus J-C, Rolain J-M, Drancourt M. *Mycobacterium chimaera* pulmonary infection complicating cystic fibrosis: a case report. *J Med Case Reports.* 2011;5:473. <http://dx.doi.org/10.1186/1752-1947-5-473>
- Elborn JS. Cystic fibrosis. *Lancet.* 2016;388:2519–31. [http://dx.doi.org/10.1016/S0140-6736\(16\)00576-6](http://dx.doi.org/10.1016/S0140-6736(16)00576-6)
- Tortoli E. The new mycobacteria: an update. *FEMS Immunol Med Microbiol.* 2006;48:159–78. <http://dx.doi.org/10.1111/j.1574-695X.2006.00123.x>

9. Griffith DE, Aksamit T, Brown-Elliott BA, Catanzaro A, Daley C, Gordin F, et al.; ATS Mycobacterial Diseases Subcommittee; American Thoracic Society; Infectious Disease Society of America. An official ATS/IDSA statement: diagnosis, treatment, and prevention of nontuberculous mycobacterial diseases. *Am J Respir Crit Care Med.* 2007;175:367–416. <http://dx.doi.org/10.1164/rccm.200604-571ST>

---

Address for correspondence: Romaric Larcher, Intensive Care Medicine Department, Lapeyronie Hospital, Montpellier University Hospital, 371 Ave Doyen Gaston Giraud, Montpellier 34295, France; email: [r-larcher@chu-montpellier.fr](mailto:r-larcher@chu-montpellier.fr)

---