



**HAL**  
open science

## **White-matter pathways and semantic processing: intrasurgical and lesion-symptom mapping evidence**

Joanna Sierpowska, Andreu Gabarrós, Alejandro Fernández-Coello, Àngels Camins, Sara Castañer, Montserrat Juncadella, Clément François, Antoni Rodríguez-Fornells

### ► To cite this version:

Joanna Sierpowska, Andreu Gabarrós, Alejandro Fernández-Coello, Àngels Camins, Sara Castañer, et al.. White-matter pathways and semantic processing: intrasurgical and lesion-symptom mapping evidence. *Neuroimage-Clinical*, 2019, 22, pp.101704. 10.1016/j.nicl.2019.101704 . hal-02060847

**HAL Id: hal-02060847**

**<https://hal.science/hal-02060847>**

Submitted on 7 Mar 2019

**HAL** is a multi-disciplinary open access archive for the deposit and dissemination of scientific research documents, whether they are published or not. The documents may come from teaching and research institutions in France or abroad, or from public or private research centers.


L'archive ouverte pluridisciplinaire **HAL**, est destinée au dépôt et à la diffusion de documents scientifiques de niveau recherche, publiés ou non, émanant des établissements d'enseignement et de recherche français ou étrangers, des laboratoires publics ou privés.



Contents lists available at ScienceDirect

NeuroImage: Clinical

journal homepage: www.elsevier.com



## White-matter pathways and semantic processing: intrasurgical and lesion-symptom mapping evidence

Joanna Sierpowska<sup>a, b, c, d, \*</sup>, Andreu Gabarrós<sup>a, e</sup>, Alejandro Fernandez-Coello<sup>e, f</sup>, Àngels Camins<sup>g</sup>, Sara Castañer<sup>g</sup>, Montserrat Juncadella<sup>h</sup>, Clément François<sup>a, b, i</sup>, Antoni Rodríguez-Fornells<sup>a, b, j, \*</sup>

<sup>a</sup> Cognition and Brain Plasticity Group, Bellvitge Biomedical Research Institute- IDIBELL, 08097, L'Hospitalet de Llobregat, Barcelona, Spain

<sup>b</sup> Dept. of Cognition, Development and Education Psychology, University of Barcelona, Campus Bellvitge, 08097, L'Hospitalet de Llobregat, Barcelona, Spain

<sup>c</sup> Radboud University, Donders Institute for Brain, Cognition and Behaviour, Nijmegen, The Netherlands

<sup>d</sup> Radboud University Medical Center, Donders Institute for Brain Cognition and Behaviour, Department of Medical Psychology, Nijmegen, The Netherlands

<sup>e</sup> Hospital Universitari de Bellvitge (HUB), Neurosurgery Section, Campus Bellvitge, University of Barcelona - IDIBELL, 08097, L'Hospitalet de Llobregat, Barcelona, Spain

<sup>f</sup> CIBER de Bioingeniería, Biomateriales y Nanomedicina (CIBER-BBN), Barcelona, Spain

<sup>g</sup> Institut de Diagnòstic per la Imatge, Centre Bellvitge, Hospital Universitari de Bellvitge, 08097, L'Hospitalet de Llobregat, Barcelona, Spain

<sup>h</sup> Hospital Universitari de Bellvitge (HUB), Neurology Section, Campus Bellvitge, University of Barcelona - IDIBELL, 08097, L'Hospitalet de Llobregat, Barcelona, Spain

<sup>i</sup> Aix Marseille Univ, CNRS, LPL, Aix-en-Provence, France

<sup>j</sup> Catalan Institution for Research and Advanced Studies, ICREA, 08010 Barcelona, Spain

### ARTICLE INFO

#### Keywords:

ESM = electrical stimulation mapping  
Dual stream models for language processing  
Diffusion tensor imaging (DTI)  
Semantic processing  
Voxel lesion-symptom mapping (VLSM)

### ABSTRACT

In the present study, we aimed to test the association between the correct function of the left ventral white matter pathways and semantic processing (dual stream models for language processing, Hickok & Poeppel, 2004), using a new set of language tasks during intraoperative electrical stimulation at white matter level. Additionally, we evaluated brain regions needed for correct performance on the different semantic tasks using lesion-symptom analyses (voxel lesion-symptom mapping and track-wise lesion analysis) in a sample of 62 candidates for the awake brain surgery. We found that electrical stimulation in the vicinity of the inferior longitudinal and inferior fronto-occipital fasciculi disturbed performance on semantic processing tasks. Individuals presented with significantly more semantic paraphasias during brain tumor resection than during the electrical stimulation at the cortex level. Track-wise analyses confirmed the role of these left ventral pathways in semantic processing: a significant relationship was observed between the probability of inferior fronto-occipital fasciculus disconnection/damage and the semantic matching tasks, as well as the number of semantic paraphasias in naming. Importantly, the same analyses for the total score of the Boston Naming Test confirmed significant relationships between this test score and the integrity of the inferior fronto-occipital, inferior longitudinal and uncinate fasciculi. This was further supported by the results of VLSM analyses showing a significant relationship between BNT and the presence of lesion within left middle and inferior temporal gyri. The present findings provide new intraoperative evidence for the role of the white-matter ventral pathways in semantic processing, while at the same time emphasizing the need to include a broader assessment of semantic-conceptual aspects during the awake neurosurgical intervention. This approach will ensure better preservation of functional tissue in the tumoral vicinity and therefore substantially diminish post-surgical language impairments.

**Abbreviations:** AF, arcuate fasciculus; ATL, anterior temporal lobe; BNT, Boston Naming Test; CCT, Camel and Cactus Test; CUSA, Cavitron ultrasonic surgical aspirator; ESM, electrical stimulation mapping; FWER, family-wise error rate; HF, LF, High frequency, low frequency; HI, LI, High imageability, low imageability; IFOF, inferior fronto-occipital fasciculus; ILF, inferior longitudinal fasciculus; MNI, Montreal Neurological Institute; MTG, middle temporal gyrus; PPT, Pyramids and Palm Trees Test; SPT, Semantic Pairs Task; UF, uncinate fasciculus; VLSM, Voxel-lesion symptom mapping; WM, white matter.

\* Corresponding authors at: Cognition and Brain Plasticity Unit, IDIBELL, University of Barcelona (Dept. of Cognition, Development and Education Psychology), Campus Bellvitge, 08097, L'Hospitalet de Llobregat, Barcelona, Spain.

Email addresses: j.sierpowska@donders.ru.nl (J. Sierpowska); antoni.rodriguez@icrea.es (A. Rodríguez-Fornells)

<https://doi.org/10.1016/j.nicl.2019.101704>

Received 24 May 2018; Received in revised form 25 January 2019; Accepted 29 January 2019

Available online xxx  
2213-1582/© 2018.

## 1. Introduction

Semantic processing is a core aspect of language comprehension and production. It permits the access to the meaning of words and, thus, orientation in the surrounding world by means of language production. A plethora of studies on this facet of language processing has focused on individuals with semantic dementia, post-stroke aphasia or temporal lobe resection (Jefferies et al., 2007, 2009; Lambon Ralph et al., 2012; Adlam et al., 2006; Noonan et al., 2013; Cloutman et al., 2009; Schwartz et al., 2009; Mirman et al., 2015). However, individuals with brain tumor have received far less attention (Campanella et al., 2009; Bi et al., 2011), and their intraoperative assessment has mainly focused on naming abilities (for a review: De Witte & Marien, 2013). The interest in this specific population becomes critical in the context of electrical stimulation mapping (ESM) during awake brain surgery.

A large proportion of brain tumors grows in the deep white matter and can alter crucial linguistic pathways of the left hemisphere such as the uncinate (UF), the inferior longitudinal (ILF) and the inferior fronto-occipital fasciculi (IFOF; Anderson et al., 1990). Traditionally, these tracts, along with their surrounding gray matter portions, have been associated with semantic processing, as proposed in dual stream models for language (Hickok & Poeppel, 2007; Saur et al., 2008; Rauschecker and Scott, 2009; Weiller et al., 2011; Kummerer et al., 2013; Brauer et al., 2013; Chang et al., 2015; Skeide & Friederici, 2016; Fujii et al., 2016; Ueno and Lambon Ralph, 2013). Accordingly, the brain portions running dorsally to the central fissure may convert speech sounds into articulatory representations, whereas brain areas located south of this fissure might be involved in the processing of the meaning of words. Importantly, the essential role of the posterior MTG (pMTG) as a semantic processing “hub” has been recently proposed, mostly due to the large functional and structural connectivity observed in this brain area (Binder et al., 2009; Mestres-Misse et al., 2010; Buckner et al., 2009; Vigneau et al., 2006). For instance, Turken & Dronkers (2011) used DTI and resting-state functional connectivity analyses to show that the ventral WM matter pathways (ILF and IFOF) as well as the direct and indirect parieto-temporal branches of the arcuate fasciculus (AF) intersect with the pMTG (see also: Dick and Tremblay, 2012). These structural connections are crucial for the fast communication and transfer of information between other inter- and intra-hemispheric temporal regions, inferior parietal and frontal regions (especially the orbital part of the inferior frontal cortex, BA47). This rich connectivity is probably necessary to properly bind arbitrary lexical representations (words) into a disperse set of representations supported by semantic-conceptual networks (including multisensory-motor representations as well as more abstract type of associations; Allport, 1985). Besides the MTG, the anterior part of the temporal lobe (ATL), where the ILF and UF converge, has been suggested to act as a representational hub that may contribute to refining various modality-specific sources of information (sensory, motor and verbal) into coherent concepts (Rogers et al., 2004; Patterson, 2007).

To the best of our knowledge, only a handful of studies in individuals with brain tumor have reported observations related to the intraoperative monitoring of semantic processing at the deep WM level. For instance, Duffau et al. (2005) found that electrical stimulation of the superior temporal sulcus, the anterior floor of the external capsule, the frontal IFOF terminations and the IFOF itself are the most likely to induce errors of semantic nature (paraphasias). Supporting these observations, Almairac and collaborators (2014) performed a voxel-lesion symptom mapping analysis (VLSM) showing a strong relationship between IFOF integrity and the level of performance on a verbal fluency task. Notice, however, that verbal fluency does not only measure semantic processing, but rather how easily, fluidly, and imaginatively a person can retrieve stored knowledge to produce a particular output

(Banich, 2009). Thus, the level of performance on this task also involves cognitive control mechanisms distinct from pure semantic processing, such as voluntary generation of non-overlearned responses based on sustained activation and selection between possible outputs (Robinson et al., 2012; Schnur et al., 2009; Thompson-Schill et al., 1997). The lack of semantic specificity of the verbal fluency task used in these studies allows the interpretation of the results of Almairac and colleagues (2014) in terms of involvement of cognitive control mechanisms during semantic retrieval rather than strictly semantic processing. Therefore, other types of cognitive tasks are needed or could be more relevant to precisely study semantic processing during awake brain surgery.

In addition, within the ventral WM pathways' triad, the involvement of the IFOF in semantic processing is the most debatable. While the ILF and UF directly project to the areas traditionally related to semantic processing such as the ATL (Sanjuán et al., 2015; for a review Simmons & Martin, 2009), the IFOF does not (Catani and Thiebaut de Schotten, 2008; Egger et al., 2015; but see also, Turken & Dronkers, 2011). Instead, this long horizontal tract reaches the frontal cortex, and thus may subserve functions commonly attributed to the anterior prefrontal cortex, such as cognitive control processes needed for the correct performance on fluency tasks (Jurado and Rosselli, 2007; Aron et al., 2004, 2014; Buchsbaum et al., 2005; Chikazoe, 2010). Interestingly, Jefferies et al. (2007) observed that specific semantic access impairment might arise in individuals with damage encompassing the left inferior frontal cortex. These results suggested a possible role of the IFOF in semantic processing in which semantic selection and lexical retrieval are linked with difficulties in controlling activation within this specific network.

### 1.1. Rationale and development of the study

In the present study, we aimed to explore the direct relationship between ventral pathways for language (IFOF and ILF) and semantic processing during intraoperative electrical stimulation of the left temporal lobe white matter in individuals with brain tumor. We also used a voxel lesion symptom mapping approach (VLSM, Bates et al., 2003) combined with a track-wise lesion analysis (tractotron; Thiebaut de Schotten et al., 2014) to accurately delineate the relationships between the precise lesion location, the integrity of the ILF, IFOF and UF and the level of performance on the different semantic tasks. We first evaluated participants before surgery using a set of naming and semantic matching tasks that are known to tap into different aspects of semantic processing. Specifically, we used four semantic matching tasks for preoperative screening and two of them for intraoperative monitoring (see methods). These tasks allowed us to explore conceptual knowledge based on: visual semantic matching on material varying in complexity (Pyramids and Palm Trees and Camel and Cactus tests) and auditory to picture matching (Environment Sounds Recognition test). We explored lexical semantics by carrying out words matching on items varying in their frequency and imageability (Semantic Pairs Task, see methods). Additionally, we evaluated participants' lexical access abilities with the Boston Naming Test and we calculated the number of semantic paraphasias. In addition, high resolution T1 weighted (and T2 or FLAIR) and diffusion weighted imaging (DWI) data were obtained before surgery. Preoperatively, we used these neuroimaging data to prepare the intraoperative neuronavigation (and thus a correct identification of IFOF/ILF vicinity). After completing the entire sample, we gathered anatomical T1 and T2 or FLAIR data to outline the lesions' extent, compare their precise location with participants' performance on the tasks of interest and calculate the lesion volume. For the intraoperative procedures, we selected the naming, PPT and SPT tests. Each of these measures was individually tailored for participants' preoperative performance in a way that the individuals entered the surgical room at

100% level of accuracy in the tasks. Also, this allowed the participants to be familiarized with tasks instructions. In this manner, we assumed that any error occurring during the surgery might be interpreted as a result of electrical stimulation and not due to the individuals' prior semantic knowledge. Importantly, the same neuropsychologist-experimenter accompanied participants both before and during the surgery.

We hypothesized that: (1) electrical stimulation mapping at the level of IFOF/ILF vicinity should significantly impair performance on semantic matching tasks and induce semantic paraphasias, (2) lesion-symptom analyses should reveal significant relationships between the damaged areas within the ventral pathways for language, and both the number of semantic paraphasias during naming and semantic matching scores (both assessed preoperatively). Additionally, we explored lesion-symptom relationship for the gold-standard naming task (i.e., BNT) to confirm our methodological choices (Baldo et al., 2013).

## 2. Materials and methods

### 2.1. Sample

The study sample was collected during the period from 2012 to 2016 and comprised of 62 participants (28 females) whose intrinsic brain lesions (39 high-grade tumors, 15 low-grade tumors, and seven vascular malformations, see Table 1) infiltrated the deep WM of the left perisylvian language-related areas. All individuals underwent presurgical screening at the Neurology and Neurosurgery Departments of the Hospital Universitari de Bellvitge (Barcelona), permitting to qualify 55 of them for the awake brain surgery. Finally, according to each participant's lesion location and his/her preoperative performance, 16 individuals underwent the intraoperative monitoring for semantic processing (Fig. 1). The study protocol was accepted by the Hospital Universitari de Bellvitge Ethical Committee in accordance with the principles of the Declaration of Helsinki and the participants signed the informed consent for the participation in the study.

### 2.2. Neuropsychological and language assessment

#### 2.2.1. Before surgery

The presurgical assessment protocol included both standard and specific (semantic processing) language and neuropsychological tests. As part of standard evaluation, the following measures were collected: handedness (Edinburgh Inventory; Oldfield, 1971), verbal comprehension (The Token Test; De Renzi and Faglioni, 1978), semantic (animals) and phonological (letter 'p') verbal fluency, attention and working memory (Digit Span – Wechsler Adult Intelligence Scale; Wechsler, 1997). Spanish normative data for these tasks scoring was obtained from the Neuronorma database by Pena-Casanova and collaborators (Pena-Casanova, 2005; Quinones-Ubeda, Gramunt-Fombuena, Aguilar, et al., 2009; Pena-Casanova, Quinones-Ubeda, Gramunt-Fombuena, Quintana-Aparicio, et al., 2009; Aranciva et al., 2012; Casals-Coll et al., 2013) and from the Spanish adaptation of the Wechsler Memory scale, III edition (Wechsler, 2004). Before surgery, two kinds of naming tasks were administered: the Boston Naming Test (BNT, Goodglass and Kaplan, 2001) and a homemade simplified naming task (Havas et al., 2015). The BNT was carried out to allow comparison with normative data and the simplified naming was a screening task allowing tailoring of the task for intrasurgical monitoring (65% of this task completion was a criterion for inclusion in the study). Additionally, these tasks allowed us to accurately compute the number of semantic paraphasias. For specific semantic processing evaluation, participants were also administered the Semantic Pairs Task – SPT (adapted to Spanish from the original 96 synonym judgment task; see Jefferies et al., 2009), Pyramids and Palm Trees Test (PPT, Howard and Patterson, 1992), Camel and Cactus Test (CCT, Bozeat et

al., 2000) and Environmental Sound Recognition Test (or, shortly “The Sounds Task”; Bozeat et al., 2000). All the aforementioned tasks required semantic matching in which the participants were instructed to find the best combinations between: (1) the target image and its best match from two other drawings (PPT, black and white line drawings) or four other images (CCT, color images); (2) the target environmental sound and its best match between six images (3) a target word and its best match between three proposed options (SPT). PPT is a task widely used in clinics, the CCT was downloaded from the open database (The Cambridge Semantic Memory Test Battery, Adlam et al., 2006) and the Environmental Sounds Test was provided from the author upon request (Bozeat et al., 2000). The PPT, CCT, and Sounds tasks were presented to the participants on a laptop computer screen. SPT was a modified version of the original 96 Synonym Judgment Task adapted to Spanish criteria of frequency (Davis and Perea, 2005) and imageability. We further used the low and high ranges of frequency and imageability, resulting in 64 items and a  $2 \times 2$  design. Both indices were varied orthogonally, resulting in sixteen trials in each of the four frequency by imageability conditions. The SPT task was presented to participants by showing the target word and 3 options of response on a computer screen and was additionally read aloud by the experimenter (JS or MJ).

Additionally to the distinct ranges of frequency and imageability created during this task design, we have retrospectively checked whether the Accessibility Index (Nelson et al., 2004) of the items could also influence participants' scores. To do so, the Spanish adapted SPT task was translated back to English and after scanning the database, 48 items could have been normed. On its basis, a median range of Accessibility Index (AccInd) was determined ( $Md = 11$ ) and the items with  $AccInd > median$  were sorted as “High AccInd”, and those with  $AccInd < median$  as “Low AccInd”. Items that hit the median were excluded, as well as one item of extremely high AccInd (“money” with  $AccInd = 302$ ). In this way, 44 items covered these two newly formed ranges (22 Low AccInd + 22 High AccInd).

For the presurgical assessment, normative data for the PPT task were obtained from Gudayol-Ferre et al. (2008), the scores in the SPT task were compared to those of a control sample tested for this purpose (see results). The results on CCT and Sound task were expressed as a percentage of accuracy.

#### 2.2.2. Intraoperatively

During the surgery, only the simplified version of naming task was carried out and again, the number of semantic paraphasias was calculated. In terms of experimental tasks, we used only the PPT and SPT. This time for the SPT task, we created an additional category for comparison difficulty i.e. task difficulty low difficulty- “easy”- items (high frequency, high imageability, HF/HI) and items of high difficulty (low frequency and low imageability, LF/LI). Besides the brain tumor group, 40 healthy controls matched for age, gender and education were assessed with SPT task in order to obtain normative scores.

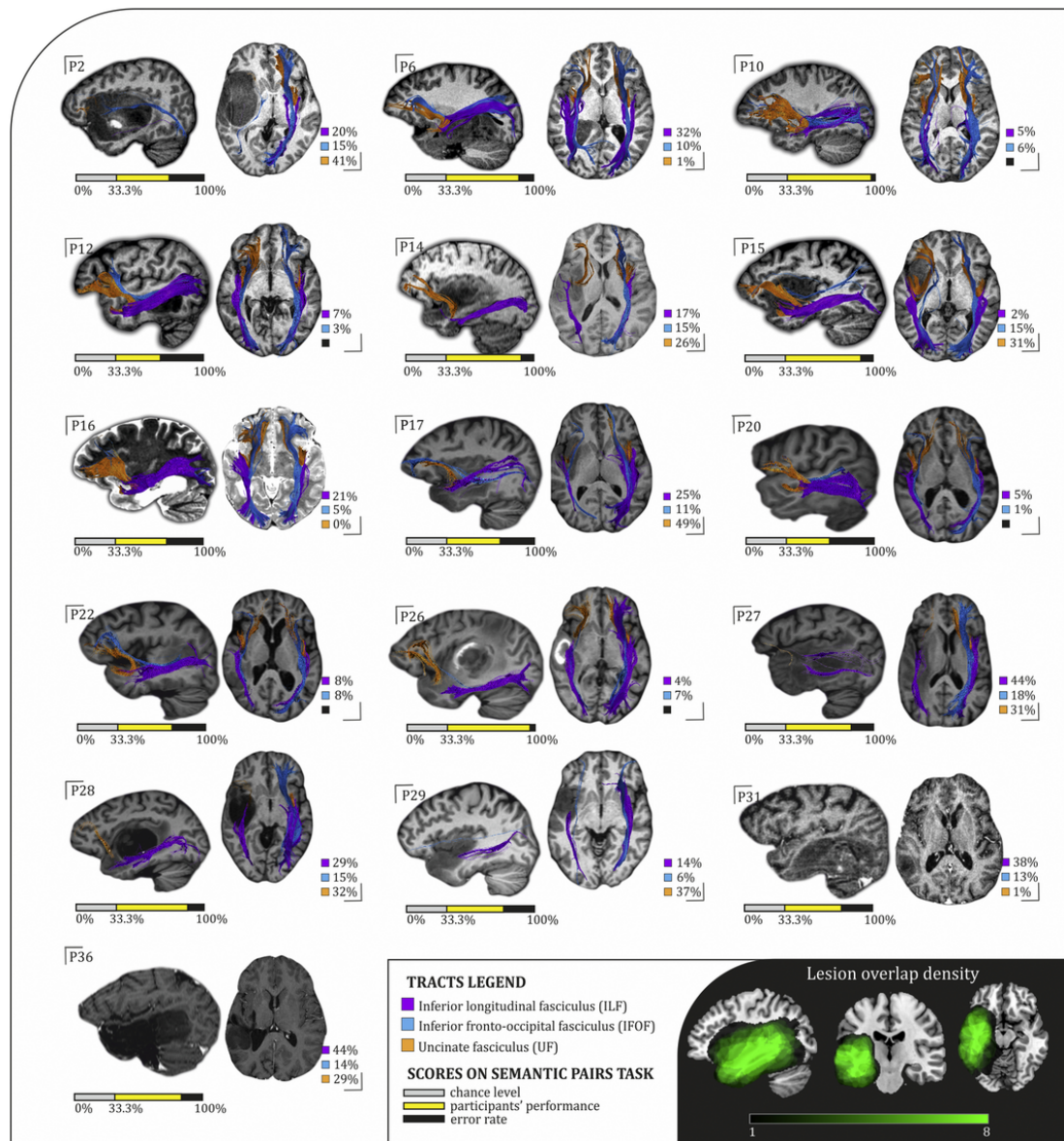
Intraoperative tasks were registered on a tailored response sheet and were audio recorded. A naming item was considered correct if the response was produced immediately after the image presentation, otherwise it was classified as one of the following error types: latency (delay), missing (anomia), language switching, circumlocution (description of a specific concept or object without using its specific name-label), phonological paraphasia (inclusion, substitution, or deletion of word phonemes up to 50% of the target word, for example, pable for table) and semantic paraphasia (substitution of an intended word with another one, within the same or different category, for example pear or shoe for apple), the latter being of special interest for this study. For the SPT and PPT, the item was scored as “correct” only if a correct response was indicated within 3 s after the presentation of the slide. The scoring sheets were compared to the audio recordings by the main experimenter (JS) after the surgery and corrected accordingly. The intra-

**Table 1**  
Participants' demographic data and lesion main features.

	Participant's code	Gender (female)	Age (years)	Education (years)	Handedness (Edinburgh Inventory)	Lesion type	WHO grade	Lesion volume (ml)
1	P1	.	51	12	10	hemiangioblastoma	4	19,0
2	P2	.	46	12	30	glioblastoma	4	121,1
3	P3	.	57	6	10	glioblastoma	4	146,6
4	P4	.	45	12	10	diffuse astrocytoma	2	49,0
5	P6	.	22	12	10	diffuse astrocytoma	2	93,7
6	P7	f	57	10	10	glioblastoma	4	49,7
7	P8	f	64	6	10	metastasis of the parotid gland	4	55,0
8	P9	f	18	11	10	cavernous angioma	-	3,4
9	P10	.	23	14	15	diffuse astrocytoma	2	21,8
10	P11	f	33	10	10	cavernous angioma	-	14,3
11	P12	.	47	10	45	glioblastoma	4	13,2
12	P13	.	43	8	10	anaplastic astrocytoma	3	230,5
13	P14	.	39	12	43	oligoastrocytoma	3	101,5
14	P15	.	57	12	10	anaplastic oligodendroglioma	3	79,0
15	P16	.	57	8	10	diffuse astrocytoma	2	47,4
16	P17	f	47	10	46	anaplastic oligoastrocytoma	3	88,4
17	P18	f	37	6	10	anaplastic oligoastrocytoma	3	20,8
18	P19	.	42	10	10	anaplastic oligoastrocytoma	3	254,0
19	P20	.	62	12	10	glioblastoma	4	26,8
20	P21	.	45	14	10	glioblastoma	4	19,1
21	P22	f	67	3	10	glioblastoma	4	42,1
22	P23	f	56	8	10	glioblastoma	4	130,7
23	P24	.	57	8	10	glioblastoma	4	33,3
24	P25	f	41	12	10	diffuse astrocytoma	2	125,2
25	P26	f	67	8	10	glioblastoma	4	42,3
26	P27	.	59	8	10	diffuse large B-cell lymphoma	3-4	134,3
27	P28	f	62	13	10	gliosarcoma	4	124,7
28	P29	.	40	8	10	diffuse (fibrillar) astrocytoma	2	51,7
29	P30	f	45	17	10	oligodendroglioma	2	61,3
30	P31	.	65	10	10	oligodendroglioma	2	85,8
31	P32	.	47	12	10	diffuse astrocytoma	2	179,0
32	P33	f	60	10	10	glioblastoma	4	97,4
33	P34	.	40	20	10	glioblastoma	4	135,2
34	P35	f	66	10	10	glioblastoma	4	74,5
35	P36	f	30	10	35	oligoastrocytoma	2	99,1
36	P37	f	39	15	10	glioblastoma with oligodendroglial component	4	218,0
37	P38	.	28	12	10	diffuse astrocytoma	2	124,3
38	P39	f	49	12	10	arterovenous malformation	-	2,9
39	P40	.	65	4	10	glioblastoma with oligodendroglial component	4	98,8
40	P41	f	61	4	10	glioblastoma	4	34,6
41	P42	f	39	15	10	arterovenous malformation	-	130,3
42	P43	.	25	10	10	glioma	3-4	285,1
43	P44	.	40	15	40	glioblastoma	4	176,8
44	P45	.	37	15	10	oligoastrocytoma	3	69,0
45	P46	.	28	12	10	oligoastrocytoma	2	185,7
46	P47	.	40	12	16	low-grade glioma*	2	65,4
47	P49	f	67	8	10	glioblastoma	4	59,8
48	P50	f	53	12	10	glioblastoma	4	14,7
49	P51	f	33	18	10	glioblastoma	4	28,3
50	P52	.	68	12	10	glioblastoma	4	132,3
51	P53	f	45	15	10	metastasis of carcinoma	3-4	79,6
52	P56	.	38	18	10	oligodendroglioma	2	96,7
53	P57	f	38	12	10	anaplastic astrocytoma	3	33,4
54	P58	.	35	10	10	oligodendroglioma	2	23,0
55	P59	f	30	12	10	arterovenous malformation	-	4,1
56	P60	.	54	10	10	anaplastic astrocytoma	3	14,7
57	P61	f	44	10	10	cavernous angioma	-	1,7
58	P62	f	35	10	10	diffuse astrocytoma	2	10,9
59	P63	.	33	16	10	anaplastic oligodendroglioma	3	54,6
60	P64	f	35	15	10	cavernous angioma	-	0,4
61	P65	.	60	4	10	anaplastic astrocytoma	3	35,1
62	P66	.	35	18	10	glioblastoma	4	163,0
		∑ 28 women	M = 45.8 SD = 11.1	M = 11.1 SD = 3.6	M = 13.1 SD = 9.0	.	∑ 31 HG ∑ 16 LG	M = 80.9 SD = 66.8

f, female; WHO, World Health Organization; M, Mean; SD, Standard deviation.

\* Not confirmed by biopsy, HG, high-grade, LG, low-grade.



**Fig. 1.** White background: DTI virtual in-vivo dissections of the tracts of interest ILF/UF/IFOF superimposed on the T1 weighted images of 16 individuals who performed the intraoperative monitoring of semantic processing during the awake brain surgery (DTI data from participants 31 and 36 were not available). On the right side of each brain image- the proportion of possible tract damage calculated using Tractotron is reported (only the tracts in which the probability of disconnection surpassed 50% are marked in colors, otherwise in black). Below each brain image, the percentage of correct responses on Semantic Pairs Task is depicted (light gray color-chance level (33%), yellow-correct responses, black-error rate). Dark-gray background: Lesion overlap for the 16 individuals undergoing semantic processing intraoperative assessment, lesions outlines normalized to MNI. All the images are presented in the neurological convention.

operative results in naming were expressed as a proportion between accurately named items/all the presented items and the number of semantic paraphasias/all the presented items. The results in PPT and SPT were expressed as a proportion between correct responses/presented items.

### 2.3. Brain imaging data

The anatomical (T1 and/or T2 weighted and/or FLAIR and/or diffusion-weighted MRI) images were collected before surgery at the Hospital Universitari de Bellvitge and the Duran i Reynals Hospital (if participants were redirected from a distinct area, their raw anatomical data were obtained upon request. For more detailed information consult our previous work: Sierpowska et al., 2016). Data necessary for lesion-symptom analyses (track-wise and VLSM) were obtained by

drawing the lesion outline in the native space using MRIcron software package (<http://www.mccauslandcenter.sc.edu/crnl/mricron/>. Rorden and Brett, 2000). All lesion outlines were delineated by the same experimenter (JS) in the axial plane and further smoothed for sharp edges (Fig. 1 for the visualization of lesions). Further, the unified segmentation (Ashburner & Friston, 2005) with medium regularization and cost function masking (CFM) was applied to the T1 weighted image using the resliced lesion mask, in order to obtain the normalization parameters (Andersen, Rapsak, & Beeso, 2010; Brett et al., 2001; Ripolles et al., 2012). Then, using these parameters, both the T1 image and the resliced lesion mask were normalized to MNI space. After the normalization, the experimenter reviewed the individual masks and T1 images confirming that no distortions occurred. Lesion volume was obtained by multiplying the number of voxels composing the lesion by the voxel size in the native space.



#### 2.4. Voxel-based lesion symptom mapping (VLSM)

VLSM was performed to explore the relationships between precise lesion location and language performance, voxel by voxel. This analysis is based on a division of participants into two groups: according to whether or not their lesion affected a particular voxel. Behavioral scores are then compared between these two groups, yielding a t-statistic for each voxel (Bates et al., 2003). We carried out the VLSM analysis for four preoperative measures: PPT, SPT, BNT (with the semantic paraphasias scored separately) reaching the final sample of  $N = 41$ ,  $N = 40$  and  $N = 62$ . (The analyses were not performed for CCT and the Sounds task due to an insufficient number of subjects completing the extended language/neuropsychological assessment protocol). To involve a particular voxel in the analysis, a minimum of 20% of individuals presenting a lesion in this location was required. VLSM was performed with Chris Rorden's nonparametric mapping software – NPM (version June, 1, 2015) using 1000 permutations and Brunner-Munzel test. The results were displayed at a  $p < .05$  permutation-based family-wise error rate (permutation-based FWER) corrected threshold.

#### 2.5. Track-wise lesion analysis

We performed a track-wise lesion analysis based on a method that uses an atlas of human adult white matter tracts to explore the impact of lesions on the IFOF, ILF, and UF. The Tractotron toolbox provides a percentage of likelihood for a specific tract to be disconnected, thus offering more information to describe the pattern of damage induced by the lesion. The probability and proportion of damage were calculated based on the comparison between the voxels depicting lesion distribution and a WM atlas, both within the MNI coordinates (Thiebaut de Schotten et al., 2014). We expressed the probability of tract disconnection in two ways: continuous and binary (preserved vs. disconnected – if the probability of damage was higher than 50%, the tract was assumed to be disconnected, otherwise as “preserved”).

In order to quantify the severity of disconnection, we calculated the proportion of disconnected tracts (voxels affected by a lesion/all voxels composing the tract) and treated them as a continuous variable in further analyses. To illustrate how the software estimates the tracts disconnection, we compared a high proportion of lesion impact on the UF and the virtual absence of this tract in individuals P2, P17 and P27 and a low proportion of lesion impact on this tract and its conservation in P6, P10 and P16 (see Fig. 1).

To further confirm the anatomical specificity of the white matter damage, the severity of disconnection was converted into z-values, allowing us to assess whether the IFOF, ILF, and UF were statistically more damaged than the assembly of major WM tracts of the human brain. Z-scores were calculated on the basis of mean proportion of 22 main WM tracts of participants, reproducing the methodology reported by Thiebaut de Schotten et al., 2015. Z-scores higher than 1.96 were considered as statistically more damaged than the mean being  $p < .05$ , two-tailed statistical threshold for this analysis (see Table A in the supplementary material).

#### 2.6. WM pathways visualization

In 14 individuals undergoing awake brain surgery and semantic processing monitoring, IFOF, ILF, and UF were dissected in vivo, for visualization purposes. The dissections were carried out according to the anatomical landmarks comprised in WM atlas (Catani and Thiebaut de Schotten, 2008) and replicating previously reported procedures (François et al., 2016; Sierpowska et al., 2015). DWI data from two participants could not be obtained (P31 and P36), and thus we based

our observations on both visual exams of lesion location and on IFOF, ILF, and UF track-wise analyses results.

#### 2.7. Electrical stimulation mapping (ESM)

We explored WM involvement in semantic processing intraoperatively using the SPT, PPT, and naming tasks (intraoperative situation and time constraints allowed us to choose only three tasks from the preoperative protocol). Furthermore, we recorded participants' online performance on the naming task to compute the number of semantic paraphasias in two stages of surgery: during the ESM procedures at the cortical level and during the tumoral resection/electrical stimulation at the WM level. On this basis, we extracted a global measure of error rates for each individual separately. Importantly, because both SPT and PPT tasks rely on semantic matching mechanisms, the participant needs to identify and process all the items presented in a particular trial (i.e. a target word and three possible responses for the SPT and a target image and two possible responses for the PPT). This higher cognitive load may be further translated to slower reaction time, in contrast to the immediate response in the naming tasks. For this reason, we focused on the electrical stimulation that was provoked by the mere resection of the tumor (see Carrabba et al., 2008) and thus of longer duration than the one applied at the brain cortex level (usually lasting for less than one second). Indeed, we tested participants simultaneously via the stimulation of tumor adjacent structures achieved using Cavitron Ultrasonic Surgical Aspirator (CUSA). This type of stimulation is comparable to the stimulation induced by the Ojemann cortical stimulator in ESM (the mechanism of CUSA was explained in the original paper Carrabba et al., 2008 and in our previous publication, Sierpowska et al., 2016). Thanks to a more long-lasting and widespread stimulation provoked by CUSA, we were able to test the performance on semantic processing tasks each time the surgical manipulations approached the level of the ventral WM pathways. Within the sample of 16 individuals undergoing surgery with semantic processing monitoring, we have only tested the tasks in the ILF/IFOF vicinity and/or intersection (UF was usually at a considerable distance from the main location of cranial exposure resultant from the fronto-temporo-parietal craniotomy). The online information about the IFOF/ILF level in tumoral resection and CUSA work was possible with the neuronavigation system using in vivo reconstructions for WM sub-cortical fasciculi (iplan, BrainLab TM).

#### 2.8. Statistical analysis

The level of performance on the PPT, SPT, CCT, the Sound task and BNT tasks as well as the number of semantic paraphasias were not normally distributed (Shapiro-Wilk test), therefore Spearman correlations were used. The correlations were computed between: (1) the lesion volume and the number of semantic paraphasias occurring during surgery, (2) the preoperative and intraoperative performances on the tasks of interest and finally (3) individuals' performance on these tasks and both the probability and proportion of tract disconnection (IFOF, ILF and UF).

Mann-Whitney U tests were used to test if level of performance depended on whether the tract was disconnected or preserved. The number of semantic paraphasias that occurred during surgical procedures at the cortical level or at the white matter level was compared using repeated measures t-test. Similarly, the two levels of difficulty of the SPT task (easy versus difficult; 1), frequency effect (high versus low; 2); imageability effect (high versus low; 3), semantic accessibility effect (high versus low, 4), and the difference between PPT and SPT error rates (5) were assessed using paired samples t-test.

The threshold for significance was set at  $P = .05$  (uncorrected). For correlations, we assumed that an increase in damage to the tract should

be related with poorer performance on the task or to a more frequent occurrence of semantic paraphasias. Also, we assumed that the preoperative performance should not be inversely correlated with the intraoperative score. Therefore, one-tailed significance levels were considered.

All the aforementioned statistical analyses were performed with SPSS PASW Statistics 18 (SPSS Inc. Released 2009. PASW Statistics for Windows, Version 18.0. Chicago: SPSS Inc).

### 3. Results

#### 3.1. Preoperative assessment

Before surgery, 62 participants were assessed with the BNT, and a large proportion of them completed the PPT and SPT tasks (41 and 40 out of 62, respectively). Only a small number of participants were evaluated using the CCT (29) and the Sounds Task (19), usually due to fatigue. Overall, individuals scored the highest in the PPT task (above 90%) and had around 80% of accuracy in the remaining semantic tasks (Table 2). The mean of the scaled scores on the BNT was of 7 (SD = 3.6).

A control group undergoing assessment on SPT task scored  $M = 60.7$ ,  $SD = 2.45$  on the total score of the task;  $M = 30.38$ ,  $SD = 1.48$  for the HF items,  $M = 30.33$ ,  $SD = 1.37$  for the LF items;  $M = 31.43$ ,  $SD = 0.96$  (HI items) and  $M = 29.28$ ,  $SD = 2$  (LI items). On the basis of these results from healthy population, we further calculated Z-scores to observe the extent to which individuals with brain tumor differed from the control sample. (Notice that the Z-scores were further used for the VLSM analyses. See Fig. 4 for the Z-score dependent difference in lesion locations).

#### 3.2. Intraoperative semantic paraphasias

We replicated previously reported methodology, confirming the appearance of semantic paraphasias during tumoral resection at the level of the left temporal lobe (Duffau et al., 2005; Rofes et al., 2017). Additionally, we analyzed semantic errors as a function of the stages of surgery (electrical stimulation at the cortex level versus CUSA action at the WM level) and observed that the number of semantic paraphasias was significantly higher during resection of the tumor than during electrical stimulation at the cortical level ( $t[14] = 2.9$ ;  $P = .012$ ).

Furthermore, we observed that the number of semantic paraphasias occurring during tumor resection was predicted by lesion volume before surgery ( $r_s(14) = 0.613$ ;  $P = .008$ , see Fig.2 A). However, this type of error was particularly unusual during surgery (fifteen participants committed <5% of semantic errors during the cortical ESM and during tumor resection the number of semantic paraphasias was lower than 5% in 8 participants, for the exact scores see Table 3). Thus, we sought complementary and more sensitive tasks to refine the intraoperative monitoring of semantic processing.

#### 3.3. Intraoperative semantic processing tasks performance

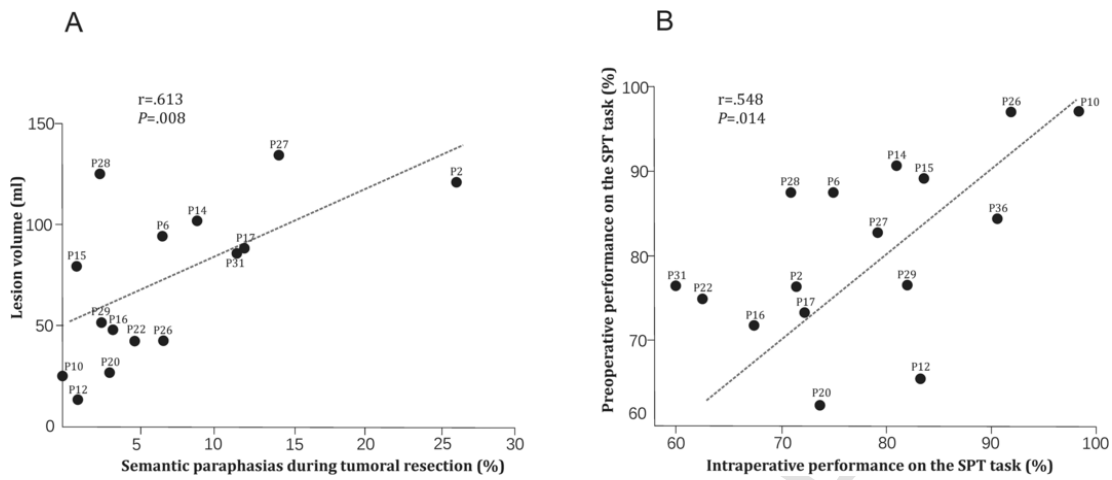
Individuals presented errors in both tasks (PPT, SPT) intraoperatively (Table 3). However, the error rate was higher for SPT than for the PPT ( $t(7) = -5.32$ ,  $P = .001$ ). Importantly, the presurgical performance on the SPT task significantly predicted the intrasurgical one ( $r_s(15) = 0.548$ ,  $P = .014$ , Fig. 2 B), whereas there was no such effect for the PPT. Further, the SPT task allowed assessing semantic processing also in those individuals who presented a very low number of semantic paraphasias. Before surgery, we observed the effects of both imageability and frequency within the SPT task ( $t(39) = 2.07$ ,  $P = .045$ ;  $t(39) = 2.16$ ,  $P = .037$ , respectively), Similar effects were found for the semantic Accessibility Index ( $t(39) = 6.78$ ,  $P < .0001$ ).

**Table 2**  
Participants' preoperative performance on the tasks of interest.

	Participant's code	BNT SS	PPT %	SPT %	CCT %	The sounds task %	NWR/40
1	P1	12	-	88	77	-	
2	P2	4	-	77	43	-	25
3	P3	6	96	81	63	-	32
4	P4	10	100	98	97	-	35
5	P6	7	90	88	93	-	40
6	P7	7	98	72	97	-	28
7	P8	7	44	72	57	-	38
8	P9	7	90	81	100	-	37
9	P10	9	92	97	-	-	40
10	P11	4	94	44	83	-	38
11	P12	5	96	66	83	88	33
12	P13	7	73	33	83	94	39
13	P14	7	96	91	-	-	21
14	P15	11	98	89	84	19	30
15	P16	3	98	72	81	79	27
16	P17	5	92	73	88	98	35
17	P18	8	100	83	88	98	36
18	P19	2	92	67	83	96	38
19	P20	6	96	63	80	88	30
20	P21	7	96	95	91	75	25
21	P22	6	79	75	-	-	40
22	P23	3	92	69	-	-	20
23	P24	12	92	77	-	-	35
24	P25	2	87	69	-	50	33
25	P26	3	92	97	-	-	1
26	P27	9	94	83	84	96	35
27	P28	6	96	88	88	75	37
28	P29	11	100	77	84	92	35
29	P30	11	100	98	88	98	40
30	P31	2	98	77	78	85	39
31	P32	2	81	61	64	58	23
32	P33	2	-	-	-	-	26
33	P34	1	100	-	-	-	38
34	P35	2	83	61	-	-	38
35	P36	2	100	84	90	-	37
36	P37	5	-	-	-	-	-
37	P38	9	94	86	-	-	21
38	P39	9	94	86	-	-	35
39	P40	3	77	55	-	67	35
40	P41	10	-	-	-	-	31
41	P42	2	58	-	-	-	33
42	P43	7	94	92	95	100	40
43	P44	6	90	88	83	-	35
44	P45	10	-	-	-	-	-
45	P46	14	-	-	90	-	37
46	P47	2	85	-	-	-	35
47	P49	11	96	84	-	79	39
48	P50	11	-	-	-	-	21
49	P51	14	-	-	-	-	39
50	P52	2	-	-	-	-	38
51	P53	9	-	-	-	-	32
52	P56	5	-	-	-	-	-
53	P57	14	-	-	-	-	-
54	P58	9	98	80	-	-	-
55	P59	12	-	-	-	-	-
56	P60	8	-	-	-	-	-
57	P61	10	-	-	-	-	-
58	P62	10	-	-	-	-	-
59	P63	7	-	-	-	-	-
60	P64	10	-	-	-	-	-
61	P65	10	-	-	-	-	-
62	P66	6	-	-	97	-	-
<b>Total patients</b>		<b>62</b>	<b>41</b>	<b>40</b>	<b>29</b>	<b>19</b>	<b>48</b>
<b>Mean</b>		<b>7.0</b>	<b>90.8</b>	<b>77.9</b>	<b>83.17</b>	<b>80.8</b>	<b>32.9</b>
<b>SD</b>		<b>3.6</b>	<b>11.3</b>	<b>14.4</b>	<b>12.7</b>	<b>20.7</b>	<b>2.9</b>

BNT, Boston Naming Test; SS, Scalar Score; PPT, Pyramids and Palm Trees Test; SPT, Semantic Pairs Task; CCT, Camel and Cactus Test; NWR, non-words repetition.





**Fig. 2.** Spearman correlations between: lesion volume and the proportion of semantic paraphasias produced during the tumoral resection (A) and between the percentages of errors committed during the Semantic Pairs Task before versus during the surgery (B).

**Table 3**

Intraoperative scores on the semantic matching tasks and semantic paraphasias amount.

Participant's code	Sem. Paraph. at the cortex level (%)	Sem. Paraph. at the WM level (%)	TOTAL PPT (%)	TOTAL SPT (%)	HF/HI SPT (%)	LF/LI SPT (%)
1 P2	2	26	–	71	79	59
2 P6	3	7	–	75	88	60
3 P10	0	0	–	98	100	93
4 P12	0	1	94	83	93	71
5 P14	4	9	–	81	100	54
6 P15	0	1	96	84	88	73
7 P16	1	3	94	67	92	57
8 P17	0	12	83	72	94	17
9 P20	1	3	80	74	80	29
10 P22	5	5	–	63	73	29
11 P26	6	7	–	92	93	81
12 P27	3	14	–	79	96	71
13 P28	3	3	86	71	80	57
14 P29	0	3	92	82	100	50
15 P31	3	12	–	60	*	*
16 P36	0	0	97	91	100	73
<b>The number of participants</b>	<b>16</b>	<b>16</b>	<b>8</b>	<b>16</b>	<b>15</b>	<b>15</b>
<b>Mean</b>	<b>1.94</b>	<b>6.63</b>	<b>90.25</b>	<b>77.69</b>	<b>90.4</b>	<b>58.27</b>
<b>SD</b>	<b>1.98</b>	<b>6.83</b>	<b>6.39</b>	<b>10.58</b>	<b>8.82</b>	<b>20.69</b>

Sem.Paraph., semantic paraphasia; PPT, Pyramids and Palm Trees Test; SPT, Semantic Pairs Task; HF/HI, High frequency/high imageability; LF/LI, Low frequency/low imageability. \*, results on the imageability and frequency measures were not taken into account for the Participant 31 due to an extremely low number of items presented (10 items, 6 correct)

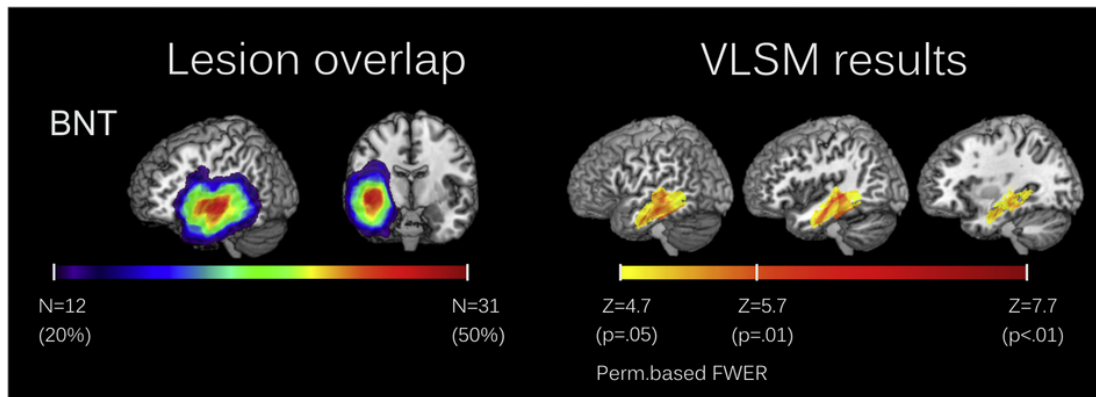
Intrasurgically, the frequency effect disappeared ( $P = .062$ ) and the imageability and semantic accessibility effects both remained ( $t(14) = 8.06$ ,  $P < .001$  and  $t(14) = 2.78$ ,  $P = .15$ ). During brain tumor removal, participants committed significantly more errors for “difficult” items (low frequency and low imageability) than for “easy” items (high frequency and high imageability;  $t(14) = -6.7$ ;  $P < .001$ ).

**3.4. Lesion-symptom analyses– VLSM**

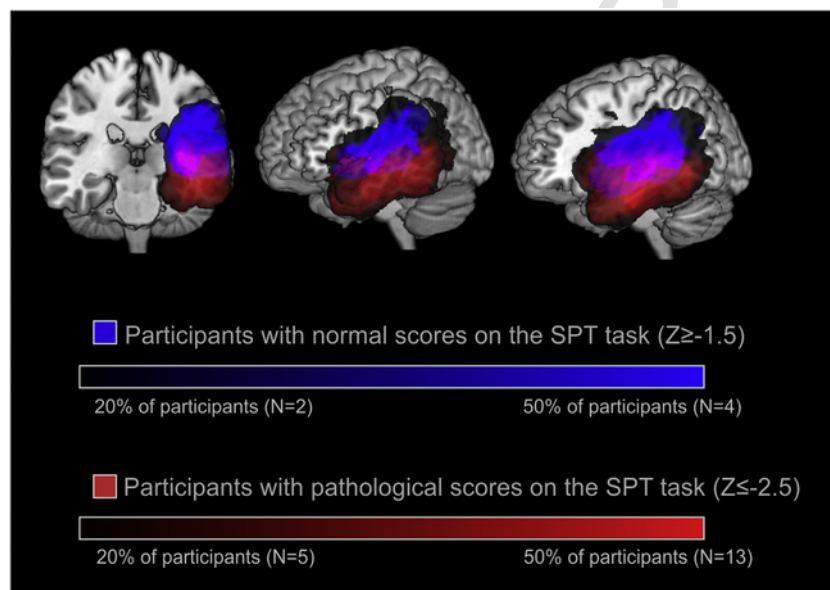
The VLSM analyses for the BNT task score revealed associations with the damage of structures within the left middle (MTG) and inferior temporal gyri ( $Z = 4.7$ , permutation-based FWER corrected, Fig. 3, see also Mirman et al., 2018), but no voxels were significantly associated with the total score of semantic paraphasias, PPT or SPT tasks using the same correction method.

**3.5. Visual assessment of lesions' site related to normal and pathological scores on SPT task**

Following the intraoperative results on the SPT task, we performed a visual exploration of lesion distribution as a function of the SPT score. We divided our sample into two groups: participants presenting pathological scores ( $Z \leq -2.5$ ) and participants with normal scores ( $Z \geq -1.5$ ). This visual comparison of the overlap of lesions classified per group (Fig. 4) showed that the normal scores on the SPT task were related to the presence of lesions located around the Sylvian fissure and superior to the latter, whereas the pathological scores were associated with lesions mainly encompassing the left middle and inferior temporal gyri.



**Fig. 3.** Lesion overlap maps (left panel) and VLSM results maps (right panel) for the Boston Naming Test (BNT;  $N = 62$ ). The lesion overlap maps are displayed starting from 20% of overlap - the minimal threshold established for the voxels to be involved in the analysis and extended until 50% of the overlap, for visualization purposes. The VLSM results start from the threshold surviving the permutation based family-wise error rate (permutation-based FWER) correction ( $P < .05$ ) and is extended to more stringent statistical significance values ( $P < .01$ ) for visualization purposes. Images are displayed in neurological convention.



**Fig. 4.** Lesion overlap of participants with pathological score ( $Z \leq -2.5$ ,  $N = 26$ ) on Semantic Pairs Task (SPT) contrasted with the lesion map of participants with normal scores on this task ( $Z \geq -1.5$ ,  $N = 8$ ).

### 3.6. Visualization of white-matter pathways and track-wise lesion-deficit analysis

The deterministic manual reconstruction of IFOF, ILF, and UF with DTI in vivo virtual dissections (see Fig. 1) confirmed that the integrity of ILF and IFOF was directly compromised in all individuals, whereas the UF was damaged in eight participants.

Quantitatively, the probability of disruption of the tracts of interest was above chance level in 52 of 62 individuals for the IFOF, in 41 for the ILF and in 38 for the UF. The mean proportion of damage was of:  $0.11 \pm 0.11$  for the IFOF;  $0.66 \pm 0.45$  for the ILF and  $0.17 \pm 0.22$  for the UF. Importantly, Tractotron allowed us estimating the level of disconnection/damage of specific white matter tracts in two participants in whom the DWI data were not available. In these tracts (P31 and P36, see Fig. 1), the track-wise analysis revealed a high probability of damage ( $> 50\%$ ) for all the tracts of interest. Furthermore, the proportion of disconnected tracts showed that the most significantly damaged was the ILF in both individuals ( $Z$ -score  $> 1.96$ , see supplementary material).

We used tractotron values to estimate the relationships between damage of specific tract (probability and proportion, Table 4) and task performance. In this manner, we aimed to complement our VLSM results providing results pinpointing to WM more precisely. In line with the intraoperative observations, results of the Mann-Whitney U test revealed that the level of performance on the SPT task was significantly higher for the individuals with a preserved IFOF integrity ( $Mdn = -1.09$ ) than for those presenting a disconnected IFOF ( $Mdn = -4.7$ ; see Table 4 for U- and P- values). When the continuous measures of tracts disconnection probability were implemented, the relationship between IFOF and SPT was not confirmed. However, two additional effects were revealed for this tract with the disconnection probability correlating with the performance on the PPT task and the number of semantic paraphasias (see Table 4 for the  $r_s$  and P values). Furthermore, results indicated that the performance on BNT relied on the integrity of all the tracts of interest. Scores in this task were significantly higher in participants with spared IFOF ( $Mdn = 10$ ); ILF ( $Mdn = 10$ ) and UF ( $Mdn = 9.5$ ), than it was if these tracts were substantially damaged ( $Mdn = 6$ ,  $Mdn = 6$ ,  $Mdn = 5.5$ , respectively, see Table 4 for U- and P- values). Importantly, this observation was further

**Table 4**

Mann-Whitney U tests results for the relationships between the specific tasks performance and the probability of the tracts disconnection/damage (binary measure) and Spearman correlation results for the links between the tasks performance and both probability and proportion (continuous measures) of the tracts disconnection/damage.

	IFOF		ILF			UF			
	Probability		Proportion	Probability		Proportion	Probability		
	Binary	Continuous	Continuous	Binary	Continuous	Continuous	Binary	Continuous	
<b>SPT</b>	27.5*	–	–	–	–	–	–	–	–0.319*
<b>PPT</b>	–	–0.305*	–0.310*	–	–	–	–	–	–0.262*
<b>BNT</b>	119**	–0.490***	–0.474***	197***	–0.635***	–0.588***	203***	–0.435***	–0.423**
<b>Sem. paraphasias</b>	–	0.320*	–	–	–	–	–	–	–
<b>The Sounds task</b>	–	–	–	–	–	–	–	–	–
<b>CCT</b>	–	–	–	–	–	–	–	–	–

CCT, Camel and Cactus Test; BNT, Boston Naming Test; PPT, Pyramids and Palm Trees Test; SPT, Semantic Pairs Task; IFOF-inferior fronto-occipital fasciculus; ILF-inferior longitudinal fasciculus; UF, uncinat fasciculus.

\*  $P < .05$ .

\*\*  $P < .01$ .

\*\*\*  $P < .001$ .

confirmed by the significant correlations between the performance on BNT and the indices of proportion of disconnection in all the tracts. Finally, no significant relationships were detected between the tracts of interest and both the Sound Task and CCT.

#### 4. Discussion

In the present study, we provide new evidence for the crucial role of the left ventral pathways for language processing using combined intra-operative electrical stimulation mapping and lesion-symptom analyses.

We found that the electrical stimulation at the level of IFOF/ILF disrupted semantic processing during the semantic matching task (SPT). Moreover, the track-wise analysis revealed that the preoperative scores on the SPT task were associated with the probability of IFOF damage (Table 4, see also Fig. 1). Importantly, both the track-wise and the VLSM findings support the previously shown robust relationship between the naming tasks and the integrity of the ventrally located brain areas. The same was only partially confirmed for the total count of semantic paraphasias (moderate association with the IFOF disconnection probability) which, in turn, appeared frequently during tumoral resections within the left temporal lobe.

##### 4.1. Preoperative findings

Using the presurgical anatomical neuroimaging data, we performed VLSM and track-wise analyses for both semantic matching tasks and the Boston Naming Test (commonly used in ESM), with a specific focus on the number of semantic paraphasias before surgery. These analyses revealed strong links between the total normalized score on the BNT and with both the left MTG and the inferior temporal cortices (VLSM outcome, Fig. 3) and additionally with the integrity of the IFOF, ILF, and UF (track-wise indices). This outcome is of the utmost importance for the individuals with a brain tumor – firstly, this area represents an anatomical hyper-connected hub, where several white matter structures converge (including IFOF, ILF, direct and indirect segments of arcuate fasciculus, middle longitudinal fasciculus and transcallosal projections; Turken & Dronkers, 2011) and secondly – the posterior MTG has been suggested as crucial for learning the meaning of new words. The language learning model by Rodriguez-Fornells et al. (2009) emphasizes the specific role of the MTG as a multimodal semantic processing “hub” involved in storing and accessing long-term conceptual knowledge, lexico-semantic processing, and semantic integration. Several studies showed clear activation in this region when participants were acquiring the meaning of new words (Mestres-Misse et al., 2010;

Ripolles et al., 2014). Furthermore, the strength of the white matter pathways running beneath these left temporal areas can predict the success in the semantic learning (Ripolles et al., 2017). In addition, our findings completed the results by Papagno and collaborators who reported that, at 3 months after surgery, participants after surgical removal of the UF were obtaining significantly lower scores in picture naming when compared to the group with spared UF (Papagno et al., 2011). Our output also extended previous results reported in stroke (Baldo et al., 2013), showing a robust relationship between the occurrence of lesions in MTG and naming scores. In a similar fashion, Catani et al. (2013) showed that the damage to UF correlated with the deficits in semantic processing as assessed by the Peabody Picture Vocabulary Test in individuals with Primary Progressive Aphasia. In healthy subjects, Ripolles et al. (2017), showed an association between the microstructural properties of the UF and the cross-situational semantic learning.

Importantly, we could not confirm in our sample, VLSM-based relationships with semantic processing as measured by semantic matching tasks (using permutation-based FWER correction method). However, we did find a moderate effect for the track-wise measure of IFOF disruption probability and both PPT and SPT semantic matching tasks, as well as with the total count of semantic paraphasias in the BNT. These track-wise results suggest that future work should be necessarily undertaken in order to further explore the involvement of the IFOF in mental operations of this kind. Importantly, although the number of pre-operative semantic paraphasias correlated with the track-wise index of IFOF integrity, the VLSM analysis did not confirm similar relationships between the integrity of areas comprising the left ventral pathways for language and the same preoperative score. This means that counting the number of semantic paraphasias is still not sensitive enough for the pre-operative assessment of semantic processing in individuals with a brain tumor, which is also at odds with a previous report by Schwartz and collaborators (2009). These authors performed a VLSM analysis in 64 post-stroke individuals and showed a strong relationship between semantic errors in naming and left anterior temporal lobe lesions. However, stroke is an acute brain insult, whereas brain tumors develop over months or years (Louis et al., 2016). Therefore, plasticity mechanisms appearing in the presence of slow-growing brain tumors, but absent in abrupt brain damage, may explain these differences (Kong et al., 2016).

##### 4.2. Intraoperative findings

The first relevant outcome showed that the participants from our sample produced more semantic paraphasias during tumor resection

than during the ESM at the cortical level, confirming previous intrasurgical observations using electrical stimulation mapping (Duffau et al., 2005; Rofes et al., 2017). This result may also indicate that this type of error appears once a severe disconnection of the WM has occurred. Furthermore, we observed that the number of semantic paraphasias occurring during tumoral resection positively correlated with the lesion volume, which goes in line with a study showing that the amount of resected tissue in individuals with unilateral temporal lobe sclerosis predicted the severity of semantic impairment (Lambon Ralph et al., 2012). We also observed that the appearance of semantic paraphasias is extremely unusual during brain surgery (see results section), and some participants were not committing any errors of this kind.

In contrast to the intraoperative semantic paraphasias observed during the naming task, we were able to observe semantic errors in all participants with the SPT task. Moreover, the number of preoperative errors in the SPT task predicted the intraoperative performance (Fig. 2). Interestingly, we did not observe a clear effect of word frequency in the SPT task performed during tumoral resection. A lack of this effect was suggested as a characteristic of semantic access deficits (in contrast to semantic storage degradation, Warrington and Shallice, 1979; Campanella et al., 2009; Jefferies et al., 2007). This result therefore pinpoints that brain tumors probably do not compromise semantic storage. Nonetheless, we observed a clear effect of words' imageability during surgery, which confirms a previous study showing difficulties in dealing with abstract concepts in individuals undergoing anterior temporal lobe resection for the treatment of temporal lobe epilepsy (Lambon Ralph et al., 2012). Of equal interest, participants dealt better with words of high semantic accessibility (Nelson et al., 2004), meaning that the words which tend to come to mind in free association to a greater variety of different cues were less easily impacted by the electrical stimulation at the ILF/IFOF intersection level. Semantic accessibility is one of the measures associated with semantic neighborhood (Mirman and Magnuson, 2008), which in our sample was expected to relate with the number of errors that the participants produce in the semantic matching task. Indeed, it was previously observed that semantic neighbors are sensitive to impairments of cognitive control, presumably due to increased difficulty resolving ambiguity and rejecting partially activated distractors (Mirman, 2011). We have predicted such a relationship since participants' lesions at inclusion potentially compromised of at least one of the critical hubs for cognitive control in semantic processing (i.e. inferior frontal regions, the anterior temporal lobe and the middle/superior temporal gyri; Mirman, 2011). We also observed that errors for the items of high difficulty (low imageability and low frequency) occurred significantly more often than for low difficulty (high frequency and imageability) items. In the future, the aforementioned effects may help in creating different levels of task difficulty and semantic accessibility depending on individuals' preoperative performance and the stage of surgery.

Regarding the differences between the semantic tasks used here, an interesting aspect is that the error rate was higher for SPT than for the PPT. One possible explanation for this discrepancy may be due to different levels of complexity between the tasks (2 versus 3 alternative choices) with the SPT task requiring maintaining more items in short term memory than in the PPT task. A similar result was observed in individuals with aphasia, where increasing working memory load significantly reduced accuracy during a synonym judgment task (Martin et al., 2012). Another plausible reason may be that the tasks involved two distinct types of stimuli. Each stimulus in the PPT is composed of black and white line drawings of concrete, everyday life objects. Thus, individuals could perform the task even if they were unable to evoke the name of the objects (using no intermediary lexical access). In contrast, the SPT involves written words that represent concepts varying in their frequency and imageability. Importantly in this sense, the SPT task had to rely on the use of phonological intermediary and semantic-lexical

access (see Indefrey & Levelt, 2004; Dell et al., 2013). Since the SPT task performance required more cognitive operations or short-term memory load, it may have been more easily impaired in presence of a brain lesion. The latter interpretation fits with the hypothesis that semantic access difficulties are related to the disruption of control mechanisms within the semantic system (Jefferies et al., 2007). Moreover, the link between the lowered SPT performance and IFOF disconnection also pinpoints the role of the frontal cortex in semantic selection. Within the framework of the dual stream models for language processing (Hickok & Poeppel, 2007; Saur et al. 2008, Rauschecker and Scott, 2009; Weiller et al., 2011, Kummerer et al., 2013; Brauer et al., 2013; Chang et al., 2015; Skeide & Friederici, 2016; Fujii et al., 2016, Ueno and Lambon Ralph, 2013), our results go in line with previous research in stroke showing that acute impairments in comprehension are associated with temporo-frontal damage (Kummerer et al., 2013). In the same vein, Mirman et al. (2015) recently showed that a semantic recognition factor (semantic judgment and word-to-picture matching tasks) was associated with lesions located in WM pathways medial to the insula and lateral to the basal ganglia. Strikingly, these results pinpointed that the semantic recognition VLSM map was located within the UF, IFOF and thalamic radiations, this area being a "bottleneck" for the connectivity between the frontal lobe and other regions crucial for speech processing.

Importantly, our results reappraise those from Almairac and collaborators (2012). We have initially questioned the role of the IFOF in semantic processing, being this tract not directly connected to the ATL. In light of our results, we suggest that WM connections projecting to the frontal lobe may be equally important to perform semantic tasks, indicating that the semantic difficulties observed in individuals with brain tumor might be associated with semantic control or selection deficiency rather than with semantic storage deterioration (see Jefferies et al., 2007).

Our intraoperative results may be also interpreted in light of the comprehensive computational model of access to the semantic system (Gotts and Plaut, 2002). These authors claimed that albeit the degradation of semantic representations (1) could be due to damage involving cortical neurons within the semantic system (information encoding), the access type impairment (2) could be related to a lack of correct neuromodulation within WM systems. This neuromodulation is normally implicated in an efficient regulation of normal refractory processes within the cortical semantic network. The adequacy of this model for our data interpretation is further strengthened when considering the particularity of the ESM approach. Gotts and Plaut (2002) based their rationale on biological phenomena of synaptic depression – typical reduction in the activity of synapses after repetitive firing – and hypothesized that brain insults (e.g. stroke) may cause abnormal levels of this synaptic depression. Thus, if the damage occurs within the temporal lobes, it may lead to a neuromodulatory breakdown and a reversible disruption of the semantic system. Moreover, in the context of the electrical stimulation at the white matter level, it has been hypothesized that transient inhibition of axonal conduction may explain the temporary disruption of brain function induced by the CUSA (Carrabba et al., 2008). Thus, the electrical stimulation generated by CUSA action may cause similar abnormal levels of synaptic depression and, in consequence, result in a reduction of correct functioning of the semantic system. Interestingly, according to this model, these impairments should be reversible. Therefore, the post-surgical follow-up of the individuals composing our sample will be of utmost importance.

#### 4.3. Limitations

Several limitations to the current research deserve to be mentioned. First, intraoperatively, we could not monitor selectively WM fibers belonging either to the IFOF or to the ILF. These two tracts are in an in-

timate contact in their traverse within the temporal lobe, and the current methodology did not enable us sufficient precision. Second, despite the fact that track-wise analysis provided a complementary data-driven approach that strikingly converged with the VLSM and ESM data, results of this analysis on the IFOF must be cautiously interpreted. Indeed, Tractotron calculates the impact of a lesion on the WM matter circuitry assuming its normal distribution. However, brain tumors can easily displace or infiltrate WM fibers (Lazar et al., 2006) and thus, the software may indicate a disruption even if the tract is preserved. It is also important to bear in mind that Tractotron could generate the same score of a lesion impact regardless of the manner and direction in which the lesion intersects the tract. The third shortcoming is associated with a relatively liberal level of presenting the statistical results (Spearman correlations at the level of  $P = .05$  uncorrected). However, given that the results from three different methodologies converged (intraoperative electrical stimulations, the comparison between lesion distribution between participants with normal and pathological scores and track-wise lesion analyses) in showing relationships between semantic processing and the left middle and inferior temporal areas, we considered presenting our results even with moderate statistical strength. The fourth limitation may be related to the fact that the ventral streams for language processing are bilateral (Forkel et al., 2014; Egger et al., 2015 for the IFOF and ILF) and that traditionally the left-lateralized tracts were associated with language processing (e.g. AF, Catani, 2007 or frontal aslant tract, Catani et al., 2012). However, we assume that, although structurally the ventral pathways for language are bilaterally distributed, their function for semantic processing may still be left-lateralized. In this sense, Sanjuán et al. (2015) reported left-lateralized functional activations related to object naming and semantic matching. In addition, a vast meta-analysis of semantic processing-related tasks revealed the implication of temporal and frontal lobes, similarly within the left hemisphere (Bajada et al., 2016). In the same vein, Lambon-Ralph and colleagues (2012) observed that semantic processing was abnormal and inefficient in individuals with unilateral temporal lobe resection for the treatment of epilepsy. Finally, a variety of plastic and compensatory mechanisms induced by different types of lesions (low-grade tumors, which are growing slowly as opposed to the rapidly growing high-grade tumors) may have substantially changed the neural representation of language functions (Bi et al., 2011; Herbet et al., 2016; Francois et al., 2016; for a review see Kong et al., 2016; Desmurget et al., 2007; Lambon Ralph et al., 2012). Future work is needed to better understand the specific neuropathological mechanisms underlying the spectrum of language disorders observed in individuals with brain tumors.

## 5. Conclusions

In this study, we support the relationship between the left ventral white matter language-related pathways and semantic processing by showing that the electrical stimulation at the level of IFOF/ILF disrupted semantic processing during object naming and/or semantic matching tasks in 16 individuals undergoing awake brain surgery. Additionally, track-wise analyses of semantic processing supported the intraoperative findings, showing, that the level of performance on the SPT task was significantly higher in participants who preserved IFOF integrity than in those who did not. Importantly, lesion volume positively correlated with the number of intraoperative semantic paraphasias produced during tumor resection. We propose the use of the SPT task in surgical interventions for intrinsic lesions compromising the integrity of the ventral pathways for language processing.

## Uncited references

Almairac et al., 2015

Ius et al., 2011  
 Louis et al., 2007  
 McRae et al., 2005  
 Thiebaut de Schotten et al., 2011

## Acknowledgments

The authors would like to thank the individuals from the present study group for their willingness to participate in the study, Dr. Vitória Piai and Dr. Pablo Ripollés for their very constructive methodological and theoretical remarks, Dr. Michel Thiebaut de Schotten and Chris Foulon for their help and advice regarding Tractotron analyses and Anael Prados for her help in testing control sample with the SPT task.

## Funding

This project was supported by a Catalan Government award (SGR 2014 SGR1413), Spanish Government grant (Ministerio de Economía y Competitividad, PSI2015-69178-P, MINECO/FEDER) to ARF and the Spanish Government Predoctoral Grant for the University Lecturers Training (FPU, 12/04117) awarded to JS. CF was supported by a SLT002/16/00390 grant, funded by the Department of Health of the Generalitat de Catalunya by the call “Acció instrumental d’incorporació de científics i tecnòlegs”.

## Disclosure

The authors declare no conflict of interest concerning the materials and methods used in this study or the findings specified in this paper.

## Appendix A. Supplementary data

Supplementary data to this article can be found online at <https://doi.org/10.1016/j.nicl.2019.101704>.

## References

- Adlam, A.-L.R., Patterson, K., Rogers, T.T., Nestor, P.J., Salmon, C.H., Acosta-Cabrero, J., et al., 2006. Semantic dementia and fluent primary progressive aphasia: two sides of the same coin?. *Brain J. Neurol.* 129 (Pt 11), 3066–3080.
- Allport, D.A., 1985. Distributed memory, modular subsystems and dysphasia. In: Newman, S.K., Epstein, R. (Eds.), *Current Perspectives in Dysphasia*. Churchill Livingstone, Edinburgh, pp. 32–60.
- Almairac, F., Herbet, G., Moritz-Gasser, S., de Champfleury, N.M., Duffau, H., 2015. The left inferior fronto-occipital fasciculus subserves language semantics: a multilevel lesion study. *Brain Struct. Funct.* 220 (4), 1983–1995.
- Andersen, S.M., Rapcsak, S.Z., Beeson, P.M., 2010. Cost function masking during normalization of brains with focal lesions: still a necessity?. *NeuroImage* 53 (1), 78–84.
- Anderson, S.W., Damasio, H., Tranel, D., 1990. Neuropsychological impairments associated with lesions caused by tumor or stroke. *Arch. Neurol.* 47 (4), 397–405.
- Aranciva, F., Casals-Coll, M., Sanchez-Benavides, G., Quintana, M., Manero, R.M., Rognoni, T., ... Pena-Casanova, J., 2012. Spanish normative studies in a young adult population (NEURONORMA young adults Project): norms for the Boston Naming Test and the Token Test. *Neurologia (Barcelona, Spain)* 27 (7), 394–399.
- Aron, A.R., Robbins, T.W., Poldrack, R.A., 2004. Inhibition and the right inferior frontal cortex. *Trends Cognit. Sci.* 8, 170–177.
- Bajada, C.J., Haroon, H.A., Azadbakht, H., Parker, G.J.M., Lambon Ralph, M.A., Cloutman, L.L., 2016. The tract terminations in the temporal lobe: their location and associated functions. *Cortex* <https://doi.org/10.1016/j.cortex.2016.03.013>.
- Baldo, J.V., Arevalo, A., Patterson, J.P., Dronkers, N.F., 2013. Grey and white matter correlates of picture naming: evidence from a voxel-based lesion analysis of the Boston naming test. *Cortex* 49 (3), 658–667.
- Banich, M.T., 2009. Executive function: the search for an integrated account. *Curr. Dir. Psychol. Sci.* 18, 89–94.
- Bates, E., Wilson, S.M., Saygin, A.P., Dick, F., Sereno, M.I., Knight, R.T., et al., 2003. Voxel-based lesion-symptom mapping. *Nat. Neurosci.* 6 (5), 448–450.
- Bi, Y., Wei, T., Wu, C., Han, Z., Jiang, T., Caramazza, A., 2011. The role of the left anterior temporal lobe in language processing revisited: evidence from an individual with ATL resection. *Cortex* 47 (5), 575–587.
- Binder, J.R., Desai, R.H., Graves, W.W., Conant, L.L., 2009. Where is the semantic system? A critical review and meta-analysis of 120 functional neuroimaging studies. *Cereb Cortex* 19 (12), 2767–2796, N Y N 1991.

- Brauer, J., Anwender, A., Perani, D., Friederici, A.D., 2013. Dorsal and ventral pathways in language development. *Brain Lang.* 27 (2), 289–295.
- Brett, M., Leff, A.P., Rorden, C., Ashburner, J., 2001. Spatial normalization of brain images with focal lesions using cost function masking. *NeuroImage* 14 (2), 486–500.
- Buchsbaum, B.R., Greer, S., Chang, W.-L., Berman, K.F., 2005. Meta-analysis of neuroimaging studies of the Wisconsin card-sorting task and component processes. *Hum. Brain Mapp.* 25 (1), 35–45.
- Buckner, R.L., Sepulcre, J., Talukdar, T., Krienen, F.M., Liu, H., Hedden, T., et al., 2009. Cortical hubs revealed by intrinsic functional connectivity: mapping, assessment of stability, and relation to Alzheimer's disease. *J. Neurosci.* 29 (6), 1860–1873.
- Campanella, F., Mondani, M., Skrap, M., Shallice, T., 2009. Semantic access dysphasia resulting from left temporal lobe tumours. *Brain* 132 (Pt 1), 87–102.
- Carrabba, G., Mandonnet, E., Fava, E., Capelle, L., Gaini, S.M., Duffau, H., Bello, L., 2008. Transient inhibition of motor function induced by the cavitrion ultrasonic surgical aspirator during brain mapping. *Neurosurgery* 63 (1), E178–E179.
- Casals-Coll, M., Sanchez-Benavides, G., Quintana, M., Manero, R.M., Rognoni, T., Calvo, L., ... Pena-Casanova, J., 2013. Spanish normative studies in young adults (NEURO-NORMA young adults project): norms for verbal fluency tests. *Neurologia (Barcelona, Spain)* 28 (1), 33–40.
- Catani, M., Mesulam, M.M., Jakobsen, E., Malik, F., Martersteck, A., Wieneke, C., ... Rogalski, E., 2013. A novel frontal pathway underlies verbal fluency in primary progressive aphasia. *Brain: A J. Neurol.* 136 (Pt 8), 2619–2628.
- Catani, M., Thiebaut de Schotten, M., 2008. A diffusion tensor imaging tractography atlas for virtual in vivo dissections. *Cortex* 44 (8), 1105–1132.
- Chang, E.F., Raygor, K.P., Berger, M.S., 2015. Contemporary model of language organization: an overview for neurosurgeons. *J. Neurosurg.* 122 (2), 250–261.
- Chikazoe, J., 2010. Localizing performance of go/no-go tasks to prefrontal cortical subregions. *Curr. Opin. Psychiatry* 23 (3), 267–272.
- Cloutman, L., Gottesman, R., Chaudhry, P., Davis, C., Kleinman, J.T., Pawlak, M., et al., 2009. Where (in the brain) do semantic errors come from? *Cortex* 45 (5), 641–649.
- Davis, C.J., Perea, M., 2005. BuscaPalabras: a program for deriving orthographic and phonological neighborhood statistics and other psycholinguistic indices in Spanish. *Behav. Res. Methods* 37 (4), 665–671.
- De Renzi, E., Faglioni, P., 1978. Normative data and screening power of a shortened version of the Token Test. *Cortex* 14 (1), 41–49.
- Dell, G.S., Schwartz, M.F., Nozari, N., Faseyitan, O., Branch, Coslett H., 2013. Voxel-based lesion-parameter mapping: identifying the neural correlates of a computational model of word production. *Cognition* 128 (3), 380–396.
- Desmurget, M., Bonnetblanc, F., Duffau, H., 2007. Contrasting acute and slow-growing lesions: a new door to brain plasticity. *Brain* 130 (Pt 4), 898–914.
- Dick, A.S., Tremblay, P., 2012. Beyond the arcuate fasciculus: consensus and controversy in the connective anatomy of language. *Brain* 135 (Pt 12), 3529–3550.
- Duffau, H., Gatignol, P., Mandonnet, E., Peruzzi, P., Tzourio-Mazoyer, N., Capelle, L., 2005. New insights into the anatomo-functional connectivity of the semantic system: a study using cortico-subcortical electrostimulations. *Brain* 128 (Pt 4), 797–810.
- Forkel, S.J., Thiebaut de Schotten, M., Kawadler, J.M., Dell'Acqua, F., Danek, A., Catani, M., 2014. The anatomy of fronto-occipital connections from early blunt dissections to contemporary tractography. *Cortex* 56, 73–84.
- Francois, C., Ripolles, P., Bosch, L., Garcia-Alix, A., Muchart, J., Sierpowska, J., et al., 2016. Language learning and brain reorganization in a 3.5-year-old child with left perinatal stroke revealed using structural and functional connectivity. *Cortex* 77, 95–118.
- Fujii, M., Maesawa, S., Ishiai, S., Iwami, K., Futamura, M., Saito, K., 2016. Neural basis of language: an overview of an evolving model. *Neurol. Med. Chir. (Tokyo)* 56 (7), 379–386.
- Goodglass, H., Kaplan, E., 2001. *Boston Naming Test*. Lippincott Williams & Wilkins.
- Gotts, S.J., Plaut, D.C., 2002. The impact of synaptic depression following brain damage: a connectionist account of “access/refractory” and “degraded-store” semantic impairments. *Cogn. Affect. Behav. Neurosci.* 2 (3), 187–213.
- Gudayol-Ferre, E., Lara, J.P., Herrera-Guzman, I., Bohm, P., Rodes, E., Ansaldo, A.I., Pena-Casanova, J., 2008. Semantic memory as assessed by the Pyramids and Palm trees test: the impact of sociodemographic factors in a Spanish-speaking population. *J. Int. Neuropsychol. Soc.: JINS* 14 (1), 148–151.
- Hickok, G., Poeppel, D., 2007. The cortical organization of speech processing. *Nat. Rev. Neurosci.* 8 (5), 393–402.
- Howard, D., Patterson, K., 1992. *The Pyramids and Palm Trees Test. A Test of Semantic Access from Words and Pictures*, Bury St. Edmunds, UK: Thames Valley: Bury St. Edmunds.
- Ius, T., Angelini, E., Thiebaut de Schotten, M., Mandonnet, E., Duffau, H., 2011. Evidence for potentials and limitations of brain plasticity using an atlas of functional resectability of WHO grade II gliomas: towards a “minimal common brain”. *NeuroImage* 56 (3), 992–1000.
- Jefferies, E., Baker, S.S., Doran, M., Ralph, M.A.L., 2007. Refractory effects in stroke aphasia: a consequence of poor semantic control. *Neuropsychologia* 45 (5), 1065–1079.
- Jefferies, E., Patterson, K., Jones, R.W., Lambon Ralph, M.A., 2009. Comprehension of concrete and abstract words in semantic dementia. *Neuropsychologia* 4, 492–499.
- Jurado, M.B., Rosselli, M., 2007. The elusive nature of executive functions: a review of our current understanding. *Neuropsychol. Rev.* 17 (3), 213–233.
- Kong, N.W., Gibb, W.R., Tate, M.C., 2016. Neuroplasticity: insights from patients Harboring Gliomas. *Neural Plast.* 2016, 2365063.
- Kummerer, D., Hartwigsen, G., Kellmeyer, P., Glauche, V., Mader, I., Kloppel, S., et al., 2013. Damage to ventral and dorsal language pathways in acute aphasia. *Brain* 136 (Pt 2), 619–629.
- Lambon Ralph, M.A., Ehsan, S., Baker, G.A., Rogers, T.T., 2012. Semantic memory is impaired in patients with unilateral anterior temporal lobe resection for temporal lobe epilepsy. *Brain* 135 (Pt 1), 242–258.
- Lazar, M., Alexander, A.L., Thottakara, P.J., Badie, B., Field, A.S., 2006. White matter reorganization after surgical resection of brain tumors and vascular malformations. *AJNR Am. J. Neuroradiol.* 27 (6), 1258–1271.
- Louis, D.N., Ohgaki, H., Wiestler, O.D., Cavenee, W.K., Burger, P.C., Jouvet, A., et al., 2007. The 2007 WHO classification of tumours of the central nervous system. *Acta Neuropathol. (Berl.)* 114 (2), 97–109.
- Louis, D.N., Perry, A., Reifenberger, G., von Deimling, A., Figarella-Branger, D., Cavenee, W.K., et al., 2016. The 2016 World Health Organization classification of tumors of the central nervous system: a summary. *Acta Neuropathol. (Berl.)* 131 (6), 803–820.
- Martin, N., Kohen, F., Kalinyak-Fliszar, M., Soveri, A., Laine, M., 2012. Effects of working memory load on processing of sounds and meanings of words in aphasia. *Aphasiology* 26 (3–4), 462–493.
- McRae, K., Cree, G.S., Seidenberg, M.S., McNorgan, C., 2005. Semantic feature production norms for a large set of living and nonliving things. *Behav. Res. Methods* 37 (4), 547–559.
- Mestres-Misse, A., Rodriguez-Fornells, A., Munte, T.F., 2010. Neural differences in the mapping of verb and noun concepts onto novel words. *NeuroImage* 49 (3), 2826–2835.
- Mirman, D., 2011. Effects of near and distant semantic neighbors on word production. *Cogn. Affect. Behav. Neurosci.* 11 (1), 32–43.
- Mirman, D., Chen, Q., Zhang, Y., Wang, Z., Faseyitan, O.K., Coslett, H.B., et al., 2015. Neural organization of spoken language revealed by lesion-symptom mapping. *Nat. Commun.* 6, 6762.
- Mirman, D., Landrigan, J.-F., Kokolis, S., Verillo, S., Ferrara, C., Pustina, D., 2018. Corrections for multiple comparisons in voxel-based lesion-symptom mapping. *Neuropsychologia* 115, 112–123.
- Nelson, D.L., McEvoy, C.L., Schreiber, T.A., 2004. The University of South Florida free association, rhyme, and word fragment norms. *Behav. Res. Methods Instrum. Comput. J. Psychon. Soc.* 36 (3), 402–407.
- Noonan, K.A., Jefferies, E., Garrard, P., Eshan, S., Lambon Ralph, M.A., 2013. Demonstrating the qualitative differences between semantic aphasia and semantic dementia: a novel exploration of nonverbal semantic processing. *Behav. Neurol.* 26 (1–2), 7–20.
- Oldfield, R.C., 1971. The assessment and analysis of handedness: the Edinburgh inventory. *Neuropsychologia* 9, 97–113.
- Patterson, K., 2007. The reign of typicality in semantic memory. *Philos. Trans. R. Soc. Lond. Ser. B Biol. Sci.* 362 (1481), 813–821.
- Peña-Casanova, J., 2005. *Integrated Neuropsychological Exploration Program Barcelona Test Revised*. Masson, Barcelona.
- Pena-Casanova, J., Quinones-Ubeda, S., Gramunt-Fombuena, N., Aguilar, M., Casas, L., Molinuevo, J.L., ... Blesa, R., 2009. Spanish Multicenter Normative Studies (NEURO-NORMA Project): norms for Boston naming test and token test. *Arch. Clin. Neuropsychol. Off. J. Natl. Acad. Neuropsychol.* 24 (4), 343–354.
- Pena-Casanova, J., Quinones-Ubeda, S., Gramunt-Fombuena, N., Quintana-Aparicio, M., Aguilar, M., Badenes, D., ... Blesa, R., 2009. Spanish Multicenter Normative Studies (NEURO-NORMA Project): norms for verbal fluency tests. *Arch. Clin. Neuropsychol. Off. J. Natl. Acad. Neuropsychol.* 24 (4), 395–411.
- Rauschecker, J.P., Scott, S.K., 2009. Maps and streams in the auditory cortex: nonhuman primates illuminate human speech processing. *Nat. Neurosci.* 12 (6), 718–724.
- Ripolles, P., Biel, D., Penaloza, C., Kaufmann, J., Marco-Pallares, J., Noesselt, T., Rodriguez-Fornells, A., 2017. Strength of temporal white matter pathways predicts semantic learning. *J. Neurosci. Off. J. Soc. Neurosci.* 37 (46), 11101–11113.
- Ripolles, P., Marco-Pallares, J., de Diego-Balaguer, R., Miro, J., Falip, M., Juncadella, M., ... Rodriguez-Fornells, A., 2012. Analysis of automated methods for spatial normalization of lesioned brains. *NeuroImage* 60 (2), 1296–1306.
- Ripolles, P., Marco-Pallares, J., Hielscher, U., Mestres-Misse, A., Tempelmann, C., Heinze, H.-J., et al., 2014. The role of reward in word learning and its implications for language acquisition. *Curr. Biol.* 24 (21), 2606–2611.
- Robinson, G., Shallice, T., Bozzali, M., Cipolletti, L., 2012. The differing roles of the frontal cortex in fluency tests. *Brain J. Neurol.* 135 (Pt 7), 2202–2214.
- Rodriguez-Fornells, A., Cunillera, T., Mestres-Misse, A., de Diego-Balaguer, R., 2009. Neurophysiological mechanisms involved in language learning in adults. *Philos. Trans. R. Soc. Lond. Ser. B Biol. Sci.* 364 (1536), 3711–3735.
- Rofes, A., Spena, G., Talacchi, A., Santini, B., Miozzo, A., Miceli, G., 2017. Mapping nouns and finite verbs in left hemisphere tumors: a direct electrical stimulation study. *Neurocase* 1–9.
- Rogers, T.T., Lambon Ralph, M.A., Garrard, P., Bozeat, S., McClelland, J.L., Hodges, J.R., et al., 2004. Structure and deterioration of semantic memory: a neuropsychological and computational investigation. *Psychol. Rev.* 111 (1), 205–235.
- Rorden, C., Brett, M., 2000. Stereotaxic display of brain lesions. *Behav. Neurol.* 12 (4), 191–200.
- Sanjuan, A., Hope, T.M.H., Jones, O'ivi Parker, Prejawa, S., Oberhuber, M., Guerin, J., et al., 2015. Dissociating the semantic function of two neighbouring subregions in the left lateral anterior temporal lobe. *Neuropsychologia* 76, 153–162.
- Saur, D., Kreher, B.W., Schnell, S., Kümmerer, D., Kellmeyer, P., Vry, M.-S., et al., 2008. Ventral and dorsal pathways for language. *Proc. Natl. Acad. Sci. U. S. A.* 105 (46), 18035–18040, 18.
- Schnur, T.T., Schwartz, M.F., Kimberg, D.Y., Hirshorn, E., Coslett, H.B., Thompson-Schill, S.L., 2009. Localizing interference during naming: convergent neuroimaging and neuropsychological evidence for the function of Broca's area. *Proc. Natl. Acad. Sci. U. S. A.* 106 (1), 322–327.



- Schwartz, M.F., Kimberg, D.Y., Walker, G.M., Faseyitan, O., Brecher, A., Dell, G.S., et al., 2009. Anterior temporal involvement in semantic word retrieval: voxel-based lesion-symptom mapping evidence from aphasia. *Brain* 132 (Pt 12), 3411–3427.
- Sierpowska, J., Gabarros, A., Fernandez-Coello, A., Camins, A., Castaner, S., Juncadella, M., et al., 2015. Morphological derivation overflow as a result of disruption of the left frontal aslant white matter tract. *Brain Lang.* 142, 54–64.
- Sierpowska, J., Gabarros, A., Fernandez-Coello, A., Camins, A., Castaner, S., Juncadella, M., et al., 2016. Words are not enough: nonword repetition as an indicator of arcuate fasciculus integrity during brain tumor resection. *J. Neurosurg.* 1–11.
- Thiebaut de Schotten, M., Dell'Acqua, F., Ratiu, P., Leslie, A., Howells, H., Cabanis, E., et al., 2015. From Phineas Gage and Monsieur Leborgne to H.M.: revisiting disconnection syndromes. *Cereb. Cortex* 25 (12), 4812–4827, N Y N 1991.
- Thiebaut de Schotten, M., Ffytche, D.H., Bizzi, A., Dell'Acqua, F., Allin, M., Walshe, M., et al., 2011. Atlas location, asymmetry and inter-subject variability of white matter tracts in the human brain with MR diffusion tractography. *NeuroImage* 54 (1), 49–59.
- Thiebaut de Schotten, M., Tomaiuolo, F., Aiello, M., Merola, S., Silveti, M., Lecce, F., et al., 2014. Damage to white matter pathways in subacute and chronic spatial neglect: a group study and 2 single-case studies with complete virtual “in vivo” tractography dissection. *Cereb Cortex* 24 (3), 691–706, N Y N 1991.
- Thompson-Schill, S.L., D'Esposito, M., Aguirre, G.K., Farah, M.J., 1997. Role of left inferior prefrontal cortex in retrieval of semantic knowledge: a reevaluation. *Proc. Natl. Acad. Sci. U. S. A.* 94 (26), 14792–14797.
- Ueno, T., Lambon Ralph, M.A., 2013. The roles of the “ventral” semantic and “dorsal” pathways in conduite d'approche: a neuroanatomically-constrained computational modeling investigation. *Front. Hum. Neurosci.* 7, 422.
- Vigneau, M., Beaucois, V., Herve, P.Y., Duffau, H., Crivello, F., Houde, O., et al., 2006. Meta-analyzing left hemisphere language areas: phonology, semantics, and sentence processing. *NeuroImage* 30 (4), 1414–1432.
- Warrington, E.K., Shallice, T., 1979. Semantic access dyslexia. *Brain J. Neurol.* 102 (1), 43–63.
- Wechsler, D., 2004. Adaptación al castellano de la escala de memoria de Wechsler-III. TEA Ediciones, Madrid.
- Wechsler, D., Psychological Corporation, 1997. WAIS-III: Wechsler Adult Intelligence Scale. San Antonio, Tex, Psychological Corp.
- Weiller, C., Bormann, T., Saur, D., Musso, M., Rijntjes, M., 2011. How the ventral pathway got lost: and what its recovery might mean. *Brain Lang.* 118 (1–2), 29–39.