



HAL
open science

The prospects for application of computational anatomy in forensic anthropology for sex determination

Angélique Franchi, Sébastien Valette, Rémi Agier, Rémy Prost, Razmig
Kéchichan, Laurent Fanton

► To cite this version:

Angélique Franchi, Sébastien Valette, Rémi Agier, Rémy Prost, Razmig Kéchichan, et al.. The prospects for application of computational anatomy in forensic anthropology for sex determination. Forensic Science International, 2019, 297, pp.156-160. 10.1016/j.forsciint.2019.01.009 . hal-02047728

HAL Id: hal-02047728

<https://hal.science/hal-02047728>

Submitted on 22 Oct 2021

HAL is a multi-disciplinary open access archive for the deposit and dissemination of scientific research documents, whether they are published or not. The documents may come from teaching and research institutions in France or abroad, or from public or private research centers.

L'archive ouverte pluridisciplinaire **HAL**, est destinée au dépôt et à la diffusion de documents scientifiques de niveau recherche, publiés ou non, émanant des établissements d'enseignement et de recherche français ou étrangers, des laboratoires publics ou privés.



Distributed under a Creative Commons Attribution - NonCommercial 4.0 International License

Title page

Technical note: the prospects for application of computational anatomy in forensic anthropology for sex determination

Franchi Angélique^{1,2}, Valette Sébastien³, Agier Rémi³, Prost Rémy³, Kéchichan Razmig³, Fanton Laurent^{1,2,3}

¹ Forensic Medicine Department, University Hospital of Lyon (France)

² University of Lyon, UCBL1, faculty of medicine, Lyon (France)

³ Research laboratory of medical imagery CREATIS, Villeurbanne (France)

Corresponding author: Doctor Angélique Franchi

Service de Médecine Légale, Unité-Médico-Judiciaire, Pavillon F

Hôpital Edouard Herriot, 5 place d'Arsonval 69003 LYON, FRANCE

Phone: +0033427858028

Fax: +0033427858025

Email: angelique.franchi@hotmail.fr or angelique.franchi@chu-lyon.fr

Abstract

The purpose of this study is to assess the relevance of computational anatomy for the sex determination in forensic anthropology. A novel groupwise registration algorithm is used, based on keypoint extraction, able to register several hundred full body images in a common space. Experiments were conducted on 83 CT scanners of living individuals from the public VISCERAL database. In our experiments, we first verified that the well-known criteria for sex discrimination on the hip-bone were well preserved in mean images. In a second experiment, we have tested semi-automatic positioning of anatomical landmarks to measure the relevance of groupwise registration for future research. We applied the Probabilistic Sex Diagnosis tool on the predicted landmarks. This resulted in 62% of correct sex determinations, 37% of undetermined cases, and 1% of errors. The main limiting factors are the population sample size and the lack of precision for the initial manual positioning of the landmarks in the mean image. We also give insights on future works for robust and fully automatic sex determination.

Keywords

Forensic science, forensic anthropology, sex determination, computational anatomy, groupwise registration, probabilistic sex diagnosis method

Introduction

Forensic anthropology is the application of the science of physical anthropology to the legal process using standard scientific techniques developed to identify human remains and to assist in the detection of crime. The practice of forensic anthropology is increasingly focused on developing theories and methods that will be effective during expert testimony. The ever-increasing amount of medical images, stored in a picture archiving and communication system (PACS) in hospitals, offers a great opportunity for analysis of large data sets, which could be analyzed to extract knowledge on human anatomy. Recent advances in machine learning [1] or atlas based-approaches [2] have pushed for efficient big data analysis tools. We are interested in computational anatomy [3], an emerging research field, which aims to help forensic scientists in their daily practice by analyzing many individuals. To our knowledge, the use of computational anatomy for forensic anthropology is still an open challenge [4]. The purpose of this study is to investigate the prospects of the application of computational anatomy for sex determination on the pelvis bone. This can be carried out via morphological and metrical analysis by testing the positioning of the landmarks of the Probabilistic Sex Diagnosis (DSP) method [5] on a 3D reconstructed pelvis bone obtained with groupwise registration.

Material and method

Medical imaging, such as computed tomography (CT), provides the opportunity for in situ three-dimensional (3D) imaging of the skeleton of known individuals. We use a deformable registration algorithm [6], based on keypoint extraction, able to register several hundred full body images in a common space. The algorithm proceeds in three steps: 3D SURF interest point extraction from input images [7], descriptor-based keypoint pairing, and half-transform optimization by minimizing the distance between paired points while aiming at discarding outlier influence. Note that once the interest points are extracted, the image voxels are no longer necessary, and can be discarded. This has the side-effect of reducing memory and computation requirements. This algorithm is fully automatic, robust to anatomical variability, and can register a group of one hundred images within a few hours. Experiments have been conducted on the Visual Concept Extraction Challenge in RadioLogy (VISCERAL) database [8] of living individuals suffering that visceral pathologies. This challenge focused on comparing segmentation and anatomical landmark positioning. The CT scans are shared by the Medical University of Heidelberg (Germany), with the approval from the local ethics board [9]. Collected CT

scans were only of patients older than 18 years that signed an informed consent to agree with the use of their images for the VISCERAL project. Registration has been carried out on 20 full-body CT scans [FIG. 1a] and 83 CT C.A.P. (Chest, Abdomen and Pelvis) [FIG. 1b]. These images have been obtained by extracting the bones of each individual, and by transforming all the bones in the common space using the registration transforms. Registration in Figure 1.a is accurate except for the arms, as arm postures differ a lot between individuals. Figure 1.b shows the hip bone region. In a similar manner, the average image [FIG. 2] is obtained by transforming each patient image in the common space using its respective registration transform, and by averaging all the transformed images. With this registration framework, we have conducted two main experiments. In a first step, two tests were carried out: a separate registration of male and female groups and a registration group of males and females together, for qualitative comparison purpose. In a second step, we have used semi-automatic anatomical landmark positioning and the DSP tool to test automatic determination of sex for each individual. This tool is based on a worldwide hip-bone metrical database of 2040 adult specimens of known sex, from 12 different reference populations, with 95% accuracy [5], and the implementation is freely available on the internet. This method requires 10 measurements from 18 anatomical landmarks using anthropology tools.

Results

The first results focus on the morphological analysis on the pelvis bone, which is one of the most distinct regions between men and women. The aim is to show if the well-known criteria for sex determination are preserved on the 3D reconstruction of the average image. Experiments show that the well-known criteria for sex discrimination (e.g. the opening angle of pubic symphysis or the greater sciatic notch) are well preserved in the mean pelvis of men and women when they are registered separately [FIG.3a]. On the other hand, one can still see differences between men and women when they are registered together [FIG.3b]. This difference, although much smaller than for the differentiated case, reflects the remaining variability between men and women which has not been captured by the registration algorithm.

The second results focus on the metrical analysis, by a test of the DSP tool which is based on worldwide variability in hip-bone measurements with a success rate close to 100%. Instead of separately computing one average image for men and one for women, we computed the average image of all individuals regardless of their sex. The 18 needed anatomical landmarks were placed manually on the 3D reconstruction of the pelvis bone obtained from the mean image [FIG.4]. Landmark positioning was facilitated by inspecting a reduced model of

the average pelvis obtained with a 3D printer [FIG. 5]. Afterwards, the 18 anatomical landmarks have been automatically positioned for each individual by applying the respective inverse registration transform on the 18 manually placed landmarks. The entire workflow for this experiment is summarized in [FIG. 6] to clarify the procedure. Hence, using groupwise registration avoid the need to place anatomical landmarks for all 83 individuals. Using the freely available implementation of DSP on the internet published by the authors [10], we predicted the sex of each individual, by measuring 10 reference distances between the predicted landmarks. Manual positioning of the anatomical landmarks on the average pelvis has been carried out twice by the same physician, to measure intra-observer error. This resulted in 62% of individuals with correct assessments, 37% of undetermined cases (i.e. the DSP implementation indicated that landmark positions were not discriminative enough) and 1% of errors. The second manual positioning by the physician led to the same results. Note that the case of wrong sex determination (the 1% of error) is obtained for an image where the bottom part of the pelvis is missing.

Discussion

Groupwise registration allows the use of the field of computational anatomy to assist forensic practitioners in their daily practice. Establishing the biological profile of an individual is a crucial topic in forensic anthropology. Frequently, when bones or body parts are found, it is obvious to forensic practitioners whether they are human or not [11]. But the determination of a biological profile requires appropriate training in forensic anthropology, in particular, in the case of bone fragments. The crucial matter, when a forensic practitioner is confronted with bones of human skeleton, is the search for criteria of sex determination. Our preliminary results show promising results for the use of computational anatomy for sex determination. According to the literature, the most predictably dimorphic bones in the human body are those of the bony pelvis, which become distinctive during the adolescent growth spurt [12]. Researchers have developed methods for estimating sex through measurements and observations of morphological variations, such as the shape of the pubic bone and the presence of a ventral arc [13]. Our morphological tests on the pelvis bone showed a good preservation of sex determination criteria in the 3D reconstruction of the mean image obtained by groupwise registration. It was very important to know if the registration kept these well-known criteria to continue our research. However, our results can still see differences between men and women when they are registered together. This reflects the remaining variability between men and women which has not been captured by the registration algorithm. This can be explained by a

limiting factor: population sample size. Among the different computerized methods to determine sex in forensic anthropology frequently used in France, we have focused on the DSP method [5] which requires bone extraction and preparation prior measurements. We have placed manually the 18 landmarks on the 3D reconstruction of a mean hip bone and tested automatic transfer of the landmarks on each individual. Using the groupwise registration, our results showed in the two tests by the same physician 1% of error. It was a generally correct estimation of sex close to 62%, but the level of confidence can still be improved (37% of undetermined cases). The main difficulty to apply the DSP method to registration is a lack of precision in placing the landmarks manually in the common space on the 3D reconstruction of the mean image. However, this test is promising, because the application of a scientifically validated method is possible on 3D reconstruction of the mean image obtained by registration. But using the DSP method in conjunction with groupwise registration is not ideal, as it takes into account a relatively low number of anatomical landmarks per patient (eighteen). Further works will focus on taking a much larger number of measures for each individual, and to include a larger population in the study, to increase robustness and accuracy. Our aim is to access the database of Lyon's hospitals (PACS) to study larger sets of images. Note that the used groupwise registration approach relies only on keypoints, which do not disclose patient appearance, which guarantees anonymous data. This can give promising opportunities for the creation of a public anatomical database. In conclusion, sex determination by computational anatomy is a promising means to automatically extract anthropological information.

Figures

FIG.1a – Registration on 20 full-body CT scans. Bones have been extracted from each scan, and transformed into the common space.

FIG.1b – Registration on 83 CT C.A.P. (hip bone). Bones have been extracted from each scan, and transformed into the common space.

FIG.2 – Average image from the registration of the 83 CT scanners.

FIG.3a – Mean pelvis image and reconstructed bones of women (top) and men (bottom) registered separately.

FIG.3b – Mean pelvis image and reconstructed bones of women (top) and men (bottom) registered together.

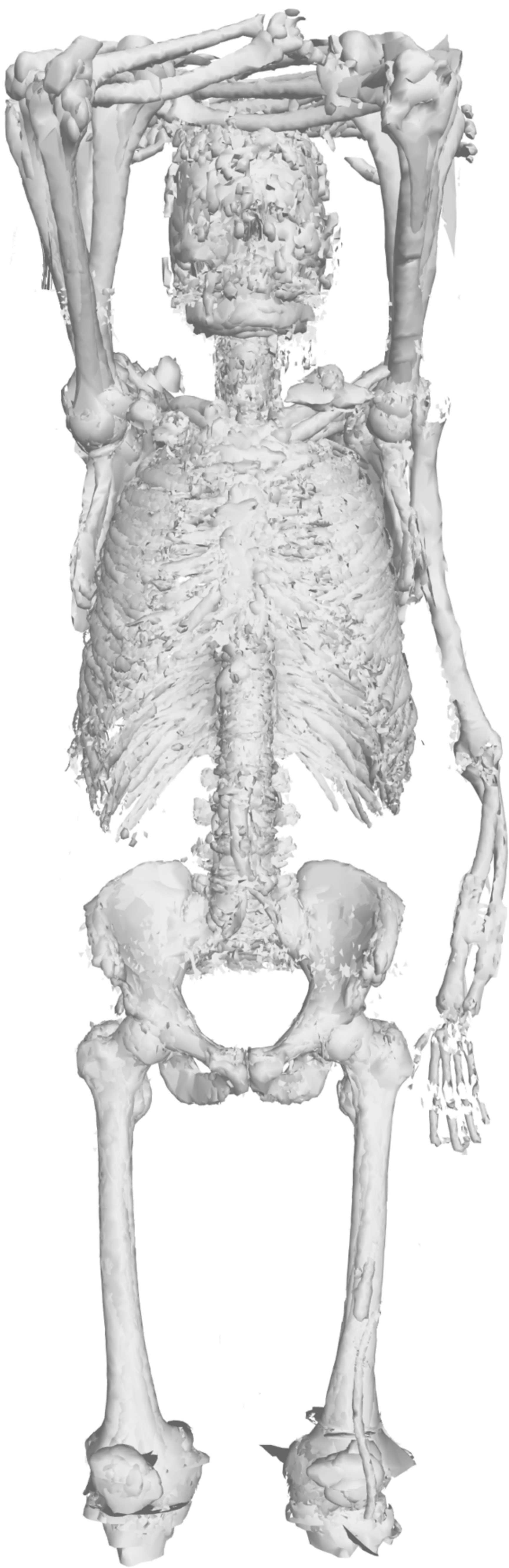
FIG.4 – 18 anatomical landmarks of DSP method placed manually in the 3D reconstruction of the pelvis bone from the mean image.

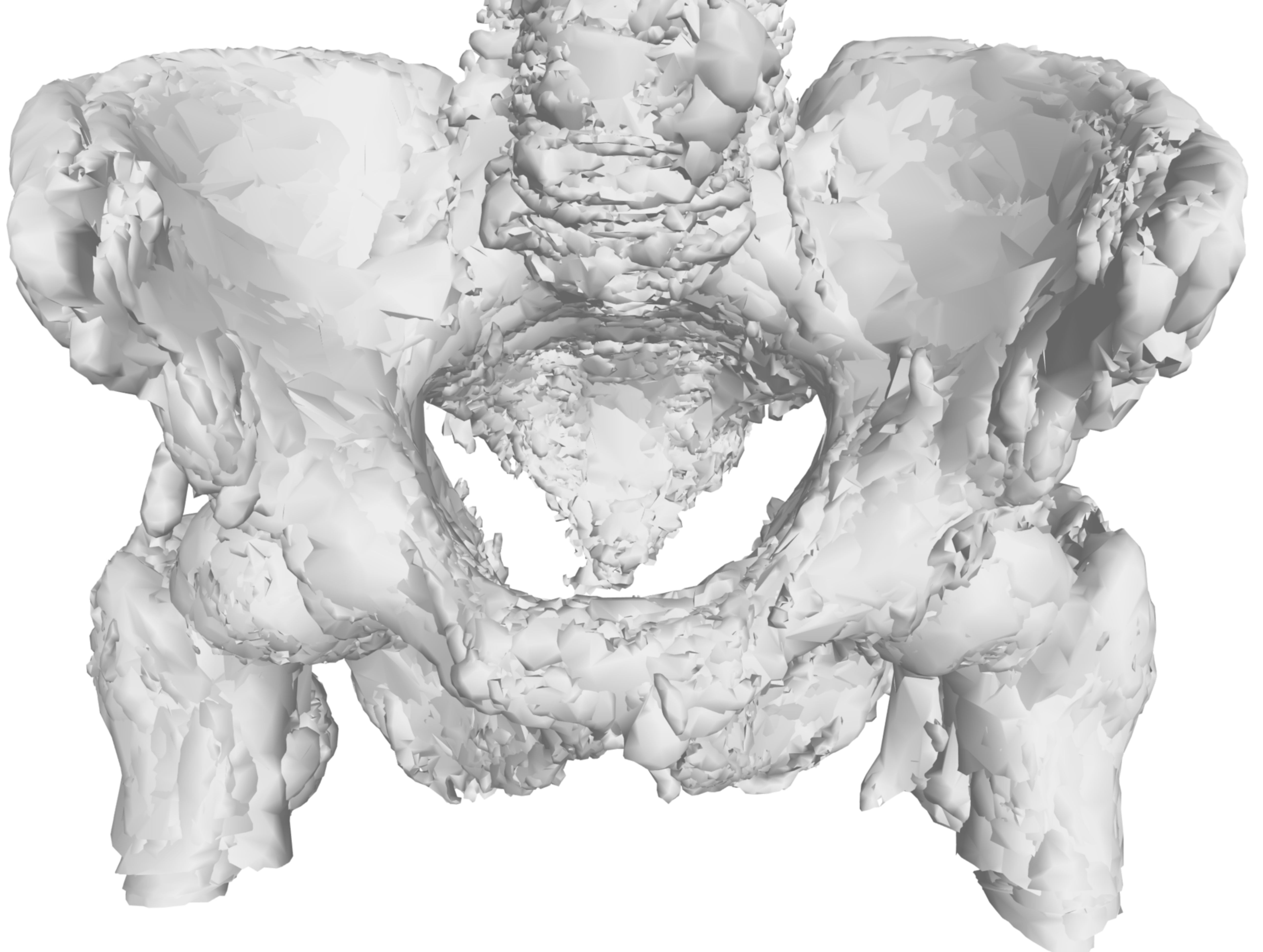
FIG.5 – Picture of the reduced model of the average pelvis obtained with a 3D printer.

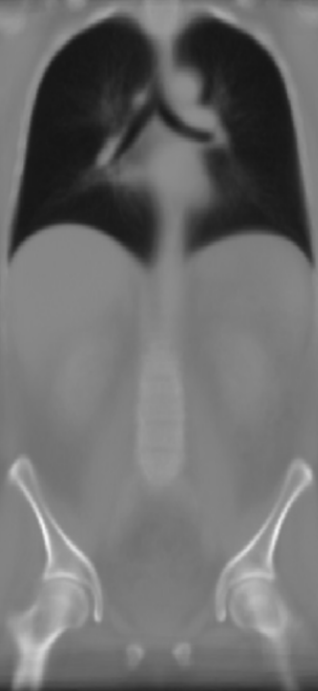FIG.6 – Workflow of the second experiment. On the left, the 83 input images are registered using a groupwise algorithm. Applying the registration transforms on the images yields an average image (center top), from which an average hip bone is extracted (center bottom). A physician manually positioned 18 anatomical landmarks, which are further back-transformed for each individual (right) using the registration inverse transforms. Afterwards the DSP tool is applied for each individual.

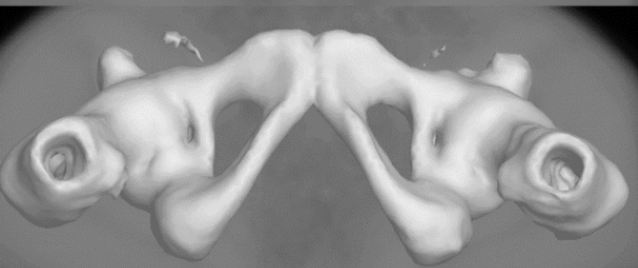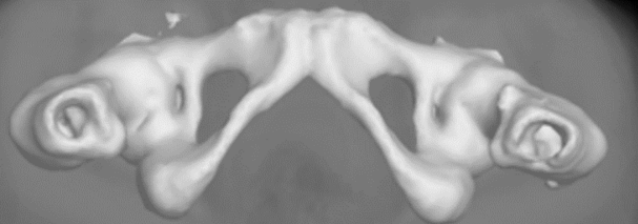References

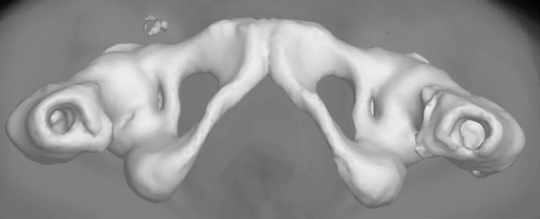
- [1] Michalski RS Carbonell JG Mitchell TM. Machine learning: An artificial intelligence approach. Springer Science & Business Media, 2013
- [2] Iglesias JE Sabuncu M. Multi-atlas segmentation of biomedical images: A survey. *Med Image Anal.* 2015;24(1): 205-19
- [3] Winslow RL Trayanova N Geman D Miller MI. Computational medicine: translating models to clinical care. *Sci Transl Med* 2012;4(158):158-211
- [4] Kishan K Chatterjee PM Kanchan T Kaur S Baryah N Singh RK. A review of sex estimation techniques during examination of skeletal remains in forensic anthropology casework. *Forensic Sci Int* 2016;261(165):1-8
- [5] Murail P Bruzek J Houët F Cunha E. DSP: A tool for probabilistic sex diagnosis using worldwide variability in hip-bone measurements. *Bulletins et mémoires de la Société d'Anthropologie de Paris.* 2005;17(3-4): 167-76
- [6] Agier R Valette S Kechichian R Fanton L Prost R. Hubless keypoint-based 3D deformable groupwise registration. Submitted to *Med Image Anal.* 2018.
- [7] Agier R Valette S Fanton L Croisille P Prost R. Hubless 3D medical image bundle registration. *International Joint Conference on Computer Vision, Imaging and Computer Graphics Theory and Applications.* Rome, Italy. 2016:3(265-72)
- [8] Menze B Langs G Montillo A Kelm M Müller H Tu Z. *Medical Computer Vision. Large Data in Medical Imaging. Third International MICCAI Workshop, MCV 2013, Nagoya, Japan, September 26, 2013, Revised Selected Papers.*
- [9] Salas T Grunberg K Langs G Muller H Weber M Winterstein M. VISCERAL 2013. <http://www.visceral.eu/assets/Uploads/Deliverables/VISCERAL-D2.1.1> [En ligne]
- [10] <http://www.pacea.u-bordeaux1.fr/publication/dspv1.html> [En ligne]
- [11] Cunha E Cattaneo C. *The State of the Art chez Forensic Anthropology and Forensic Pathology*, Humana Press, Totowa, New Jersey, 2006, pp. 9-53
- [12] Coleman WH. Sex differences in the growth of the human bony pelvis. *American Journal of Physical Anthropology.* 1969;31(2):25-152
- [13] France D. *Observational and metric analysis of sex in the skeleton chez Forensic Osteology: Advances in the Identification of Human Remains*, Springfield, K.J.Reichs, 1998, pp. 163-186

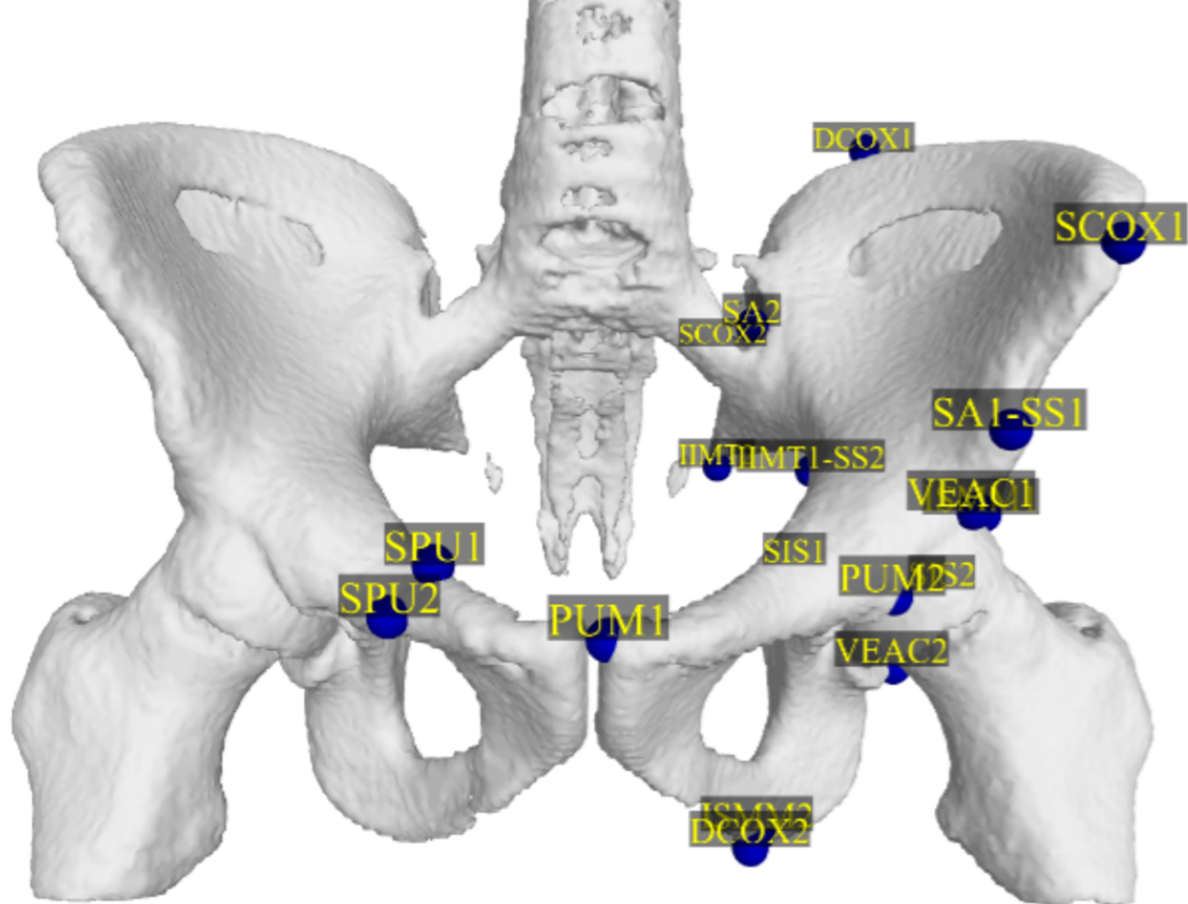


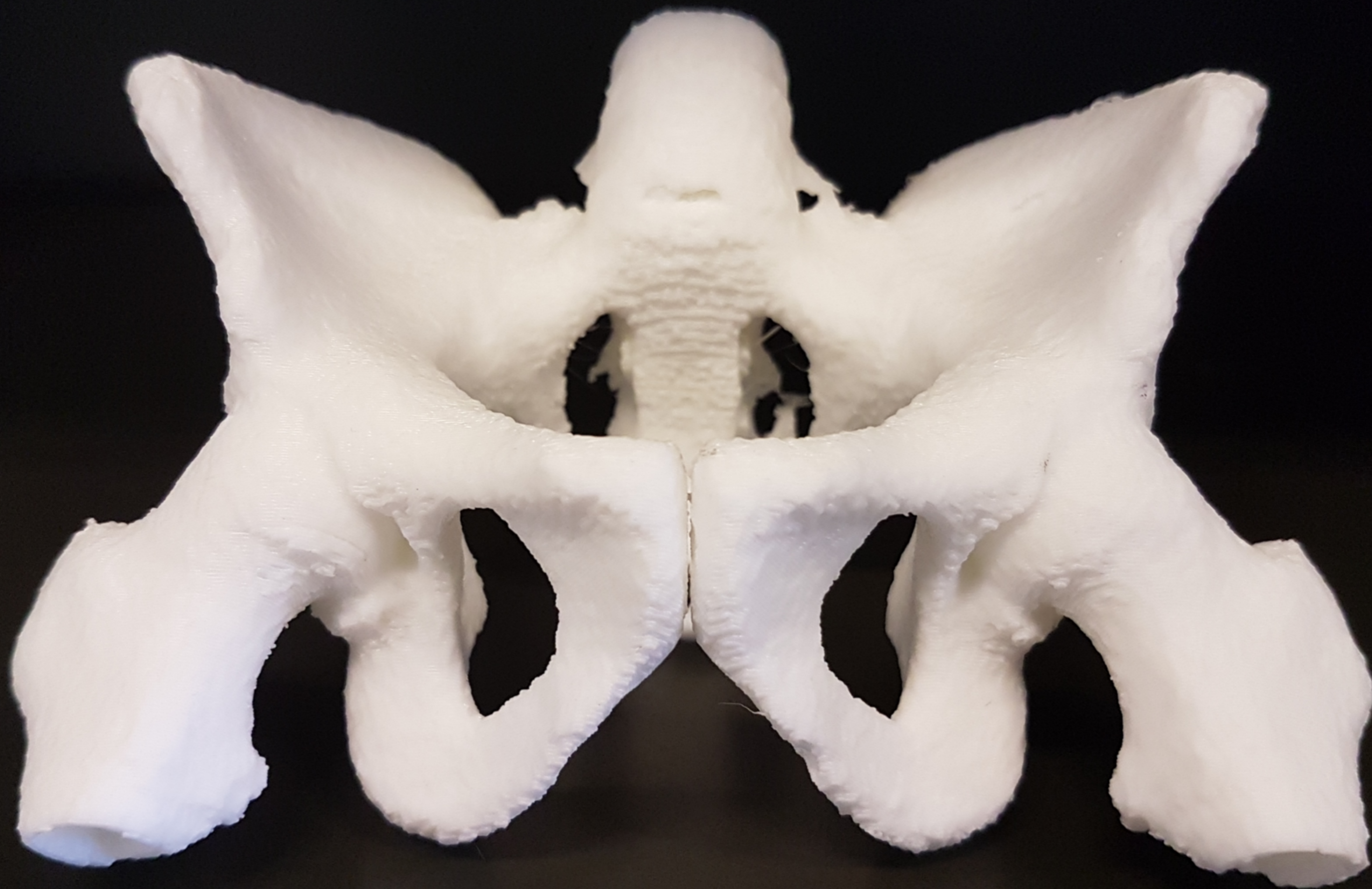












Individuals

Average image

Individual anatomical
Landmark sets for DSP

