



HAL
open science

Necrotizing Meningoencephalitis in a Captive Black and White Ruffed Lemur (*Varecia variegata variegata*) Caused by *Acanthamoeba* T4 Genotype

Nicolas Gaide, Michel Pélandakis, Cynthia Robveille, Olivier Albaric, Grégory Jouvion, Maud Souchon, Arnaud Risler, Jérôme Abadie

► To cite this version:

Nicolas Gaide, Michel Pélandakis, Cynthia Robveille, Olivier Albaric, Grégory Jouvion, et al.. Necrotizing Meningoencephalitis in a Captive Black and White Ruffed Lemur (*Varecia variegata variegata*) Caused by *Acanthamoeba* T4 Genotype. *Journal of Comparative Pathology*, 2015, 153 (4), pp.231-235. 10.1016/j.jcpa.2015.07.005 . hal-02001312

HAL Id: hal-02001312

<https://hal.science/hal-02001312v1>

Submitted on 14 Oct 2024

HAL is a multi-disciplinary open access archive for the deposit and dissemination of scientific research documents, whether they are published or not. The documents may come from teaching and research institutions in France or abroad, or from public or private research centers.

L'archive ouverte pluridisciplinaire **HAL**, est destinée au dépôt et à la diffusion de documents scientifiques de niveau recherche, publiés ou non, émanant des établissements d'enseignement et de recherche français ou étrangers, des laboratoires publics ou privés.

Necrotizing Meningoencephalitis in a Captive Black and White Ruffed Lemur (*Varecia variegata variegata*) Caused by *Acanthamoeba* T4 Genotype

N. Gaide^{*}, M. Pelandakis[†], C. Robveille^{*}, O. Albaric[‡], G. Jouvion[§],
M. Souchon[†], A. Risler[†] and J. Abadie^{*,‡}

^{*} Department of Pathology, LUNAM, ONIRIS, Nantes, [†] Université de Lyon, CNRS UMR 5240, Université Lyon 1, F-69622, Villeurbanne, [‡] Laboratoire d'Histopathologie Animale, LUNAM, ONIRIS, Nantes and [§] Institut Pasteur, Histopathologie Humaine et Modèles Animaux, 28 Rue du Docteur Roux, Paris, France

Summary

A mature male, black and white ruffed lemur (*Varecia variegata variegata*) died in a zoological garden after a 4-day history of lethargy and non-responsive convulsions. Necropsy and histopathological examinations revealed acute necrotizing and haemorrhagic meningoencephalitis with intralésionales amibes confirmed by immunohistochemistry. *Acanthamoeba* T4 genotype was identified as the causative agent of the brain lesion, based on amplification and sequencing of 18S ribosomal RNA genes. The presence of free-living amibes in water and mud from the lemur's environment was investigated by morphological and molecular analyses. The two predominant genera, representing 80% of isolated amibes, were *Naegleria* spp. and *Acanthamoeba* spp. All *Acanthamoeba* isolates belonged to the T4 genotype. To the author's knowledge, this is the first report of a meningoencephalitis due to *Acanthamoeba* T4 genotype in Lemuridae with concurrent analysis of pathological tissues and environment.

Keywords: *Acanthamoeba*; lemur; meningoencephalitis

Amoebic meningoencephalitis is a life-threatening condition in mammals recognized throughout the world. Causative agents are ubiquitous free-living amibes identified as *Naegleria fowleri*, *Acanthamoeba* spp., *Balamuthia mandrillaris* and *Sappinia diploidea* (Visvesvara *et al.*, 2007). *N. fowleri* can cause primary acute meningoencephalitis following water inhalation and brain invasion through the cribriform plate (Daft *et al.*, 2005). In contrast, *Acanthamoeba* spp. and *B. mandrillaris* are reported to trigger acute to chronic meningoencephalitis after haematogenous spread (Rideout *et al.*, 1997; Guarner *et al.*, 2007). For *Acanthamoeba* spp., primary sites of infection include the respiratory tract (Westmoreland *et al.*, 2004; Reed *et al.*, 2010) and the skin (Rosenberg and

Morgan, 2001). *Acanthamoeba* spp. has been isolated from soil, dust, sea and cool waters (Visvesvara *et al.*, 2007). Meningoencephalitis due to *Acanthamoeba* spp. has been documented in people (Guarner *et al.*, 2007), dogs (Reed *et al.*, 2010) and a captive Simian immunodeficiency virus (SIV)-infected macaque (Westmoreland *et al.*, 2004). Among the 19 genotypes described for *Acanthamoeba* spp. (T1 to T19), the T4 genotype is overrepresented in human disease (Maciver *et al.*, 2013). This report describes the first case of amoebic meningoencephalitis due to *Acanthamoeba* T4 genotype in a captive lemur, with concurrent analysis of pathological tissues and environment.

A 14-year-old male, black and white ruffed lemur (*Varecia variegata variegata*) was presented with a history of sudden-onset lethargy, recumbency and persistent convulsions. The lemur lived with four

other congeners in a zoological garden in western France, in an island habitat isolated from other captive species by a narrow strip of water. This water was drawn from a lake near the park, circulating between each island and forming a closed-circuit water system. Following hospitalization, haematological and serum biochemical analyses revealed marked neutrophilic leucocytosis ($17 \times 10^9/l$; reference range $0.3\text{--}6.0 \times 10^9/l$) with lymphopenia ($0.55 \times 10^9/l$; reference range $1.1\text{--}5.4 \times 10^9/l$) and a mild increase in serum alanine aminotransferase (327 IU/l; reference range 10–210 IU/l). Despite supportive therapy, which included intravenous fluids, a sedative and antibiotics, the animal died after 4 days.

A post-mortem examination was performed within 24 h of death. Gross lesions were restricted to the brain and meninges. On cut section, the cerebrum had multifocal, randomly distributed, pinpoint foci of malacia and haemorrhage, affecting the left frontal and parietal lobes. These foci were numerous, large and coalescing in the grey matter, but were rare and sparse in the white matter. Prominent haemorrhages were observed in the surrounding meninges and along the medial longitudinal fissure. Samples of the brain, liver, kidney, spleen and intestine were submitted for microbiological examination. Aerobic bacteria were cultured on nutrient and blood agar plates at 37°C. *Clostridium* spp. were cultured selectively on Columbia blood agar with neomycin at 37°C under anaerobic conditions. Detection of *Salmonella* spp. included a pre-enrichment in buffered peptone water, enrichment in Muller–Kauffmann tetrathionate–novobiocin and Rappaport–Vassiliadis soya peptone broths and a culture on a xylose–lysine desoxycholate agar plate at 37°C under aerobic conditions. A Sabouraud’s agar plate with chloramphenicol at 35°C under aerobic conditions was used for fungal culture. After 48 h (for bacterial) and 72 h (for fungal) incubation, neither significant bacteria nor fungi were detected.

At the time of necropsy examination, the brain was collected and fixed in 10% neutral buffered formalin. The fixed brain was sliced in 0.5 cm coronal sections. Selected sections included the cerebrum at the level of the basal ganglia, thalamus, occipital lobes and cerebellum. Slices were processed routinely and embedded in paraffin wax. Sections (4 µm) were stained with haematoxylin and eosin (HE) and by the periodic acid–Schiff (PAS) reaction.

Histopathological examination of the brain confirmed the presence of haemorrhagic and necrotic foci (Fig. 1). The Virchow–Robin spaces were expanded by neutrophils and fewer macrophages (Fig. 2). The leptomeninges were markedly expanded by congestion, haemorrhage, fibrinous exudate, neu-

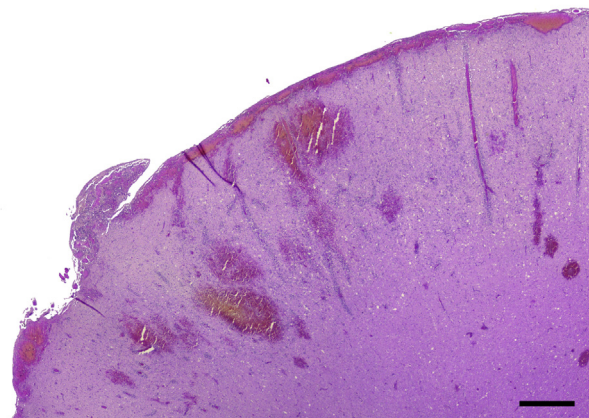


Fig. 1. Multifocal haemorrhagic necrosis in the left frontal lobe, large and coalescing areas in the grey matter, but sparse foci in the white matter. HE. Bar, 1 mm.

trophils and occasional macrophages (Fig. 3). Cortical lesions contained numerous double-walled amoebic cysts and 15–30 µm diameter trophozoites, characterized by an abundant, eosinophilic, vacuolated cytoplasm and a central round nucleus with one prominent central nucleolus (Fig. 2). The cytoplasm of the trophozoites was stained by PAS.

To confirm the amoebic nature of the microorganisms, immunohistochemistry (IHC) was performed on paraffin wax-embedded sections of affected cerebrum, using a Leica BOND-III automate and the Bond Polymer Refine Detection Kit following the manufacturer’s instructions (Leica Biosystems, Newcastle upon Tyne, UK). Primary polyclonal rabbit

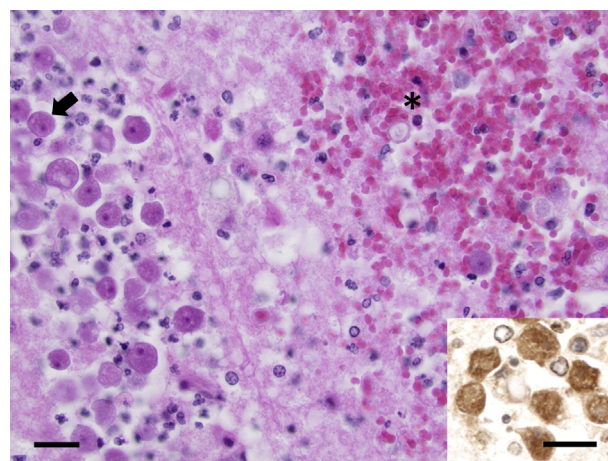


Fig. 2. Expanded Virchow–Robin spaces with *Acanthamoeba* trophozoites (arrow) and a focus of haemorrhagic necrosis with one double-walled cyst (*). HE. Bar, 50 µm. Inset: trophozoites identified by IHC. Bar, 50 µm.

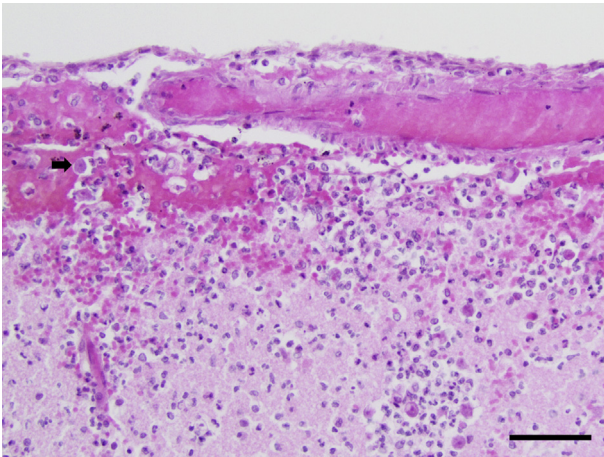


Fig. 3. Leptomeninges with congestion, haemorrhage, infiltration by neutrophils and trophozoites (arrow). HE. Bar, 200 µm.

antisera, specific for amoebic lectins (Pasteur Institute, Paris, France), were applied at a dilution of 1 in 200 for 30 min at room temperature. Immunohistochemical labelling was positive (Fig. 2 inset).

Molecular identification was conducted on paraffin wax-embedded brain tissues. DNA was extracted using the NucleoSpin[®] Tissue Extraction Kit following manufacturer's recommendations (Macherey–Nagel, Düren, Germany). For identification of *Acanthamoeba* spp., *N. fowleri* and *B. mandrillaris*, partial 18S ribosomal RNA (rRNA) gene sequences were amplified by polymerase chain reaction (PCR), using primers and methods as described by Dykova *et al.* (1999) for *Acanthamoeba* spp., Pélandakis and Pernin (2002) for *N. fowleri* and Qvarnstrom *et al.* (2006) for *B. mandrillaris*. PCR results were positive for *Acanthamoeba* spp. and negative for *N. fowleri* and *B. mandrillaris*. For *Acanthamoeba* genotyping, the purified PCR product was sequenced by an automatic ABI 3730XL (Genoscreen, Lille, France) and revealed a T4 genotype (accession number KM434770 in GenBank).

To investigate the source of infection, 2 l of 10°C tap water and mud were taken from the lemur's enclosure, several weeks after the death of the lemur. Amoebas were isolated from water samples after filtration through 1.2 µm cellulose nitrate membranes. Culture was assessed by inverting membranes on non-nutrient agar plates, previously covered with a lawn of living *Escherichia coli* K-12 cells (Na₂HPO₄ 0.66 g/l, KH₂PO₄ 0.4 g/l and agar–agar 12.0 g/l). After incubation at 30°C for 4–8 days, the emerging fronts were observed microscopically. Several known amoeba genera were identified according to their morphology and quantified by the most probable number method (Table 1).

Amplification and sequencing of 18S rRNA genes were then performed for *Acanthamoeba* genotyping and *N. fowleri* detection, using the same molecular analysis as described above.

In the tap water, the two most prevalent genera were *Naegleria* spp. (63.9%) and *Acanthamoeba* spp. (16.7%). The same proportion was observed from the mud with 56.1% and 22.8%, respectively. Among the 18 isolates belonging to *Acanthamoeba* spp., all were of the T4 genotype, but none of them shared complete homology with the lemur isolate. Pathogenic *N. fowleri* were not detected. Other identified amoebas included *Vermamoeba* spp. detected in both water (11.1%) and mud (12.3%), *Vahlkampfia* spp. and *Tetramitus* spp. detected only in mud (1.75% and 5.3%, respectively) and *Nuclearia* spp. detected only in tap water (2.8%).

The present report describes amoebic meningoencephalitis in a captive black and white ruffed lemur, confirmed by IHC and identified as *Acanthamoeba* T4 genotype by PCR and 18S rRNA gene sequencing. Meningoencephalitis due to *Acanthamoeba* spp. has been reported in the context of severe immunosuppression in man (Guarner *et al.*, 2007), a non-human primate (Westmoreland *et al.*, 2004) and a dog (Reed *et al.*, 2010). In the present case, neither previous disease nor concurrent lesions on post-mortem examination were observed in the lemur. Therefore, no evidence of an immunocompromised status was found.

Invasive amoebiasis occurs in non-human primates more commonly as gastrointestinal and systemic diseases. The main agent is the enteroinvasive *Entamoeba histolytica*, which is responsible for ulcerative colitis in New World monkeys, Old World monkeys and the great apes (Bennett *et al.*, 1998). Haematogenous spread to the liver, lung and brain were reported (Bennett *et al.*, 1998), as well as gastritis in Colobinae (Ulrich *et al.*, 2010). Amoebiasis due to *B. mandrillaris*

Table 1
Amoeba in water and mud from the lemur's environment

Organism	Water (%)	Mud (%)
<i>Naegleria</i>	63.9	56.1
<i>Acanthamoeba</i>	16.7	22.8
<i>Vermamoeba</i>	11.1	12.3
<i>Nuclearia</i>	2.8	0
<i>Vahlkampfia</i>	0	1.75
<i>Tetramitus</i>	0	5.3
Small amoebas	2.8	0
Unidentified	2.7	1.75

The % represents the proportion of a genus (e.g. *Naegleria*) among all amoebas that were identified on agar plate cultures.

is rare, but has been documented in Old World monkeys and gorillas, as isolated meningoencephalitis or systemic diseases (Rideout *et al.*, 1997). In non-human primates, *Acanthamoeba* infection was only reported in one captive Rhesus macaque infected with SIV. In this monkey, gross and histopathological examinations were consistent with acute necrotizing meningoencephalitis associated with a granulomatous pneumonia. The genotype of *Acanthamoeba* spp. was unknown (Westmoreland *et al.*, 2004). To the authors' knowledge, the present case provides the first description of amoebic meningoencephalitis due to *Acanthamoeba* T4 genotype in a spontaneously infected, captive lemur.

For brain invasion, direct extension through the nasal mucosa is reported to be the typical route of entry of *N. fowleri* (Daft *et al.*, 2005), but this is reported rarely for *Acanthamoeba* spp. infection in man (Lackner *et al.*, 2010) or in experimental infection in mice (Culbertson *et al.*, 1959). In the present case, all of the organs apart from the brain were unremarkable. Cerebral lesions were rostral and the meningitis was prominent. Moreover, the lemur was often seen swimming in the water. Consequently, nasal infection is suspected in this case and the water was the likely source of infection.

Naegleria spp., *Acanthamoeba* spp. and *Vermamoeba* spp. were the most predominant free-living amoebas isolated from the water and mud close to the lemur's habitat. This preponderance was described in previous reports (Delafont *et al.*, 2013). Those three genera were commonly found in the environment, but proportions varied according to outdoor temperatures (Rodríguez-Zaragoza, 1994). Other detected free-living amoebas included *Nuclearia* spp., *Tetramitus* spp. and *Vahlkampfia* spp. These were detected less frequently in water (Patterson, 1984; De Jonckheere, 2007). Their pathogenicity is poorly documented and restricted to keratitis in human *Vahlkampfia* infections (Alexandrakis *et al.*, 1998). All *Acanthamoeba* isolates detected in the water and mud belonged to the T4 genotype, as did the lemur isolate. The T4 genotype overrepresentation in environmental isolates is consistent with previous reports (Maciver *et al.*, 2013).

In conclusion, this report describes the first spontaneously arising case of acute meningoencephalitis due to *Acanthamoeba* T4 genotype in a captive, outdoor black and white ruffed lemur without evidence of concurrent immunocompromise. The abundance of *Acanthamoeba* T4 genotype in the environment of this animal supports the water as the source of infection. These results highlight the risk of closed-circuit water systems for captive animals in zoological gardens as a source of infectious disease.

Conflict of Interest Statement

The authors declare no conflict of interest.

References

- Alexandrakis G, Miller D, Huang AJ (1998) Amebic keratitis due to *Vahlkampfia* infection following corneal trauma. *Archives of Ophthalmology*, **116**, 950–951.
- Bennett BT, Abee CR, Henrickson R (1998) *Non-human Primates in Biomedical Research: Diseases*. Academic Press, San Diego, pp. 116–119.
- Culbertson CG, Smith JW, Cohen HK, Minner JR (1959) Experimental infection of mice and monkeys by *Acanthamoeba*. *American Journal of Pathology*, **35**, 185–197.
- Daft BM, Visvesvara GS, Read DH, Kinde H, Uzal FA *et al.* (2005) Seasonal meningoencephalitis in Holstein cattle caused by *Naegleria fowleri*. *Journal of Veterinary Diagnostic Investigation*, **17**, 605–609.
- De Jonckheere JF (2007) Molecular identification of free-living amoebae of the *Vahlkampfiidae* and *Acanthamoebidae* isolated in Arizona (USA). *European Journal of Protistology*, **43**, 9–15.
- Delafont V, Brouke A, Bouchon D, Moulin L, Héchard Y (2013) Microbiome of free-living amoebae isolated from drinking water. *Water Research*, **47**, 6958–6965.
- Dykova I, Lom J, Schroeder-Diedrich JM, Booton GC, Byers TJ (1999) *Acanthamoeba* strains isolated from organs of freshwater fishes. *Journal of Parasitology*, **85**, 1106–1113.
- Guarner J, Bartlett J, Shieh WJ, Paddock CD, Visvesvara GS *et al.* (2007) Histopathologic spectrum and immunohistochemical diagnosis of amoebic meningoencephalitis. *Modern Pathology*, **20**, 1230–1237.
- Lackner P, Beer R, Broessner G, Helbok R, Pfausler B *et al.* (2010) Acute granulomatous *Acanthamoeba* encephalitis in an immunocompetent patient. *Neurocritical Care*, **12**, 91–94.
- Maciver SK, Asif M, Simmen MW, Lorenzo-Morales J (2013) A systematic analysis of *Acanthamoeba* genotype frequency correlated with source and pathogenicity: T4 is confirmed as a pathogen-rich genotype. *European Journal of Protistology*, **49**, 217–221.
- Patterson DJ (1984) The genus *Nuclearia* (*Sarcodina*, *Filosea*): species composition and characteristics of the taxa. *Archiv fuer Protistenkunde*, **128**, 127–139.
- Pélandakis M, Pernin P (2002) Use of multiplex PCR and PCR restriction enzyme analysis for detection and exploration of the variability in the free-living amoeba *Naegleria* in the environment. *Applied and Environmental Microbiology*, **68**, 2061–2065.
- Qvarnstrom Y, Visvesvara GS, Sriram R, Da Silva AJ (2006) Multiplex real-time PCR assay for simultaneous detection of *Acanthamoeba* spp., *Balamuthia mandrillaris* and *Naegleria fowleri*. *Journal of Clinical Microbiology*, **44**, 3589–3595.
- Reed LT, Miller MA, Visvesvara GS, Gardiner CH, Logan MA *et al.* (2010) Cerebral mass in a puppy with respiratory distress and progressive neurologic signs. *Veterinary Pathology*, **47**, 1116–1119.

- Rideout BA, Gardiner CH, Stalis IH, Zuba JR, Hadfield T *et al.* (1997) Fatal infections with *Balamuthia mandrillaris* (a free-living amoeba) in gorillas and other Old World primates. *Veterinary Pathology*, **34**, 15–22.
- Rodríguez-Zaragoza S (1994) Ecology of free-living amoebae. *Critical Reviews in Microbiology*, **20**, 225–241.
- Rosenberg AS, Morgan MB (2001) Disseminated acanthamoebiasis presenting as lobular panniculitis with necrotizing vasculitis in a patient with AIDS. *Journal of Cutaneous Pathology*, **28**, 307–313.
- Ulrich R, Böer M, Herder V, Spitzbarth I, Hewicker-Trautwein M *et al.* (2010) Epizootic fatal amebiasis in an outdoor group of Old World monkeys. *Journal of Medical Primatology*, **39**, 160–165.
- Visvesvara GS, Moura H, Schuster FL (2007) Pathogenic and opportunistic free-living amoebae: *Acanthamoeba* spp., *Balamuthia mandrillaris*, *Naegleria fowleri*, and *Sappinia diploidea*. *FEMS Immunology and Medical Microbiology*, **50**, 1–26.
- Westmoreland SV, Rosen J, MacKey J, Romsey C, Xia DL *et al.* (2004) Necrotizing meningoencephalitis and pneumonitis in a Simian immunodeficiency virus-infected Rhesus macaque due to *Acanthamoeba*. *Veterinary Pathology*, **41**, 398–404.