

3D Right ventricular strain: comparative analysis of Tetralogy of Fallot and atrial septal defect

Authors:

P Mocerì¹, M Sermesant², D Baudouy¹, E Ferrari¹, N Duchateau³, ¹University Hospital of Nice - Hospital Pasteur - Nice - France, ²INRIA, Asclepios Research Project - Sophia-Antipolis - France, ³University Claude Bernard of Lyon, CREATIS - Lyon - France,

Topic(s):

Right ventricular systolic function

Citation:

European Heart Journal Supplements (2017) 18 (Supplement 3), iii136

Funding Acknowledgements:

AO2I 2013 CHU de Nice / European Union (VP2HF FP7-2013-611823)

Background: Right ventricular (RV) function assessment is crucial in CHD patients, especially in atrial septal defect (ASD) and Tetralogy of Fallot (TOF) patients. Indeed, prognosis is very different between TOF patients with pulmonary regurgitation and ASD patients, and only little is known about 3D deformation in RV overload.

Purpose: The aim of our study was to assess RV remodeling differences between ASD, TOF patients and controls.

Methods: We performed a prospective case-control study. We included 10 patients with an ASD (mean age 53.3±21y) and 10 with TOF (mean age 34.9±18y) who were older than 16 years old, and compared them to a control group free from any cardiovascular disease (N=44, mean age 42.5±15y). 3D transthoracic RV echocardiographic sequences were acquired. Myocardial tracking was performed by a semi-automatic commercial software. Output RV meshes included spatial correspondences. They were post-processed to align the data temporally and extract local deformation. Global and local statistics provided deformation patterns for each subgroup of subjects.

Results: Overall, ASD and TOF patients had similar but reduced RV ejection fraction (respectively 44.3±10 and 44.5±12 %) and dilated right ventricles (mean RV EDV 158.3±100 and 115.4±46mL) using 3D analysis. Similar RV global area strain (GAS), global longitudinal strain (GLS) and global circumferential strain (GCS) were observed between the two groups. Compared to controls, ASD patients had lower GAS (-22.2±8 vs -29.4±5%; p=0.01), lower GCS (-12.9±4 vs -17.1±4%; p=0.009) but similar GLS (p=0.07). TOF patients had also lower GAS (-25.1±6%; p=0.03) but lower GLS (-10.0±3%; p=0.01) and similar GCS (-15.5±4%; p=0.4) in comparison with the control group. However, ASD patients had significantly lower CS in the infundibular, inlet and membranous septum as compared with TOF patients (respectively p=0.02, p=0.05 and p=0.03).

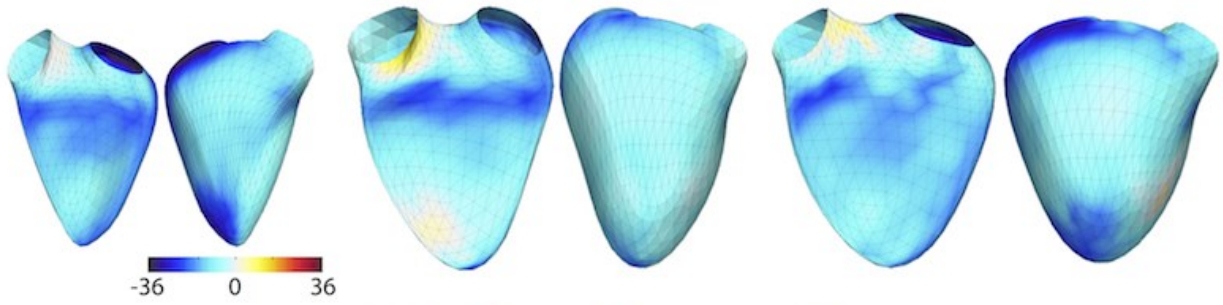
Conclusion: Volume overload in ASD patients seems to impact circumferential strain and preserve longitudinal strain, whereas TOF patients tend to have lower longitudinal strain with preserved circumferential strain, probably because of the combination of RV pressure and volume overload. A larger cohort of patients could help understand the insights of RV remodeling in congenital heart disease using 3D speckle-tracking imaging.

Controls (N=44)

Fallot (N=10)

Atrial septal defect (N=10)

Longitudinal strain (%)



Circumferential strain (%)

