

Incremental prognostic value of changes in 3D right ventricular function in pulmonary hypertension

Authors:

P. Mocerì¹, N. Duchateau², D. Baudouy¹, C. Sanfiorenzo¹, F. Squara¹, E. Ferrari¹, M. Sermesant³,
¹University Hospital of Nice - Hospital Pasteur - Nice - France, ²University Claude Bernard of Lyon, CREATIS - Lyon - France, ³INRIA, Asclepios Research Project - Sophia-Antipolis - France,

Topic(s):

Tissue Doppler, Speckle Tracking and Strain Imaging

Citation:

European Heart Journal (2018) 39 (Supplement), 966

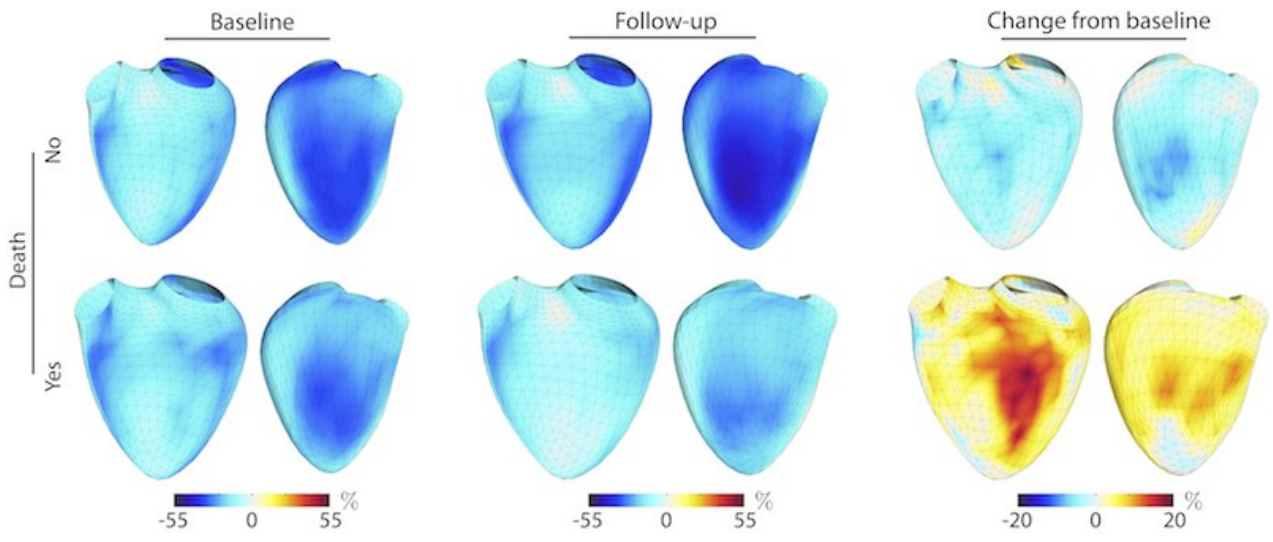
Funding Acknowledgements:

CHU de Nice, France (AO2I-2013 and AOI-2014); European Union 7th Framework Programme (VP2HF FP7-2013-611823); grant from Actelion pharmaceuticals

Aims: Outcomes in pulmonary hypertension (PH) are related to right ventricular (RV) function and remodeling. We hypothesized that changes in RV function, especially area strain (AS), could provide incremental prognostic data. In this study, we aimed to assess global and regional 3D RV function changes between baseline and 6-months visit and evaluate their prognostic value in PH.

Methods and results: 65 PH patients were prospectively included in this longitudinal study. All patients underwent 2D and 3D transthoracic echocardiography at baseline and 6-month follow-up. 3D RV echocardiographic sequences were analyzed by semi-automatic software and output meshes were post-processed to extract regional deformation. At baseline, there was no significant difference in RV AS between patient subgroups. Patients who were considered clinically stable or improving presented at 6-months a significant increase in RV EF ($p=0.04$) and decrease in RV global AS ($p=0.001$). The most significant regional changes occurred within the septum. Over a median follow-up of 24.8 months [22.1–25.7], 16 patients died from PH or were transplanted. On multivariate COX analysis, 6-month changes in WHO class (HR 17.4 [5.2–58.5]), BNP (HR 1.003 [1.001–1.004]) and RV global AS (HR 1.12 [1.03–1.21]) were independent predictors of survival. A composite score including these parameters could identify patients with a 9-fold increased risk of outcomes.

Conclusion: Our study demonstrates the additional prognostic value of following changes in RV deformation using 3D echocardiography. A composite score including changes in WHO function class, BNP and 3D RV AS could help stratifying the patients' risk and should be assessed in a larger cohort.



RV global area strain evolution