



**HAL**  
open science

## **Comparison of HR-MRI with $\mu$ CT arthrography for the morphological assessment of non-human primate models of osteoarthritis**

A.L. Perrier, Emmanuel Chereul, Denis Grenier, F. Taborik, M Abdallah, T. Chuzel, S Martin, L Magnier, X. Pesesse, Sandra Pietri, et al.

### **► To cite this version:**

A.L. Perrier, Emmanuel Chereul, Denis Grenier, F. Taborik, M Abdallah, et al.. Comparison of HR-MRI with  $\mu$ CT arthrography for the morphological assessment of non-human primate models of osteoarthritis. GDR imagerie du vivant: "Nouvelles méthodologies en imagerie du vivant", Dec 2012, Lyon, France. , Nouvelles méthodologies en imagerie du vivant. <hal-01984019>

**HAL Id: hal-01984019**

**<https://hal.science/hal-01984019v1>**

Submitted on 16 Jan 2019

**HAL** is a multi-disciplinary open access archive for the deposit and dissemination of scientific research documents, whether they are published or not. The documents may come from teaching and research institutions in France or abroad, or from public or private research centers.

L'archive ouverte pluridisciplinaire **HAL**, est destinée au dépôt et à la diffusion de documents scientifiques de niveau recherche, publiés ou non, émanant des établissements d'enseignement et de recherche français ou étrangers, des laboratoires publics ou privés.



HAL Authorization

## Introduction

### Background:

- Several models of induced OA in small animals :
  - ⊗ do not mimic the complex human OA
  - ⊗ large genetic, phenotypic and pathophysiological heterogeneity between human and rodent
- > ineffective models in evaluating new treatments
- Similarities between monkey and human
  - 😊 monkeys more appropriate to model the human disease
- Non invasive techniques [1]
  - 😊 3D HR-MRI to assess the cartilage thickness on guinea pigs [2]
  - 😊 volume and thickness quantification of rat knee cartilage is possible using HR-MRI [3,4]

### Objectives:

- To develop a dedicated protocol for knee joint examination of primates at 1.5 T and with  $\mu$ CT arthroscanner.
- To compare morphological parameters based on MRI and  $\mu$ CTA acquisitions on a group of 10 old primates with spontaneous osteoarthritis (OA).

## Material and method

- 10 old female primates
  - between 12 and 18 years old (mean  $13.8 \pm 1.8$ )
  - spontaneous osteoarthritis
- 2 imaging modalities ( $\mu$ CT and MRI)
- experimental protocol approved by the Animal Ethics Committee of our institution

### $\mu$ CTA

- GE Locus  $\mu$ -CT (standard voltage and amperage)
- isotropic resolution of 90  $\mu$ m
- scan time/knee : 15 min

### MRI

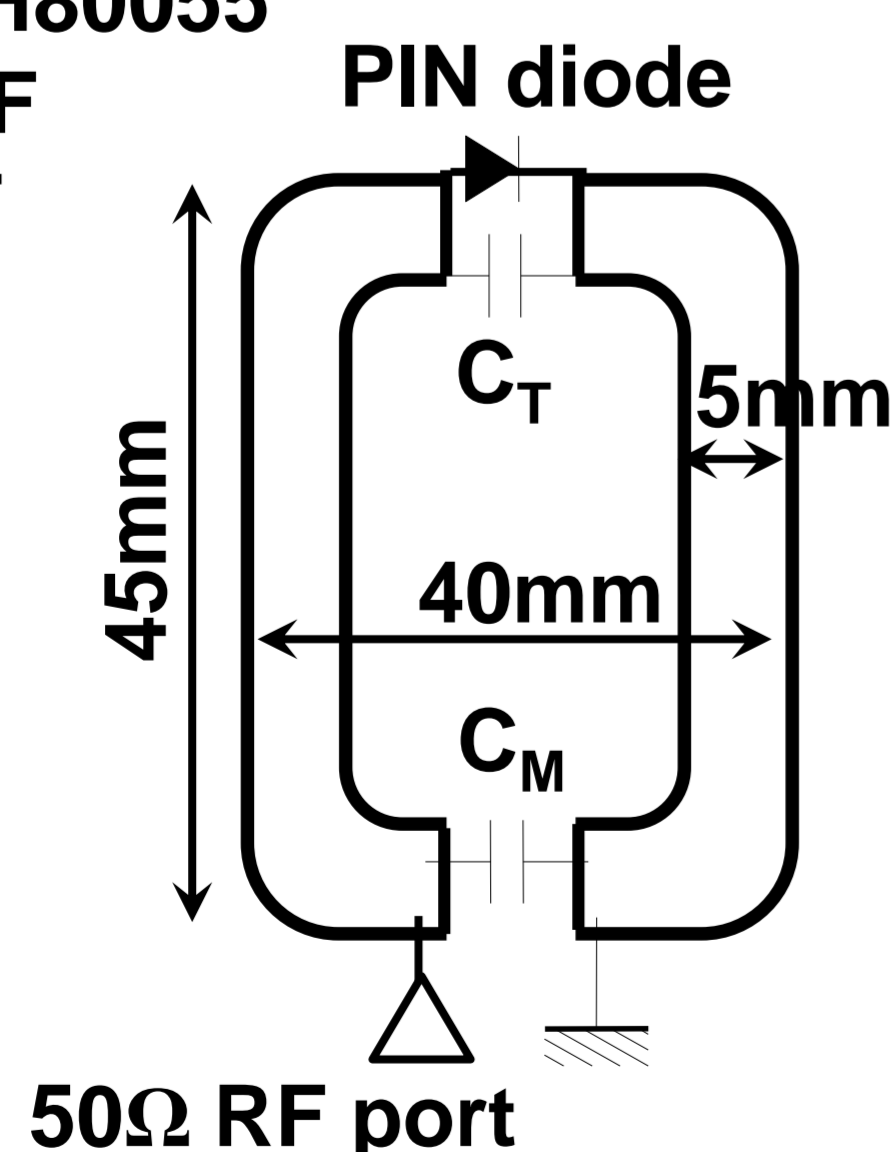
- 1.5T Siemens Sonata system
  - 3D water excitation FLASH sequence: 25° flip angle, 27 ms TR, 11.7 ms TE, 70 Hz/Pixel receiver bandwidth
  - a pair of homemade two-channel array coil
- in-plane pixel: 112x131  $\mu$ m<sup>2</sup>, thickness: 220  $\mu$ m
- scan time/knee : 20 min

### Two-channel array coil:

- Two single coils overlapped with  $|S_{21}| < -20$ dB.
- Coil elements pasted on a thermoformable plastic support with about 32mm outer diameter to fit the animal's morphology.
- placed on the top of patella and encompassing the knee joint

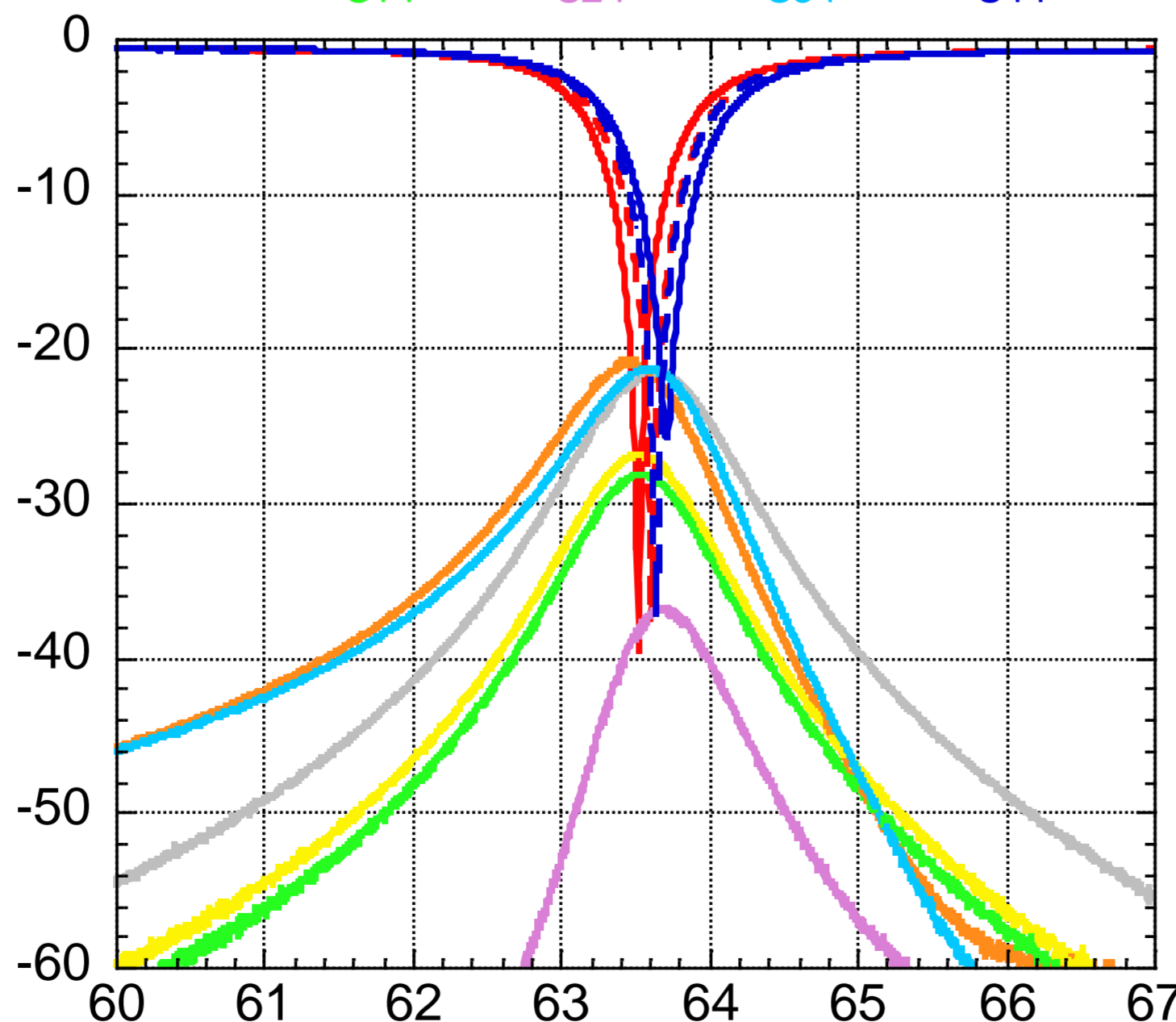
### Circuit of a single coil:

- Substrate: RT/Duroid 5880 (508 $\mu$ m)
- Copper: 35 $\mu$ m thickness
- diode PIN: DH80055
- $C_T = 620 \pm 20$ pF
- $C_M = 100 \pm 2$ pF




### S-parameters of the coils in experimental conditions:

- S11, S12, S13, S14, S21, S22, S23, S24, S31, S32, S33, S34, S41, S42, S43, S44



### Experimental set up :



## Results

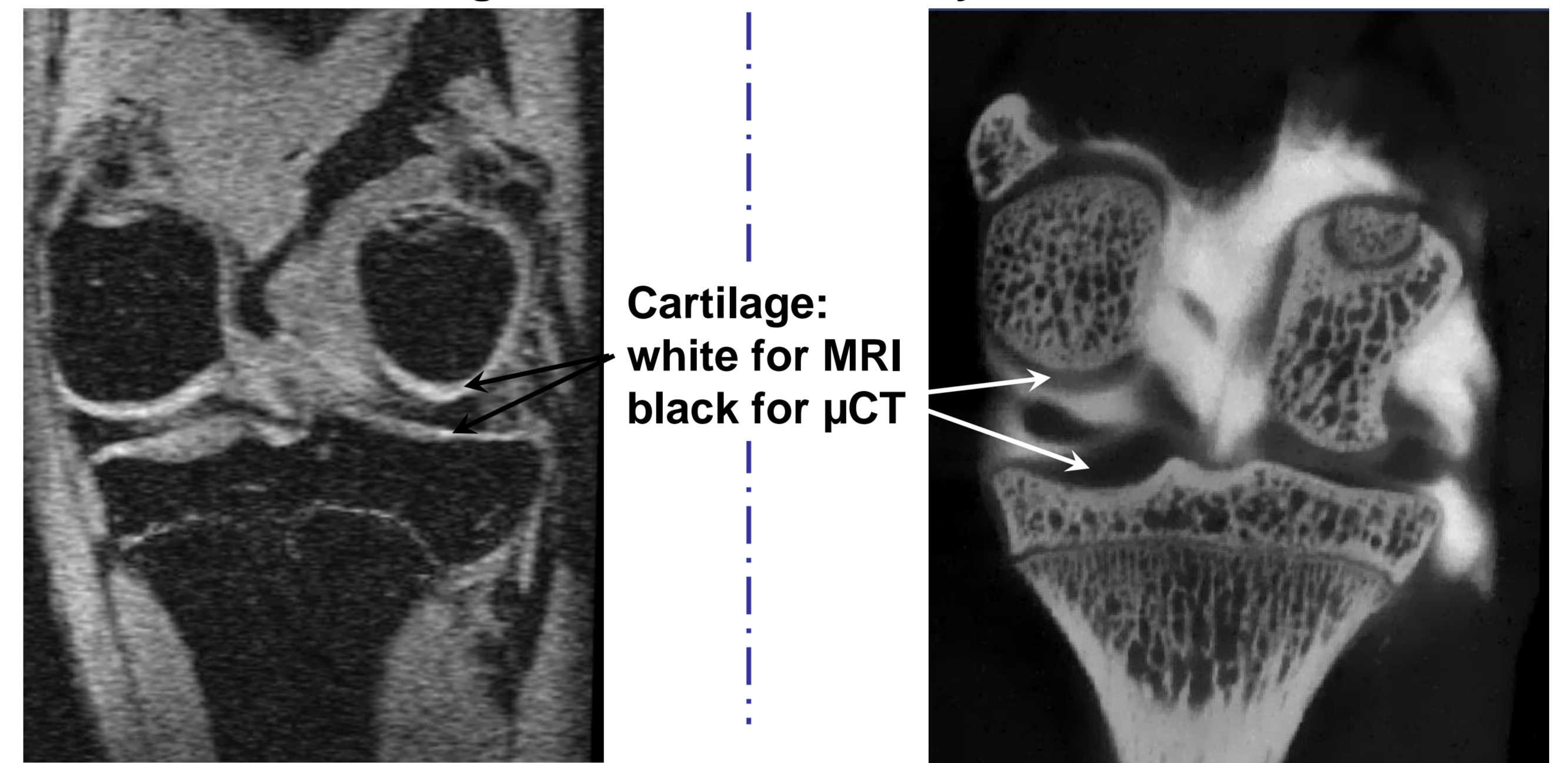
### MRI

- On phantoms (1,25g/L of NiSO<sub>4</sub>, 5g/L of NaCl):
  - SNR gain was 4.4 compared with a 40 mm diameter surface coil
  - With 16% signal uniformity in the region of interest

### $\mu$ CTA

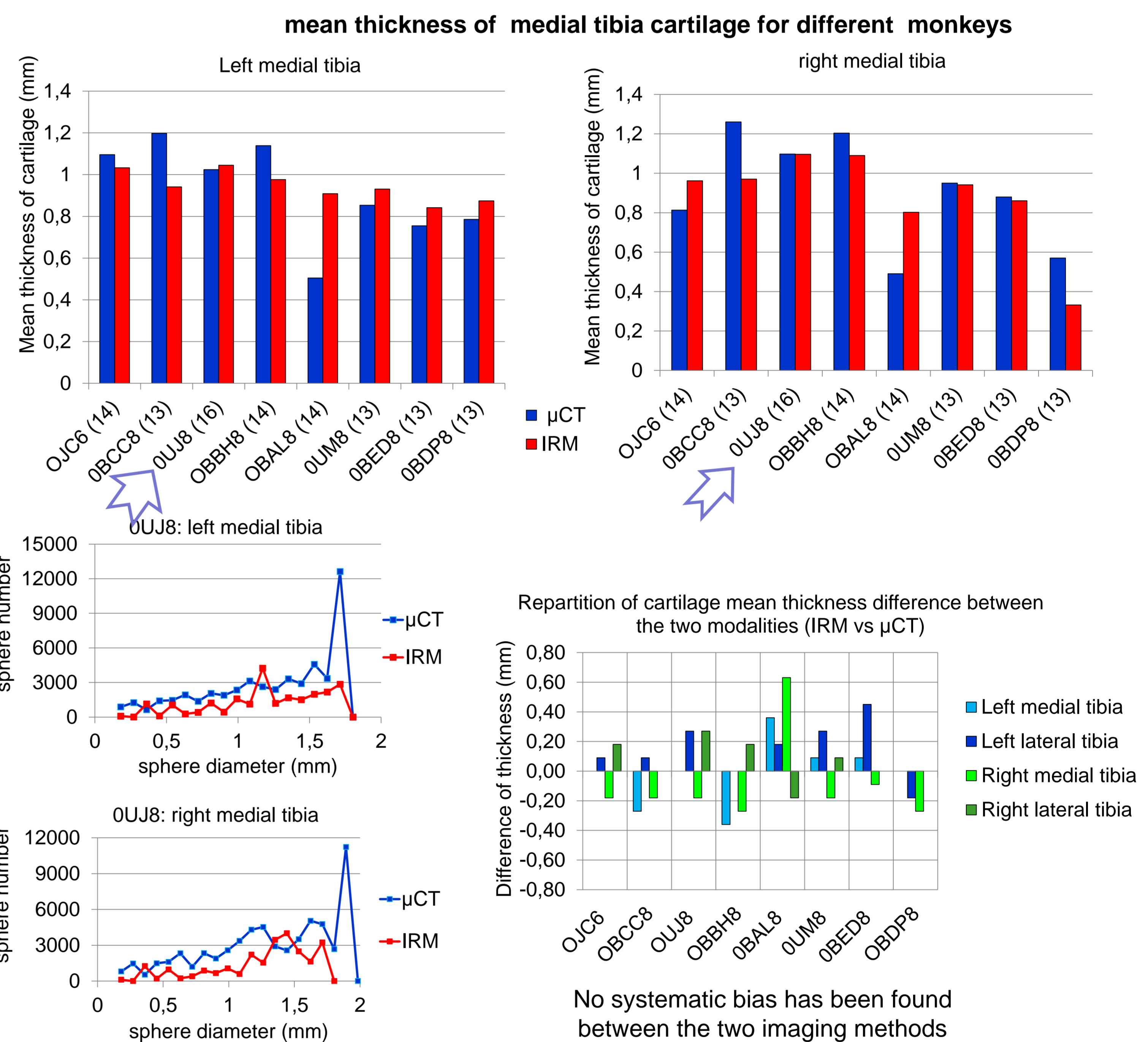
- Contrast agent injected in synovial capsule : Hexabrix 320mg/ml

Reformatted coronal images of the same monkey knee with the two modalities.



### Comparison MRI vs $\mu$ CTA

- manual segmentation
- 3D cartilage thickness measurement with Hildebrandt method [5]



## Conclusion

### MRI acquisitions :

- the dedicated two-channel coils improve significantly the SNR
- the suitable signal uniformity allow a good segmentation process leading to morphological cartilage parameters

### MRI and $\mu$ CTA modalities are valuable to measure cartilage morphology (volume, thickness).

### additional information can be obtained :

- Indirectly about cartilage structure (T2, T1rho...) with MRI
- Subchondral bone density with  $\mu$ CTA

### Perspectives

To validate  $\mu$ CTA method in comparison with MRI and to characterize an induced model of OA by transection of the anterior cruciate ligament (ACL).

### References

- [1] J. Tessier et al., Osteoarthritis Cartilage 11:845-53 (2003).
- [2] R. Bolbos et al., Osteoarthritis Cartilage 15:656-65 (2007)
- [3] A. Rengle et al., IEEE Trans Biomed Eng 56:2891-2897 (2009).
- [4] JC. Goebel et al., Rheumatology 49:1654-1664 (2010).
- [5] Hildebrand et al., J Microsc 185, 67-75(1997).

Acknowledgements: This work is funded by OSEO by grant E! 5671 from the Eurostars European program

