



HAL
open science

Rickettsia sibirica mongolitimonae human infection: a diagnostic challenge

Pierre Rajoelison, Oleg Mediannikov, Emilie Javelle, Didier Raoult, Philippe Parola, Olivier Aoun

► **To cite this version:**

Pierre Rajoelison, Oleg Mediannikov, Emilie Javelle, Didier Raoult, Philippe Parola, et al.. Rickettsia sibirica mongolitimonae human infection: a diagnostic challenge. Travel Medicine and Infectious Disease, 2018, 26, pp.72-73. 10.1016/j.tmaid.2018.07.002 . hal-01970212


HAL Id: hal-01970212

<https://hal.science/hal-01970212>

Submitted on 10 Apr 2019

HAL is a multi-disciplinary open access archive for the deposit and dissemination of scientific research documents, whether they are published or not. The documents may come from teaching and research institutions in France or abroad, or from public or private research centers.

L'archive ouverte pluridisciplinaire **HAL**, est destinée au dépôt et à la diffusion de documents scientifiques de niveau recherche, publiés ou non, émanant des établissements d'enseignement et de recherche français ou étrangers, des laboratoires publics ou privés.



Diagnostic Challenge

Rickettsia sibirica mongolitimonae human infection: A diagnostic challenge

Pierre Rajoelison^a, Oleg Mediannikov^b, Emilie Javelle^{c,d}, Didier Raoult^b, Philippe Parola^d, Olivier Aoun^{a,*}

^a 5th Armed Forces Medical Center, Strasbourg, France

^b Aix Marseille Univ, IRD, AP-HM, MEPHI, IHU-Méditerranée Infection, Marseille, France

^c Infectious and Tropical Diseases Department, Laveran Military Hospital, Marseille, France

^d Aix Marseille Univ, IRD, AP-HM, SSA, VITROME, IHU-Méditerranée Infection, Marseille, France

ARTICLE INFO

Keywords:

Rickettsia sibirica mongolitimonae

Emerging

Tick-borne

Rickettsiosis

Skin swab

qPCR

A 42-year-old female patient, with no prior medical history, and living in Les Pennes-Mirabeau, 20 km north of Marseille, southern France, was admitted to our emergency department, on July 30th, 2016. She had a 5-day history of fever, associated with fatigue, headaches and arthromyalgia. She mentioned an itching maculopapular rash that preceded the fever on July 24th along with two necrotic right upper quadrant skin lesions that were initially vesicular. She reported no recent travel, forest hiking or gardening though she had a garden. She however visited a zoo 2 weeks before onset. She had taken ibuprofen from July 25th to 29th and applied topical mupirocin ointment on the lesions. Upon admission, she had a 38.5 °C temperature, a significant fatigue, two necrotic eschars on the right upper quadrant (Fig. 1) with a painful ipsilateral axillary lymphadenopathy. There was no lymphangitis, abdominal pain, or generalized rash. Laboratory investigations revealed leukopenia (2420/mm³) including neutropenia (1302/mm³) and lymphopenia (840/mm³, thrombocytopenia (105 000/mm³), elevated liver enzymes (122 UI/l AST, 146 UI/l ALT, 101 UI/l GGT, and 151 UI/l ALP) and mild inflammatory syndrome (43.7 mg/l C-Reactive Protein). The detection of serum antibodies against spotted fever group (SFG) rickettsiae, *Coxiella burnetii*, and *Bartonella henselae*, performed as previously described by Fournier et al., was negative. DNA samples, obtained from eschar swabs, tested positive using qPCR with genus-specific primers and probes targeting a fragment of the *gltA* and *ompA* genes of all spotted fever group Rickettsia species. Subsequently, positive samples were tested with species-specific *R. massiliae*, *R. conorii conorii* and *R. sibirica mongolitimonae* primers and probes. The infection

was thus definitely documented to *Rickettsia sibirica mongolitimonae*. Other qPCR testing on eschar swabs, performed as described by Morand et al., ruled out *Bartonella* sp, *Borrelia* sp, *Coxiella burnetii*, *Leishmania* sp, *Francisella tularensis*, *Treponema pallidum*, *Streptococcus pyogenes*, *Staphylococcus aureus*, *Orthopoxvirus*, *Parapoxvirus* and *Coxiella* like endosymbionts. Patient initially received an empirical 100 mg bid doxycycline treatment that was pursued for a total of 10 days following the PCR diagnosis confirmation. Outcome was favorable with a complete recovery.

Rickettsia sibirica mongolitimonae was historically isolated from *Hyalomma asiaticum* ticks collected in Inner Mongolia in 1991 and the first human case of this SFG rickettsiosis was reported in France in 1996. Potential vectors include ticks of the genus *Hyalomma* and also *Rhipicephalus pusillus*, a species of tick found on the European wild rabbit (also can be found on wild carnivorous animals, dogs, and domestic cats), which may bite humans. In Europe, *R. sibirica mongolitimonae* was detected in *Hyalomma excavatum* ticks in Greece and Cyprus; in *Rhipicephalus pusillus* ticks in France, Portugal, and Spain; and in *Rhipicephalus bursa* ticks in Spain. In Turkey, it was also detected in *Rhipicephalus bursa*, *Haemaphysalis parva*, *Hyalomma excavatum*, and *Hyalomma marginatum*. This latter tick is also present in Corsica and South of France. In Israel, it was isolated in *Hyalomma turanicum*. Less than 40 human cases of *R. sibirica mongolitimonae* have been reported, for the great majority in Mediterranean (France, Spain, Portugal, Greece, and Turkey) and African countries (Algeria, Egypt, Cameroon, and South Africa). Due to the ropelike lymphangitis sign, between the

* Corresponding author.

E-mail address: olivier.aoun@gmail.com (O. Aoun).

<https://doi.org/10.1016/j.tmaid.2018.07.002>

Received 26 June 2018; Received in revised form 5 July 2018; Accepted 9 July 2018

Available online 14 July 2018

1477-8939/ © 2018 Elsevier Ltd. All rights reserved.

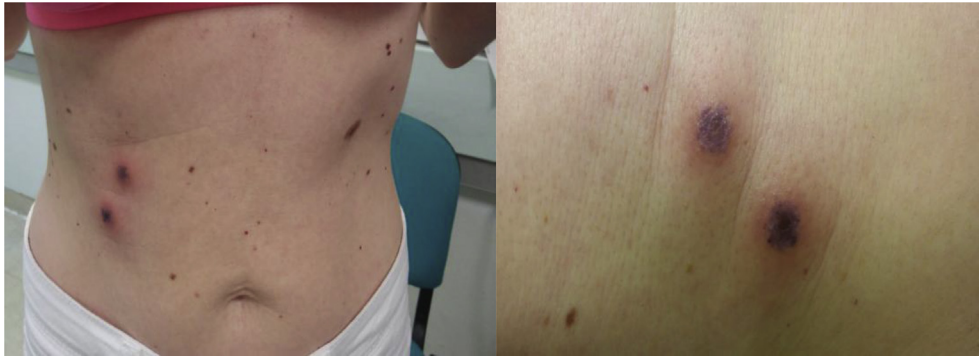

Fig. 1. The two abdominal inoculation eschars.

inoculation eschar and lymphadenitis, it was named lymphangitis-associated Rickettsiosis (LAR), though this clinical feature was inconsistently described. Typical clinical signs include fever (100%), headache (86%), myalgia (90%), cutaneous rash (77%), enlarged lymph nodes (71%) and/or lymphangitis (43%), and single or multiple inoculation eschars (92%)¹. A history of tick bite is reported in less than 50% of cases. Most of the cases occur in spring and summer, probably due to the activity of the tick vectors. No fatal case has been observed, but complications such as retinal vasculitis, lethargy with hyponatremia, septic shock, myopericarditis, and acute renal failure, have been described.

The most available tools for the diagnosis of tick-borne rickettsioses are serological assays, including immunofluorescence, the reference method. However, serology is limited by cross-reactions and frequent negative results during the acute stages. In the recent years, PCR and qPCR-based methods on skin biopsy and swab samples have been shown to be highly sensitive and specific tests. Testing on swab samples

is to be preferred as it is simpler, painless, and gives faster results than on skin biopsy. The use of these molecular methods will probably lead in the future to an increased documentation of *R. sibirica mongolitimonae* infections. This emerging rickettsiosis is probably underdiagnosed and mistaken for the other SFG rickettsioses such as *R. conorii conorii* infection, the agent of Mediterranean spotted fever.

Conflicts of interest

We wish to confirm that there are no known conflicts of interest associated with this publication and there has been no significant financial support for this work that could have influenced its outcome.

Acknowledgements

This work received no funding from any organization (including grant).