



HAL
open science

Fixation augmentation using calcium-phosphate bone substitute improves outcomes of complex tibial plateau fractures. A matched, cohort study

Matthieu Ollivier, Yassine Bulaid, Christophe Jacquet, Sebastien Pesenti, Jean-Noël Argenson, Sebastien Parratte

► **To cite this version:**

Matthieu Ollivier, Yassine Bulaid, Christophe Jacquet, Sebastien Pesenti, Jean-Noël Argenson, et al.. Fixation augmentation using calcium-phosphate bone substitute improves outcomes of complex tibial plateau fractures. A matched, cohort study. *International Orthopaedics*, 2018, 42 (12), pp.2915-2923. <10.1007/s00264-018-3926-7>. <hal-01960521>

HAL Id: hal-01960521

<https://hal.science/hal-01960521v1>

Submitted on 17 Apr 2019

HAL is a multi-disciplinary open access archive for the deposit and dissemination of scientific research documents, whether they are published or not. The documents may come from teaching and research institutions in France or abroad, or from public or private research centers.

L'archive ouverte pluridisciplinaire **HAL**, est destinée au dépôt et à la diffusion de documents scientifiques de niveau recherche, publiés ou non, émanant des établissements d'enseignement et de recherche français ou étrangers, des laboratoires publics ou privés.



HAL Authorization

Fixation augmentation using calcium-phosphate bone substitute improves outcomes of complex tibial plateau fractures. A matched, cohort study

Matthieu Ollivier^{1,2,3} & Yassine Bulaïd^{1,2,3} & Christophe Jacquet^{1,2,3} & Sebastien Pesenti^{1,2,3} & Jean-noel Argenson^{1,2,3} & Sebastien Parratte^{1,2,3}

Abstract

Introduction Injectable cements have been developed to improve fixation's stability and thus obtain early return to adequate joint function. We aimed to compare post-operative radiographic and clinical outcomes of patients suffering from a complex tibial plateau fracture (TPF) fixed with calcium-phosphate bone substitutes (CPBS) augmentation to a matched group of patients with identical fracture pattern, treated with the same fixation's type, but augmented with bone grafting.

Methods After local ethic committee approval, we retrospectively identified in a prospectively collected database, patients with complex comminuted metaphyseal and epiphysal bicondylar TPF (Schatzker type VI) admitted in our emergency department between January 2011 and December 2013. From those, 23 patients (14 males, 9 females) were treated with CPBS (Quickset-CP®, Graftys, Aix-en-Provence, France) fixation augmentation. Patients' mean age were 44.4 years. We then created a control group using a 1:1 matching process on gender, age, fracture pattern, and method of fixation. Patients were evaluated prospectively at 3, 6, and then every six months using radiographic (AP/ML views) and clinical criteria (knee osteoarthritis outcomes score (KOOS) and EuroQOL-5D).

Results Articular step-off and variation of articular step-off were significantly lower in the CPBS groups (mean step-off 1.4 ± 1.9 (0.5–6.5 mm) and mean step-off $\Delta = 0.3 \pm 0.4$ (0.5–2.2 mm)) than in the control group (mean step-off 3.6 ± 2.1 (1–7.5 mm) and mean step-off $\Delta = 2.2 \pm 2$ (0.5–7 mm) $p < 0.01$). At last follow-up, patients of the control group presented a higher rate of step-off > 2 mm and step-off $\Delta > 2$ mm (respectively, 56 and 35%) than patients of the CPBS group (26 and 9%). Odd ratio of, respectively, 3.6 (95% CI (1.08–12.7) and $p = 0.03$) and 5.6 (95% CI (1.04–30.1) and $p = 0.03$). At mean follow-up of 29 months, KOOS pain subscore was significantly better in patients of the CPBS group (85.3 ± 12.1) than in control patients (74.2 ± 10.4 and $p = 0.03$).

Conclusion The present study demonstrates that calcium-phosphate bone substitute used as synthesis augmentation improves mid-term radiological outcomes of patients suffering from complex tibial plateau fracture. Series reporting outcomes from a larger number of patients and longer follow-up must confirm clinical benefits and safety of this method.

Keywords Tibial Plateau Fractures · Augmentation · Osteosynthesis · Phosphocalcic cement · Clinical outcomes · CT-Scan

Introduction

Tibial plateau fractures (TPF) are complex intra-articular and metaphyseal lesions, accounting for 5–8% of all fractures of the lower leg [1]. To prevent post-traumatic arthritis and stiffness, ideal management of those fractures must provide both an anatomical restoration of the joint surfaces to protect articular cartilage and a rigid fixation to permit early rehabilitation [2–4]. Various treatment modalities can be used for the management of comminuted and/or depressed TPF. Conventional plate fixation with a single incision requires invasive exposure of the fracture zone, potentially harmful to soft tissue and

* Matthieu Ollivier
ollivier.matthieu@yahoo.fr

¹ Investigation performed at St. Marguerite Hospital, Aix-Marseille University, Marseille, France

² APHM, Institut du mouvement et de l'appareil locomoteur, Department of Orthopaedic Surgery, Sainte-Marguerite Hospital, 13009 Marseille, France

³ CNRS, ISM UMR 7287, Aix-Marseille University, 13009 Marseille, France

epiphyseal vascularization, thus compromising post-operative outcome [5].

To reduce soft tissue complications and deep infections, external fixation have been advocated; however, this technique is associated with high rates of non-union and pin track infections [6–8]. Recent developments in the techniques of internal fixation, including development of locked plating with raft screws and minimal invasive techniques have substantially decreased the complication rates observed [9–13]. However, secondary loss of reduction remains a thorny issue [14–17]. Injectable cements have been developed to improve fixation's stability and thus obtain early return to adequate joint function [14]. Several recent studies have demonstrated that calcium-phosphate bone substitutes (CPBS) has a superior capability than cancellous bone grafts to prevent articular subsidence [18–21]. We hypothesized that the use of CPBS instead of bone grafting in complex TPF would prevent from articular subsidence.

In this study, we aimed to compare post-operative radiographic and clinical outcomes of patients, suffering from a complex TPF (Schatzker VI), fixed with CPBS augmentation to a matched group of patients with identical fracture pattern, treated with the same fixation's type, but augmented with bone grafting.

Patients and methods

After local ethic committee approval, we retrospectively identified in a prospectively collected database, patients with complex comminuted metaphyseal and epiphysial bicondylar TPF (Schatzker type VI, AO/OTA type 41 C2 and C3) admitted in our emergency department between January 2011 and December 2013. For this study, inclusion criteria were patients age between 18 and 85 years, presenting an acute, closed, bicondylar metaphyseal, and epiphysial multi-fragmentary (Schatzker type VI, AO/OTA type 41 C2 and C3) TPF. The exclusion criteria were skeletally immature patients, pathological fractures, and significant pre-existing degenerative joint disease, severe systemic illness that contraindicated surgery or a neurological condition that would interfere with rehabilitation.

From the 67 patients meeting both inclusion and exclusion criteria, we then identified 23 TPF treated with a CPBS (injectable resorbable Bone substitute, Quickset-CP®, Graftys, Aix en provence, France) fixation augmentation. Patients mean age was 44.4 ± 10.7 years (18–71), 14 of them being males and nine females.

In the same database, a control group of patients were selected for having similar inclusion criteria but a different osteosynthesis augmentation based on allogeneic or autogeneic bone grafting. Those control patients were then included following a 1:1 matching process on gender, age (± 5 years), fracture pattern (AO classification), and type of

fixation (dual plates or plate + screws).

A tourniquet was routinely used during synthesis procedures; all patients were operated-on in a supine position, with the injured leg in semiflexion. Twenty-one patients had surgery performed within 48 h. A staged protocol for soft tissue management was used in the other 25 patients; the fracture was initially stabilized using transcalfaneal traction device and converted to open reduction and internal fixation (ORIF) after the skin wrinkle sign was observed as described by Egol et al. [22]. In both groups, all surgeries consisted of the following standardized surgical steps in each case: (1) As recommended by Freeman et al. [23], medial column restoration was performed first with either a medial incision starting on posteromedial border of the tibial metaphysis or a more central incision centered on the tibial tuberosity. (2) Reduction of the fragment and temporary fixation was done using K-wires. (3) The surgeon decided either to fix the fracture using a locking plate (LCP® Depuy-synthes Inc., Warsaw, IN, USA or Perilocking® Zimmer Inc., Warsaw, IN, USA) or screws depending on the fracture pattern. (4) An anterolateral approach (through either a second skin incision or the same central incision) of the lateral articular surface was then performed including a transverse submeniscal arthrotomy allowing direct visualization of the articular surface's reduction. (5) Depressed fragments were elevated and supported with a compression clamp or temporary K-wires to obtain anatomic reduction. (6) As on the medial side and depending on the fracture pattern, a locking plate (LCP® Depuy-synthes Inc., Warsaw, IN, USA) or Perilocking® Zimmer Inc., Warsaw, IN, USA) or cannulated cancellous bone screws were used. (7) Meniscus, cruciate ligaments, and tibial spines injuries were repaired when possible. (8) Augmentation of the fixation was performed using 16 cm³ of CPBS or morcelized bone allograft or autograft to fill the metaphyseal defect. (9) Finally, watertight closures were performed in layers with drain aloof from the grafted zone. Fluoroscopy was used at each step to assess reduction.

All patients had a similar postoperative regimen: the post-operative mobilization scheme included toe-touch weight bearing using two crutches for four to six weeks, followed by progressive increase to obtain a full-weight bearing at three months; active knee motion was encouraged on the third day after surgery. Thromboprophylaxis (low molecular weight heparin (tinzaparin 4.500 IU)) was administered in subcutaneous route post-operatively until full weight bearing was authorized. The first injection was performed at the hospital the day after the operation and then by a nurse at home or in the rehabilitation facility (Figs. 1, 2, 3, 4, 5 and 6).

The data collection pre-operatively included demographics, mechanism of injury, initial fracture pattern, time to surgery, and method of fixation (Table 1).

Patients were evaluated prospectively at three, six and then every six months. Radiographic outcomes were assessed using weight-bearing (when possible) anterior-

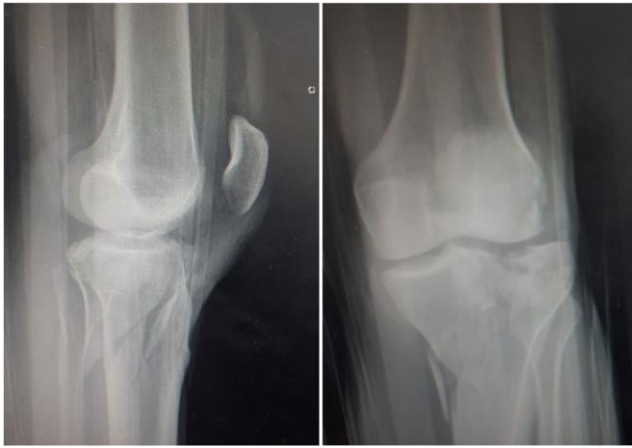

Fig. 1 should appear at the end of methods part. thanks... Clinical case: 40-year-old patient. Closed Schatzker 6 TPF. Pre-operative x-rays

full-weight bearing and radiological union as the presence of bridging callous of two cortices visible on two x-ray views (evidence of presence of bone healing by direct or indirect means in at least two planes on x-ray). Potential articular step(s)-off, medial proximal tibial angle (MPTA), posterior proximal tibial angle (PPTA), tibial plateau widening (TPW), existence of post-traumatic arthritis, and structural void filler support were noticed and summarized using Heyney-Redfern (H-R) scale at last available follow-up [24]. Patients were also evaluated clinically in order to identify treatment complication and appreciate range of motion,

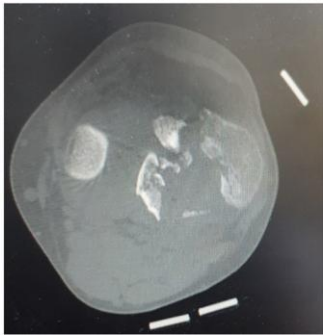
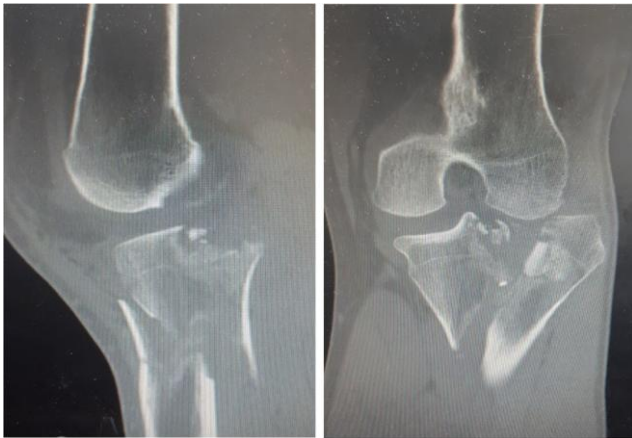

Fig. 2 Clinical case: 40-year-old patient. Closed Schatzker 6 TPF. Pre-operative CT SCAN

rehabilitation using the knee osteoarthritis outcomes score (KOOS) and EuroQOL-5D [25, 26].

This study sample size (min 20 patients/groups) was designed to detect a 2-mm difference (reported standard deviation 2.5 mm) in terms of articular step-off between groups with $\alpha = 0.05$ and $1-b = 0.8$.

Normality of distributions was tested using Kolmogoroff-Smirnoff test; parametric tests were used to compare normally distributed parameters (paired student *t* test: demographic parameters, radiological outcomes); Wilcoxon tests were used to compare clinical scores; and Fisher exact tests were used to compare categorical parameters. All statistical analysis assumed two-tailed test, PASW Statistics version 20 (SPSS, IBM Inc., Chicago, Illinois) was used. The threshold for statistical significance was set at $p < 0.05$.

Results

No patient was lost to follow-up at mean follow-up 29.3 ± 11.2 months (12-44).

Radiographic outcomes

Post-operatively and at last follow-up, we found no difference between groups in terms of MPTA, PPTA, structural void

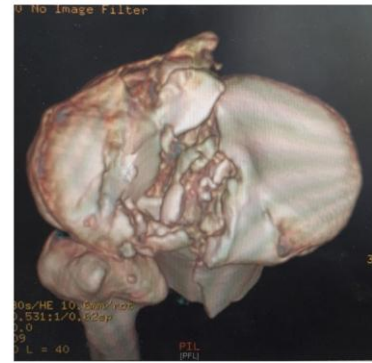
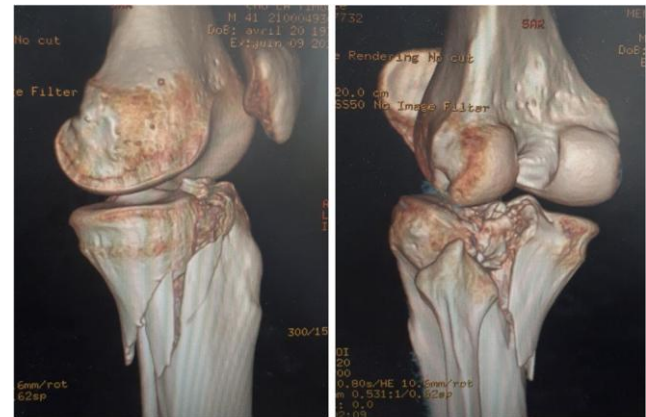


Fig. 3 Clinical case: 40-year-old patient. Closed Schatzker 6 TPF. Pre-operative CT SCAN: 3D reconstructions

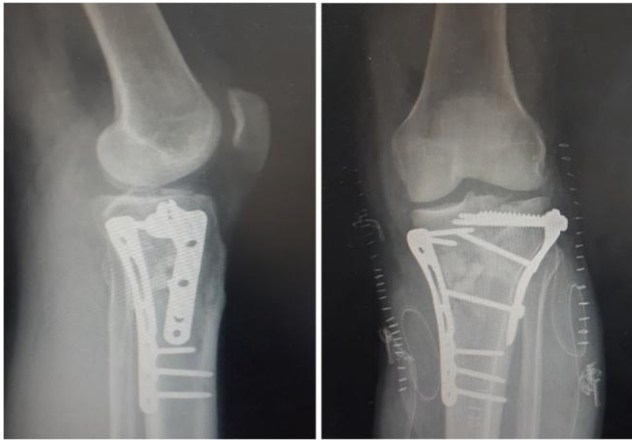


Fig. 4 Clinical case: 40-year-old patient. Closed Schatzker 6 TPF. Post-operative x-rays

support, TPW, or evidence of arthritis (Tables 2 and 3). However, articular step-off and variation (post-operative to last follow-up) of articular step-off were significantly lower in the CPBS groups (mean step-off 1.4 ± 1.9 (0.5–6.5 mm) and mean step-off $\Delta = 0.3 \pm 0.4$ (0.5–2.2 mm)) than in the control group ((mean step-off 3.6 ± 2.1 (1–7.5 mm) and mean step-off $\Delta = 2.2 \pm 2$ (0.5–7 mm) and both $p < 0.01$).

The mean H-R score was 12.3 ± 3.8 points in the CPBS group at the time of the last radiographic evaluation.

At last follow-up, patients of the control group presented a higher rate of step-off > 2 mm (56%) than patients of the CPBS group (26%), odd ratio 3.6 (95% CI (1.08–12.7) and $p = 0.03$).

At last follow-up, patients of the control group presented a higher rate of step-off delta > 2 mm (35%) than patients of the CPBS group (9%), Odd ratio 5.6 (95% CI (1.04–30.1) and $p = 0.03$).

Clinical outcomes

At mean follow-up 29 months, KOOS symptoms, activity of daily living, sports/recreational activities, and quality of live

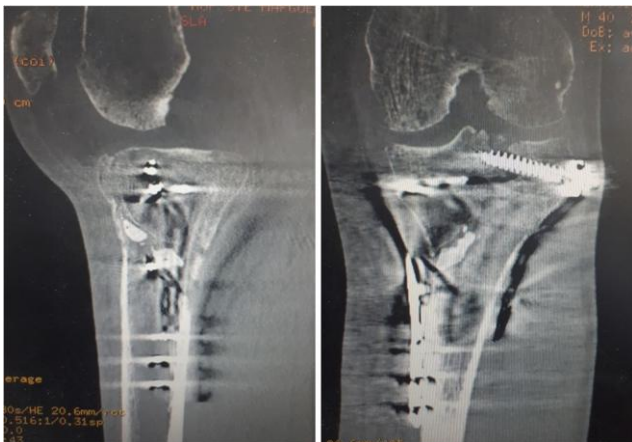

Fig. 5 Clinical case: 40-year-old patient. Closed Schatzker 6 TPF. CT SCAN at last follow-up

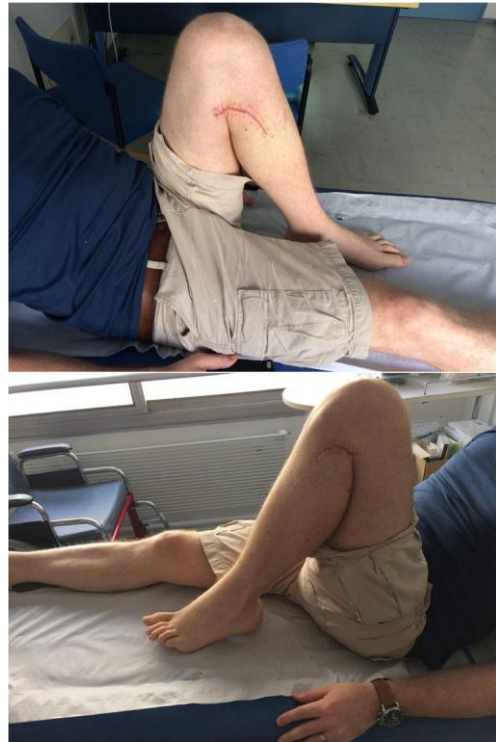

Fig. 6 Clinical case: 40-year-old patient. Closed Schatzker 6 TPF. Photographs illustrating the range of motion at last follow-up

subscores as well as EuroQOL-5D evaluations were similar in both groups (Table 4). We found significant difference between groups in terms of KOOS pain subscore, as patients of the CPBS group presented lower pain score (85.3 ± 12.1 range (50–100)) than control patients (74.2 ± 10.4 (45–100), $p = 0.03$). All of the patients with ongoing professional activities before the trauma (34 patients) have resumed their professional activities at least one year after surgery.

Complication

We found no difference in terms of complications rate (CR) between CPBS group (CR = 22%; 5/23) and control group (CR = 17%; 4/23) ($p = 0.4$). Superficial wound infection occurred in five cases (three in CPBS group and two in control group, all of them were classified as Tscherne grade 2 or more), all patients were managed and healed with a course of oral antibiotics for a week. Deep infection occurred in two patients; the first case was a 40-year-old male of the CPBS group with persistent wound drainage 15 days after trauma which was treated with debridement (a methy-S staph. Aureus was found), and antibiotic course for six weeks (bone union was achieved radiologically and clinically at 5 months). The second patient was a 51-year-old active smoker, female, that presented a non-union and wound complication six months after trauma due to the deep infection (bone biopsy revealed a Methy-S staph. Aureus deep infection); she was

Table 1 Pre-operative patients' demographics, fracture patterns, and procedure details

Parameters		CBPS group (n=23)	Control group (n=23)	p value
Age (years)		43.9± 10.3 (21-72)	44.8 ± 11.3 (18-71)	0.7
Gender (M/F)		14/9	14/9	NA
Fracture pattern	AO 41 C2	17	17	NA
	AO 41 C3	6	6	
Tscherne classification	0	2	1	0.5
	1	10	12	
	2	8	8	
	3	3	2	
Mechanism of injury		Sport: 9 Vehicle collision: 13 Fall: 1	Sport: 7 Vehicle collision: 16	0.5
Time to surgery (days)		4.7 ± 3.9 (0-11)	3.9 ± 4.6 (0-14)	0.3
Patients with time to surgery < 48 h		10	11	
Fixation				0.8
Dual plating		14	13	
Plate + screws		9	10	
Augmentation type		CBPS 23	Bone allograft 10 Bone autograft 13	NA

treated with debridement, plate removal, and external fixator for six weeks, then treated as a septic bone non-union. We found two cases of thromboembolic complications in this

series (one in each group, both were deep vein thrombosis that required curative treatment based on low molecular weight heparin (tinzaparin 10.000 IU).

Table 2 post-operative radiographic analysis

Parameters	CBPS	Control	p value
Articular step-off (mm)	1.1 ± 1.2 (0.5-6)	1.4 ± 1.5 (0.5-5)	0.7*
Number	18	17	0.2 [#]
<2 mm	4	6	
2 - 5 mm	1		
>5 mm			
MPTA (°)	87.2 ± 7.1 (78-92)	86.4 ± 9.1 (77-92)	0.6*
Number	17	16	0.8 [#]
85°-90°	5	6	
80°-84° or 91°-94°	1	1	
< 80° or > 94°			
PPTA (°)	7.1 ± 4.3 (1-10)	7.6 ± 3.7 (3-10)	0.4*
Number			
6°-12°	15	17	0.7 [#]
3°-5° or 13°-15°	7	6	
< 3° or > 15°	1		
Structural void support			
Number			
Sufficient	19	15	0.2 [#]
Partial	4	7	
Insufficient		1	
Time to union (months)	5.2 ± 1.1 (4-7)	4.8 ± 1.5 (3-7)	0.6*

Articular step-off: If more than one, due to fragmentation, the biggest one is reported here

MPTA medial proximal tibial angle, PPTA posterior proximal tibial angle

* Paired student *t* test

[#] Exact 2 × 3 Fisher

Parameters	CBPS	Control	<i>p</i> value
Articular step-off (mm)	1.4 ± 1.9 (0.5–6.5 mm)	3.6 ± 2.1 (1–7.5 mm)	0.001*
Variation Δ (mm)	0.3 ± 0.4 (0.5–2 mm)	2.2 ± 2 (0.5–7 mm)	0.0001*
Number			
< 2 mm	17	10	0.08 [#]
2 – 5 mm	5	11	
>5 mm	1	2	
MPTA (°)	86.5 ± 7.3 (77–92)	85 ± 9.3 (77–91)	0.09*
Variation Δ (mm)	0.8 ± 0.7 (0–2)	1.2 ± 1.1 (0–4)	0.1*
Number			
85°–90°	16	15	0.9 [#]
80°–84° or 91°–94°	5	5	
< 80° or > 94°	2	3	
PPTA (°)	7.3 ± 4.1 (3–10)	8.1 ± 3.4 (4–12)	0.3*
Variation Δ (mm)	0.2 ± 0.5 (0–2)	0.7 ± 0.8 (0–3)	0.8 [#]
Number			
6°–12°	15	16	
3°–5° or 13°–15°	7	7	
< 3° or > 15°	1		
Structural void support			
Number			
Sufficient	18	13	0.1 [#]
Partial	5	9	
Insufficient		2	
Global tibial plateau widening (mm)	1 ± 1.2 (0–3)	1.3 ± 1.4 (0–3.5)	0.7
Post-traumatic arthritis (nb)	1	2	0.6

Articular step-off: if more than one, due to fragmentation, the biggest one is reported here

Tibial plateau widening: variation of the distance measured between two parallel lines (both perpendicular to the joint line) that pass from the most lateral and most medial part of the tibial plateau

MPTA medial proximal tibial angle, PPTA posterior proximal tibial angle

*Paired student *t* test

[#] Exact 2 × 3 Fisher

Table 4 Clinical outcomes evaluation at last follow-up

Scores	Parameters	CPBS group	Control group	<i>p</i> value
KOOS (points)	Pain	85.3 ± 12.1 (50–100)	74.2 ± 10.4 (45–100)	0.03
	Symptoms	82.4 ± 7.4 (55–100)	77.1 ± 6.5 (50–100)	0.06*
	ADL	84.1 ± 12.7 (65–100)	80 ± 11.4 (55–100)	0.2*
	Sports	65.5 ± 12.4 (35–100)	61.4 ± 15.3 (35–100)	0.2*
	QOL	71.8 ± 9.5 (65–100)	68.9 ± 11.4 (55–100)	0.3*
EuroQOL 5D	Health state scale (points)	91 ± 12 (80–100)	85 ± 9 (74–100)	0.07*
	Mobility (number – %)	3	5	0.6
	Self-care (number – %)	0	1	1
	Usual activities (number – %)	3	4	1
	Pain (number – %)	5	11	0.1
	Anxiety depression (number – %)	1	3	0.6

For EuroQOL-5D, numbers (%) reported are number of patients that report moderate to extreme issues regarding the parameters

KOOS knee injury and osteoarthritis outcome score, ADL activity of daily living, QOL quality of life

Discussion

The main finding of this study is that TPF treated with ORIF and CPBS augmentation result in better radiological outcomes than TPF operated-on with the same synthesis but augmented with bone grafting.

Several limitations can be outlined in our study. First, the retrospective design of the series limits extrapolation of our results, but the prevalence of Schatzker VI tibial fracture in the general population also limits a prospective data collection with a sufficient number of patients. Our sample size allowed us to compare radiological parameters between groups but might be not enough to evaluate clinical outcomes, morbidity, and revision rate. We performed a secondary power analysis, and our sample size was sufficient to detect the minimum clinically important differences regarding KOOS and EuroQOL scoring system. Moreover, we did not randomize fixation and augmentation process, but retrospectively matched patient based on surgeons' decision during surgery. Thus, patients were selected to receive one- or two-stage operative fixation based on the severity of their soft tissue presentation more than from a protocol decision. Complex TPF management is quite impossible to systematize due to their different clinical and radiological presentations.

Concerning the modality of bone grafting in the control group, our extensive use of allogeneic bone graft to fill bone loss in knee revision have led some surgeons in our institution

to propose it as an alternative to autologous bone graft in case of complex bone trauma as presented in this study. This duality led to potential bias due to two different types of graft in the control group.

We intended to evaluate post-operative outcomes of patients suffering from Schatzker VI tibial fracture, depending on the type of bfixation augmentation^ techniques (CPBS and bone grafting). Regarding radiological outcomes, we found that mean articular step-off was significantly lower, at a mean follow-up of 29 months, in the CPBS groups than in the control group. Some authors have shown that resorbable calcium-phosphate cement provides more support of the articular surface than does cancellous bone grafting. Two cadaveric studies demonstrated that in Schatzker type-II fracture, the rate of displacement was 68% lower for subchondral defects filled with calcium-phosphate cement than for those filled with cancellous bone graft. In an animal model, Welch et al. [27] also concluded that collapse and resorption of the autogenous graft material occurred almost immediately in the post-operative period, conducting to an articular collapse and a fixation failure. The collapse was significantly lower with calcium-phosphate cement compared to cancellous bone grafting ($p < 0.05$). Our results are also consistent with recent literature comparing these two types of augmentations [14, 19]. Our results are poorer regarding the rate of articular step-off > 2 mm, as compared to the Russel et al. and Simpson et al. study. However, we included only Schatzker 6 fractures while

Table 5 Results of different series from the literature

Studies	Series	Mean Age (range)	FU	Type of fracture	Radiographic analysis	Infection rate
Simpson et al. [14]	26 patients: - 13 BG - 13 CBPS (SRS)	51.5 (21-71)	12 months	AO: B2.2 = 3, B3.1 = 10	Mean step-off = 4 vs 0.7 mm	0%
Trenholm et al. [18]	20 specimens: - 10 autogreffes - 10 CBPS (BSM)			Schatzker: I = 1, II = 52, III = 26, IV = 11, V = 28, VI = 2	Mean step-off: 3.8 vs 1.2 mm	
Russel et al. [19]	119 patients: - 38 BG - 82 CBPS	43	12 months		Step-off > 2 mm: 30 vs 9%	1.2%
Bajammal et al. (meta-analysis) [20]	455 patients	N/A		Schatzker: I = 1, II = 52, III = 26, IV = 11, V = 28, VI = 2	Reduction failure: CPBS vs BG RR 0.7	n/a
Goff et al. (meta-analysis) [21]	672 patients	50 (15-89)			Step-off > 2 mm: - 8.6% bone substitute - 5.4% HA - 3.7% CPBS - 11% calcium sulfate	Stratified by graft type: - 3.4% bone substitute - 5.4% HA - 2.9% CPBS - 5.4% calcium sulfate
Our study	46 patients: - 23 BG - 23 CPBS	44.4 (18-71)	29 months	Schatzker VI = 46	Step-off > 2 mm: 56% BG 26% CBPS	15%

these two authors studied all type of fractures [14, 19] of which only a few complex TPF ($n = 2$ for Russel et al. [19], $n = 0$ for Simpson et al. [14]). Our follow-up was 29 months while the mean follow-up of these two studies was one year.

With the number available, we did not find any difference between groups regarding clinical outcomes (except for pain subscore of the KOOS), these results are consistent with the literature, as no study demonstrates clinical superiority of re-sorbable cement on autologous bone grafting. However, diversity of scoring systems used by other authors complicates comparison of our clinical outcomes [20, 21]. The results of these studies are summarized in Table 5.

The total complication rates were similar between groups in our retrospective evaluation; high rate of complications have been described based on initial soft tissue damage and fixation technique. Deep wound infection is often observed in patients with high energy trauma: with dual plates through two incisions in the series of Jiang et al., an incidence of 4.7% deep infection was reported [28]. Despite using staged management with a temporary traction wire in high-risk patients, we found seven sepsis in our series: five superficial and two deep infections.

The present study demonstrates that calcium-phosphate bone substitute used as synthesis augmentation improves mid-terms radiological outcomes of patients suffering from complex TPF. Series reporting outcomes from a larger number of patients and longer follow-up must confirm clinical benefits and safety of this method as compared to autologous bone grafting.

Compliance with ethical standards

This article does not contain any studies with human participants performed by any of the authors. Informed consent was obtained from all individual participants included in the study.

Conflict of interest The authors declare that they have no competing interests.

References

1. Petersen W, Zantop T, Raschke M (2006) Fracture of the tibial head. *Unfallchirurg* 109:219–232; quiz 233–234. <https://doi.org/10.1007/s00113-006-1066-9>
2. Manidakis N, Dosani A, Dimitriou R et al (2010) Tibial plateau fractures: functional outcome and incidence of osteoarthritis in 125 cases. *Int Orthop* 34:565–570. <https://doi.org/10.1007/s00264-009-0790-5>
3. Dang AC, Kim HT (2009) Chondrocyte apoptosis after simulated intraarticular fracture: a comparison of histologic detection methods. *Clin Orthop* 467:1877–1884. <https://doi.org/10.1007/s11999-009-0829-3>
4. Rademakers MV, Kerkhoffs GMMJ, Sierevelt IN et al (2007) Operative treatment of 109 tibial plateau fractures: five- to 27-year follow-up results. *J Orthop Trauma* 21:5–10. <https://doi.org/10.1097/BOT.0b013e31802c5b51>
5. Hannouche D, Duparc F, Beaufile P (2006) The arterial vascularization of the lateral tibial condyle: anatomy and surgical applications. *Surg Radiol Anat* 28:38–45. <https://doi.org/10.1007/s00276-005-0044-1>
6. Messina M, Herbert B, Mauffrey C (2013) The use of arthroscopy to assist reduction of depressed tibial plateau fractures. *Curr Orthop Pract* 24:160–164. <https://doi.org/10.1097/BCO.0b013e318286d227>
7. Siegler J, Galissier B, Marcheix P-S et al (2011) Percutaneous fixation of tibial plateau fractures under arthroscopy: a medium term perspective. *Orthop Traumatol Surg Res* 97:44–50. <https://doi.org/10.1016/j.otsr.2010.08.005>
8. Biggi F, Di Fabio S, D'Antimo C, Trevisani S (2010) Tibial plateau fractures: internal fixation with locking plates and the MIPO technique. *Injury* 41:1178–1182. <https://doi.org/10.1016/j.injury.2010.08.001>
9. Young MJ, Barrack RL (1994) Complications of internal fixation of tibial plateau fractures. *Orthop Rev* 23:149–154
10. Basques BA, Webb ML, Bohl DD et al (2015) Adverse events, length of stay, and readmission after surgery for tibial plateau fractures. *J Orthop Trauma* 29:e121–e126. <https://doi.org/10.1097/BOT.0000000000000231>
11. Chen X-Z, Liu C-G, Chen Y et al (2015) Arthroscopy-assisted surgery for tibial plateau fractures. *Arthrosc J Arthrosc Relat Surg Off Publ Arthrosc Assoc N Am Int Arthrosc Assoc* 31:143–153. <https://doi.org/10.1016/j.arthro.2014.06.005>
12. Belanger M, Fadale P (1997) Compartment syndrome of the leg after arthroscopic examination of a tibial plateau fracture. Case report and review of the literature. *Arthrosc J Arthrosc Relat Surg Off Publ Arthrosc Assoc N Am Int Arthrosc Assoc* 13:646–651
13. Dall'Oca C, Maluta T, Lavini F et al (2012) Tibial plateau fractures: compared outcomes between ARIF and ORIF. *Strateg Trauma Limb Reconstr* 7:163–175. <https://doi.org/10.1007/s11751-012-0148-1>
14. Simpson D, Keating JF (2004) Outcome of tibial plateau fractures managed with calcium phosphate cement. *Injury* 35:913–918. [https://doi.org/10.1016/S0020-1383\(03\)00109-8](https://doi.org/10.1016/S0020-1383(03)00109-8)
15. Weigel DP, Marsh JL (2002) High-energy fractures of the tibial plateau. Knee function after longer follow-up. *J Bone Joint Surg Am* 84-A:1541–1551
16. Lachiewicz PF, Funcik T (1990) Factors influencing the results of open reduction and internal fixation of tibial plateau fractures. *Clin Orthop*:210–215
17. Lefkoe TP, Walsh WR, Anastasatos J et al (1995) Remodeling of articular step-offs. Is osteoarthritis dependent on defect size? *Clin Orthop*:253–265
18. Trenholm A, Landry S, McLaughlin K et al (2005) Comparative fixation of tibial plateau fractures using alpha-BSM, a calcium phosphate cement, versus cancellous bone graft. *J Orthop Trauma* 19:698–702
19. Russell TA, Leighton RK, Alpha-BSM Tibial Plateau Fracture Study Group (2008) Comparison of autogenous bone graft and endothermic calcium phosphate cement for defect augmentation in tibial plateau fractures. A multicenter, prospective, randomized study. *J Bone Joint Surg Am* 90:2057–2061. <https://doi.org/10.2106/JBJS.G.01191>
20. Bajammal SS, Zlowodzki M, Lelwica A et al (2008) The use of calcium phosphate bone cement in fracture treatment. A meta-analysis of randomized trials. *J Bone Joint Surg Am* 90:1186–1196. <https://doi.org/10.2106/JBJS.G.00241>
21. Goff T, Kanakaris NK, Giannoudis PV (2013) Use of bone graft substitutes in the management of tibial plateau fractures. *Injury* 44(Suppl 1):S86–S94. [https://doi.org/10.1016/S0020-1383\(13\)70019-6](https://doi.org/10.1016/S0020-1383(13)70019-6)
22. Egol KA, Tejwani NC, Capla EL et al (2005) Staged management of high-energy proximal tibia fractures (OTA types 41): the results of a prospective, standardized protocol. *J Orthop Trauma* 19:448–455 discussion 456

-
23. Freeman MAR, Pinskerova V (2005) The movement of the normal tibio-femoral joint. *J Biomech* 38:197–208. <https://doi.org/10.1016/j.jbiomech.2004.02.006>
 24. Heiney JP, Redfern RE, Wanjiku S (2013) Subjective and novel objective radiographic evaluation of inflatable bone tamp treatment of articular calcaneus, tibial plateau, tibial pilon and distal radius fractures. *Injury* 44:1127–1134. <https://doi.org/10.1016/j.injury.2013.03.020>
 25. Ornetti P, Parratte S, Gossec L et al (2008) Cross-cultural adaptation and validation of the French version of the knee injury and osteoarthritis outcome score (KOOS) in knee osteoarthritis patients. *Osteoarthritis Cartilage* 16:423–428. <https://doi.org/10.1016/j.joca.2007.08.007>
 26. Giannoudis PV, Harwood PJ, Kontakis G et al (2009) Long-term quality of life in trauma patients following the full spectrum of tibial injury (fasciotomy, closed fracture, grade IIIB/IIIC open fracture and amputation). *Injury* 40:213–219. <https://doi.org/10.1016/j.injury.2008.05.024>
 27. Welch RD, Zhang H, Bronson DG (2003) Experimental tibial plateau fractures augmented with calcium phosphate cement or autologous bone graft. *J Bone Joint Surg Am* 85–A:222–231
 28. Jiang R, Luo C-F, Wang M-C et al (2008) A comparative study of less invasive stabilization system (LISS) fixation and two-incision double plating for the treatment of bicondylar tibial plateau fractures. *Knee* 15:139–143. <https://doi.org/10.1016/j.knee.2007.12.001>